

Routine Mucosal Closure with a Detachable Snare and Clips after Endoscopic Submucosal Dissection for Gastric Epithelial Neoplasms: A Randomized Controlled Trial

Bo-In Lee*, Byung-Wook Kim*, Hyung-Keun Kim[†], Hwang Choi*, Jeong-Seon Ji*, Sun-Mee Hwang*, Young-Seok Cho[†], Hiun-Suk Chae[†], and Kyu-Yong Choi[‡]

*Division of Gastroenterology, Department of Internal Medicine, Incheon St. Mary's Hospital, The Catholic University of Korea College of Medicine, Incheon, [†]Division of Gastroenterology, Department of Internal Medicine, Uijeongbu St. Mary's Hospital, The Catholic University of Korea College of Medicine, Uijeongbu, and [‡]Division of Gastroenterology, Department of Internal Medicine, Seoul St. Mary's Hospital, The Catholic University of Korea College of Medicine, Seoul, Korea

Background/Aims: The aim of this study was to determine whether the routine closure of mucosal defects after endoscopic submucosal dissection (ESD) can enhance mucosal healing and reduce ESD-associated bleeding. **Methods:** Patients with gastric epithelial neoplasias and no obvious submucosal invasion were prospectively enrolled. Mucosal defects were left untreated in the control group. In the study group, mucosal closure was attempted with a 2-channel endoscope, a detachable snare, and clips. All participants received a second-look endoscopy the day after ESD, and coagulation therapy was administered to patients with visible vessels and active bleeding points. **Results:** Fifty-two patients were enrolled in the study, and 26 patients were assigned to each group. Complete mucosal defect closure occurred in 16 patients (61%) in the study group; incomplete closure occurred in 8 patients (31%) in the study group, and failed closure occurred in 2 patients (8%). Coagulation therapy at the second-look endoscopy was performed more often in the control group than in the study group (31% vs 4%, $p=0.024$). There were no significant differences in the incidence of immediate or delayed bleeding or in the two-week decrease in hemoglobin between the groups. The prevalence of open ulcers after 8 weeks was significantly lower in the study group than in the control group (18% vs 43%, $p=0.012$). **Conclusions:** Routine mucosal closure after ESD supports earlier healing of artificial ulcers. A larger-scale trial is necessary to determine whether mucosal closure can reduce ESD-associated bleeding. (**Gut Liver 2011;5:454-459**)

Key Words: Stomach neoplasms; Endoscopic submucosal dissection; Closure

INTRODUCTION

The development of endoscopic submucosal dissection (ESD) has enabled the en bloc resection of larger gastrointestinal neoplasms.^{1,2} However, ESD-associated complications such as perforation and bleeding are still serious considerations. Some studies have shown that postoperative bleeding occurs in approximately 6% to 16% of patients after gastric ESD.³⁻⁵ While surgeons almost always approximate and close surgical wounds after surgery, a mucosal defect remains following gastric ESD. Such defects may be associated with complications such as bleeding.

Mucosal closure with clips is not always feasible, especially for larger defects after ESD.⁶ However, we have shown that larger mucosal defects can be closed with a two-channel endoscope, a detachable snare, and clips.⁷ Other researchers have used a comparable method to close mucosal defects after colorectal endoscopic mucosal resection (EMR).⁸

This study was performed to determine whether the routine closure of mucosal defects after ESD with a detachable snare and clips can enhance mucosal healing, shorten hospital stays, and reduce ESD-associated complications.

Correspondence to: Byung-Wook Kim

Division of Gastroenterology, Department of Internal Medicine, Incheon St. Mary's Hospital, The Catholic University of Korea College of Medicine, 665 Bupyeong-dong, Bupyeong-gu, Incheon 403-720, Korea

Tel: +82-32-280-5052, Fax: +82-32-280-5987, E-mail: gastro@catholic.ac.kr

Received on February 22, 2011. Revised on March 30, 2011. Accepted on April 10, 2011.

pISSN 1976-2283 eISSN 2005-1212 <http://dx.doi.org/10.5009/gnl.2011.5.4.454>

© This is an Open Access article distributed under the terms of the Creative Commons Attribution Non-Commercial License (<http://creativecommons.org/licenses/by-nc/3.0>) which permits unrestricted non-commercial use, distribution, and reproduction in any medium, provided the original work is properly cited.

MATERIALS AND METHODS

1. Study subjects

This randomized controlled trial was carried out at Incheon St. Mary's Hospital, The Catholic University of Korea in Incheon, Korea between January 2008 and August 2009. The protocol was approved by the Institutional Review Board. Eligible patients had gastric epithelial neoplasias (noninvasive low grade dysplasia, noninvasive high grade dysplasia, or invasive neoplasia without obvious submucosal invasion).⁹ The depth of invasion was estimated primarily by gross findings. Endoscopic ultrasonography (EUS) was performed when the depth of invasion could not be assessed by gross findings only. All biopsy specimens from the body and antrum were stained using the Warthin-Starry method to identify *Helicobacter pylori* infection at the preoperative endoscopy.

Patients were excluded from the study if they had received anticoagulant, or had a coagulation disorders, end-stage renal disease, severe cardiopulmonary disorder, or undifferentiated cancer. Patients were also excluded if they were scheduled to receive ESD for multiple gastric lesions or a locally recurrent lesion after a previous EMR or ESD. Patients were also excluded if a clip was applied to control profuse bleeding or to close an obvious or impending perforation during the procedure. Patients with neoplasia at the cardia, fundus, or upper one third of corpus were not included because mucosal closure with a detachable snare and clips often cannot be performed at those locations.

Antiplatelet agents, including aspirin, were stopped one week before ESD and were then withdrawn for three weeks under the supervision of the cardiologist or neurologist.

2. ESD

All ESD procedures were performed by one physician (B.W.

Kim). During the procedure, patients were under conscious sedation with midazolam (0.05 mg/kg) and pethidine (50 mg); additional doses were given according to the physician's instructions.

A conventional gastroscope (GIF-Q240X; Olympus, Tokyo, Japan) fitted with a transparent distal attachment (D-201-11304; Olympus) was used for the ESD procedures. The margin of the tumor was determined by gross findings and indigocarmine chromoscopy. Circumferential markings were generated with argon plasma coagulation, effect 2 (ARCO 3000; Söring GmbH, Quickborn, Germany), 0.5 cm from the margin of the tumor. After a mixture of 0.9% normal saline and 0.0005% epinephrine was injected into the submucosal layer, a precut was made outside the marking with a hook knife (KD-620LR; Olympus) and an Endocut-I current (effect 1, duration 3, interval 3; VIO300D; ERBE Elektromedizin GmbH, Tübingen, Germany). Submucosal dissection was performed mainly with a hook knife and a forced coagulation current (effect 2, 40 W). A coagrasper (FD-410LR; Olympus) and a soft coagulation current (effect 7, 80 W) was primarily used to control bleeding.

ESD was performed as extensively as possible for complete removal of the lesion. When extreme difficulty was encountered during the submucosal dissection for any reason (e.g., severe fibrosis or profuse bleeding), snaring with an Endocut-Q current was allowed for the final excision.

The size of the resected specimen/mucosal defect was measured with a 3-cm flexible linear probe, and the area was estimated using the formula to calculate the area of an ellipse ($1/4 \times \pi \times \text{major axis} \times \text{minor axis}$).

3. Mucosal closure

Patients were randomly assigned to either a study group or a control group; attempts were made to close mucosal defects in the study group, and these defects were left untreated in the

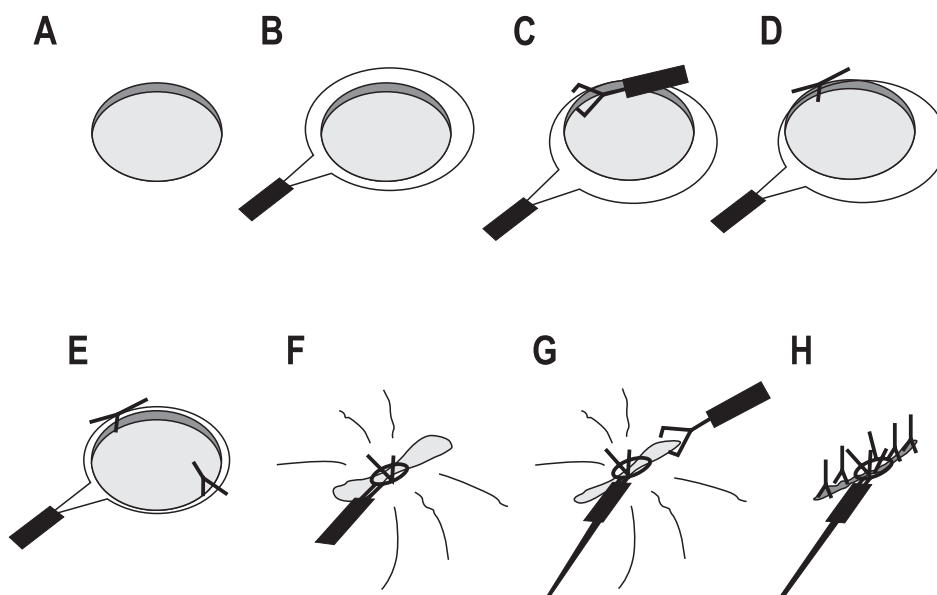


Fig. 1. Mucosal closure with a detachable snare and clips after endoscopic submucosal dissection. (A) A mucosal defect remains after ESD. (B) A detachable snare is deployed on the mucosal defect through a working channel, and a rotating clip-fixing device with a long clip is inserted through the other working channel. (C) The wire of the detachable snare is placed between both legs of the clip. (D) The clip is applied to the edge of the mucosal defect. (E) Another clip is applied to the opposite side of the mucosal defect in the same manner. (F) The snare is squeezed gently, and the mucosal defect is approximated. (G) Additional clips are applied to close the defect. (H) The defect is closed completely.

control group. Mucosal closure was performed with a double channel endoscope (GIF-2T200; Olympus), a detachable snare (HX-20Q; Olympus), and clips (HX-610-090L; Olympus) (Fig. 1).⁷ 'Complete closure' occurred when no submucosa or muscle was apparent after the closure (Fig. 2). 'Incomplete closure' occurred when the mucosal defect was still visible after the procedure but had clearly decreased in size. 'Failed closure' occurred when the size of the mucosal defect could not be decreased using the procedure.

4. Post-ESD protocol

Following the ESD procedure, pantoprazole (40 mg) was administered intravenously once a day for 3 days and then given to the patients orally. All participants received a second-look endoscopy on the day after ESD; during this endoscopy, dehiscence of the mucosal closure was assessed, particularly in the study group. Visible vessels or active bleeding was treated with a coagrasper and soft coagulation as described above.

Patients who did not receive coagulation therapy at the second-look endoscopy were allowed to eat a light meal the day after ESD. Those who did receive coagulation therapy were allowed to eat a light meal the day after the therapy. All patients were discharged from the hospital the day after oral intake was allowed unless they showed any signs or symptoms of complications (i.e., significant changes in vital signs, persistent abdominal pain, or tarry stools). Hemoglobin levels were checked daily during admission and a follow-up check was performed at the outpatient department 2 weeks after ESD. Pantoprazole was maintained for 6 weeks, and a follow-up endoscopy was performed 8 weeks after ESD.

5. Assessment

All specimens were fixed with formalin, cut into 2-mm slices

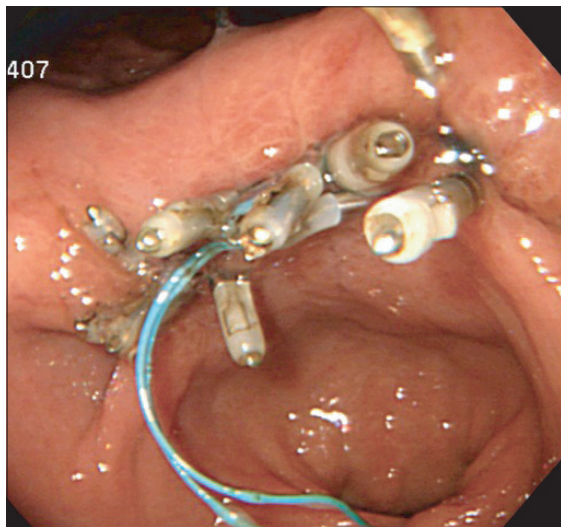


Fig. 2. The mucosal defect at the gastric angle is closed completely with a detachable snare and clips.

and examined. Histological assessment was performed according to the Vienna classification of gastrointestinal epithelial neoplasia.⁹

'Complete submucosal dissection' occurred when the lesion could be cut off without snaring. 'En bloc resection' was defined as a single-piece resection of the entire lesion where the rim of the artificial ulcer was tumor-free after ESD. 'Histologic complete resection' occurred when no neoplasia could be observed histologically in the lateral or deep margin of the resected specimen.

Immediate bleeding was defined as either a hemodynamic change or a necessary blood transfusion during or within 24 hours of the procedure. Delayed bleeding was defined as bleeding requiring transfusion or endoscopic hemostasis, or as a 2 g/dL or more decrease in hemoglobin concentration after 24 hours.

The ESD procedure time was measured from the insertion of the endoscope to its withdrawal and included the mucosal closure.

At the follow-up endoscopy 8 weeks after ESD, a closed ulcer was defined when complete epithelialization was achieved and no exudation or fibrin was observed.

6. Statistical analysis

A chi-square (χ^2) test was used to compare the sex ratio and the prevalence of *H. pylori* infection between the control and study groups. Fisher's exact test was used to compare the following variables between the two groups: recent use of antiplatelet agents, tumor location, the rate of complete submucosal dissection, en bloc resection and histologic complete resection, final histology, the frequency of coagulation therapy at the second-look endoscopy, and the incidence of immediate and delayed bleeding. Fisher's exact test was also used to examine the prevalence of open ulcers at 8 weeks after ESD in relation to

Table 1. Baseline Characteristics of the Control and Study Group

Characteristic	Control group	Study group	p-value
Sex			
Male	19 (73)	18 (69)	1.000
Female	7 (27)	8 (31)	
Age, yr	63.9±6.8	63.2±7.8	0.720
Recent use of antiplatelet agents	0 (0)	1 (4)	1.000
<i>H. pylori</i> infection	18 (70)	17 (65)	0.768
Location			
Body	8 (31)	7 (27)	0.324
Angle	3 (11)	1 (4)	
Antrum	13 (50)	18 (69)	
Pyloric ring	2 (8)	0 (0)	

Data are presented as mean±SD or number (%).

the completeness of mucosal closure in the study group.

The Student's *t*-test was used to compare age, procedure time, and decrease in hemoglobin 2 weeks following ESD. A Wilcoxon rank sum test was used to compare the area of the resected specimen, the area of the mucosal defect, procedure time per area of resected specimen, and duration of stay in the hospital between the control and study groups. The area of the mucosal defect that could be closed completely was also compared with the area that could not be closed completely using a Wilcoxon rank sum test.

A *p*-value of 0.05 was used to denote significance. SPSS version 12.0 (SPSS Inc., Chicago, IL, USA) was used for all statistical calculations.

RESULTS

Fifty-two patients were enrolled in the study; 26 patients

were randomly assigned to each group. EUS was performed in 13 patients (25%), and all the lesions were confined within the mucosal layer. There were no significant differences in sex, age, recent use of antiplatelet agents, or prevalence of *H. pylori* infection between the 2 groups. There was also no significant difference in the location of the neoplasia between the groups (Table 1). A second-look endoscopy was performed in all patients. A follow-up endoscopy was performed 8 weeks after ESD in 81% (21/26) of the control group patients and 85% (22/26) of the study group patients.

There were no significant differences in the area of the resected specimen or the mucosal defect between the control and study groups. A snare was used at the final stage of dissection in one case in each group. En bloc resection was performed in all cases, whereas histologic complete resection was not achieved in one case in the study group.

Among the control group, 11 (42%) patients had invasive

Table 2. Results of ESD between the Control and Study Group

Variable	Control group	Study group	<i>p</i> -value
Area of resected specimen, median (range), cm ²	10.3 (2.8–27.0)	7.7 (3.1–24.0)	0.164
Area of mucosal defect, median (range), cm ²	14.1 (5.9–30.0)	11.0 (4.5–37.7)	0.213
Complete submucosal dissection	25 (96)	25 (96)	1.000
En bloc resection	26 (100)	26 (100)	–
Histologic complete resection	26 (100)	25 (96)	1.000
Final histology			
Noninvasive low grade neoplasia	11 (42)	6 (23)	
Noninvasive high grade dysplasia	4 (16)	6 (23)	0.344
Intramucosal carcinoma	11 (42)	14 (54)	

Data are presented as median (range) or number (%).
ESD, endoscopic submucosal dissection.

Table 3. Mucosal Closure and Related Outcomes between the Control and Study Group

Variable	Control group	Study group	<i>p</i> -value
Procedure time, mean±SD, min	58.4±26.6	62.2±20.0	0.562
Elapsed time for mucosal closure, median (range), min	–	14.4 (7.4–32.1)	–
Procedure time/area of resected specimen, median (range), min/cm ²	4.6 (2.0–26.0)	6.8 (2.9–22.0)	0.026
Mucosal closure, n (%)			
Complete		16 (61)	
Incomplete	–	8 (31)	–
Failed		2 (8)	
Coagulation therapy at the second-look endoscopy, n (%)	8 (31)	1 (4)	0.024
Immediate bleeding, n	0	0	–
Delayed bleeding, n (%)	0 (0)	1 (4)	1.000
Hb decrease 2 wk after ESD, mean±SD, g/dL	0.3±0.7	0.0±0.9	0.273
Hospital stay, median (range), day	4 (3–13)	3 (2–4)	0.000
Open ulcer until 8 wk after ESD, n (%)	9 (43)	2 (9)	0.016

Hb, hemoglobin level; ESD, endoscopic submucosal dissection.

neoplasia, whereas 14 (54%) patients presented this condition in the study group. However, there was no case with submucosal invasion in either group (Table 2).

Although there was no significant difference in the overall procedure time between the control and study groups, there was a significant difference in the procedure time per area of resected specimen (Table 3). Among the study group, the mucosal defect could be closed completely in 16 cases (61%) and incompletely in 8 cases (31%). Mucosal closure failed in 2 cases (8%) because the mucosal edge where the clip was applied tore when the snare was squeezed. Among the study group, the median area of the mucosal defect that could be closed completely was 10.1 cm² (range, 4.5 to 23.0); the median area of the defect that could be closed incompletely or could not be closed was 14.5 cm² (range, 8.2 to 37.7; $p=0.053$).

At the second-look endoscopy, dehiscence occurred in 3 (19%) of the 16 patients whose mucosal defects had been closed completely. The area of dehiscence was enlarged in 3 (38%) of the 8 patients with incompletely closed mucosal defects. Eight patients in the control group received coagulation therapy for visible vessels or bleeding, while only one study group patient required coagulation therapy (31% vs 4%, $p=0.024$).

No patients experienced immediate bleeding. One patient in the control group developed acute pancreatitis after ESD that was resolved with conservative care. Delayed bleeding occurred in one study group patient 10 days after ESD; this patient's mucosal defect had been closed completely and the closure showed no dehiscence at the second-look endoscopy. However, an emergency endoscopy revealed complete dehiscence of the closure and black stigmata on the ulcer base. There was no significant difference in the 2-week hemoglobin decrease between the control and study groups. The length of stay in the hospital was significantly shorter in the study group than in the control group (median 3 days, 2 to 4 vs. 4 days, 3 to 13; $p=0.000$).

There was a significant difference in the prevalence of open ulcers 8 weeks after ESD between the control and study groups (43% vs 18%, $p=0.012$). However, in the study group, no significant relationship was observed between the prevalence of open ulcers 8 weeks after ESD and the completeness of mucosal closure (complete closure 8% vs incomplete closure 14% vs failed closure 0%; $p=1.000$).

One or two clips remained in 9 patients (41%) from the study group and no tumor recurrence was observed within 8 weeks after ESD in either the control or study groups.

DISCUSSION

We hypothesized that immediate closure of the artificial ulcer by ESD would decrease exposure of the submucosal vessels to gastric acid, pepsin, and mechanical stimuli and, therefore, would decrease ESD-associated bleeding. However, this study failed to confirm that routine mucosal closure after ESD can

reduce ESD-associated bleeding. Only one case of bleeding (2%) occurred among 52 ESD procedures; this rate is much lower than the bleeding rates reported in other studies.³⁻⁵ It is well known that proton pump inhibitors (PPIs) effectively prevent bleeding from the ulcer created after ESD,^{10,11} and in this study, a standard dose of pantoprazole was given to all participants intravenously for 3 days and then orally for 6 weeks. Coagulation therapy at the second-look endoscopy might also decrease bleeding rates in this study, although there is some debate over whether a second-look endoscopy after gastric ESD can contribute to the prevention of delayed bleeding.⁴ In addition, patients with a high risk of bleeding (i.e., those who received anticoagulation therapies, who have coagulation disorders, end stage renal disease, severe cardiopulmonary disease, or who required the application of clips to control profuse bleeding during submucosal dissection) were excluded from the study; these exclusions may have decreased the bleeding rate observed in the study. Small numbers of the subjects in each group is another limitation of the study.

Active bleeding or visible vessels were infrequently observed in the study group at the second-look endoscopy, and therefore, coagulation therapy was rarely necessary. However, stigmata might be covered by the mucosal closure in the study group. Finally, there was no significant difference in the incidence of immediate or delayed bleeding or in the hemoglobin decrease between the groups.

It is not conclusive that mucosal closure shortened hospital stay even though the duration was significantly shorter in the study group than in the control group. Patients who received coagulation therapy were allowed a meal 1-day later than those who did not, therefore the result of the second-look endoscopy might play as a primary determinant of hospital stay. In addition, the patient who developed acute pancreatitis in the control group was admitted for 13 days.

However, the present study did demonstrate that mucosal closure after ESD facilitated healing of the artificial ulcer. When the continuity of the mucosal epithelium of the gastrointestinal tract is disrupted, a process called 'restitution' occurs as viable epithelial cells migrate from areas adjacent to the injured surface to re-establish a barrier to the noxious substances within the lumen.^{12,13} Approximation with a detachable snare and clips is comparable to restitution because the process forces the migration of the mucosal layer to the artificial ulcer and reseals the barrier.

The prevalence of open ulcer 8 weeks after ESD in the control group seems to be higher than those in other studies.^{14,15} This may be because H3 stage ulcers were considered as open ulcers in this study and PPI was discontinued 2 weeks before a follow endoscopy.

One potential concern is that mucosal closure after ESD could conceal local recurrence of the tumor. However, there is currently no evidence that mucosal closure delays the detection of

local recurrence. When the resection margin is involved by the tumor, it is common practice in Korea and Japan to perform an additional endoscopic resection to prevent local recurrence. We consider it probable that the mucosal closure with a detachable snare and clips could be easily reopened for additional resection by the time the histopathologic report is available (3 to 5 days after ESD). A lateral resection margin was positive in a 50-year-old male with intramucosal carcinoma in the study group; however no remaining tumor was found at the second-look endoscopy, and the patient wanted only to be followed closely; there was no recurrence until the 6-month follow-up endoscopy.

The use of a detachable snare and clips is not always feasible in some locations and for large mucosal defects. Tumors located at the proximal stomach were excluded from the study because we recognized the use of this method was difficult at proximal locations during the pilot study period.⁷ Nevertheless, the mucosal defect could be closed completely only in 61% of the patients in the study group. Early dehiscence is another limitation. In addition, mucosal closure with a detachable snare and clips is a time-intensive procedure; a significant difference was observed in procedure time per area of resected specimen between the control and study groups. More effective methods are expected to be developed in the future.

We did not observe significant differences in the prevalence of open ulcers 8 weeks after ESD according to the completeness of mucosal closure in the study group. We postulate that this finding is mainly a result of the small numbers included in each subgroup among the study group patients who received a follow-up EGD (i.e., 13 patients with complete closure, 7 with incomplete closure, and 2 with failed closure). One limitation of the study is that we did not examine subjective symptoms, including pain after ESD.

In summary, the results of this study demonstrated that routine mucosal closure after gastric ESD can facilitate earlier healing of the mucosal defect. Larger-scale trials with different protocols are needed to further examine whether mucosal closure can reduce ESD-associated complications such as bleeding.

CONFLICTS OF INTEREST

No potential conflict of interest relevant to this article was reported.

REFERENCES

1. Fujishiro M, Yahagi N, Nakamura M, et al. Successful outcomes of a novel endoscopic treatment for GI tumors: endoscopic submucosal dissection with a mixture of high-molecular-weight hyaluronic acid, glycerin, and sugar. *Gastrointest Endosc* 2006;63:243-249.
2. Gotoda T. A large endoscopic resection by endoscopic submucosal dissection procedure for early gastric cancer. *Clin Gastroenterol Hepatol* 2005;3(7 Suppl 1):S71-S73.
3. Chung IK, Lee JH, Lee SH, et al. Therapeutic outcomes in 1000 cases of endoscopic submucosal dissection for early gastric neoplasms: Korean ESD Study Group multicenter study. *Gastrointest Endosc* 2009;69:1228-1235.
4. Goto O, Fujishiro M, Kodashima S, et al. A second-look endoscopy after endoscopic submucosal dissection for gastric epithelial neoplasm may be unnecessary: a retrospective analysis of postendoscopic submucosal dissection bleeding. *Gastrointest Endosc* 2010;71:241-248.
5. Oka S, Tanaka S, Kaneko I, et al. Advantage of endoscopic submucosal dissection compared with EMR for early gastric cancer. *Gastrointest Endosc* 2006;64:877-883.
6. Choi KD, Jung HY, Lee GH, et al. Application of metal hemoclips for closure of endoscopic mucosal resection-induced ulcers of the stomach to prevent delayed bleeding. *Surg Endosc* 2008;22:1882-1886.
7. Lee BI, Choi KY, Kim BW, et al. Approximation of large mucosal defects after endoscopic mucosal resection: a new technique using a detachable snare and clips. *Gastrointest Endosc* 2004;59:P150.
8. Matsuda T, Fujii T, Emura F, et al. Complete closure of a large defect after EMR of a lateral spreading colorectal tumor when using a two-channel colonoscope. *Gastrointest Endosc* 2004;60:836-838.
9. Schlemper RJ, Riddell RH, Kato Y, et al. The Vienna classification of gastrointestinal epithelial neoplasia. *Gut* 2000;47:251-255.
10. Uedo N, Takeuchi Y, Yamada T, et al. Effect of a proton pump inhibitor or an H2-receptor antagonist on prevention of bleeding from ulcer after endoscopic submucosal dissection of early gastric cancer: a prospective randomized controlled trial. *Am J Gastroenterol* 2007;102:1610-1616.
11. Oh TH, Jung HY, Choi KD, et al. Degree of healing and healing-associated factors of endoscopic submucosal dissection-induced ulcers after pantoprazole therapy for 4 weeks. *Dig Dis Sci* 2009;54:1494-1499.
12. Lacy ER. Epithelial restitution in the gastrointestinal tract. *J Clin Gastroenterol* 1988;10 Suppl 1:S72-S77.
13. Podolsky DK. Healing the epithelium: solving the problem from two sides. *J Gastroenterol* 1997;32:122-126.
14. Asakuma Y, Kudo M, Matsui S, et al. Comparison of an ecabet sodium and proton pump inhibitor (PPI) combination therapy with PPI alone in the treatment of endoscopic submucosal dissection (ESD)-induced ulcers in early gastric cancer: prospective randomized study. *Hepatogastroenterology* 2009;56:1270-1273.
15. Kawano S, Okada H, Kawahara Y, et al. Proton pump inhibitor dose-related healing rate of artificial ulcers after endoscopic submucosal dissection: a prospective randomized controlled trial. *Digestion* 2011;84:46-53.