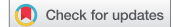
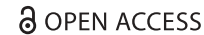
CASE REPORT



## Pulmonary alveolar proteinosis - a crazy presentation of dyspnea

Inge Raadal Skov<sup>a</sup>, Elisabeth Bendstrup <sup>b</sup> and Jesper Rømhild Davidsen <sup>a</sup>

<sup>a</sup>Department of Respiratory Medicine, Odense University Hospital, Odense, Denmark; <sup>b</sup>Department of Respiratory Medicine and Allergology, Aarhus University Hospital, Aarhus, Denmark

### ABSTRACT

This case report demonstrates 44-year old man, presenting with recurring clinical pneumonias during a period of over 1 year. The patient was clinically affected with, i.e., weight loss, finger clubbing and severely reduced diffusion capacity. Repetitive chest x-rays showed bilateral and consolidating infiltrates, and a high-resolution computed tomography of the thorax (HRCT) exposed ground glass opacities superimposed on a reticular pattern as the so-called 'crazy paving' pattern. A bronchoscopic alveolar lavage revealed alveolar proteinaceous material compatible with the diagnosis pulmonary alveolar proteinosis (PAP). PAP is a rare syndrome where surfactant is accumulated in the alveoli, causing respiratory disease in typically young to middle-aged patients with male predominance. Both symptoms and prognosis are variable, and range from spontaneous remission to terminal respiratory failure. The standard treatment is whole lung lavage, where surfactant is mechanically rinsed from the lungs. The lack of specific clinical symptoms makes it easy to overlook the diagnosis, as supported by this case report. It serves as a reminder, that the findings of a crazy paving pattern on HRCT in young adults should alert of this rare disease, and advises on the further examinations required to make the diagnosis.

### ARTICLE HISTORY

Received 22 June 2018  
Accepted 19 November 2018

### KEYWORDS

PAP; pulmonary alveolar proteinosis; GM-CSF; granulocyte-macrophage colony-stimulating factor; HRCT; crazy paving; WLL; whole lung lavage; rare lung disease

### Introduction

Pulmonary alveolar proteinosis (PAP) is a rare syndrome in which surfactant is accumulated in the alveoli causing respiratory symptoms typically in young to middle-aged people [1]. Both symptoms and prognosis are variable ranging from spontaneous remission to terminal respiratory failure [2]. The majority of cases are of autoimmune origin, but PAP also occurs as a congenital disease or secondary to inhalational exposures e.g. dust-silica and cellulose fibers or hematologic malignancies e.g. myeloproliferative diseases and myeloid leukemia [1]. PAP often debuts with insidious dyspnea at exertion and dry cough [3], which resembles a wide range of respiratory differential diagnoses. Patients with PAP related symptoms are at high risk of years of delayed diagnostics. Once diagnosed, it is recommended that the patients are managed and followed in specialized expert centers. In this case report, we describe that a crazy paving pattern in combination with specific blood assays and bronchoscopic examination made the diagnosis of the rare syndrome PAP.

### Case presentation

A 44-year-old man with an active smoking history of 50 pack-years was referred to the local Department of

Respiratory Medicine due to at least 1 year of declining general condition with recurrent episodes of acute respiratory worsening interpreted as pneumonias, weight loss of 10 kg, fatigue, dry cough, and progressive dyspnea. The patient had a noteworthy alcohol intake of approximate 49 units per week. He was working in an office environment and had, besides smoking, no other exposures. At physical examination finger clubbing was observed, and lung auscultation revealed bibasilar crackles.

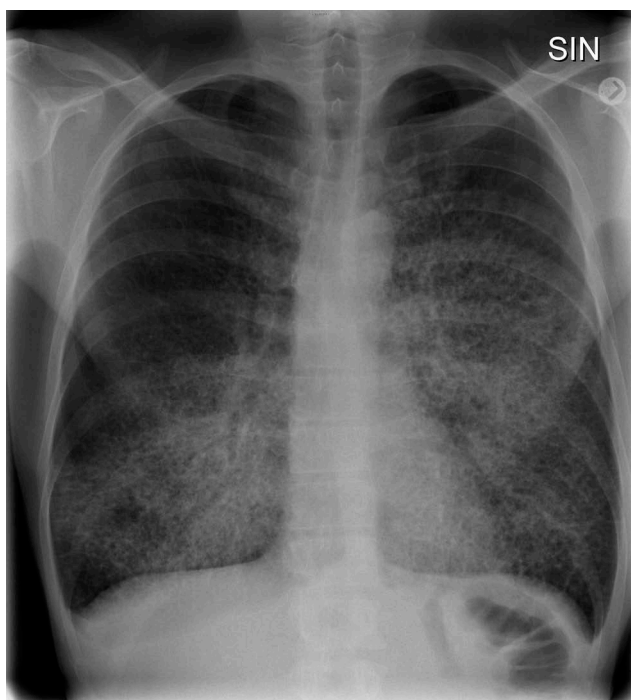
### Investigations

Spirometry showed a forced expiratory ventilation in 1 sec (FEV1) of 2.79 l (69% of predicted) and a forced vital capacity (FVC) of 4.04 l (81% of predicted) with an index of 69%. The diffusion capacity (diffusion capacity of the lung for carbon monoxide, DLCO) and coefficient (KCO) was 22%/32%, respectively. At rest, oxygen saturation was between 84 and 90% on room air, and a 6 min walking test with a walking distance of 490 m caused a significant desaturation of nine percent points from 89 to 78%. Biochemistry showed elevation of lactate dehydrogenase (339 U/l; reference 105–205 U/l). Repetitive chest x-rays (CXR) showed a reticular pattern and bilateral infiltrates

**CONTACT** Inge Raadal Skov  [inge.raadal.skov@rsyd.dk](mailto:inge.raadal.skov@rsyd.dk)  Department of Respiratory Medicine, Odense University Hospital, Denmark

© 2018 The Author(s). Published by Informa UK Limited, trading as Taylor & Francis Group.

This is an Open Access article distributed under the terms of the Creative Commons Attribution-NonCommercial License (<http://creativecommons.org/licenses/by-nc/4.0/>), which permits unrestricted non-commercial use, distribution, and reproduction in any medium, provided the original work is properly cited.



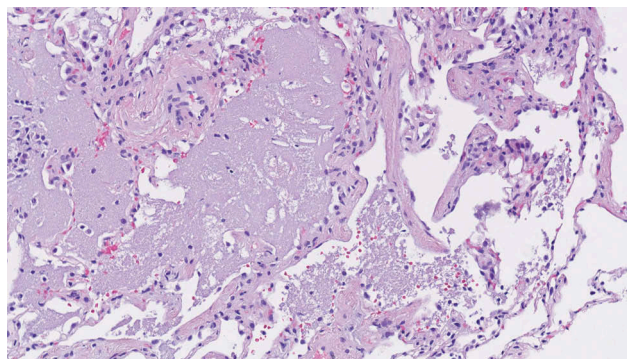
**Figure 1.** Chest X-ray often reveal bilateral symmetrical opacities centrally in mid and lower lung zones and sometimes reticular markings. Segmental atelectasis may occur due to obstruction. In chronic cases of PAP focal fibrosis may occur [1].

(Figure 1). High-resolution computed tomography (HRCT) of the thorax showed interlobular septal thickening with diffuse as well as interlobular ground glass opacities (GGOs) with fluctuating consolidation presenting in a ‘crazy paving’ pattern (Figure 2). A following bronchoalveolar lavage (BAL) revealed a milky white BAL fluid. Microbiological analyses of BAL were either normal or negative. Supplemental

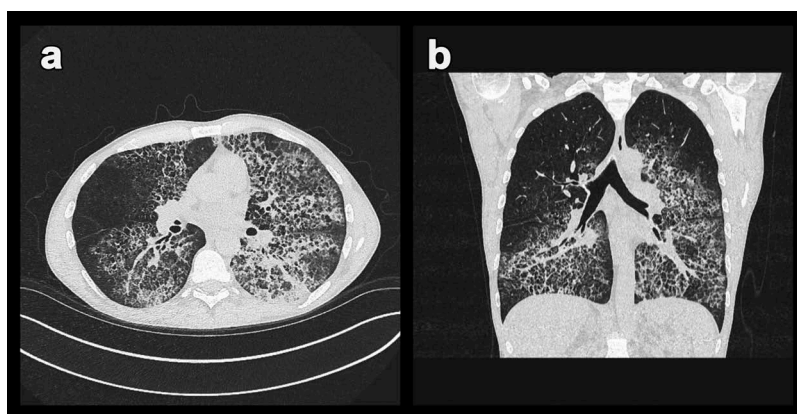
transbronchial biopsies (TBB) performed during bronchoscopy revealed intraalveolar accumulation of a proteinaceous material, which was consistent with the diagnosis PAP (Figure 3). A subsequent blood sample confirmed the diagnosis of autoimmune PAP due to positive anti-GM-CSF (granulocyte-macrophage colony-stimulating factor) antibodies.

### Differential diagnosis

Differential diagnoses of crazy paving pattern observed at HRCT are multiple and may include the following suspicions [4]: 1) *Bronchioloalveolar carcinoma*(BAC), a latent type of non-small cell lung cancer which may present with crazy paving pattern. However, the BAL and TBB were without malignant cyto-histology; 2) *Infectious pneumonia*, which was not suitable to the



**Figure 3.** Photomicrographs of the transbronchial lung biopsy showed massive filling of alveolar spaces with granular material. The alveolar septae were focally thickened, but otherwise the structure was intact. There were no signs of inflammation or malignancy.



**Figure 2.** A. Transversal and B.coronal HRCT image during inspiration, where PAP presents by the characteristic crazy paving pattern due to intraalveolar and interlobular interstitial accumulation of surfactant. It is distinctive by the combination of ground glass opacity and sharply delineated polygonal shaped secondary lobuli with septal thickening, giving rise to a cobblestone like pattern [4].

long time span without clinical presentation of fever, sputum production, positive microbiology, and without typical findings on thoracic imaging; 3) *Non-specific interstitial pneumonia*, which, the age in mind, predominantly presents in relation to a connective tissue disease (CTD). The latter was rather unlikely due to negative CTD symptoms and clinical signs, negative autoimmunology and furthermore not supported by the TBB findings; 4) *Eosinophilic pneumonia* was regarded unlikely due to the lack of blood and BAL eosinophilia; 5) *Pulmonary edema* secondary to heart failure, which did not fit the findings of a low pro-BNP (50 pmol/L), and though a transthoracic echocardiography was not performed, the patient did not present with classical symptoms or clinical findings of congestive heart failure; 6) *Diffuse alveolar hemorrhage* (DAH), which most often is characterized by anemia and hemoptysis. As neither of these symptoms were observed and nor blood or hemosiderin containing macrophages were present in BAL, DAH was not further pursued.

### Treatment

The standard treatment of PAP is whole lung lavage (WLL), where the surfactant is mechanically rinsed from the lungs with sterile saline during bronchoscopy, performed with the patient in general anesthesia. After three sessions of WLL over a period of 5 weeks, the patient experienced reduced symptoms along with a significant improvement in the DLCO from 22 to 38%. A follow-up HRCT showed evident regression of the interlobular septal thickening, but still with widespread GGO. The patient still suffered from impaired lung function, which was partially interpreted as due to the heavy smoking-status. Two more sessions of WLL were performed, but with only limited benefits on symptoms and lung physiological parameters.

### Follow-up

The patient was and is currently enrolled in a placebo-controlled pharmaceutical trial of inhaled molgramostim (GM-CSF substitution) (ClinicalTrials.gov identifier: NCT02702180). On this treatment, the patient is described as well-being without any respiratory complaints, and with an improved pulmonary function with a DLCO/KCO of 51%/53% and a FVC of 4.6 l (94% of predicted) compared to the initial values of 22%/32% and 4.04 l (81% of predicted), respectively.

### Discussion

PAP is a rare interstitial lung disease with an estimated annual incidence, and prevalence of 0.24–0.49 and 2.04–6.20 cases per million, respectively, for autoimmune PAP [3]. PAP is characterized by accumulation of surfactant protein in the alveoli typically due to macrophage dysfunction as a result of a defect in the GM-CSF pathway [5], reducing the macrophage maturation and their ability to clear surfactant, and, secondary, to clear lung infections. Depending on the severity, gas exchange is impaired resulting in a reduced diffusion capacity leading to dyspnea, cough, fatigue and weight loss, and subsequently respiratory failure. The median age at presentation is 39 years with a male predomination (male:female ratio 2.7:1.0) [2]. Approximately 90% of the PAP cases are associated with an autoimmune production of antibodies against GM-CSF [3]. The remaining 10% are either congenital or related to previous inhalational exposures (e.g. dust-silica, aluminum, titanium, cellulose fibers, flour) or hematologic malignancies (e.g. myeloproliferative diseases, myeloid leukemia, lymphoma) [1]. The symptoms are often vague and the onset is often slowly developing, and thereby delaying the diagnosis. The clinical presentation of dyspnea, cough, and weight loss is similar to other respiratory diseases, but symptoms and clinical presentation are variable [2,3]. One third of PAP patients are asymptomatic, while others unfortunately suffer from fatal respiratory failure. The lack of specific clinical symptoms makes it easy to overlook the diagnosis.

The diagnostic approach often consists of thoracic imaging as CXR and HRCT combined with bronchoscopic examinations. The BAL fluid typically has a milky-like appearance, characterized by a high content of period acid Schiff (PAS)-positive material. Biopsies are seldom necessary for the diagnosis, but might be performed to exclude malignant differential diagnoses as e.g. BAC. Histological examination will show lipoproteinaceous material in the terminal bronchioles with no or little inflammation and a preserved architecture of the alveoli, though often focally thickened septa (Figure 3). Lactate dehydrogenase is elevated in up to 80% of patients with PAP [1]. Pulmonary function tests will typically show a restrictive lung function pattern and a reduced DLCO. The finding of anti-GM-CSF autoantibodies is diagnostic for autoimmune PAP. Secondary PAP is diagnosed based on a history of exposures such as hematologic diseases or inhalation agents and the lack of antibodies, while congenital PAP rests on genetic testing [1]. The standard



treatment of autoimmune PAP is WLL, where the excess surfactant is mechanically cleansed from the lungs [6]. Reiterated treatments are often necessary. If WLL is not tolerable or not effective, administration of GM-CSF protein as inhalation has shown effects, but the treatment is under investigation and still not approved. Rituximab (an anti-CD 20 B-cell antibody) has been reported with beneficial clinical outcome due to improved DLCO, CT scan, symptoms, and in case reports corresponding a reduced number of GM-CSF antibodies. In the case of progressive terminal respiratory failure despite of attempts with the mentioned treatment modalities, lung transplantation may be the last choice of treatment, but has only been described in a few cases [6].

## Conclusion

Our case supports the above-mentioned latency in diagnostics, and describes the typical symptoms and improvement due to treatment with WLL and CM-CSF substitution in autoimmune PAP. Despite the rarity of PAP, the HRCT crazy paving presentation in young, and predominant male adults should alert the clinician of a potential rare disease that requires further examination in order to make the correct diagnosis and provide the best treatment.

## Learning points

- Crazy paving is a radiological pattern on chest HRCT with GGOs and consolidations with interlobular septal thickening.
- Findings of crazy paving on HRCT and milky white BAL should raise suspicion of PAP.
- PAP is a rare cause of respiratory failure with symptoms such as slowly progressive dyspnea, dry cough, fatigue, and weight-loss in weeks to months.
- Among adults, autoimmune PAP is most frequent and mostly in middle-aged men.
- The standard treatment for autoimmune PAP consists of whole lunge lavage, but administration of GM-CSF or rituximab are alternatives at the experimental stage.

## Disclosure statement

No potential conflict of interest was reported by the authors.



## Notes on contributors

*Inge Raadal Skov*, MD, received her medical degree from the University of Southern Denmark in 2016. She is now a young doctor at the Department of Respiratory Medicine, Odense University Hospital, Denmark, where she will begin her PhD study within the field of respiratory medicine commencing in 2019.

*Elisabeth Bendstrup*, MD, PhD, is a consultant at Department of Respiratory Diseases and Allergy, Aarhus University Hospital, Denmark. She is a specialist in pulmonary diseases, and her main research focus is interstitial lung diseases.

*Jesper Rømhild Davidsen*, MD, PhD, completed his Medical degree from the University of Southern Denmark in 2002, and his PhD in asthma pharmacoepidemiology from the Research Unit of General Practice, University of Southern Denmark in 2011. Jesper is a consultant in internal and respiratory medicine at the South Danish Center for Interstitial Lung Diseases at Department of Respiratory Medicine, Odense University Hospital, Denmark. Jesper is Research Associate Professor at Institute of Clinical Research, University of Southern Denmark, Denmark. Jespers main research area is interstitial lung diseases, lung-transplantation, and lung ultrasound.

## ORCID

Elisabeth Bendstrup  <http://orcid.org/0000-0002-4238-6963>  
 Jesper Rømhild Davidsen  <http://orcid.org/0000-0003-4128-4014>

## References

- [1] Kumar A, Abdelmalak B, Inoue Y, et al. Pulmonary alveolar proteinosis in adults: pathophysiology and clinical approach. *Lancet Respir Med*. 2018 Jan 31:S2213-2600(18)30043-2. Epub ahead of print. DOI:10.1016/S2213-2600(18)30043-2
- [2] Seymour JF, Presneill JJ. Pulmonary alveolar proteinosis: progress in the first 44 years. *Am J Respir Crit Care Med*. 2002;166:215–235.
- [3] Inoue Y, Trapnell BC, Tazawa R, et al. Characteristics of a large cohort of patients with autoimmune pulmonary alveolar proteinosis in Japan. *Am J Respir Crit Care Med*. 2008;177:752–762.
- [4] De Wever W, Meersschaert J, Coolen J, et al. The crazy paving pattern: a radiological pathological correlation. *Insights Imaging*. 2011;2:117–132.
- [5] Tanaka N, Watanabe J, Kitamura T, et al. Lungs of patients with idiopathic pulmonary alveolar proteinosis express a factor which neutralizes granulocyte-macrophage colony stimulating factor. *FEBS Lett*. 1999;442:246–250.
- [6] Leth S, Bendstrup E, Vestergaard H, et al. Autoimmune pulmonary alveolar proteinosis: treatment options in year 2013. *Respirology*. 2013;18:82–91.