

Post-traumatic anosmia in patients with mild traumatic brain injury (mTBI): A systematic and illustrated review

Phileas J. Proskynitopoulos, Martina Stippler, Ekkehard M. Kasper

Department of Neurosurgery, Beth Israel Deaconess Medical Center, Boston, USA

E-mail: Phileas J. Proskynitopoulos - phileas.proskynitopoulos@stud.mh-hannover.de; Martina Stippler - mstippler@bidmc.harvard.edu;

*Ekkehard M. Kasper - ekasper@bidmc.harvard.edu

*Corresponding author

Received: 27 January 16 Accepted: 01 April 16 Published: 06 May 16

Abstract

Background: Olfactory dysfunction (OD) is a disorder associated with traumatic brain injury (TBI), which is prevalent in up to 20% of patients suffering from TBI. Nevertheless, most studies focusing on the relationship between OD and TBIs do not differentiate between the different types of TBI (mild, medium, and severe). In this paper, we conducted a comprehensive and systematic review of the existing literature for the association between mild TBI (mTBI) and OD in order to examine their relationship, focusing on its neurosurgical management and the radiographic characteristics.

Methods: The MEDLINE database was systematically reviewed according to the Preferred Reporting Items for Systematic Reviews and Meta-analyses guidelines. We found 66 articles, of which 10 fulfilled our criteria.

Results: All except two studies reported a significant association between trauma severity and olfaction. Two studies found a negative correlation between TBI severity and olfactory bulb volume with one reporting an r value of -0.62). Three studies reported an association between the observation of radiographic intracranial hemorrhage or skull base fractures and the history of TBI.

Conclusion: According to our search results, we conclude that OD is a prevalent but underdiagnosed problem in mTBI. Because OD is associated with a significant decrease in quality of life, we think that neurosurgical teams need to assess olfactory function in mTBI patients when they report to clinics. To illustrate this scenario, we include two distinct cases of patients with anosmia after mTBI in this review. Finally, we suggest a treatment algorithm for patients with mTBI so that a possible OD can be diagnosed and treated as early as possible.

Key Words: Anosmia, head trauma, olfactory dysfunction, traumatic brain injury

Access this article online

Website:

www.surgicalneurologyint.com

DOI:

10.4103/2152-7806.181981

Quick Response Code:



INTRODUCTION

Anosmia is defined as the general inability to perceive olfaction and represents the most profound olfactory dysfunction (OD). OD can be due to different pathophysiological mechanisms; it can either be a primary dysfunction and developed embryologically (e.g., due to telencephalic maldevelopment or from peripheral lesions involving the olfactory fibers at the level of the

This is an open access article distributed under the terms of the Creative Commons Attribution-NonCommercial-ShareAlike 3.0 License, which allows others to remix, tweak, and build upon the work non-commercially, as long as the author is credited and the new creations are licensed under the identical terms.

For reprints contact: reprints@medknow.com

How to cite this article: Proskynitopoulos PJ, Stippler M, Kasper EM. Post-traumatic anosmia in patients with mild traumatic brain injury (mTBI): A systematic and illustrated review. *Surg Neurol Int* 2016;7:S263-75.
[http://surgicalneurologyint.com/Post-traumatic-anosmia-in-patients-with-mild-traumatic-brain-injury-\(mTBI\)-A-systematic-and-illustrated-review/](http://surgicalneurologyint.com/Post-traumatic-anosmia-in-patients-with-mild-traumatic-brain-injury-(mTBI)-A-systematic-and-illustrated-review/)

cribriform plate) or it can be due to impairment of any of the intracranial relay stations. In the latter scenarios, it may involve any of the central pathways such as the olfactory bulb (OB) and olfactory tract (OT), as well as the orbitofrontal cortex, the frontal lobe, and the antero-inferior part of the temporal lobe, the piriform cortex, the periamygdaloid cortex, the amygdala proper as well as the entorhinal cortex and the entorhinal tubercle.^[28,33,34,49,50]

However, most frequently it is an acquired dysfunction and follows traumatic brain injury (TBI), with some studies suggesting that as many as 5% to 20% of individuals suffering from OD had sustained a preceding head trauma.^[31] This translates into a rate of 5% to 16%^[3,43] and in some studies to 30%^[4] of head trauma patients subsequently suffering from OD.

Imaging diagnostics

Magnetic resonance imaging (MRI) studies have shown that, for TBI patients, the brain regions most frequently associated with OD are the OB and the OT, the temporal lobe, and the subfrontal lobe.^[49,50] In general, a decrease in OB volume is associated with OD, which has been shown in functional MRI studies for patients with OD due to TBI.^[25,34,49] This observation is corroborated by observations made for other OD conditions such as chronic inflammation,^[38,49,50] schizophrenia,^[32,44] and some neurodegenerative diseases such as Alzheimer disease.^[35] In a review by Rombaux, Duprez, and Hummel, the authors pointed out that a decrease in OB volume generally correlates with OD; although in their paper this correlation was only valid for retronasal as opposed to orthonasal odor identification.^[34] Strong evidence exists which shows that, in particular, the volume of the OB can change over time after the recovery of olfactory function (OF) has been demonstrated.^[6,18,34]

Brain areas and functional tests associated with olfactory dysfunction

Research over the past several years has produced strong evidence that the entorhinal cortex and the OB are neuronal structures that display neuroplasticity and most importantly have the potential for significant regeneration.^[28,46] Dramatically different recovery rates have been reported for both peripheral and central lesions in animals^[7,28,31,48] and humans,^[29,46] with peripheral regeneration being better understood and more extensively examined than central regeneration.^[28] Recovery rates have been studied by employing the so called “Sniffin Sticks” test (SST) in order to test a measurable improvement in OF over time.^[22] For both post-infectious as well as post-traumatic patient populations, studies have reported significantly improved scores for OF when compared to baseline, which was assessed initially.^[29] Of note, the reported increase in OF was less for post-traumatic patients; in one study, 67.8% of patients previously

suffering from upper respiratory tract infections improved whereas only 32% of post-traumatic patients showed recovery of some OF.^[29] Using the SST, odor threshold, discrimination, and identification (TDI) can be assessed and quantified into a TDI-score. Any value below 16.5 is interpreted as anosmia, between 16.5 and 30.5 as hyposmia, and above 30.5 as normosmia.^[29] The University of Pennsylvania Smell Identification Test (UPSIT) consists of four test booklets containing 10 odorants each, resulting in a total of 40 distinct measures.^[10,13] The odorant is released by the so called “scratch ‘n’ sniff” technique, i.e., by scratching the surface of the capsule with a pencil. For evaluation purposes, each odor is rated with four options; “This odor smells mostly like: a) Banana, b) orange, c) leather, d) mint.”^[10,13] It has been shown to have a high reliability ($r = 0.94$).^[11]

Recovery of olfactory dysfunction post-traumatic brain injury

The recovery rate of any OF depends on several clinical factors other than the anatomical location of the lesion alone. In 1995 Ikeda *et al.* looked at a group of patients who all had previously suffered some form of head trauma. The authors tried to examine the influence of steroids in this setting, namely bethamason or prednisolone (30–60 mg at the beginning, followed by tapering of the dose), and examined the recovery of OF in 20 such patients.^[23] From this study, it was concluded that steroids help to regenerate OF, and for observed OF recovery, there was a correlation to the period that had passed between the moment of traumatic injury and the beginning of the treatment.^[15,23] Jiang used the following dosage scheme of prednisolone: 15 mg QID for 3 days, 10 mg QID for 3 days, 10 mg TID for 3 days, 10 mg BID for 3 days, and 5 mg BID for 3 days, combined with a follow up testing of OF using the phenyl ethyl alcohol (PEA) odor detection threshold test. In this study, 16.4% of patients had improvement in OF after steroid treatment, whereas in Fujii’s study the ratio of improvement was 6 out of 18 patients.^[15,26] However, the authors discussed that the interval between the injury and the beginning of the treatment was not controlled, possibly having a negative influence on the measured effect of steroids. In addition to this, the authors suggested that the improvement of OF can be partly explained by spontaneous regeneration (sometimes in one-third of patients)^[28] and the removal of hematoma or edema in the affected olfactory regions.^[23]

The relationship between trauma severity and olfactory dysfunction

Several authors have suggested that the pathophysiology of anosmia in TBI patients is correlated to the trauma severity (e.g., as defined by the Glasgow Coma Scale (GCS), the duration of Post-Traumatic Amnesia (PTA), or Loss of Consciousness (LOC)). Several studies have

reported a strong association between OD and the severity of TBI.^[12,29,50] Both, strong as well as moderate TBI are highly associated with OD.^[37] mTBI, on the other hand, has been less investigated; a case report published in 2000 described a patient who had suffered from total anosmia following mTBI.^[26] In addition, Schofield *et al.* concluded in their systematic review that, for the studies they examined, in the case of mTBI, the outcome for the ability to smell did not differ significantly between individuals who had sustained a mTBI and those in the control groups.

The purpose of our review

To the best of our knowledge, there are no reviews that have specifically examined the relationship between mTBI with its neurosurgical management as well as simultaneously examined the radiographic characteristics in patients suffering from OD. Therefore, we conducted a comprehensive review on this topic to present a coherent picture of the current state of research in this area, which we also illustrate with two distinct cases. The presented clinical vignettes will give an example of how our institution managed two exemplary patients who suffered mTBI and developed post-traumatic anosmia. Despite very similar mechanisms of injury and comparable clinical presentations, one of the patients has since then recovered her olfactory sense whereas the other patient has not. Therefore, we will try to address the following questions:

- Is there evidence about an association between mTBI, OD, and certain radiographic characteristics?
- Why do both anosmia and OD remain a frequently underdiagnosed problem in patients suffering from mTBI?
- In what way could the neurosurgical management of patients suffering from mTBI be altered in order to ensure a more promising rehabilitation of patients suffering from post-traumatic OD?

CASE ILLUSTRATION #1

In 2010, a 56-year-old female reported to our clinic after being struck by a car. On arrival, the patient was amnesic to the event and could not recall the actual accident or her trip to the hospital. Her GCS was assessed as 14 and the patient was stable, alert but slightly confused, although she was oriented to herself and the date. The neurological examination showed a post-concussive syndrome, and all other investigations were without any pathological findings. No surgical intervention was necessary.

As part of her trauma and TBI work up, the on-call neurosurgeon requested a CT scan of the skull without contrast [Figure 1]. Imaging showed a left-sided occipital bone fracture extending through the condyle centrally also involving the right-sphenoid sinus and opacification of the right sphenoid sinus, which was suggestive of associated

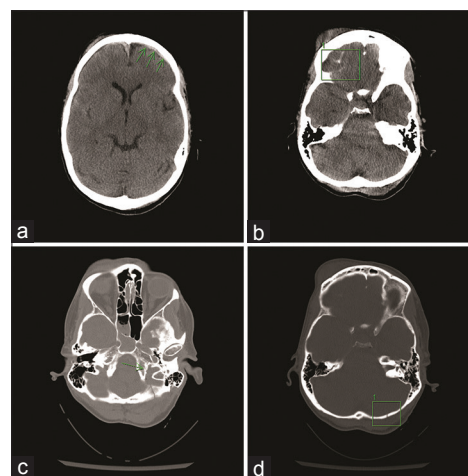


Figure 1: Acute injury CT exam (a-d): (a) Axial frontal subdural hematoma left (b) axial frontal subdural hematoma (c) occipital fracture 1 (d) occipital fracture 2

hemorrhage. Soft tissue windows revealed small bilateral frontal subdural hematomas as well as subarachnoid hemorrhage over the right frontal lobe. Some subgaleal hemorrhage was reported, located superiorly in the left frontal region and inferiorly in the right frontal region. Neither a shift of midline structures, herniation nor intraventricular hemorrhage was observed. A subcentimeter incidental calcified parafalcine lesion was also found by imaging, which was suggestive of meningioma; however, this bears no clinical relevance for this case. Trauma CT of the torso revealed left superior and inferior pubic rami fractures, a left sacral and parasymphiseal fracture, as well as a left clavicular fracture, all reflecting the significant impact of the incident.

The patient was monitored in the intensive care unit. Head CT was repeated after 12 h to assess the intracranial hemorrhage (ICH) for potential blossoming of the contusions and expansion of the subdural haemorrhage (SDH) and subarachnoidal haemorrhage (SAH). Follow-up imaging showed no new foci of ICH. She did not develop hydrocephalus and there was no progression of ICH. She was discharged four days after her accident without any other recorded neurological abnormalities.

Several months later, the patient was re-evaluated in our outpatient clinic for follow up where she reported complete anosmia. No other neurological deficits were found on examination. An MRI was obtained to investigate the cause of her symptoms. No persistent or new extra-axial fluid collection or new ICH was reported. Ventricles and extra-axial cerebrospinal fluid (CSF) spaces were normal in size and configuration. MRI revealed signs of frontobasal encephalomalacia. [Figure 2]. In addition to this, an incidental nearly empty sella was described, however, its significance was uncertain.

Annual office visits for re-evaluation with a repeat of qualitative tests (smelling burned matches/cinnamon/

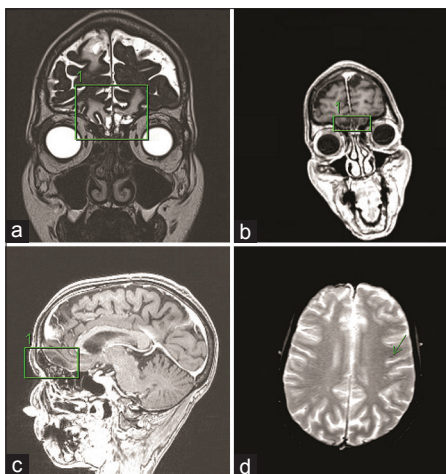


Figure 2: Delayed MRI exam: (a) Coronal T2 encephalomalacia (b) coronal films showing encephalomalacia (c) sagittal image showing frontal encephalomalacia (d) small GRE heme

coffee) for her persistent anosmia were conducted. She denied any neurological symptoms such as headache, nausea, vomiting, dizziness, or seizures or difficulty with bowel or bladder function. Examination confirmed the retained ability to taste all qualities of salty, sour, sweet, and bitter, but the patient reported a complete loss of aromatic sensations (smelling coffee, cinnamon, cloves, and food). Repeat MRI revealed no new abnormalities except the abovementioned frontobasal encephalomalacia and mild hemosiderin deposits on GRE-sequences reflecting her prior ICH. Her anosmia was explained by the mechanism of her prior head trauma resulting in a shear injury to the nerve fibers transversing the cribriform plate, the fila olfactoria. It was explained to her that regeneration of these nerve fibers and subsequent regaining of her sense of smell would be unlikely. The patient has been followed up by sequential examinations and imaging since then, and as of now, nearly five years after her TBI, she remains neurologically at her baseline without signs of functional recovery of olfaction. This case has led to complex assessments throughout the course of discovery during prolonged litigation, which most recently was settled by arbitration and has made legal history, being the first case of anosmia settled in favor of the plaintiff.^[41]

CASE ILLUSTRATION #2

In August 2005, a 22-year-old woman reported to our clinic after being struck by a car while she was jogging. She suffered loss of consciousness at the scene but recovered to a GCS of 14 when she arrived at the hospital. When she was asked what happened, she was found to be amnesic and could not recall the actual accident or the ambulance trip.

Neurological examination upon arrival revealed that the patient was somnolent but arousable by voice. She was

oriented to person but was unable to recite months or year without falling asleep. Her comprehension was good and she was able to follow commands, however, she was only speaking in short, laconic sentences. No dysarthria or paraphrasic errors were noted during the examination. All cranial nerves except the olfactory nerve were tested and no abnormalities were recorded. Her motor strength, sensation, and coordination were all found to be intact. She was assessed by orthopedic surgery for other injuries, which included fractures of her pelvis and left knee.

Following the trauma bay examination, a CT scan of the head was obtained. Imaging revealed a right skull base fracture involving the occipital bone, some minimal subarachnoid blood as well as pneumocephalus in the right posterior-fossa due to a mastoid fracture [Figure 1]. Detailed neurosurgical examination did not reveal a CSF leak. No carotid dissection was noted on CTA.

The patient received hydromorphone, trazodone, and ondansetron for her pain and nausea and was discharged on post-trauma day three in stable general condition with instructions to follow-up in our clinics.

Three months later, a follow-up neurological examination was performed in our outpatient clinic for reassessment. During the examination, the patient reported complete olfactory loss as her only symptom, but denied any other complaints such as headache, nausea, vomiting, dizziness, or seizures. She was also found to be neurologically intact. We disclosed to her during this clinic visit that this particular disability is most frequently observed in patients with closed head injury and associated fractures of the occipital bone. We explained to the patient that her anosmia was most likely due to a shearing of the fine nerves of the fila olfactoria and tearing at the olfactory bulb, and our advice was to consult a neurologist or an ENT specialist during follow-up in order to get a full olfactory evaluation and some suggestions for possible therapy. We concluded that no neurosurgical intervention was indicated and we would follow her expectantly only. The patient was devastated by the news of the likely permanent loss of her sense of smell as she intended to go to an esteemed culinary school in New York. The patient was later assessed at an outside facility including further radiographic studies using MRI, which showed a very minor amount of subarachnoidal hemosiderin deposits from her preceding SAH but did not reveal any post-traumatic parenchymal signal changes (films not shown).

Since her injury, and after a 12-month period of complete anosmia, she has regained most of her ability to perceive aromatic scents. Her multifaceted personal reflection on this life changing experience was later expressed in an autobiographic book titled "Season to taste."^[5]

We were puzzled by the difference in outcome of these two individual patients, who presented with nearly

identical injury patterns; hence, we set out to examine the relationship between such seemingly mTBI and its neurosurgical management and decided to simultaneously look at the radiographic characteristics of patients who were found to suffer from post-traumatic OD.

METHODS

Literature search

The review of available publications was conducted using the EBSCO Host search engine in September 2015. We reviewed MEDLINE, PSYINDEX, PsycINFO, and PsycARTICLES. We selected the following search terms and applied them to the publication abstracts: Traumatic brain injury, TBI, head trauma, post-traumatic, posttraumatic, olfactory dysfunction, olfactory impairment, anosmia, hyposmia, or olfaction disorder. These terms were combined using the Boolean algorithm terms “AND” and “OR” to retrieve pertinent study titles of reports and abstracts: (Traumatic brain injury OR TBI OR head trauma OR posttraumatic OR post-traumatic) AND (olfactory dysfunction OR olfactory impairment OR anosmia OR hyposmia OR olfaction disorder).

Among those terms, we did not include phrases such as “imaging” as we expected that some studies would not mention the use of imaging techniques in their abstracts even though they mentioned such data (which was the case for four studies). The research was done by applying the Preferred Reporting Items for Systematic Reviews and Meta-analyses guidelines for systematic research [Figure 3].

Research criteria

The following filters were used: Abstract available, humans, English language, adults, and academic journals. We only searched the articles published between 1991 and 2015 (with the intention to cover the MRI era).

Example of full electronic search for MEDLINE so that it could be repeated

1. Implementation of the Boolean research term to search among titles and abstracts
2. After the first selection, the following exclusion criteria were applied: English language, 1991 to 2015 (MRI era), adults (19+), abstracts available, and academic journals
3. All hereby selected journals were then screened for our inclusion criteria (see below). If full text was not available, the individual abstract was screened.

After applying the exclusion criteria, we identified 89 studies, which were then fully examined for inclusion in our analysis. Inclusion criteria were: Clinical cohort studies, trials or case reports, trauma assessment, and the use of a specific evidence-based olfaction test, and report on the use of employed imaging techniques.

Moreover, studies having no linked full text needed to reveal enough information in their abstract for fulfilling our criteria. Forty five available full texts and one abstract were screened. In the end ten studies (one of which was an abstract) were selected [Table 1].

For assessing the risk of bias in each individual study, we restricted our review to studies using valid olfactory tests, a trauma assessment, and imaging techniques, with their respective results. To assess the risk of bias across the studies, only studies fulfilling all our inclusion criteria were selected. Therefore, we tried to minimize the risk of using unspecific data, which could not be classified to a satisfying extent, e.g., studies only mentioning that a patient had sustained a TBI but not listing the respective GCS score.

RESULTS

Forty five out of the 66 articles were available as full text via the Harvard University Countway Library access system. For the remaining studies, only abstracts were examined. In the end, ten articles fulfilled our selection criteria, and of those nine were full text articles, which are presented in Table 1. Of the 56 rejected studies, 33 did not fulfill more than one criterion. Forty three out of the 66 studies did not differentiate between the different TBI types. Twenty out of the 66 studies did not report any imaging data. Three out of the 66 studies did not report mTBIs (3 studies) and five studies did not have a trauma assessment at all. A summary of these findings is provided in Table 1.

The trauma perspective

Within the identified ten studies, a total of 350 patients were described as having sustained mTBI. For classification purposes, all three TBI indicators, namely GCS,^[13,16,17,39] PTA,^[13,16,17,39,43] as well as LOC^[12,16,17,39] were used. The studies by Shiga^[38] and Swann^[43] did not give details in their sample description. However, they did so in their results section looking at the effect of trauma severity on olfactory impairment.

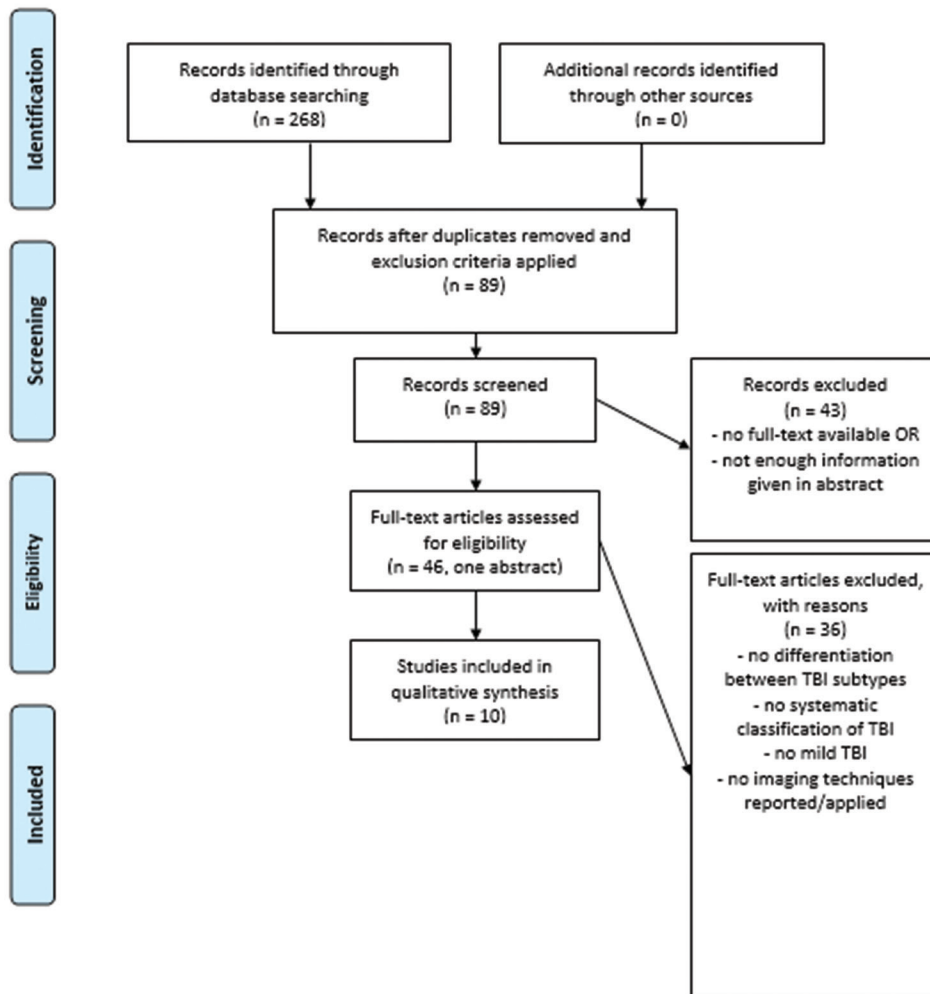
Two studies reported an association between OD and PTA.^[17,43] One publication concluded that, in the setting of no PTA and no CT abnormalities, the patients of the mTBI group did not score significantly lower on the Alberta Smell Test (AST) than individuals belonging to the control group.^[17] Another study reported that patients with a PTA of more than 5 min had a significantly higher chance of subsequent OD than patients who presented with a PTA of less than 5 min (OR: 9.6).^[43] In the latter study, PTA was correlated with the results on the AST.

A neurological point of view in respect to the used olfactory tests

Identified studies were then reviewed in detail, and we found that overall eight different olfactory tests were used. Three studies^[13,14,47] used the UPSIT score, another



PRISMA 2009 Flow Diagram



From: Moher D, Liberati A, Tetzlaff J, Altman DG, The PRISMA Group (2009). Preferred Reporting Items for Systematic Reviews and Meta-Analyses: The PRISMA Statement. *PLoS Med* 6(6): e1000097. doi:10.1371/journal.pmed1000097

For more information, visit www.prisma-statement.org.

Figure 3: PRISMA guidelines for systematic reviews

three the AST,^[23-25] whereas the Odor Memory Test (OMT), Pocket Smell Test (PST), SST, and Brief Smell Identification Test (BSIT) were all used only once. Only one study assessed the ability to smell qualitatively, which was conducted by making the test individuals smell different odors and assessing their quality. All studies except two^[19,43] reported a significant association between trauma severity and olfaction. Bivariate associations were as follows: One paper calculated Pearson correlation coefficient for the association between AST and PTA ($r = -0.23$) and GCS ($r = 0.29$) as well as the CT findings (CT-GCS: $r = -0.56$; CT-PTA: $r = 0.43$; CT-Smell test: $r = 0.31$).^[17] Odds ratio (OR) was

used once for comparing PTA values in patients with OD (9.6 for the group with PTA > 5 min compared to <5 min).^[43] Chi-square test was employed in two studies^[38,43] comparing patients with OD to healthy subjects in regards to the existence of skull fractures^[43] or OB volume^[38] (and reported both to be significant). Only one study found an insignificant difference between OF in mTBI patients and individuals in the control group.^[17]

Radiographic analysis

Eight of the ten identified studies reported the use of MRI for imaging, while six studies additionally used CT scanning and one study employed single-photon

Table 1: Results

Study	Mild-TBIs (n)	Olfactory-tests and scores	Follow-up/test or re-test	Imaging technique and diagnosis	Main messages/findings
Drummond, Douglas and Olver, 2013 ¹³	2/5	UPSIT, PST	Patient 1: 150 days post injury Patient 2: 14 days post-injury	CTB/MRI: One patient presented with bilateral periorbital hematomas, subconjunctival hemorrhages and minor right frontal subgleal hema; The other presented with (R) temporal hematoma, mild midline shift, SAH, SDH, (R) frontal hematoma, p-fossa and subfalcine hematoma	Patient 1: PST: 0/3 right UPSIT: not administered Self-report: total amnesia (0 out of 10) Patient 2: PST: 3/3 UPSIT: 30/40 Self-report: 1-2/10
Fortin, Lefebvre and Ptito 2010 ¹⁴	26	UPSIT, AST	Mean-time since injury: 10.49 months (overall)	MRI: Differentiation between frontal and other and no-lesions Frontal lesions scored significantly lower after controlling for age on the UPSIT and AST ($p < 0.005$)	UPSIT scores of mTBI: M: 24.12, SD: 8.11; Alberta Smell Test scores of mTBI: M: 9.50, SD: 4.93; For all patients, frontal lesions were associated with lower results in both tests Injury severity was no determining factor for the UPSIT and AST scores. After controlling for age, the three TBI groups differed significantly in their UPSIT scores (mTBI: M=24.12, SD=8.11; moderate TBI: M=28.22, SD=6.65; and severe TBI: M=26.79, SD=9.78 TBI; $F[2,45]=0.30$, ns) This was not the case for the AST scores after controlling for age
Green and Iverson 2001 ¹⁶	137 (LOC as criteria)	AST	NR	CT only mentioned for severe group	AST (scores out of ten) total scores: Mean: 9.6 Median: 9.0 SD: 4.9
Green, Rohling, Iverson and Gervais 2003 ¹⁷	112 mTBIs (GCS) 90 patients with no PTA (mean GCS 14,9), 46 with PTA <1 day (Mean GCS: 14.2)	AST	GCS scores were recorded in the first 24 hours after the accident	CT/MRI: 9% of the no PTA group had a lesion on the scan 23% of the PTA <1 day had a lesion on the scan Of the mTBIs, 56 patients had no PTA and 15% abnormal CT/MRI, while 40 patients of the mTBIs had some PTA and an abnormal CT/MRI in 59% of the cases The normal scan mean AST score for no PTA was 6.1 ($n=29$) Abnormal scan mean AST score for no PTA: 5.1 ($n=14$) Abnormal scan mean AST for some PTA: 3.9 ($n=5$) Abnormal scan mean AST for some PTA: 3.4 ($n=20$)	GCS > 13: Mean AST score: 5.6 No-PTA: Mean=5.8 Some PTA: Mean=3.2 AST-PTA: $r = -0.23$ AST-GCS: $r = 0.29$ CT-GCS: $r = -0.56$ CT-PTA: $r = 0.43$ CT-Smell test: $r = 0.31$ Smell test scores were the best predictor for TBI severity (GCS, LOC and PTA) Smell test scores of mTBI group did not differ significantly of the control group. If not PTA and no CT abnormalities, mTBI did not score significantly worse on AST

Contd...

Table 1: Contd...

Study	Mild-TBIs (n)	Olfactory-tests and scores	Follow-up/test or re-test	Imaging technique and diagnosis	Main messages/findings
Shiga <i>et al.</i> 2013 ³⁸	2 concussion 2 cerebral contusion 3 cerebral contusions with hemorrhage	T and T Olfactometry		SPECT/MRI: Olfactory bulb volume in TBI patients: Mean=22.5 SD=7.5 $p < .05$ in comparison to healthy volunteers	201 TI migration to olfactory bulb was significantly lower in TBI patients than in controls ($p \geq 0.05$) The higher the 201 TI migration, the better the T and T Olfactometry score Negative association between TBI severity and OB and OT volume ($p < 0.05$) t-test for Migration of nasal 201 TI migration in patients with head trauma: $P = 0.0005$
Sigurdardottir, Jerstad, Andelic, Roe, Schanke 2010 ³⁹	40	BSIT	At 12 months no significant differences between TBI groups At 3 months significant differences between TBI groups	MRI (1.5): 8 frontal lesions, 21 no lesions, 0 fronto-temporal, 0 diffuse	BSIT score >9 at 3 months: $n = 8$ (20%) BSIT score >9 at 12 months $n = 6$ (15%) No significant differences in the incidence of OD (BSIT >9) among TBI groups
Wise, Moonis and Mirza 2006 ⁴⁷	1 (no loss of consciousness)	UPSIT, OMT	After 18 months no return of OF (still abnormal MRI)	MRI (4 hours after traumatic incident): Multifocal regions of hyper intensity in the bilateral orbital frontal region, compatible with hemorrhages	UPSIT score: 13/40 OMT: right 4/12, left 5/12 After 18 months still hemorrhagic contusions on MRI
Swann <i>et al.</i> 2006 ⁴³	828 total, 134 with OD, no further differentiation in the sample description	Smell of peppermint liquid and oil of cloves		CT: Of 68 patients with skull fractures and OD, 31 had occipital, 9 had multiple, 11 temporal, 12 parietal and 5 frontal fractures	Patients with PTA >5 min have a higher chance of olfactory impairment compared to patients with a PTA <5 min (Odds Ratio: 9.6) Patients with OD had significantly more skull fractures and more occipital fractures than patients with TBI without OD (χ^2 test: $p < 0.02$) 69% of the OD group had frontal lesions Authors suggested PTA as a predictor of olfactory impairment
Haxel, Grant, Mackay-Sim, 2008 ¹⁹	32/190 mTBIs	SST	Traumatic incidents happened 6-32 months prior to the study	MRI: No specific lesions were mentioned in the abstract	Overall, the incidence of OD after head trauma was 12.8%. The authors found a significant correlation between OD and the appearance of skull base fractures and intracranial hemorrhage or hematoma
Doty <i>et al.</i> 1997 ¹²	5 had no LOC and were therefore mild	UPSIT	Re-test intervals ranging from 0.5 to 13 years	MRI: OB and OF volumes were significantly lower in males compared to controls. This was not the case for females. Only in males TBI did significantly alter OB and OT volume	mTBI did not differ significantly from moderate on their UPSIT score, but from severe Negative association of OB volume and head trauma for males: $p < .001$ The UPSIT scores of the different time intervals since injury did not differ significantly For all TBIs, traumas at the occipital or fronto-parietal parts of the head produced larger deficits and UPSIT scores were significantly lower for the patients who experienced a LOC (>24 hours)

UPSIT: University of pennsylvania smell identification test, PST: Pocket smell test, MRI: Magnetic resonance imaging, AST: Alberta smell test, mTBI: Mild traumatic brain injury, CT: Computer tomography, NR: Not reported, GCS: Glasgow coma scale: PTA: Post traumatic amnesia, SPECT: Single photon emission computed tomography, TI, OD: Olfactory dysfunction, OMT: Odor memory test, LOC: Loss of consciousness, SST: Sniffin' sticks test, OB: Olfactory bulb, OT: Olfactory tract, BSIT: Brief smell identification test

emission computed tomography (SPECT) imaging in combination with MRI. Reported abnormalities included hemorrhages,^[11,23,34,35] hematoma,^[23,35] SAH^[23] and SDH,^[23] and contusions.^[11,34] Several studies reported the location of observed abnormalities and described lesions in the frontal,^[8,23,32-34] temporal,^[8,23] occipital,^[8] or parietal^[8] areas or in multiple sites.^[8,10,23,34] Two studies correlated OB volume to trauma severity and compared measures to healthy subjects. In both the studies, the respective authors found a negative association between TBI severity and OB and OT volume ($P < 0.05$; $P < 0.011$ for males with head trauma), which implies that more severe trauma correlated with a smaller structural volume of the associated olfactory pathway, likely reflecting post-traumatic atrophy or involution.^[11,28] Five studies tried to find an association between radiographic lesions (in terms of their extent as well as location) and OD. One study reported an association of OD with frontal lesions ($P < 0.05$ for the association between frontal lesions and UPSIT score),^[33] one demonstrated this for occipital lesions^[8] (Chi-square test for trend; $P < 0.01$), and two studies showed a negative correlation with OB volume (t -test: $P = 0.0005$; $P < 0.001$ for males with head trauma).^[11,28]

Three studies found an association between the observation of post-traumatic radiographic intracranial hemorrhage^[23,35] (with the first only reporting a qualitative association) or skull base fractures^[35] and the history of TBI; although the study by Haxel *et al.* did not report the actual values in their abstract.^[19] Three studies either examined the prevalence of post-traumatic lesions/fractures in mTBI patients^[8,31] or its severity.^[35] The highest prevalence of radiographic lesions was reported for a frontal location (69%). One study found an association between the individuals' objective ability to perceive olfaction (as reflected in the measured UPSIT scores) and the mechanism of injury (distinguishing occipital and temporoparietal blows to the head but not if there was a fracture).^[28] Their observation was in concordance with the study that looked at skull fractures.

Follow up observations

Six studies^[12-14,19,39,47] contained information about the timeperiod between the trauma incident and the olfactory assessment. These intervals ranged from 14 days^[13] to 13 years.^[12] Two studies employed objective testing using the UPSIT or BSIT more than once.^[12,39] The first of the two studies assessed the patient three months post trauma and once more after 12 months. During the three-month assessment, the authors found significant differences in the scores depending on TBI severity, whereas at 12-month assessment no significant differences between TBI groups could be demonstrated. The other study reported retest intervals ranging from six months to 13 years. In the latter study, the UPSIT scores did not differ significantly at different intervals after injury. One case report, similar to

the one presented above, also reported no improvement of OF (UPSIT) 18 months after TBI in the setting of abnormal MRI findings.^[47]

DISCUSSION

Post-traumatic anosmia or olfactory dysfunction is a prevalent but surprisingly under-evaluated^[37] problem in patients with mTBI. It is a disease entity that seems largely out of the focus of many of the healthcare providers, who are initially dealing with the assessment of TBI trauma victims. When encountered in longitudinal follow-up, it often leaves both the healthcare provider and the patient in a void of knowledge about the natural history and prognosis of this condition. However, the impact of this neurological deficit is profound and severely affects the quality of life (QOL) of affected patients.

To get a clear view about the current status of the field, we conducted a review of the pertinent literature, which addresses this issue from three different viewpoints; a trauma perspective, a neurological viewpoint, and a radiographic analysis of the patient population. This review revealed that there are no available prospective studies and that the only established evidence is obtained from retrospective cohort studies, which report rather heterogeneous information concerning anosmia or OD, in general, for mTBI patients. One explanation for the lack of a better scientific understanding and the lack of more concrete evidence for the association between mTBI and OD is the fact that many trauma centers do not assess this problem systematically or with any quantifiable tests and longitudinal follow-up. Furthermore, they do not employ established scales (e.g., LOC, PTA, and GCS) in order to differentiate between the different types of TBI. From a neurosurgical point of view, this creates a problem of validity in predicting outcome and in selecting and recommending any possible rehabilitative interventions because significant differences exist between the different TBI types and their prognosis. Therefore, we want to stress that tools of proper patient classification need to be employed strictly and consistently and also need to be repeated thoroughly during longitudinal follow-up.

The association between trauma and olfactory dysfunction

A possible reason for the lack of differentiation in the trauma aspect of such studies may be the fact that most of the retrieved studies were not published by neurosurgeons but by post-hoc care providers such as otorhinolaryngologists and neuropsychologists. Still, for the few OD studies that did contain information about neurosurgical trauma severity (allowing the identification of mTBI), an association of OD with different radiographic lesion types could be observed. In addition to this, a significant difference in the post-traumatic level of OF correlating to the injury severity could be demonstrated. This showed that, even in patients

with mTBIs, such trauma can lead to structural impairment and radiographically distinct “pathologies” that correlate with OD.

This is in contrast to some conclusions drawn by a review published earlier this year.^[37] The review, which dealt with the association of OD and TBI in general, concluded that for patients with mTBI the olfaction status did not differ significantly between TBI patients and individuals from respective control groups. From our point of view, this finding of a lack of correlation between the two may have a statistical reason. The finding could, for example, be explained by the fact that a certain percentage of healthy individuals (sometimes claimed to be as high as 15%^[29,45]) suffer from hyposmia, which introduced a significant statistical bias when comparing a “healthy” control group to a cohort of partially impaired individuals. The impairment of olfaction can also be due to other external factors such as smoking or certain medical comorbidities.^[45] Finally, age can also be a covariate that needs to be controlled.^[14]

Imaging techniques

Schofield and colleagues note, in their review, that anosmia in mTBI patients is often associated with more severe radiographic pathologies (such as hemorrhages and contusions). They also mentioned that a diagnosis of anosmia may also be suggested by certain behavioral changes. This raises the point that a high index of suspicion needs to be developed by healthcare providers, which could be based on anamnesis and mechanism of injury, and emphasizes how important it is to assess OD in the early stages.^[37] As a consequence, dedicated MRI imaging, which is necessary for assessment in patients who suffer from post-TBI OD, can help in designing trials to study early intervention and recovery of olfaction. This may ultimately help in reducing subsequent impairment and dysfunction. Similar to our observations, Schofield *et al.*^[37] also concluded that the rehabilitative and diagnostic services provided for patients suffering from mTBI are lacking in thoroughness, and hence, many OD patients remain undiagnosed for prolonged times. The current guidelines of neurosurgical trauma treatment make the identification of OD from frontobasal injury somewhat difficult when it comes to patients with mTBI only. First, one causative reason may stem from the fact that recent neurosurgical TBI guidelines (e.g., the guidelines published by the Centers of Disease Control and Prevention and the American College of Emergency Physicians in 2008) no longer require or recommend CT or MRI scans for mTBI patients in otherwise good condition, i.e., without LOC or PTA and without any further symptoms such as headache, nausea, or a GCS of less than 15, when patients are being evaluated by a hospital.^[24] Because of this algorithm and the lack of a standardized assessment of the first cranial nerve, an underlying OD as well as its anatomical correlate is frequently missed.

One could argue that more sensitive^[42] algorithms, such as those based on the Canadian Head CT rule (CHCR) or New Orleans Criteria (NOC), exist and hence there is no need to think about changing the guidelines for mTBI. Still, most guidelines do not recommend MRI over noncontrast CT imaging,^[24] even though the former is superior in detecting olfactory pathway-associated lesions. Moreover, the NOC similar to the CHCR only relate to CT imaging in patients with good performance status in whom olfaction was not assessed. Furthermore, monetary constraints limit the use of expensive imaging technology in most institutions, especially when the potential findings may not immediately translate into significant changes in current TBI management protocols, because the therapeutic benefit associated with such interventions is under investigation at present.

Second, most current trauma guidelines advise against the use of steroids in brain trauma patients, even though the prescription of steroids was one of the few interventions in OD patients, which was shown to have a positive effect on the regeneration of OF. Beyond this, there is evidence in the literature suggesting that olfactory training mechanisms with different odor discrimination tests would probably also help in rehabilitation of patients with OD.

Aspects of rehabilitation

One of the pressing questions that needs to be raised here is whether head injury teams (trauma or neurosurgical) should routinely assess OF in post-TBI patients who report to a clinic, and if so when. It is certainly true that, in cases of moderate or severe TBI, immediate neurosurgical management has other priorities than to assess the patients' OF in the acute setting, especially if the patient is in a very critical state. However, for any patient who presents with mild head trauma, a diagnosis of OD can make a difference in planning further care and coping strategies and can also lead to interventions which might yield recovery of some function via possible rehabilitation. To this end, one should keep in mind that the diagnosis of OD, though belittled by many in the field, has a severe effect on each patient's QOL.

Several studies have shown such profound effect of OD on QOL. For example, due to the inability in identifying and discriminating between odors, anosmic patients suffer significantly higher risks of hazardous events such as those due to gas leaks and fires in general.^[31,36] OD can also create social constraints due to its effect on personal hygiene procedures, and it may also extend as problems for an individuals' social life, in general, as well as having an effect on his or her eating habits.^[8,21] For patients suffering from anosmia, the risk of eating rotten or spoiled food is increased, which can result in a change of eating habits or lead to a decrease in appetite sometimes resulting in a significant unintended loss of

weight.^[8] Finally, some studies showed that anosmia is also associated with psychiatric diseases such as depression and anhedonia^[8,9,27,40] and clearly demonstrated that there is a positive association between olfactory impairment and depressive and/or anxiety symptoms, which can be improved if OF regenerates.^[8,27] One caveat remains that this evidence is methodologically difficult to separate from confounding factors in the case of patients who suffered from TBI because TBI is in itself associated with depression.^[1,2] Therefore, the association between depression and TBI could to some extent be explained by the existence of OD being, statistically speaking, a possible mediator variable.

When looking at the results presented here, we must bear in mind some methodical strains, which need to be explained further; because of the various olfactory tests and TBI classifications used in the available literature, the few available studies dealing with this topic cannot be compared easily. Our review has shown that currently published data are not very strong in establishing a clear and unequivocal association between mTBI and OD. As we have pointed out above, some studies were able to demonstrate such a correlation but one failed to show a significant difference between a group of mTBI patients and the control group.^[17] In Table 1, we present a column designated as “main messages” from these studies. In extracting these messages, we limited ourselves to results that bear relevant information for our review. We may, thus, have not included other relevant messages from the respective studies, and we are aware of the fact that if a different team of researchers were to look at the studies retrieved by us and our selection criteria they may come up with a different set of core messages.

Management of mTBI patients suffering from anosmia

Our results and the theoretical background presented have shown that both an association between mTBI and radiographic images as well as a possible treatment procedure exists. However, the current management guidelines make the line of argument complicated because it is well-known that MRI is superior to CT scanning for many disease entities and this has been corroborated in patients suffering from concussions in general. In this patient population, pathological changes are visible in as many as 25% of the examined cases despite the fact that initial CT was normal.^[30] However, if the healthcare provisions and guidelines remain as they have been currently advocated (i.e. no imaging in mTBI with GCS > 13), we are stuck; if we do not have immediate or early sensitive imaging available, there will not be a treatment algorithm that can be derived from it, which will leave us with a high rate of missed OD in the clinical setting, where the loss of function is not being clinically tested in the setting of acute TBI and no sensitive imaging is obtained which may demonstrate

structural impairments. It is highly necessary to carefully think about the mechanism of injury to increase the level of suspicion for such an associated impairment of OF. It is important to encourage healthcare providers in trauma centers to routinely assess the function of the first cranial nerve similar to the other eleven whenever a patient reports to a clinic with TBI because the existence of OD from mTBI might result in different management. In our study, we identified the lack of such assessment at the time of the primary injury in most settings, which was also the case for the two patients from our institution, as illustrated earlier in case report #1. Only when the patient reported for follow-up to our clinic months later, we were able to establish the diagnosis of anosmia that was missed earlier. This finding was best explained by the mechanism of her high impact head injury, with a skull base fracture, and a deceleration injury resulting in shearing of the fila olfactoria, which at this point (five years later) will most likely not regenerate.

A possible treatment algorithm: Summary of the evidence found

Based on the theoretical background presented above and the results of our review, we would suggest a treatment algorithm [Figure 4] for all patients that report to a hospital after sustaining a TBI, especially if the assessment is not emergent. First, we recommend that, in each initial neurological examination, OF should also be grossly examined (e.g., with the use of the SST which is simple and has a high validity and reliability).^[20] If a patient is found to be impaired in his/her olfactory sense, an MRI is indicated to identify any underlying pathology, which might allow enrolling the respective patient for any trial for potentially helpful further treatment. Apart from clinical testing, MRI in combination with SPECT has high specificity and sensitivity for detecting OD.^[3] If imaging diagnostics show no evidence of neural impairment, we propose that the patient should be tested again and, if positive, be sent to a special clinic for further diagnostics. If the MRI is positive, different questions need to be raised; is a neurosurgical intervention indicated and do the trauma guidelines prohibit the use of steroids? In general, if the MRI imaging shows evidence of an underlying neurological impairment, an olfactory test such as the SST or UPSIT should be used to quantify the OD. Another question needs to be raised if a neurosurgical intervention is indicated. Following the identification of post-traumatic OD, specific treatment should be initiated and may possibly even include steroids such as prednisolone, which is otherwise not routinely considered in TBI but which was shown to have significant effects on OF recovery rates and may minimize any further decline of OD and facilitate regeneration. Because the trauma guidelines do not categorically prohibit the use of steroids, drugs such as 30–60 mg of prednisolone

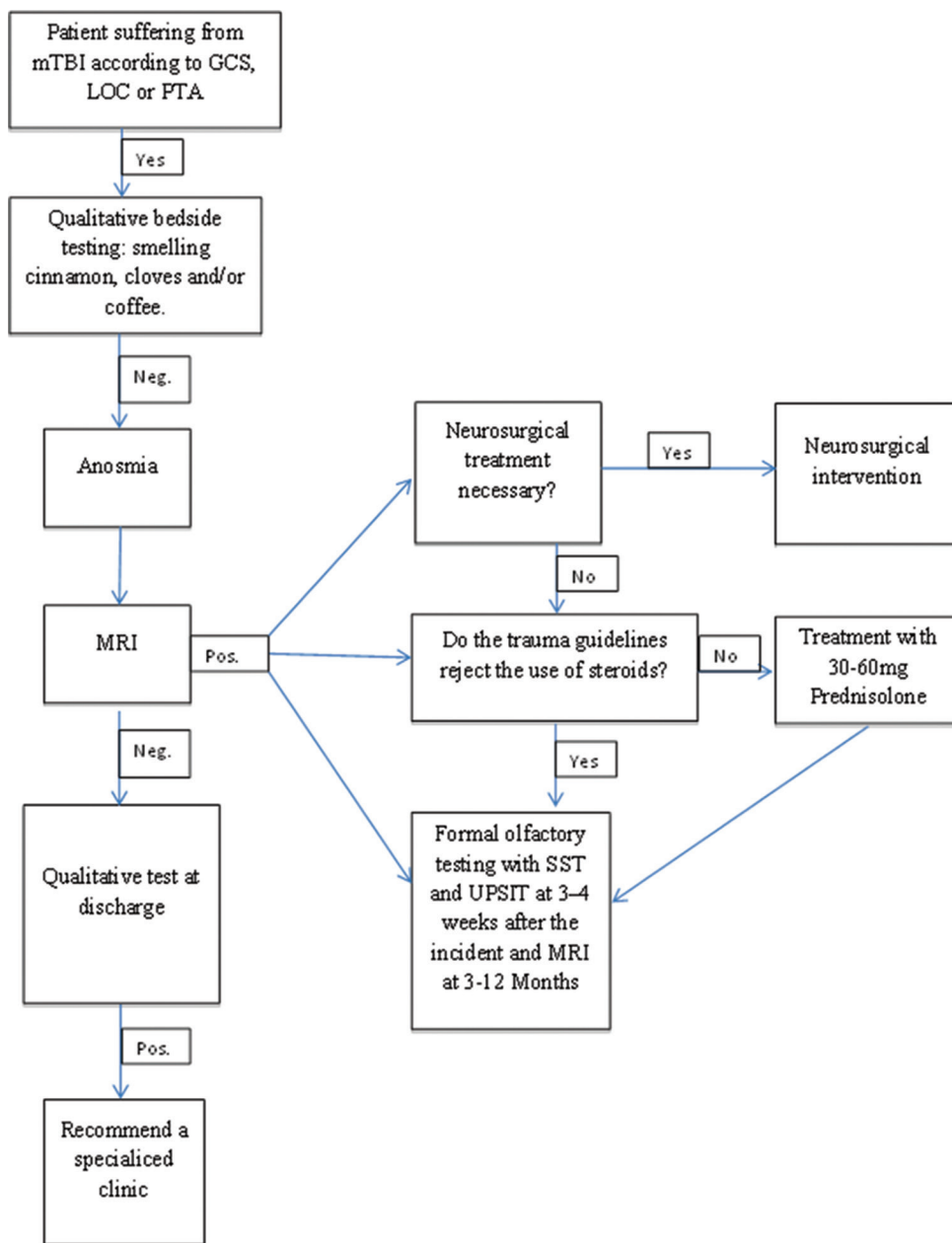


Figure 4: Treatment algorithm for patients who report to a clinic with mTBI. Depending on the diagnosis of a mTBI, in combination with an olfactory dysfunction, we suggest the described scheme that should be followed in order to manage the patient accordingly. Abbreviations: mTBI: mild traumatic brain injury, GCS: Glasgow Coma Scale, LOC: Loss of Consciousness, SST: Scratch and Sniff Test, UPSIT; University of Pennsylvania Smell Identification Test

could be administered in such circumstances. Following treatment, repeat imaging using MRI at three and 12 months could be performed to analyze post-traumatic evolution of affected areas and to study if any of the regions associated with olfaction show some signs of structural regeneration.

Along with this rather simple scheme, the trauma team or neurosurgeon could send the patient to a specialized OD clinic in order to better evaluate such patients with tests such as the SST. Should this result in any recovery of OF following the trauma, the patients' QOL will probably

be improved or sustained. Therefore, for future research, we recommend conducting a prospective study in order to investigate whether patients with post-traumatic OD from mTBI show better functional recovery and better QOL scores than patients who do not receive specific OF-related interventions.

Financial support and sponsorship

Nil.

Conflicts of interest

There are no conflicts of interest.

REFERENCES

1. Alderfer BS, Arciniegas DB, Silver JM. Treatment of depression following traumatic brain injury. *J Head Trauma Rehabil* 2005;20:544-62.
2. Anstey KJ, Butterworth P, Jorm AF, Christensen H, Rodgers B, Windsor TD. A population survey found an association between self-reports of traumatic brain injury and increased psychiatric symptoms. *J Clin Epidemiol* 2004;57:1202-9.
3. Atighechi S, Salari H, Baradaran MH, Jafari R, Karimi G, Mirjali M. A comparative study of brain perfusion single-photon emission computed tomography and magnetic resonance imaging in patients with post-traumatic anosmia. *Am J Rhinol Allergy* 2009;23:409-12.
4. Atighechi S, Zolfaghari A, Baradaranfar M, Dadgarnia M. Estimation of sensitivity and specificity of brain magnetic resonance imaging and single photon emission computed tomography in the diagnosis of olfactory dysfunction after head traumas. *Am J Rhinol Allergy* 2013;27:403-6.
5. Birnbaum M. *Season to Taste*. New York: Harper Collins; 2011.
6. Buschhuter D, Smitka M, Puschmann S, Gerber JC, Witt M, Abolmaali ND, et al. Correlation between olfactory bulb volume and olfactory function. *NeuroImage* 2008;42:498-502.
7. Costanzo RM. Neural regeneration and functional reconnection following olfactory nerve transection in hamster. *Brain Res* 1985;361:258-66.
8. Croy I, Nordin S, Hummel T. Olfactory disorders and quality of life--an updated review. *Chem Senses* 2014;39:185-94.
9. Deems DA, Doty RL, Settle RG, Moore-Gillon V, Shaman P, Mester AF, et al. Smell and taste disorders, a study of 750 patients from the University of Pennsylvania Smell and Taste Center. *Arch Otolaryngol Head Neck Surg* 1991;117:519-28.
10. Doty RL. Office procedures for quantitative assessment of olfactory function. *Am J Rhinol* 2007;21:460-73.
11. Doty RL, Frye RE, Agrawal U. Internal consistency reliability of the fractionated and whole University of Pennsylvania Smell Identification Test. *Percept Psychophys* 1989;45:381-4.
12. Doty RL, Yousem DM, Pham LT, Kreshak AA, Geckle R, Lee WW. Olfactory dysfunction in patients with head trauma. *Arch Neurol* 1997;54:1131-40.
13. Drummond M, Douglas J, Olver J. 'If I haven't got any smell... I'm out of work': Consequences of olfactory impairment following traumatic brain injury. *Brain Inj* 2013;27:332-45.
14. Fortin A, Lefebvre MB, Pito M. Traumatic brain injury and olfactory deficits: The tale of two smell tests! *Brain Inj* 2010;24:27-33.
15. Fujii M, Fukazawa K, Takayasu S, Sakagami M. Olfactory dysfunction in patients with head trauma. *Auris, Nasus, Larynx* 2002;29:35-40.
16. Green P, Iverson GL. Effects of injury severity and cognitive exaggeration on olfactory deficits in head injury compensation claims. *NeuroRehabilitation* 2001;16:237-43.
17. Green P, Rohling ML, Iverson GL, Gervais RO. Relationships between olfactory discrimination and head injury severity. *Brain Inj* 2003;17:479-96.
18. Haehner A, Rodewald A, Gerber JC, Hummel T. Correlation of olfactory function with changes in the volume of the human olfactory bulb. *Arch Otolaryngol Head Neck Surg* 2008;134:621-4.
19. Haxel BR, Grant L, Mackay-Sim A. Olfactory dysfunction after head injury. *J Head Trauma Rehabil* 2008;23:407-13.
20. Hummel T, Kobal G, Gudziol H, Mackay-Sim A. Normative data for the "Sniffin' Sticks" including tests of odor identification, odor discrimination, and olfactory thresholds: An upgrade based on a group of more than 3,000 subjects. *Eur Arch Otorhinolaryngol* 2007;264:237-43.
21. Hummel T, Nordin S. Olfactory disorders and their consequences for quality of life. *Acta Otolaryngol* 2005;125:116-21.
22. Hummel T, Rissom K, Reden J, Hahner A, Weidenbecher M, Hüttenbrink KB. Effects of olfactory training in patients with olfactory loss. *Laryngoscope* 2009;119:496-9.
23. Ikeda K, Sakurada T, Takasaka T, Okitsu T, Yoshida S. Anosmia following head trauma: Preliminary study of steroid treatment. *Tohoku J Exp Med* 1995;177:343-51.
24. Jagoda AS, Bazarian JJ, Bruns JJ, Jr., Cantrill SV, Gean AD, Howard PK, et al. Clinical policy: Neuroimaging and decisionmaking in adult mild traumatic brain injury in the acute setting. *Ann Emerg Med* 2008;52:714-48.
25. Jiang RS, Chai JW, Chen WH, Fuh WB, Chiang CM, Chen CC. Olfactory bulb volume in Taiwanese patients with posttraumatic anosmia. *Am J Rhinol Allergy* 2009;23:582-4.
26. Jiang RS, Wu SH, Liang KL, Shiao JY, Hsin CH, Su MC. Steroid treatment of posttraumatic anosmia. *Eur Arch Otorhinolaryngology* 2010;267:1563-7.
27. Katotomichelakis M, Simopoulos E, Tripsianis G, Prokopakis E, Danielides G, Velegarakis SG, et al. Improvement of olfactory function for quality of life recovery. *Laryngoscope* 2013;123:E10-6.
28. Kern RC, Quinn B, Rosseau G, Farbman AI. Post-traumatic olfactory dysfunction. *Laryngoscope* 2000;110:21-9.
29. Konstantinidis I, Tsakiropoulou E, Bekiaridou P, Kazantzidou C, Constantinidis J. Use of olfactory training in post-traumatic and postinfectious olfactory dysfunction. *Laryngoscope* 2013;123:E85-90.
30. Levin HS, Williams DH, Eisenberg HM, High WM Jr, Guinto FC Jr. Serial MRI and neurobehavioural findings after mild to moderate closed head injury. *J Neurol Neurosurg Psychiatry* 1992;55:255-62.
31. Mueller CA, Hummel T. Recovery of olfactory function after nine years of post-traumatic anosmia: A case report. *J Med Case Rep* 2009;3:9283.
32. Nguyen AD, Pelavin PE, Shenton ME, Chilakamarri P, McCarley RW, Nestor PG, et al. Olfactory sulcal depth and olfactory bulb volume in patients with schizophrenia: An MRI study. *Brain Imaging Behav* 2011;5:252-61.
33. Rombaux P, Bertrand B, Keller T, Mouraux A. Clinical significance of olfactory event-related potentials related to orthonasal and retronasal olfactory testing. *Laryngoscope* 2007;117:1096-101.
34. Rombaux P, Duprez T, Hummel T. Olfactory bulb volume in the clinical assessment of olfactory dysfunction. *Rhinology* 2009;47:3-9.
35. Royet JP, Croisile B, Williamson-Vasta R, Hibert O, Serclerlat D, Guerin J. Rating of different olfactory judgements in Alzheimer's disease. *Chem senses* 2001;26:409-17.
36. Santos DV, Reiter ER, DiNardo LJ, Costanzo RM. Hazardous events associated with impaired olfactory function. *Arch Otolaryngol Head Neck Surg* 2004;130:317-9.
37. Schofield PW, Moore TM, Gardner A. Traumatic brain injury and olfaction: A systematic review. *Front Neurolo* 2014;5:5.
38. Shiga H, Taki J, Washiyama K, Yamamoto J, Kinase S, Okuda K, et al. Assessment of olfactory nerve by SPECT-MRI image with nasal thallium-201 administration in patients with olfactory impairments in comparison to healthy volunteers. *Plos One* 2013;8:e57671.
39. Sigurdardottir S, Jerstad T, Andelic N, Roe C, Schanke AK. Olfactory dysfunction, gambling task performance and intracranial lesions after traumatic brain injury. *Neuropsychology* 2010;24:504-13.
40. Simopoulos E, Katotomichelakis M, Gouveris H, Tripsianis G, Livaditis M, Danielides V. Olfaction-associated quality of life in chronic rhinosinusitis: Adaptation and validation of an olfaction-specific questionnaire. *Laryngoscope* 2012;122:1450-4.
41. Staff MLW. Pedestrian struck by car loses sense of smell, taste. *Massachusetts Lawyers Weekly*. 2015 March 26, 2015.
42. Stiell IG, Clement CM, Rowe BH, Schull MJ, Brison R, Cass D, et al. Comparison of the Canadian CT Head Rule and the New Orleans Criteria in patients with minor head injury. *JAMA* 2005;294:1511-8.
43. Swann JJ, Bauza-Rodriguez B, Currans R, Riley J, Shukla V. The significance of post-traumatic amnesia as a risk factor in the development of olfactory dysfunction following head injury. *Emerg Med J* 2006;23:618-21.
44. Turetsky BI, Moberg PJ, Yousem DM, Doty RL, Arnold SE, Gur RE. Reduced olfactory bulb volume in patients with schizophrenia. *Am J Psychiatry* 2000;157:828-30.
45. Vennemann MM, Hummel T, Berger K. The association between smoking and smell and taste impairment in the general population. *J Neurol* 2008;255:1121-6.
46. Wang L, Chen L, Jacob T. Evidence for peripheral plasticity in human odour response. *J Physiol* 2004;554(Pt 1):236-44.
47. Wise JB, Moonis G, Mirza N. Magnetic resonance imaging findings in the evaluation of traumatic anosmia. *Ann Otol Rhinol Laryngol* 2006;115:124-7.
48. Yee KK, Costanzo RM. Restoration of olfactory mediated behavior after olfactory bulb deafferentation. *Physiol Behav* 1995;58:959-68.
49. Yousem DM, Geckle RJ, Bilker WB, Kroger H, Doty RL. Posttraumatic smell loss: Relationship of psychophysical tests and volumes of the olfactory bulbs and tracts and the temporal lobes. *Acad Radiol* 1999;6:264-72.
50. Yousem DM, Geckle RJ, Bilker WB, McKeown DA, Doty RL. Posttraumatic olfactory dysfunction: MR and clinical evaluation. *AJNR Am J Neuroradiol* 1996;17:1171-9.