



## Original Article

# Radiological analysis on femoral tunnel positioning between isometric and anatomical reconstructions of the anterior cruciate ligament<sup>☆,☆☆</sup>

Rodrigo Barreiros Vieira<sup>\*</sup>, Leonardo Augusto de Pinho Tavares,  
Rodrigo Campos Pace Lasmar, Fernando Amaral da Cunha,  
Lucas Araujo de Melo Lisboa

Orthopedics and Traumatology Service, Faculdade de Ciências Médicas de Minas Gerais, Hospital Universitário São José, Belo Horizonte, MG, Brazil

### ARTICLE INFO

#### Article history:

Received 24 February 2012

Accepted 8 February 2013

Available online 25 March 2014

#### Keywords:

Knee

Anterior cruciate ligament

Reconstructive surgical procedures

### ABSTRACT

**Objective:** the aim of this study was to radiologically evaluate the femoral tunnel position in anterior cruciate ligament (ACL) reconstructions using the isometric and anatomical techniques.

**Methods:** a prospective analytical study was conducted on patients undergoing ACL reconstruction by means of the isometric and anatomical techniques, using grafts from the knee flexor tendons or patellar tendon. Twenty-eight patients were recruited during the immediate postoperative period, at the knee surgery outpatient clinic of FCMMG-HUSJ. Radiographs of the operated knee were produced in anteroposterior (AP) view with the patient standing on both feet and in lateral view with 30° of flexion. The lines were traced out and the distances and angles were measured on the lateral radiograph to evaluate the sagittal plane. The distance from the center of the screw to the posterior cortical bone of the lateral condyle was measured and divided by the Blumensaat line. In relation to the height of the screw, the distance from the center of the screw to the joint surface of the lateral condyle of the knee was measured. On the AP radiograph, evaluating the coronal plane, the angle between the anatomical axis of the femur and a line traced at the center of the screw was measured.

**Results:** with regard to the *p* measurement (posteriorization of the interference screw), the tests showed that the *p*-value (0.4213) was greater than the significance level used (0.05); the null hypothesis was not rejected and it could be stated that there was no statistically significant difference between the anatomical and isometric techniques. With regard to the *H* measurement (height of the screw in relation to the lower cortical bone of the knee), the *p*-value observed (0.0006) was less than the significance level used (0.05); the null hypothesis was rejected and it could be stated that there was a statistically significant difference between the anatomical and isometric techniques. It can be concluded that the

<sup>☆</sup> Please cite this article as: Vieira RB, de Pinho Tavares LA, Pace Lasmar RC, da Cunha FA, de Melo Lisboa LA. Análise radiológica do posicionamento do túnel femoral com as técnicas de reconstrução isométrica ou de reconstrução anatômica do LCA. Rev Bras Ortop. 2014;49:160-166.

<sup>☆☆</sup> Work performed at the Faculdade de Ciências Médicas de Minas Gerais, Hospital Universitário São José (FCMMG-HUSJ), Belo Horizonte, MG, Brazil.

<sup>\*</sup> Corresponding author.

E-mail: [rbarreirosvieira@hotmail.com](mailto:rbarreirosvieira@hotmail.com) (R.B. Vieira).  
2255-4971 © 2014 Sociedade Brasileira de Ortopedia e Traumatologia. Published by Elsevier Editora Ltda.  
Este é um artigo Open Access sob a licença de [CC BY-NC-ND http://dx.doi.org/10.1016/j.rboe.2014.03.007](http://dx.doi.org/10.1016/j.rboe.2014.03.007)

latter difference occurred because the isometric technique generated greater values for the H measurement than the anatomical technique. With regard to the MED variable (position of the screw on the AP radiograph), the observed *p*-value (0.000) was less than the significance level (5%); the null hypothesis was rejected and it could be stated with 95% confidence that there was a significant difference between the anatomical and isometric techniques.

**Conclusions:** there were statistically significant differences in the radiological evaluations of the femoral tunnel, both in the sagittal and in the coronal plane, between the ACL reconstruction techniques.

© 2014 Sociedade Brasileira de Ortopedia e Traumatologia. Published by Elsevier Editora Ltda. Este é um artigo Open Access sob a licença de [CC BY-NC-ND](#)

## **Análise radiológica do posicionamento do túnel femoral com as técnicas de reconstrução isométrica ou de reconstrução anatômica do LCA**

### R E S U M O

*Palavras-chave:*

Joelho

Ligamento cruzado anterior

Procedimentos cirúrgicos  
reconstrutivos

**Objetivo:** avaliar radiologicamente a posição do túnel femoral na reconstrução do ligamento cruzado anterior pelas técnicas isométrica e anatômica.

**Métodos:** foi feito estudo analítico prospectivo em pacientes submetidos à reconstrução do ligamento cruzado anterior (LCA), por meio da técnica isométrica e anatômica, com o uso de enxerto de tendões flexores do joelho ou de tendão patelar. Foram captados 28 pacientes, em pós-operatório imediato, no ambulatório de cirurgia do joelho da FCMMG-HUSJ. Foram feitas radiografias do joelho operado nas incidências em anteroposterior (AP) com apoio bipodálico e perfil em 30° de flexão. Foram traçadas as linhas e medidos os ângulos e as distâncias na radiografia em perfil para avaliar o plano sagital. Foi medida a distância do centro do parafuso à cortical posterior do côndilo lateral e dividido pela linha de Blumensaat. Com relação à altura do parafuso, foi medida a distância do centro dele até a superfície articular do côndilo lateral do joelho. Na radiografia em AP, que avalia o plano coronal, mede-se a angulação entre o eixo anatômico do fêmur e uma linha traçada no centro do parafuso.

**Resultados:** pelos testes, o *p*-valor (0,4213) é maior do que o nível de significância adotado (0,05), a hipótese nula não é rejeitada e pode ser afirmado que não há diferença estatisticamente significativa entre as técnicas anatômica (TAN) e isométrica (TIS) no que diz respeito à Medida P (posteriorização do parafuso de interferência). Como o *p*-valor (0,0006) observado é menor do que o nível de significância adotado (0,05), rejeita-se a hipótese nula e pode ser afirmado que há diferença estatisticamente significativa entre a TAN e a TIS no que diz respeito à Medida H (altura do parafuso em relação à cortical inferior do joelho). Pode-se concluir que essa diferença ocorre porque a TIS gera valores maiores para a Medida H do que a TAN. Como o *p*-valor observado (0,000) é menor do que o nível de significância (5%), rejeitou-se a hipótese nula e afirmamos com 95% de confiança que há diferença significativa entre a TAN e a TIS no que diz respeito à variável MED (posição do parafuso na radiografia em AP).

**Conclusões:** houve diferença estatisticamente significativa na avaliação radiológica do túnel femoral, tanto no plano sagital como no coronal, entre as técnicas de reconstrução do LCA.

© 2014 Sociedade Brasileira de Ortopedia e Traumatologia. Publicado por Elsevier Editora Ltda. Este é um artigo Open Access sob a licença de [CC BY-NC-ND](#)

## **Introduction**

Reconstruction of the anterior cruciate ligament (ACL) is one of the most frequently performed orthopedic surgical procedures and it particularly affects young adults. It has been estimated that between 75,000 and 100,000 such procedures are carried out in the United States every year.<sup>1</sup> Reestablishment of knee biomechanics is the main objective of the treatment, in order to avoid early degenerative alterations, with consequent reduction in work capacity and sports performance.

Over recent decades, the arthroscopic procedure of intra-articular ACL reconstruction has been considered to be the

gold standard treatment because of its low morbidity, with better and faster postoperative evolution.

In the 1990s, it was believed that the isometric arthroscopic reconstruction technique for the ACL, in which the neoligament maintains its length throughout the range of motion of the knee, would more adequately restore the biomechanics of this joint. This was achieved by constructing the femoral tunnel at an orientation of close to 12 o'clock, which would make the graft vertical. Although this concept was partially true, with restoration of translational stability, a recent study revealed a failure to reach rotational stability, with maintenance of the pivot shift.<sup>2</sup> Consequently, the joint biomechanics was seen not to have been restored, which would generate early signs of osteoarthritis.

In 2003, Yasuda et al.<sup>3</sup> were the first of several authors to study anatomical ACL reconstruction in greater depth, with construction of a femoral tunnel, or tunnels in the case of a double band, at the point where these bands originate, in the medial wall of the lateral femoral condyle. Some more recent studies have shown that, with this procedure, both translational and rotational stability are achieved, thus reproducing the biomechanical characteristics of the knee faithfully.<sup>4-6</sup>

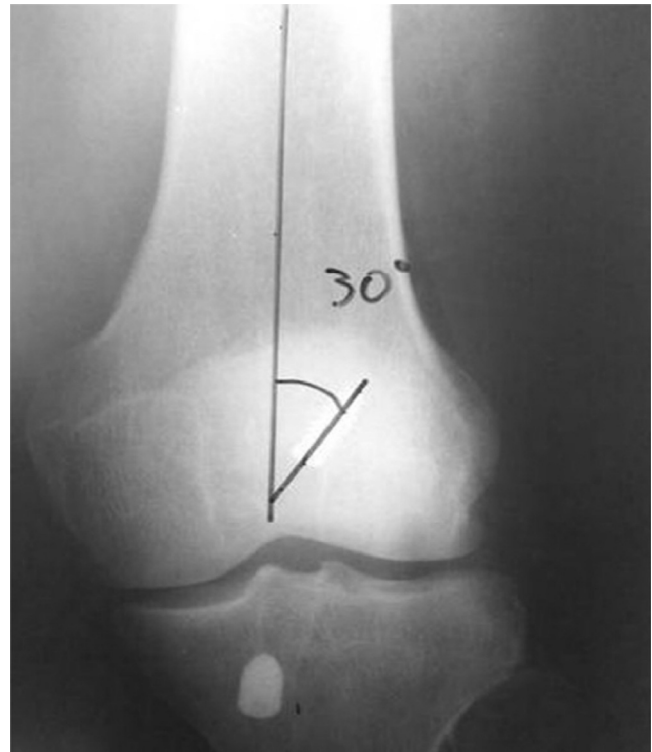With regard to evaluating the positioning of the femoral tunnel after the operation, there are some studies in the literature showing that this objective can be established through radiological studies.<sup>7-9</sup>

The aim of this study was to radiologically evaluate the position of the femoral tunnel using the isometric and anatomical reconstruction techniques.

## Materials and methods

A prospective analytical study was conducted on 28 patients who underwent ACL reconstruction using grafts from the flexor tendons of the knee or from the patellar tendon. All the procedures were performed by the same author (RBV). Fourteen patients underwent isometric reconstruction and the other 14 patients underwent anatomical reconstruction; patients were allocated randomly. All of the patients were evaluated, before and after the operation, at the knee surgery outpatient clinic of São José University Hospital, School of Medical Sciences of Minas Gerais (HUSJ-FCMMG), and they underwent the surgical procedure in the same hospital. The patients included in this study presented a condition of anterior knee instability that had been diagnosed both clinically and by means of magnetic resonance examination, a closed growth plate in the proximal tibia and distal femur, and an age of less than 50 years. All the patients were referred through the Brazilian National Health System (SUS). We excluded patients who required corrective osteotomy during the reconstructive procedure, those with advanced osteoarthritis and those with injuries to peripheral ligament structures of the knee. In this sample, 27 were men and one was a woman, and the mean age was 32.5 years (range: 16-48). There were 16 patients (57.14%) with injuries to the left knee and 12 (42.86%) to the right knee. All the patients underwent radiological examinations within the first postoperative month.

With follow-up from one of the authors, the patients were referred for imaging examinations in the radiology sector of HUSJ-FCMMG. Radiographs were performed in anteroposterior (AP) view on the operated knee, with weight-bearing on both feet, and in lateral view at flexion of 30°. These examinations were duly identified with the patient's name, the date of the surgery and the technique used (isometric or anatomical). We traced out the lines and measured the distances and angles in the following manner: on the lateral radiograph, the distances from the center of the screw to the posterior cortical bone of the lateral condyle and from the center of the screw to the anterior cortical bone were measured (Fig. 1). In relation to the height of the screw, the distance from the center of the screw to the joint surface of the lateral condyle of the knee was measured (Fig. 1). On the AP radiograph, the angle



**Fig. 1 – The posteriorization of the interference screw (measurement P) was measured by dividing the distance between points 1 and 2 (posterior cortical bone to the center of the screw) by the distance between 1 and 3 (center of the screw to the anterior cortical bone). The height of the screw in relation to the lower cortical bone of the knee (measurement H) was also measured, by means of the distance between 2 and 5.**

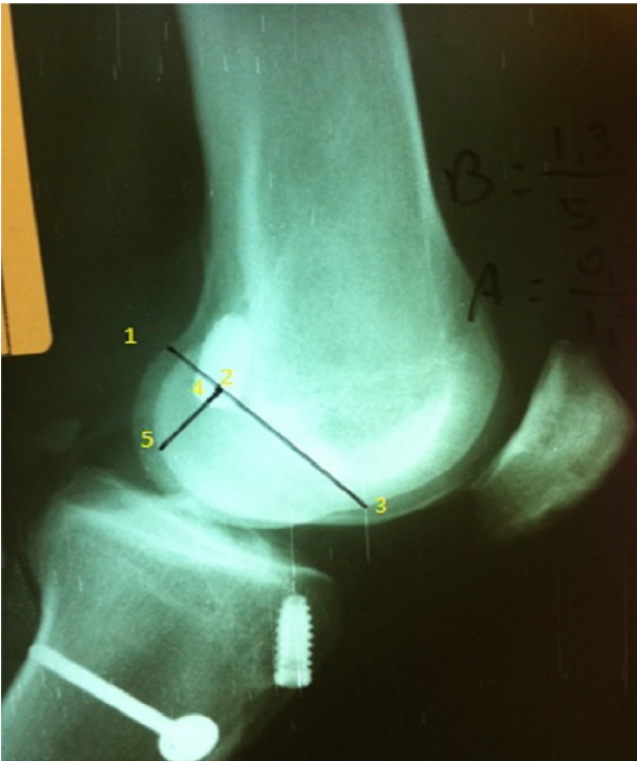
between the anatomical axis of the femur and a line traced through the center of the screw was measured (Fig. 2).

## Results

Table 1 presents a descriptive analysis on the measurements P and H from the lateral view, stratified according to the technique used: anatomical technique (ANT) or isometric technique (IST). It could be seen that, on average, the values

**Table 1 – Descriptive statistics for the measurements P and H according to the technique used.**

Technique	Measurement P		Measurement H	
	ANT	IST	ANT	IST
Count	14	14	14	14
Mean	0.4556	0.4352	0.2023	0.3119
Standard deviation	0.1236	0.0835	0.1224	0.0583
Minimum	0.2370	0.3320	0.0570	0.2270
First quartile	0.3662	0.3858	0.1430	0.2615
Median	0.4525	0.4045	0.1855	0.3065
Third quartile	0.5435	0.4688	0.2122	0.3668
Maximum	0.6820	0.6570	0.5650	0.3960



**Fig. 2 – The angle between the anatomical axis of the femur and the center of the screw was measured in anteroposterior (AP) view. The angle MED was defined.**

found for measurement P using ANT were slightly larger than those found using IST. The same was found with the standard deviations and medians.

In the case of measurement H, it could be seen that the values found through using IST were on average greater than those using ANT and also presented lower variability, since the standard deviation was smaller.

Fig. 3 shows a histogram of the distribution of measurement P for ANT and IST. For ANT, there was a very irregular distribution, and for IST, the distribution was asymmetrical to the right.

Fig. 4 shows a histogram of the distribution of measurement H for ANT and IST. It can be seen that the values for

ANT had asymmetrical distribution to the right, while for IST, the distribution was approximately uniform.

From the boxplot presented in Fig. 5, it can be seen that the distribution of measurement P was concentrated on close values both for ANT and for IST. As was seen in the initial descriptive analysis, the boxplot made it possible to see that there was less variability in IST than in ANT, since the “box” was smaller.

Regarding measurement H, the distribution of the values for ANT was concentrated on smaller values than those of IST. This indicates that there may be a significant difference between these two techniques in relation to measurement H. To check this hypothesis, an appropriate statistical test was performed.

Fig. 6 presents a plot of the individual values of each measurement, to compare ANT and IST. This graph led to conclusions similar to those from the preceding graph.

Since a small sample was used to compare measurements P and H in relation to the technique used and, moreover, it was seen through a statistical test that the assumption of normal distribution of the data was violated, the most appropriate statistical test for evaluating the hypothesis of interest was the nonparametric Mann-Whitney test.

The hypotheses to be tested were as follows:

Test 1: measurement P.

$H_0$ : ANT and IST present the same distribution.

$H_a$ : ANT and IST present different distributions.

Test 2: measurement H.

$H_0$ : ANT and IST present the same distribution.

$H_a$ : ANT and IST present different distributions.

The significance level used was  $\alpha = 0.05$ .

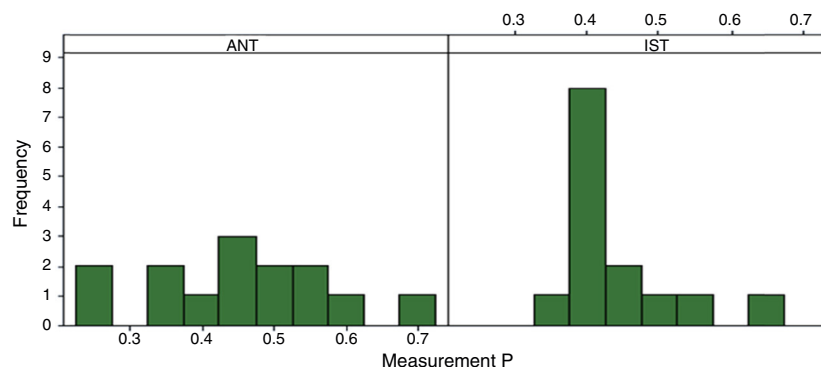
Test 1: measurement P.

Estimated difference: median (ANT) – median (IST) = 0.0355.

Confidence interval for this difference: (-0.0520; 0.1050).

$p$ -Value = 0.4213.

Therefore, since the  $p$ -value (0.4213) was greater than the significance level used (0.05), the null hypothesis was not rejected and it could be stated that there was no statistically significant difference between ANT and IST with regard to measurement P.



**Fig. 3 – Histogram of the measurement P, stratified according to technique.**

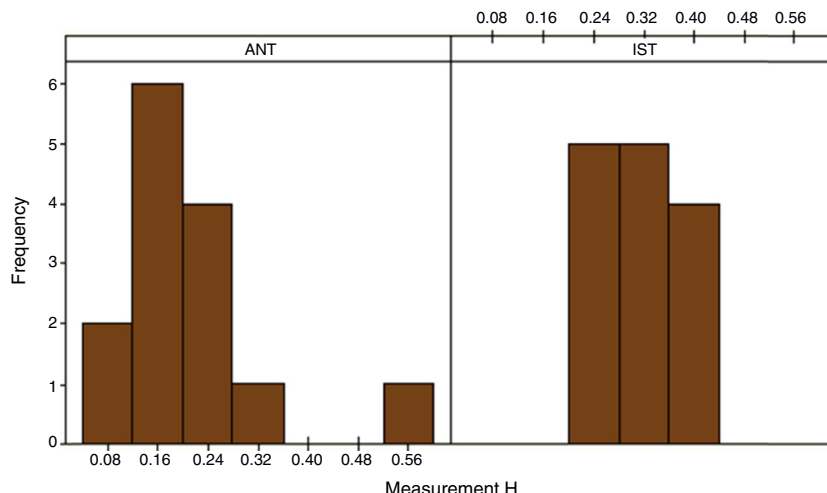


Fig. 4 – Histogram of the measurement H, stratified according to technique.

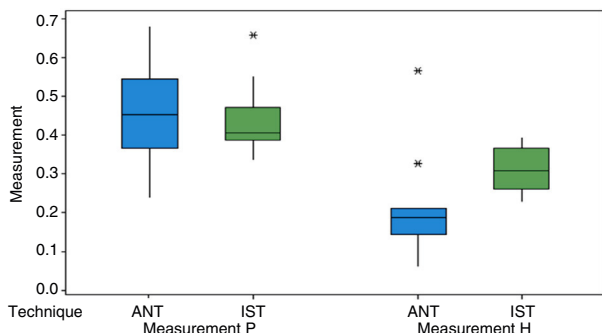


Fig. 5 – Boxplot of the measurements P and H according to the surgical technique used.

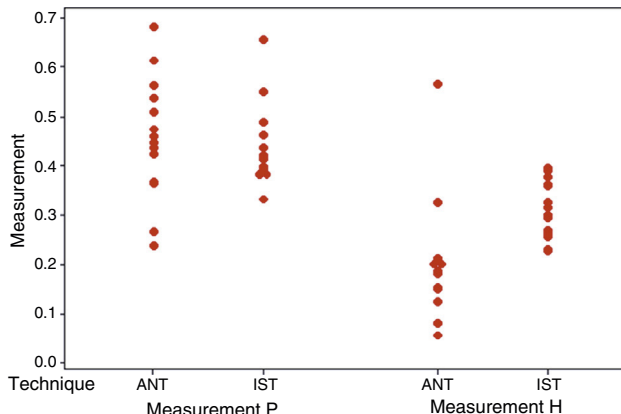


Fig. 6 – Individual values for the measurements P and H, according to the technique

Test 2: measurement H.

Estimated difference: median (ANT) – median (IST) = -0.1275.  
 Confidence interval for this difference: (-0.1820; -0.0710).  
 p-Valor = 0.0006.

Since the *p*-value (0.0006) was smaller than the significance level used (0.05), the null hypothesis was rejected and it could be stated that there was a statistically significant difference between ANT and IST with regard to measurement H. It could be concluded that this difference occurred because IST generated larger values for measurement H than ANT did.

According to Table 2, the patients on whom IST was used presented greater mean values for the variable MED, in AP view, and smaller variability.

It can be seen from Fig. 7 that the measurements observed for the variable MED were apparently greater for the patients on whom IST was applied. However, a hypothesis test was needed in order to ascertain whether this difference was statistically significant.

Fig. 8 shows that the patients on whom ANT was used had lower values for the variable MED and greater variability than the patients on whom IST was used. Again, this proved the need for a hypothesis test in order to ascertain whether this difference was statistically significant.

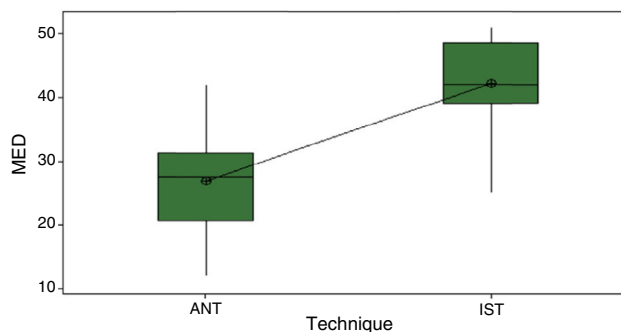
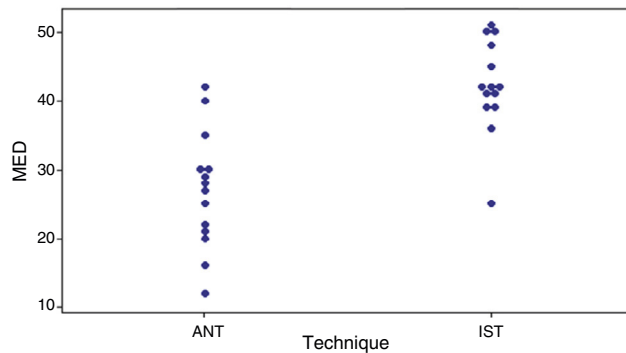


Fig. 7 – Boxplot for the variable MED.

To test this hypothesis, we used the *t* test, given that the sample had fewer than 30 observations. This test assumed that the distribution of the variable MED was normal. We used the Minitab software to do the calculations, with the significance level of 5%. Since the *p*-value observed (0.000) was smaller than our significance level (5%), the null hypothesis was rejected and it could be stated with 95% confidence that

**Table 2 – Descriptive statistics for the variable MED.**

Variable	Technique	N	Mean	Standard deviation	Minimum	Q1	Median	Q3	Maximum
MED	ANT	14	26.93	8.51	12.00	20.75	27.50	31.25	42.00
	IST	14	42.21	6.78	25.00	39.00	42.00	48.50	51.00

**Fig. 8 – Individual values for MED.**

there was a significant difference between ANT and IST with regard to the variable MED.

It could also be stated, with 95% confidence, that the patients on whom IST was applied presented results for MED that on average were 16.74 times [CI (21.93; 11.55)] greater than among those with ANT.

## Discussion

The importance of correct positioning of both the tibial and the femoral tunnel in ACL reconstruction cannot be underestimated. Poor positioning of the tunnels is a very common mistake in ACL reconstruction, and the possible problems include diminished range of motion of the knee, graft failure, impacting of the graft on the intercondylar roof and continuation of feelings of instability, which generate revision surgical procedures that often present major complexity. Since the center of rotation of the knee is closer to the femoral insertion than to the tibial insertion, greater accuracy of tunnel placement in the femur, in ACL reconstruction, is more critical than tibial tunnel positioning.<sup>10</sup> For this reason, our study only addressed analysis of this tunnel.

In most orthopedic surgical procedures involving the bone structure, radiological parameters that have already been well defined guide critical analysis on their correctness and the possible technical mistakes that could affect the final result. This is not the case with regard to ACL reconstruction; although some studies in the worldwide literature have shown different methods for radiologically positioning of the femoral tunnel,<sup>9-12</sup> none of them has been shown to be effective or has become widely disseminated.

Over a five-year follow-up on 89 patients who underwent ACL reconstruction using video-assisted arthroscopy, Aglietti et al.<sup>13</sup> demonstrated that 88% of the knees with correct positioning of the femoral tunnel presented satisfactory stability. However, anterior positioning of the femoral tunnel was associated with a failure rate of 62.5%. Khalfayan et al.<sup>14</sup> showed

that 79% of the cases with positioning of the femoral tunnel entrance within the posterior 40% portion of the lateral condyle of the femur presented good results using the KT-1000 arthrometer (up to 3 mm of anteriorization). In our study, the IST came closer to the results of the previous author, with a mean of 0.4352 or 43% posterior to the measurement, versus 0.4556 or 45%, and thus was slightly more anteriorized. This is the reason why, with the single-band ANT, the femoral tunnel was constructed at the bifurcated crest, between the insertions of the fibers of the anteromedial and posterolateral bands of the ACL, i.e. a little more anteriorized than what was used in all the other articles analyzed, which used the anteromedial band as the point at which the tunnel should be made in the femur.

In our study, it was shown that in two regards of the positioning (height and angle in the frontal plane), the transtibial access produced results that were significantly different from those obtained using a medial portal. This diverges from the study by Giron et al., in which they stated that they reached the "ideal" point on the femur both through an out-in or transtibial access and through an anteromedial approach.<sup>15</sup>

Recently, Shah et al.<sup>16</sup> conducted a radiographic evaluation on 43 patients who underwent anatomical ACL reconstruction using the anteromedial portal technique and they found that the interference screw was located on the femur at approximately 31% of the sagittal diameter in relation to the posterior cortical bone and at 25% of the height of the lateral femoral condyle.

In a radiographic analysis on bone tunnel positioning in ACL reconstruction that compared the open technique with arthroscopy via an anteromedial portal, Dambrós et al.<sup>8</sup> found a difference between the two techniques regarding the positioning of the femoral tunnel. The arthroscopic route showed greater precision in tunnel positioning, and this difference was shown to be statistically significant. We also observed a difference in our study in relation to femoral tunnel positioning, but we only used arthroscopic techniques.

Bernard et al.<sup>17</sup> demonstrated that the positioning of the interference screw in the condyle was at 28.5% of the height of the lateral femoral condyle, using the quadrant method described in their original study, which used the anteromedial portal technique.

In our result, in measuring the height of the lateral femoral condyle in relation to the Blumensaat line, the mean value for IST was 20.2% and for ANT was 31.1%. Functional evaluations with long-term follow-up are needed in order to make comparisons regarding the best surgical technique, since conclusions cannot be reached using radiographic evaluation of tunnel position.

In relation to the frontal plane, our calculations showed that the mean difference between the tunnel angles was 16.74°. The angle in the anatomical reconstruction was smaller because the direction was more horizontalized. Through this, we reached a value close to what was presented

by Aglietti et al.,<sup>18</sup> who in 1995 published a paper showing a difference of 18° between the tunnels.

Further imaging studies correlated with functional studies are still awaited, in order to affirm which radiographic parameters are correct for femoral tunnel positioning.

Certain limitations of the present study need to be highlighted. The radiographs that were analyzed in relation to our patients were produced using different radiology techniques, with follow-up by one of the authors. Consequently, they were not performed in a blinded manner, which might have led to bias. The real positioning of the graft inside the bone tunnel could not be completely viewed on the radiographic imaging; only the positioning of the screw could be seen. Lastly, the sample size was small.

## Conclusion

The positioning of the femoral tunnel on radiological examination presented results that were very similar in relation to posteriorization on the femoral condyle, independent of the technique used. However, there were significant differences in height and angle in relation to the femoral axis.

## Conflicts of interest

The authors declare no conflicts of interest.

## REFERENCES

- Griffin LY, Agel J, Albohm MJ, Arendt EA, Dick RW, Garrett WE, et al. Non-contact anterior cruciate ligament injuries: risk factors and prevention strategies. *J Am Acad Orthop Surg.* 2000;8(3):141-50.
- Jonsson H, Riklund-Ahlström K, Lind J. Positive pivot shift after ACL reconstruction predicts later osteoarthritis: 63 patients followed 5-9 years after surgery. *Acta Orthop Scand.* 2004;75(5):594-9.
- Yasuda K, Kondo E, Ichiyama H, Kitamura N, Tanabe Y, Tohyama H, Minami A. Anatomic reconstruction of the anteromedial and posterolateral bundles of the anterior cruciate ligament using hamstring tendon grafts. *Arthroscopy.* 2004;20(10):1015-25.
- Yagi M, Wong EK, Kanamori A, Debski RE, Fu FH, Woo SL. Biomechanical analysis of an anatomic anterior cruciate ligament reconstruction. *Am J Sports Med.* 2002;30(5):660-6.
- Gabriel MT, Wong EK, Woo SL, Yagi M, Debski RE. Distribution of in situ forces in the anterior cruciate ligament in response to rotatory loads. *J Orthop Res.* 2004;22(1):85-9.
- Van Eck CF, Lesniak BP, Schreiber VM, Fu FH. Anatomic single- and double-bundle anterior cruciate ligament reconstruction flowchart. *Arthroscopy.* 2010;26(2):258-68.
- Kondo E, Yasuda K, Ichiyama H, Azuma C, Tohyama H. Radiologic evaluation of femoral and tibial tunnels created with the transtibial tunnel technique for anatomic double-bundle anterior cruciate ligament reconstruction. *Arthroscopy.* 2007;23(8):869-76.
- Dambrós JM, Florêncio R, Lopes Júnior OV, Kuhn A, Saggin J, Spinelli LF. Análise radiológica do posicionamento dos túneis ósseos na cirurgia de reconstrução do ligamento cruzado anterior: comparação entre as técnicas aberta e artroscópica via portal anteromedial. *Rev Bras Ortop.* 2001;46(3):270-5.
- Aglietti P, Zaccherotti G, Menchetti PP, De Biase P. A comparison of clinical and radiological parameters with two arthroscopic techniques for anterior cruciate ligament reconstruction. *Knee Surg Sports Traumatol Arthrosc.* 1995;3(1):2-8.
- Guo L, Yang L, Wang AM, Wang XY, Dai G. Roentgenographic measurement study for locating femoral insertion site of anterior cruciate ligament: a cadaveric study with X-Caliper. *Int Orthop.* 2009;33(1):133-7.
- Amis AA, Beynon B, Blankevoort L, Chambat P, Christel P, Durselen L, et al. Proceedings of the ESSKA scientific workshop on reconstruction of the anterior and posterior cruciate ligaments. *Knee Surg Sports Traumatol Arthrosc.* 1994;2(3):124-32.
- Harner CD, Marks PH, Fu FH, Irrgang JJ, Silby MB, Mengato R. Anterior cruciate ligament reconstruction: endoscopic versus two-incision technique. *Arthroscopy.* 1994;10(5):502-12.
- Aglietti P, Buzzi R, Giron F, Simeone AJ, Zaccherotti G. Arthroscopic-assisted anterior cruciate ligament reconstruction with the central third patellar tendon. A 5-8-year follow-up. *Knee Surg Sports Traumatol Arthrosc.* 1997;5(3):138-44.
- Khalfayan EE, Sharkey PF, Alexander AH, Bruckner JD, Bynum EB. The relationship between tunnel placement and clinical results after anterior cruciate ligament reconstruction. *Am J Sports Med.* 1996;24(3):335-41.
- Giron F, Buzzi R, Aglietti P. Femoral tunnel position in anterior cruciate ligament reconstruction using three techniques. A cadaver study. *Arthroscopy.* 1999;15(7):750-6.
- Shah AA, Brien A, Lowe WR. Radiographic results of femoral tunnel drilling through the anteromedial portal in anterior cruciate ligament reconstruction. *Arthroscopy.* 2010;26(12):1586-92.
- Bernard M, Hertel P, Hornung H, Cierpinski T. Femoral insertion of the ACL. Radiographic quadrant method. *Am J Knee Surg.* 1997;10(Winter (1)):14-21.
- Aglietti P. Patellar ligament versus hamstring graft for ACL. In: Instructional course lecture, combined congress of the International Arthroscopy Association and the International Society of the Knee. 1995.