



# Establishment of an efficacious treatment period for prophylaxis of auricular keloid recurrence postexcision using topical imiquimod 5%: A demonstrative case series

Lina J. Chan, BS,<sup>a</sup> and Harry L. Greenberg, MD<sup>b</sup>

**Key words:** aldara; imiquimod; keloid; postexcision; prophylaxis; shave; topical.

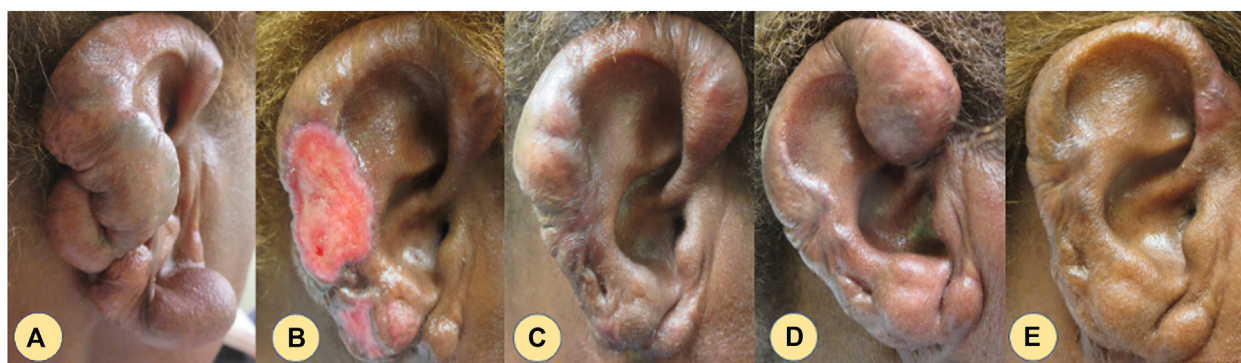
## INTRODUCTION

Keloid scars result from aberrant wound healing and have recurrence rates of 50% to 80% without treatment.<sup>1-4</sup> Clinicians who are comfortable with surgical removal often offer patients postexcision adjuvant options such as glucocorticoid creams, pressure dressings, silicone sheets, and radiation therapy.<sup>5-7</sup> These therapies involve a consistent application for success, which can lead to poor patient compliance and thus keloid recurrence.

Nonsurgical keloid treatments include intralesional steroid injections, laser treatments, and cryotherapy.<sup>5-7</sup> Although these treatment options can momentarily improve keloid appearance and symptoms, patients will have to repeatedly return for treatments.

The exact mechanism of keloid growth is unknown but transforming growth factor  $\beta$  has been theorized to play a role in keloid fibroblast activation.<sup>8,9</sup> Keloids are benign fibroproliferative disorders but demonstrate cancer-like properties, including regrowth, lack of spontaneous regression, and uncontrolled growth.<sup>10</sup> Various studies have examined imiquimod in the prophylactic treatment of keloids postexcision with success.<sup>11-16</sup>

Imiquimod is an immune response modifier with numerous antitumor properties decreasing inflammatory and fibrogenic cytokines such as transforming growth factor  $\beta$ .<sup>17</sup> Prior studies evaluated the efficacy of imiquimod adjuvant of postexcised keloids and have ambiguous treatment protocols, with some recommending application once a day and others suggesting only 3 times a week.<sup>18,19</sup> Not only



**Fig 1.** Case 1. A to E, Staged excision demonstrated.

From the Kirk Kerkorian School of Medicine at UNLV, Las Vegas, Nevada<sup>a</sup>; and Las Vegas Dermatology, Nevada, Las Vegas, Nevada.<sup>b</sup>

Funding sources: None.

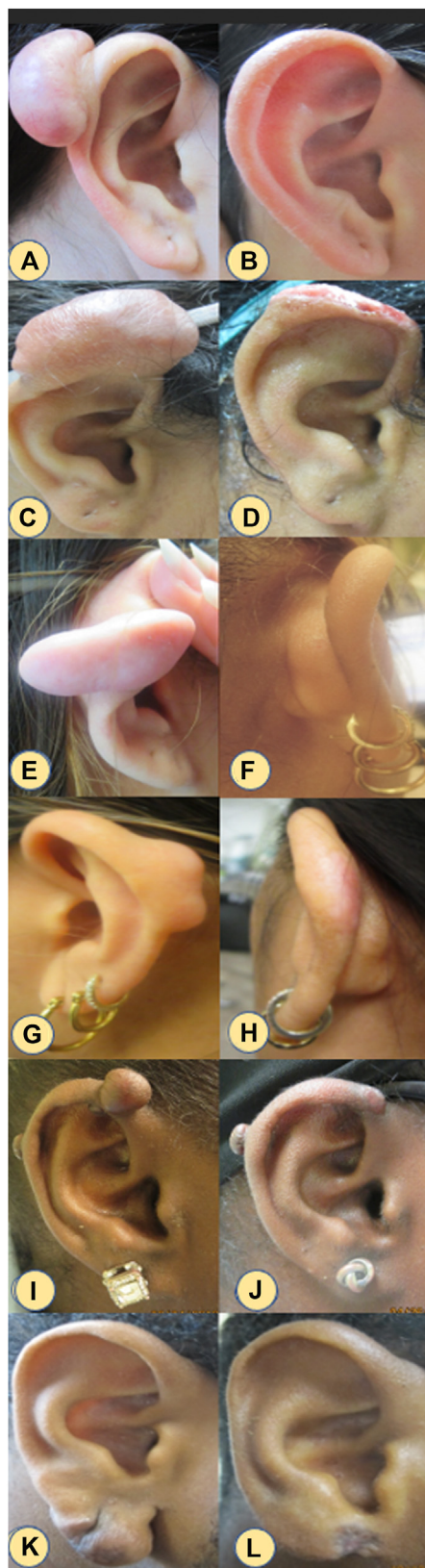IRB approval status: Not applicable.

Correspondence to: Lina J. Chan, BS, School of Medicine, 9906 Masked Duck Ave., Las Vegas, NV 89117. E-mail: [ChanL1@unlv.nevada.edu](mailto:ChanL1@unlv.nevada.edu).

JAAD Case Reports 2022;26:41-4.  
2352-5126

© 2022 by the American Academy of Dermatology, Inc. Published by Elsevier, Inc. This is an open access article under the CC BY-NC-ND license (<http://creativecommons.org/licenses/by-nc-nd/4.0/>).

<https://doi.org/10.1016/j.jdc.2022.06.012>



**Fig 2.** Case 2 to 6. Preexcision (A, C, E, G, I, K) and postexcision after complete wound healing (B, D, F, H, J, L).

do treatment regimens differ between trials, but treatment durations, which can range from 4 to 24 weeks, are also not standardized. With large discrepancies in treatment periods from other studies, our study was designed specifically to define an efficacious treatment protocol and clinical application for auricular keloid recurrence prevention.

## METHODS

Six individuals with auricular keloids from Las Vegas Dermatology were the subjects of our retrospective investigation. Keloid scar diagnosis and hypertrophic scar exclusion were made visually by a board-certified dermatologist with the following inclusion criteria: continuous growth beyond the edge of the initial wound, firm nodules, pruritic and painful scars, and tumor-like appearance (Figs 1 and 2).<sup>20</sup> As shown in Table I, participants ranged from 17 to 68 years old with keloids present from 6 months to 4 years. Our patient population ranged from III to VI in Fitzpatrick type, all of whom were keloid-prone populations (Black and Asian).<sup>21</sup> Keloid severity, symptoms (ie, pain, tenderness), and patient self-directed treatment therapies to reduce appearance were all recorded. Patients underwent surgical extirpation with healing by secondary intention except for case 6 which required primary repair. A postsurgical treatment plan of cleansing with H<sub>2</sub>O<sub>2</sub> twice daily, morning white petrolatum, and topical imiquimod 5% nightly for 6 weeks. Patients were not advised to use silicone taping or pressure therapy devices during the treatment period for keloid prophylaxis. Before and after pictures were taken in the evaluation of postexcisional healing and keloid recurrence.

## RESULTS

### Case 1

Case 1 presented with multiple keloids on the right ear present for 3 years. This patient was a lifelong sufferer of spontaneous keloids throughout the body. Intralesional steroids ameliorated associated itching and pain with scar shrinkage but no resolution. Previously failed therapies include intralesional triamcinolone steroid injections. A 4-staged multiple keloid excision was performed over a 3-year period. Fig 1A shows the initial presentation with keloids present on the right ear lobule, helix, and antihelix. After every excision, the patient waited for complete wound healing before the subsequent excision. Intralesional triamcinolone injections were administered to unoperated keloid scars between excisions.

The first excision was on the right lower lobule. Once healed (Fig 1, B) the lower helix and antihelix

**Table I.** Patient characteristics and clinical assessments

Patient no.	Age/ sex	Race	Fitzpatrick type	Duration of keloid	Location	Prior failed therapies
1	68/F	Black	VI	3 y	Right ear lobule, helix, and antihelix	Intralesional triamcinolone injections
2	24/F	Asian	III	3 y	Right superior helix	Intralesional triamcinolone injections
3	17/F	Asian	IV	2 y	Right superior helix	N/A
4	19/F	Asian	IV	4 y	Right superior helix	Intralesional triamcinolone injections
5	27/F	Black	V	6 mo	Right posterior and anterior superior helix	Home therapy (tea tree oil)
6	26/M	Black	V	6 mo	Right lobule	N/A

keloid (Fig 1, C) were excised. During the treatment period, our patient had increased keloid growth on their anterior helix which was excised, as seen in Fig 1, D. Complete surgical wound healing is demonstrated in Fig 1, E. Regrowth in excised and imiquimod 5% treated areas did not occur during this 3-year period. The dramatic change in appearance and decrease in size in this patient's right ear is noted.

**Case 2**

Case 2 (Fig 2, A) presented with a right superior helical rim keloid for 3 years. Previously failed therapy consisted of triamcinolone injections. Keloid shave excision and postsurgical regimen demonstrated keloid resolution seen in Fig 2, B, taken 3 years postexcision.

**Case 3**

Case 3 (Fig 2, C) presented with a 4.5-cm right superior helical rim keloid present for 2 years post-elective piercing. This patient complained of otalgia and pruritus. There was no previous attempted treatment to reduce keloid symptoms. Two weeks postsurgery demonstrates normal wound healing with no complications (Fig 2, D).

**Case 4**

Case 4 demonstrated a right mid posterior helical rim keloid (Fig 2, E) and a left-mid posterior helical rim keloid (Fig 2, G) present for 4 years. Previously failed therapies included triamcinolone injections. Postexcision, the right posterior helical rim healed with no obvious signs of trauma or new scarring present after 2 months (Fig 2, F). The left posterior helical rim (Fig 2, H) healed with poster inflammatory erythema but no signs of keloid recurrence.

**Case 5**

Case 5 (Fig 2, I) presented with 2 keloid scars—one on the right posterior helix and another on the right superior anterior helical rim. This patient's

keloids were caused by previous piercing and significant growth was noticed in recent months. The patient applied tea tree oil to relieve pain symptoms and keloid size with no relief. Only the right superior anterior helical rim keloid was excised with no signs of regrowth after 3 months (Fig 2, J).

**Case 6**

Case 6 (Fig 2, K) right lower lobule keloid present for 6 months. Surgical extirpation of the keloid involved suturing the lobule post-keloid excision and following the postsurgical regimen. No regrowth was demonstrated after 3 months (Fig 2, L), but hyperpigmentation was present when earlobe repair was performed.

**DISCUSSION**

There are various treatment options for keloid prophylaxis postexcision, including steroid injection, chemotherapy injection and topical (5-fluorouracil and bleomycin), topical imiquimod, topical mitomycin C, radiation therapy, compressive therapies, cryotherapy, interferons, and silicone sheeting.<sup>5,7,14,15,22</sup> In our study, only 1 patient required intralesional triamcinolone injections for the management of untreated keloid symptoms. We solely used topical imiquimod 5% to evaluate its full clinical use in prophylaxis of keloids and determined that it is suitable as a single therapy for postexcisional keloid prophylaxis. Although imiquimod 5% is a recommended option for postexcised keloid prophylaxis, there have not been many studies in recent years demonstrating visual results or defining a treatment regimen and period. Our study found that nightly imiquimod 5% topical application for 6 weeks was an efficacious post-keloid excision treatment.

Although our study had only 1 patient who was Fitzpatrick type VI (case 1), all patients included in the case series were keloid prone (Asian, Black). Case 1 suffered from lifelong spontaneous keloids

without trauma and was treated with a 4-stage excision over a 3-year period. A spontaneous keloid growth was exhibited during this treatment period, unrelated to excision or adjuvant therapy. Even with a history of spontaneous keloids, zero recurrence was exhibited in case 1, who displayed a long-term efficacy for a treatment regimen of 6-week topical imiquimod per excision for adjuvant therapy.

### Limitations

The limitations of our study include our small sample size of 6 patients, uncontrolled clinical setting, and uncertainty of patient compliance to adhere to treatment protocols.

### CONCLUSION

Topical imiquimod 5% cream once nightly for a treatment period of 6 weeks can be an effective treatment option for prophylactic treatment of keloid recurrence postexcision.

### Conflicts of interest

None disclosed.

### REFERENCES

- Jagdeo J, Kerby E, Glass DA II. Keloids. *JAMA Dermatol*. 2021; 157(6):744. <https://doi.org/10.1001/jamadermatol.2020.4705>
- Wang ZC, Zhao WY, Cao Y, et al. The roles of inflammation in keloid and hypertrophic scars. *Front Immunol*. 2020;11:603187. <https://doi.org/10.3389/fimmu.2020.603187>
- Gold MH, Nestor MS, Berman B, Goldberg D. Assessing keloid recurrence following surgical excision and radiation. *Burns Trauma*. 2020;8:tkaa031. <https://doi.org/10.1093/burnst/tkaa031>
- Klotz T, Munn Z, Aromataris EC, Greenwood JE. Imiquimod to prevent keloid recurrence postexcision: A systematic review and meta-analysis. *Wound Repair Regen*. 2020;28(1):145-156. <https://doi.org/10.1111/wrr.12766>
- Betarbet U, Blalock TW. Keloids: a review of etiology, prevention, and treatment. *J Clin Aesthet Dermatol*. 2020;13(2):33-43.
- Juckett G, Hartman-Adams H. Management of keloids and hypertrophic scars. *Am Fam Physician*. 2009;80(3):253-260.
- Ojeh N, Bharatha A, Gaur U, Forde AL. Keloids: current and emerging therapies. *Scars Burn Heal*. 2020;6:2059513120940499. <https://doi.org/10.1177/2059513120940499>
- Hunasgi S, Koneru A, Vanishree M, Shamala R. Keloid: A case report and review of pathophysiology and differences between keloid and hypertrophic scars. *J Oral Maxillofac Pathol*. 2013;17(1):116-120. <https://doi.org/10.4103/0973-029X.110701>
- Tsujita-Kyutoku M, Uehara N, Matsuoka Y, Kyutoku S, Ogawa Y, Tsubura A. Comparison of transforming growth factor-beta/Smad signaling between normal dermal fibroblasts and fibroblasts derived from central and peripheral areas of keloid lesions. *In Vivo*. 2005;19(6):959-963.
- Tan S, Khumalo N, Bayat A. Understanding keloid pathobiology from a quasi-neoplastic perspective: less of a scar and more of a chronic inflammatory disease with cancer-like tendencies. *Front Immunol*. 2019;10:1810. <https://doi.org/10.3389/fimmu.2019.01810>
- Berman B, Harrison-Balestra C, Perez OA, et al. Treatment of keloid scars post-shave excision with imiquimod 5% cream: A prospective, double-blind, placebo-controlled pilot study. *J Drugs Dermatol*. 2009;8(5):455-458.
- Berman B, Kaufman J. Pilot study of the effect of postoperative imiquimod 5% cream on the recurrence rate of excised keloids. *J Am Acad Dermatol*. 2002;47(4 Suppl):S209-S211. <https://doi.org/10.1067/mjd.2002.126585>
- Fernández-Crehuet P, Fernández-Crehuet JL, Benitez-Camacho F. Successful cosmetic outcome of earlobe keloid after surgical excision and topical imiquimod 5%. *Dermatol Ther*. 2020;33(6):e13815. <https://doi.org/10.1111/dth.13815>
- Martin-García RF, Busquets AC. Postsurgical use of imiquimod 5% cream in the prevention of earlobe keloid recurrences: results of an open-label, pilot study. *Dermatol Surg*. 2005;31(11 Pt 1):1394-1398. <https://doi.org/10.2310/6350.2005.31203>
- Aljodah MA, Alfeehan MJ, Al-Zajrawee MZ. Outcome of recurrent auricular keloid treatment with a combination of surgical excision and perioperative corticosteroid injection. *J Cutan Aesthet Surg*. 2021;14(4):392-396. [https://doi.org/10.4103/JCAS.JCAS\\_186\\_20](https://doi.org/10.4103/JCAS.JCAS_186_20)
- Prado A, Andrades P, Benitez S, Umana M. Scar management after breast surgery: preliminary results of a prospective, randomized, and double-blind clinical study with aldera cream 5% (imiquimod). *Plast Reconstr Surg*. 2005;115(3):966-972. <https://doi.org/10.1097/01.prs.0000153823.52784.7e>
- Bubna AK. Imiquimod - its role in the treatment of cutaneous malignancies. *Indian J Pharmacol*. 2015;47(4):354-359. <https://doi.org/10.4103/0253-7613.161249>
- Umamura ÁYOF, Canicoba NJB, Dorsa PP, Guarizzo J, Gonella HA. Results of keloid treatment with surgery and imiquimod 5% cream: A prospective study. *Rev Bras Cir Plást*. 2011;26(1):3-9.
- Reddy GS, Pravalika M, Lakshmi CV, Gayathri N, Mahenez F. Role of 5% imiquimod cream in the prevention of recurrence of keloids post shave excision. *Int J Contemp Med Res [IJCMR]*. 2019;6(2):1-4. <https://doi.org/10.21276/ijcmr.2019.6.2.16>
- Lv K, Xia Z. Chinese consensus panel on the prevention and treatment of scars. Chinese expert consensus on clinical prevention and treatment of scar. *Burns Trauma*. 2018;6:27. <https://doi.org/10.1186/s41038-018-0129-9>
- Robles DT, Berg D. Abnormal wound healing: keloids. *Clin Dermatol*. 2007;25(1):26-32. <https://doi.org/10.1016/j.clindermatol.2006.09.009>
- Sclafani AP, Gordon L, Chadha M, Romo T III. Prevention of earlobe keloid recurrence with postoperative corticosteroid injections versus radiation therapy: a randomized, prospective study and review of the literature. *Dermatol Surg*. 1996;22(6):569-574. <https://doi.org/10.1111/j.1524-4725.1996.tb00376.x>