

Femoral trochanteric fracture: PFNA spiral blade placement with the aid of an angler

Journal of International Medical Research

48(3) 1–11

© The Author(s) 2019

Article reuse guidelines:

sagepub.com/journals-permissions

DOI: 10.1177/0300060519890782

journals.sagepub.com/home/imr



Ye Yu, Keliang Pan and Gangxiang Wang 

Abstract

Objective: To investigate the effect of angler-assisted proximal femoral nail antirotation (PFNA) spiral blade fixation in treating femoral trochanteric fractures.

Methods: Patients who underwent angler-assisted PFNA screw blade fixation (angler-assisted group), or conventional internal fixation-intramedullary nailing (traditional surgery group) were included. Intraoperative indicators and treatment effects data were retrospectively analysed.

Results: Statistically significant differences were observed between the angler-assisted group ($n=27$) and traditional surgery group ($n=28$) regarding surgery duration (71.24 ± 8.01 min versus 81.50 ± 11.56 min), number of intraoperative fluoroscopy images (7.28 ± 0.91 versus 12.83 ± 1.55), and surgical bleeding volume (88.80 ± 7.98 ml versus 121.11 ± 27.21 ml). Rates of one-time intramedullary pin puncture for internal fixation in the angler-assisted and traditional surgery groups were 92.59% (25/27) and 32.14% (9/28), respectively. At 1 year following surgery, fractures in both groups had healed without internal fixation failure or fracture displacement failure. Harris hip function scores were 90.68 ± 4.23 (angler-assisted group) versus 81.69 ± 5.85 (traditional surgery group).

Conclusions: Angler-assisted intramedullary nailing with PFNA spiral blade provides good spiral blade positioning, low internal fixation failure rate, low fluoroscopy, short surgery time, and low bleeding volume. Hip function was well restored.

Keywords

Femoral trochanteric fracture, PFNA spiral blade, angler

Date received: 14 July 2019; accepted: 5 November 2019

Department of Orthopaedics, Shengzhou People's Hospital, Shengzhou Branch of the First Affiliated Hospital of Zhejiang University, Shengzhou, Zhejiang, China

Corresponding author:

Gangxiang Wang, Department of Orthopaedics, Shengzhou People's Hospital, Shengzhou Branch of the First Affiliated Hospital of Zhejiang University, 666 Dangu Road, Sanjiang Street, Shengzhou, Zhejiang 312400, China. Email: gangxiangwandr@163.com



Creative Commons Non Commercial CC BY-NC: This article is distributed under the terms of the Creative Commons Attribution-NonCommercial 4.0 License (<https://creativecommons.org/licenses/by-nc/4.0/>) which permits non-commercial use, reproduction and distribution of the work without further permission provided the original work is attributed as specified on the SAGE and Open Access pages (<https://us.sagepub.com/en-us/nam/open-access-at-sage>).

Introduction

Intertrochanteric fractures are common in the elderly.¹ Due to the rich blood supply in the trochanter, there is very little non-union after fracture, but hip varus is prone to occur.² Existing fixation methods are often used in patients hospitalized for fixed reduction and traction of intertrochanteric fractures of the femur, and these patients need strong intramedullary nails to stabilize the bone growth.^{3,4} The incidence of intertrochanteric fracture of the femur has increased significantly in recent years and is positively correlated with population aging.^{1,2} Current effective treatments for such injuries include open and closed reduction and internal fixation,^{5,6} and include medullary and extramedullary fixation of the intertrochanteric fractures.⁷

Despite continuous development of internal fixation devices and surgical techniques, internal fixation technology needs to be optimized and improved.¹ In addition, poor fracture reduction, prolonged surgical time, selection of the wrong type of internal fixation or excessive destruction of the local blood supply may result in poor surgical outcomes.¹

An improved proximal femoral nail (PFN) system, namely, proximal femoral nail antirotation (PFNA), is a relatively new type of proximal femoral internal fixation system.⁸ PFNA inherits the advantages of the original PFN and has the same biomechanical characteristics,⁹ however, innovations in the specific design make the fixing more effective and easier to operate. PFNA relies on a spiral blade to achieve antirotation and stable support;¹⁰ its anti-cutting stability is higher than that of traditional screw systems, and it has strong antirotation stability and resistance to varus deformity.¹¹ PFNA's spiral blade technology enhances the anchoring force to the bone and is more suitable for patients with osteoporosis and unstable fractures.^{12,13} PFNA is also

more conducive for a patient's early weight-bearing. The PFNA needs to be screwed into a spiral blade, which is easy in patients with a thin femoral neck.¹⁴ The PFNA main intermedullary nail is cannulated, and a small incision is required to insert the main nail into the medullary cavity. The main nail has a 6° external yaw angle for easy insertion from the top end of the greater trochanter into the medullary cavity.¹⁵ If the position of the guide needle is not correct, it will cause the main nail to deviate from the centre of the medullary cavity or displacement of the fracture, which may cause difficulty in insertion and lead to prolonged surgical time and increased trauma.^{16,17} Therefore, an angled blade may be used to aid accurate insertion of the PFNA spiral blade. This helps to determine the forward tilt angle of the spiral blade so that the positioning of the nail point is more accurate, duration of surgery is shorter, and the volume of femur bleeding is reduced.

Treatment of trochanteric fractures by fixation has important clinical significance. Thus, the aim of the present study was to retrospectively assess a new auxiliary tool for determining the forward tilt angle of the spiral blade, in terms of its effectiveness in increasing the accuracy of PFNA nail tip positioning, shortening the duration of surgery, and reducing the volume of surgical bleeding.

Patients and methods

Study population

This retrospective non-randomised case-control study included consecutive patients with intertrochanteric fractures who underwent intramedullary nail internal fixation at the Department of Orthopaedics, Shengzhou People's Hospital, Shengzhou, China between May 2016 and August 2018. Inclusion criteria comprised the

following: (1) patients with unilateral closed intertrochanteric fractures who were aged ≥ 60 years; and (2) patients who had been treated using a PFNA spiral blade assisted by an angler or a conventionally placed intramedullary nail. Exclusion criteria were: (1) pathological fractures (such as bone metastasis due to cancer, primary bone tumour, and metabolic bone disease); (2) a history of fractures in the affected hip; (3) bilateral femoral intertrochanteric fractures; (4) moderate to severe arthritis or femoral head necrosis at the affected side of the hip; and (5) postoperative follow-up duration < 1 year.

Patient data regarding demographics, duration of surgery, frequency of intraoperative fluoroscopy images obtained, frequency of guide pins inserted into the femoral marrow cavity, volume of intraoperative bleeding, and the Harris score of hip function were extracted from medical records and were analysed by investigators who were blinded to the experiment. For comparison, data were divided into two groups according to surgical method, namely, angler-assisted PFNA screw blade for fixation (angler-assisted group) or conventional internal fixation-intramedullary nailing (traditional surgery group).

This was a retrospective analytical study of patient case data and did not involve reintervention, thus, ethics approval was not deemed necessary. All patients included in the study provided written informed consent to undergo treatment.

Surgical method

Zimmer® Natural Nail® Cephalomedullary Asia (Zimmer Biomet; Warsaw, IN, USA) proximal femoral anatomical intramedullary nails were used in the present study. In the angler-assisted group, the PFNA spiral blade was positioned and fixed with the aid of an angler, a stainless-steel bevel protractor (Shenzhen Borui fastener;

Shenzhen, Guangdong, China; Figure 1). Surgeon preference was the main factor that governed whether patients underwent angler-assisted surgery or conventional surgery. Patients underwent internal intramedullary nail fixation under general anaesthesia according to the following method:

1. The length and diameter of the medullary cavity was estimated using a PFNA light-transmitting ruler to determine the length and diameter of the primary nail. The C-arm X-ray machine (Philips BV Endura; Philips, Amsterdam, The Netherlands) was placed in the proximal position of the proximal femur, and a long clamp was used to place the light-transmitting ruler parallel to the outside of the femur. The proximal end of the ruler was adjusted to the point where the main nail would enter and the skin was marked. At the same time, the light-transmitting ruler was placed along the central axis of the femur so that the marker rings were arranged in the isthmus. The length of the main nail was read directly from the light transmission ruler. The marker ring that was just tangent to the femoral cortex was selected, the value of which was the diameter of the main nail. Note that the main nail with the largest diameter was selected to match the medullary cavity.
2. The femoral canal was opened, the entry point was determined, and the guide needle was inserted (at least 15 cm into the medullary cavity) with the aid of the angler. The position of the initial guide pin on the lateral side must be located in the middle of the medullary cavity, as incorrect positioning will cause the PFNA intramedullary nail to enter the ventral or dorsal side too much, which will affect smooth implantation of the PFNA intramedullary nail, as well as correct positioning of the spiral blade within the femoral neck.




Figure 1. Representative image showing the stainless steel bevel protractor (angler) used in the present angler-assisted internal proximal femoral nail antirotation (PFNA) spiral blade fixation.

3. To insert the main nail, a hexagonal ball head screwdriver was used to attach the handle to the main nail by means of a connecting screw, taking care to ensure that the screw tightly engaged the main stud and handle, to avoid deviation from the direction of the spiral insert. Under fluoroscopy, the main nail was then manually inserted to the deepest point, noting that the proper main nail insertion depth should be such that the helical blade nail is located at the centre of the femoral neck.
4. After successful placement of the angler, the C-arm X-ray machine was used to collect the anteroposterior and lateral images of the hip joint. The anteroposterior and lateral images collected by fluoroscopy using the C-arm X-ray machine were then imported into the MobileView workstation (Philips).
5. The insertion planning path and simulation figure of the initial guide pin were set in the workstation (Figure 2a and 2b).
6. For the proximal interlock, the correct aiming arm was selected according to the main nail of the corresponding length and the neck dry angle, and this was then fixed onto the insertion handle. The support nut was attached to the protective sleeve and screwed to the mark on the end of the protective sleeve. The drill guide sleeve and trocar were then inserted into the protective sleeve, and the installed spiral blade sleeve was inserted into the aiming arm up to the skin until a click was heard, indicating that it was locked with the aiming arm. The mouth at the tip of the trocar was then pierced, and the sleeve assembly

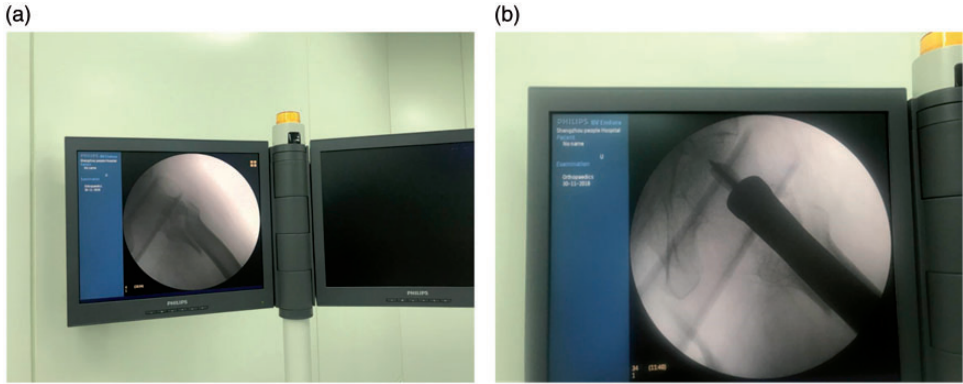


Figure 2. Representative workstation images (a and b) showing angle-assisted placement of the proximal femoral nail antirotation (PFNA) blade.

was inserted through the soft tissue into the lateral cortex. The support nut was then gently turned clockwise to push the protective sleeve to the outer cortex. The position of the guide pin should be determined on the positive side before measurement. The needle depth gauge showed the actual length of the needle within the bone. The hollow drill bit was then pushed along the 3.2-mm guide pin and drilled to the depth limited to that required to open the outer cortex. The positioning sleeve was placed on the measured length mark on the hollow reamer, and the side of the positioning sleeve that faced the tip of the drill bit was the selected length. The screw blade was then connected to the propeller and turned counterclockwise, screwing the propeller into the end of the spiral blade to unlock it. Further pivoting the support nut counterclockwise, viewed under fluoroscopy, obtained intraoperative pressure and closed the fracture line.

7. For the remote interlock, after a small opening was punctured in the skin, the drill protection sleeve was inserted through the static locking hole on the robotic arm to reach the cortical bone (Figure 3). The sleeve needle was then removed and the cortex was drilled

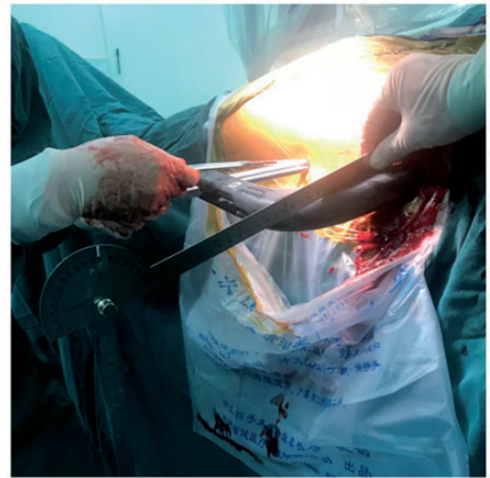


Figure 3. Representative image showing the operative region of a patient's hip. A guide pin was drilled into the femoral medullary cavity percutaneously assisted by a robotic arm.

using a 4 mm drill bit. The required cross was selected directly according to the reading on the drill bit. The length of the lock pin and the interlocking nail were determined by the sounder, and 2–4 mm was added to the measured length to ensure that the interlocking nail and the contralateral cortex were fixed. The protective sleeve was screwed

into the locking pin using a large hexagonal screwdriver.

8. To put on the tail cap, the protective sleeve and aiming arm were removed and the hex wrench was used to suspend the connection and remove the insertion arm. The hooked guide pin was inserted through the selected end cap. The hollow screwdriver was then passed through the guide pin to the tail cap. Finally, the incision was sutured.

Observation measures

Duration of surgery (Surgical time). Surgical time was defined as beginning immediately after the sterile towel was laid and ended with the sutured incision, and was mainly affected by the number of intraoperative fluoroscopy images taken, whereby repeated fluoroscopy imaging during the procedure would prolong the surgery.

Number of intraoperative fluoroscopy images. Data regarding the number of intraoperative fluoroscopy images taken during surgery, including each anteroposterior and lateral fluoroscopy image, were extracted. Repeated insertion of guide pins into the femoral marrow cavity would require an increased number of intraoperative fluoroscopy images.

Volume of surgical bleeding. Blood lost during surgery was collected into a drainage bag, and the recorded volume data were extracted. Prolonged surgical time would be related to increased intraoperative blood loss.

Fracture healing. Data from postoperative follow-up observations were extracted for all included patients, and comprised orthotopic and lateral X-ray images of the hip joint, reviewed at 1, 2, 3, 6, 9, and 12 months following surgery, to observe whether the implanted intramedullary nail

was stable, the fracture line had disappeared, and whether the fracture end had been displaced. Patients were advised to return to the hospital for re-examination at least every 6 months and 1 year following surgery to determine whether the internal fixation had failed.

Harris Hip Score. Data regarding postoperative functional rehabilitation status, evaluated using the Harris hip score, was extracted. The hip function of all patients was evaluated by a physical examination of joint activity at 1 year following surgery, according to the Harris hip scoring standard,¹⁸ that was used to score and grade the pain, gait, and other functions of the affected hip joint, and the degree of deformity. The overall Harris hip score varies between 0 and 100, where higher scores represent better hip function. The postoperative hip status (representing the clinical effects) was scored as follows: excellent, 90–100 points; good, 80–89 points; fair, 70–79 points; poor, <70 points. The mean Harris hip scores, and the rates for each score grade, were calculated for each group.

Statistical analyses

Statistical analyses were performed using SPSS software, version 20.0 (IBM, Armonk, NY, USA). Measurement data, including surgical time, number of intraoperative fluoroscopy images, frequency of guide pin insertion into the femoral marrow cavity, volume of surgical bleeding, and Harris hip scores are presented as mean \pm SD and were statistically analysed using Student's *t*-test. Data for the rate of one-time guide pin insertion into the femoral marrow cavity was statistically analysed using Fisher's exact test of probabilities in a 2×2 data table. The 'excellent' and 'good' Harris hip score rates were statistically

Table 1. Comparison of intraoperative characteristics patients who received angler-assisted proximal femoral nail antirotation screw blade for fixation (angler-assisted group) or conventional internal fixation-intramedullary nailing (traditional surgery group).

Study group	Number of cases	Surgery duration (min)	Frequency of intraoperative fluoroscopy imaging	Volume of surgical bleeding (ml)
Angler assisted group	27	71.24 ± 8.01	7.28 ± 0.91	88.80 ± 7.98
Traditional surgery group	28	81.50 ± 11.56	12.83 ± 1.55	121.11 ± 27.21
t-value		3.21	4.51	2.61
Statistical significance		$P = 0.002$	$P < 0.001$	$P < 0.001$

Data presented as mean ± SD.

Statistically significant between-group differences at $P < 0.05$ (Student's *t*-test).

analysed using χ^2 -test. A P value < 0.05 was considered statistically significant.

Results

Patient demographics

A total of 55 patients with intertrochanteric fractures who underwent intramedullary nail internal fixation were included in this study, comprising 27 patients in the angler-assisted group and 28 patients in the traditional surgery group. The angler-assisted group included 13 male and 14 female patients (mean age, 73.4 years; range, 59–85 years), and the traditional surgery group included 14 male and 14 female patients (mean age, 72.5 years; range, 61–84 years).

Intraoperative measures

The duration of surgery (surgery time) was 12.34% shorter in the angler-assisted group (71.24 ± 8.01 min) compared with the traditional surgery group (81.50 ± 11.56 min; $P < 0.05$; Table 1).

The number of intraoperative fluoroscopy images obtained was 42.25% lower in the angler-assisted group (7.28 ± 0.91 images) than in the traditional surgery group (12.83 ± 1.55 images; $P < 0.05$; Table 1).

The volume of surgical bleeding was 26.67% lower in the angler-assisted group (88.80 ± 7.98 ml) compared with the

traditional surgery group (121.11 ± 27.21 ml; $P < 0.05$; Table 1).

The rate of one-time internal fixation intramedullary pin puncture was 92.59% (25/27) in the angler-assisted group compared with 32.14% (9/28) in the traditional surgery group ($P < 0.05$).

Outcome measures

All patients were followed for two years. During the two-year follow-up, no loosening of the internal fixation and no fracture displacement had occurred.

Harris hip score was determined in both groups at 1 year following surgery. The mean Harris score of hip function was 9.93% higher in the angler-assisted group (90.68 ± 4.23) than in the traditional surgery group (81.69 ± 5.85; $t = 2.78$, $P < 0.001$). In the angler-assisted group, the clinical effect was 'excellent' in 17 cases, 'good' in eight cases, 'fair' in two cases, and 'poor' in 0 cases, resulting in an 'excellent' and 'good' rate of 92.59% (25/27). In the traditional surgery group, the clinical effect was 'excellent' in eight cases, 'good' in 12 cases, 'fair' in four cases, and 'poor' in four cases, resulting in an 'excellent' and 'good' rate of 71.43% (20/28). The rates of combined 'excellent' and 'good' Harris hip scores were significantly different between the two groups ($P < 0.05$).

Discussion

As the number of patients with intertrochanteric fractures has increased, attention has focussed on the fixation of fractures, particularly intramedullary and extramedullary fixation. For intertrochanteric fractures of the femur, particularly the femoral trochanteric fractures, intramedullary fixation has certain advantages over extramedullary fixation, such as increased patient activity and reduced surgical failure rate.¹⁹⁻²¹ The frequency of use of intramedullary nailing is influenced by the surgeon's experience, and unstable bare-hand surgeries and visual bias make it difficult to ensure one-time success. Repeatedly adjusting the guide pin puncture path will increase the number of punctures, which may cause reinjury of muscles, soft tissues, and bones, increase the degree of surgical trauma, and increase the amount of bleeding in patients. At the same time, prolonging the surgical time and increasing the fluoroscopy imaging and exposure time of patients and medical staff to radiation will have a great impact on the health of both doctors and patients.

Intertrochanteric fracture is a type of orthopaedic disease with a high incidence among the elderly, that increases year by year with the continuous changes in people's living standards and living habits. Clinical statistics demonstrate that disease accounts for about 5% of femoral fractures.²² In the past, the main clinical treatment for intertrochanteric fractures was PFN internal fixation, however, because elderly patients need to rest in bed for a long time, patients are prone to complications, and the treatment effect is not satisfactory.²³ Conventional surgical treatment involves the sliding nail internal fixation system, but this method produces considerable trauma to the patient and results in increased intraoperative blood loss. In addition, osteoporosis occurs under the steel plate because the periosteum under the

steel plate is prone to ischaemia.²⁴ Furthermore, because of excessive peeling of the periosteum, the patient's fracture site could become necrotic due to ischaemia, and the fracture site would have difficulty healing. A series of complications may easily occur following surgery, including screw cutting and hip deformity,⁷ therefore, in elderly patients with intertrochanteric fractures, the use of intramedullary fixation is more effective. The proximal femoral nail (PFN) is based on an improvement of the Gamma nail fixation method.¹⁶ Features include a small bending moment, short arm, sliding pressure, and hip screw antirotation, and it has the advantage of using double nails in the patient's femoral neck for weight-bearing so that the tensile, antirotation, and anti-stress ability of the fracture site is greatly enhanced.²⁵ The distal end of the main nail in PFN internal fixation has a special groove design, which can effectively reduce the phenomenon of refracture during the recovery process. Compared with previous methods, the surgery is more convenient, the design is more reasonable, and the damage to the patient's body is less, thus, the procedure is more suitable for elderly patients with poor recovery ability.^{26,27} PFNA is a relatively new type of proximal femoral nail for PFN internal fixation that involves a spiral blade. The effect of inserting two screws in the internal fixation method is the same, but PFNA greatly shortens the duration of surgery, makes the surgery easier, and patients have fewer complications following surgery.^{17,28} In the PFNA internal fixation method, the spiral blade is inserted directly into the body before drilling, removing the need to drill in advance.²⁹ Loss of cancellous bone during surgery is reduced, which is more conducive to patient recovery in the later stage. At the same time, after the spiral blade is inserted, loose bone around the affected limb will become denser and stronger after being

squeezed.³⁰ Relevant research has shown that the cancellous bone can be better pressed to strengthen the firmness of the spiral blade.³⁰ Stability, better prevention of collapse and rotation, and stronger anti-extraction force compared with screw fixation in the PFN internal fixation method allow patients to recover faster and with better therapeutic effect.⁹ As the PFNA internal fixation nail has a distal locking screw hole, only insertion of a coil into the femoral neck during fixing is necessary, and after inserting a distal nail, the surgery can be completed.³¹

The PFNA internal fixation method uses a long groove and tip design to make it easier to insert into the patient, while avoiding a concentration of pressure in the same area, effectively improving the hip function after surgery and reducing the patient's postsurgical pain. However, regarding the current clinical method of surgical application, the PFNA blade is prone to direction deviation during insertion into the patient.³² The probability of one-time insertion direction success depends on the surgeon's experience, and the surgical effect will have an impact on the patient.³³ The present study found that an angle device that can assist the insertion of the PFNA blade improved the success rate of insertion, reduced the surgical time and the amount of surgical bleeding, and, thus, reduced the duration of radiation exposure for the patient. The study also found that postoperative recovery, in terms of Harris hip score, was better in the angler-assisted patient group than in patients who underwent conventional surgery without the assistance of an angler. Therefore, using an angle device during PFNA internal fixation appears to be more effective in treating patients with femoral trochanteric fractures.

The present study results may be limited by certain factors. For example, this was a retrospective single-centre study in a series

of patients with simple femoral fractures. Further studies should include cases with other fracture complications, such as comminuted fractures, pelvic fractures, and major bleeding, to ascertain whether use of an angler improves outcomes in such cases.

Declaration of conflicting interest

The authors declare that there is no conflict of interest.

Funding

This research received no specific grant from any funding agency in the public, commercial, or not-for-profit sectors.

ORCID iD

Gangxiang Wang  <https://orcid.org/0000-0001-5455-8446>

References

1. von Rden C, Hungerer S, Augat P, et al. Breakage of cephalomedullary nailing in operative treatment of trochanteric and subtrochanteric femoral fractures. *Arch Orthop Trauma Surg* 2015; 135: 179–185.
2. Yoon BH and Park SB. Insufficiency fracture occurring 3 years after union of an intertrochanteric hip fracture: a case report. *JBJS Case Connect* 2017; 7: e1.
3. Cui Q, Liu YS, Li DF, et al. Cemented hip hemiarthroplasty clinical observations on unstable intertrochanteric fracture in elderlies. *Eur J Trauma Emerg Surg* 2016; 42: 651–656.
4. Yang X, Wu Q, and Wang X. Investigation of perioperative hidden blood loss of unstable intertrochanteric fracture in the elderly treated with different intramedullary fixations. *Injury* 2017; 48: 1848–1852.
5. Ahn J and Bernstein J. Fractures in brief: intertrochanteric hip fractures. *Clin Orthop Relat Res* 2010; 468: 1450–1452.
6. Butler M, Forte M, Kane RL, et al. *Treatment of common hip fractures. Evidence Report/Technology Assessment No. 184.* AHRQ Publication No. 09-E013, August 2009. Rockville: Agency for Healthcare Research and Quality.

7. Kokoroghiannis C, Aktselis I, Deligeorgis A, et al. Evolving concepts of stability and intramedullary fixation of intertrochanteric fractures—a review. *Injury* 2012; 43: 686–693.
8. Jiang X, Wang Y, Ma X, et al. Proximal femoral nail antirotation versus reverse less invasive stabilization system-distal femur for treating proximal femoral fractures: a meta-analysis. *Medicine (Baltimore)* 2016; 95: e3168.
9. Luo X, He S, Zeng D, et al. Proximal femoral nail antirotation versus hemiarthroplasty in the treatment of senile intertrochanteric fractures: case report. *Int J Surg Case Rep* 2017; 38: 37–42.
10. Esen E, Dur H, Ataoglu MB, et al. Evaluation of proximal femoral nail-antirotation and cemented, bipolar hemiarthroplasty with calcar replacement in treatment of intertrochanteric femoral fractures in terms of mortality and morbidity ratios. *Ekleml Hastalik Cerrahisi* 2017; 28: 35–40.
11. Cho HM and Lee K. Clinical and functional outcomes of treatment for type a1 intertrochanteric femoral fracture in elderly patients: comparison of dynamic hip screw and proximal femoral nail antirotation. *Hip Pelvis* 2016; 28: 232–242.
12. Sadic S, Custovic S, Jasarevic M, et al. Proximal femoral nail antirotation in treatment of fractures of proximal femur. *Med Arch* 2014; 68: 173–177.
13. Zehir S, Zehir R, Zehir S, et al. Proximal femoral nail antirotation against dynamic hip screw for unstable trochanteric fractures; a prospective randomized comparison. *Eur J Trauma Emerg Surg* 2015; 41: 393–400.
14. Jiamton C, Boernert K, Babst R, et al. The nail-shaft-axis of the of proximal femoral nail antirotation (PFNA) is an important prognostic factor in the operative treatment of intertrochanteric fractures. *Arch Orthop Trauma Surg* 2018; 138: 339–349.
15. Sadic S, Custovic S, Jasarevic M, et al. Proximal femoral nail antirotation in treatment of intertrochanteric hip fractures: a retrospective study in 113 patients. *Med Arch* 2015; 69: 352–356.
16. Sharma A, Mahajan A, and John B. A comparison of the clinico-radiological outcomes with proximal femoral nail (PFN) and proximal femoral nail antirotation (PFNA) in fixation of unstable intertrochanteric fractures. *J Clin Diagn Res* 2017; 11: RC05–RC09.
17. Hong JB, Dan Y, Ouyang L, et al. Biomechanical study on different lengths of PFNA fixation for unstable intertrochanteric femoral fractures. *J Musculoskelet Neuronal Interact* 2017; 17: 299–302.
18. Nilsson A and Bremander A. Measures of hip function and symptoms: Harris Hip Score (HHS), Hip Disability and Osteoarthritis Outcome Score (HOOS), Oxford Hip Score (OHS), Lequesne Index of Severity for Osteoarthritis of the Hip (LISOH), and American Academy of Orthopedic Surgeons (AAOS) Hip and Knee Questionnaire. *Arthritis Care Res (Hoboken)* 2011; 63: S200–S207.
19. Parker MJ, Bowers TR, and Pryor GA. Sliding hip screw versus the Targon PF nail in the treatment of trochanteric fractures of the hip: a randomised trial of 600 fractures. *J Bone Joint Surg Br* 2012; 94: 391–397.
20. Queally JM, Harris E, Handoll HH, et al. Intramedullary nails for extracapsular hip fractures in adults. *Cochrane Database Syst Rev* 2014; 9: CD004961.
21. Parker MJ and Handoll HH. Gamma and other cephalocondylic intramedullary nails versus extramedullary implants for extracapsular hip fractures in adults. *Cochrane Database Syst Rev* 2008; 3: CD000093.
22. Fang C, Gudushauri P, Wong TM, et al. Increased fracture collapse after intertrochanteric fractures treated by the dynamic hip screw adversely affects walking ability but not survival. *Biomed Res Int* 2016; 2016: 4175092.
23. Hsu CE, Shih CM, Wang CC, et al. Lateral femoral wall thickness. A reliable predictor of post-operative lateral wall fracture in intertrochanteric fractures. *Bone Joint J* 2013; 95-B: 1134–1138.
24. Filardi V. Characterization of an innovative intramedullary nail for diaphyseal fractures of long bones. *Med Eng Phys* 2017; 49: 94–102.
25. Gölge UH, Pazarcı O, Kılınc S, et al. The treatment of intertrochanteric fractures comparison of PFN and hemiarthroplasty

- 3-year mortality study. *Acta Orthop Belg* 2016; 82: 508–515.
26. Banan H, Al-Sabti A, Jimulia T, et al. The treatment of unstable, extracapsular hip fractures with the AO/ASIF proximal femoral nail (PFN)—our first 60 cases. *Injury* 2002; 33: 401–405.
 27. Wang XD, Lan H and Li KN. Treatment of femoral neck fractures with cannulated screw invasive internal fixation assisted by orthopaedic surgery robot positioning system. *Orthop Surg* 2019; 11: 864–872.
 28. Lei J, Zhang B, Cong Y, et al. Tranexamic acid reduces hidden blood loss in the treatment of intertrochanteric fractures with PFNA: a single-center randomized controlled trial. *J Orthop Surg Res* 2017; 12: 124.
 29. Makki D, Matar HE, Jacob N, et al. Comparison of the reconstruction trochanteric antigrade nail (TAN) with the proximal femoral nail antirotation (PFNA) in the management of reverse oblique intertrochanteric hip fractures. *Injury* 2015; 46: 2389–2393.
 30. Wild M, Jungbluth P, Thelen S, et al. The dynamics of proximal femoral nails: a clinical comparison between PFNA and Targon PF. *Orthopedics* 2010; 33. DOI: 10.3928/01477447-20100625-04.
 31. Jia L, Zhang K, Wang ZG, et al. Proximal femoral nail antirotation internal fixation in treating intertrochanteric femoral fractures of elderly subjects. *J Biol Regul Homeost Agents* 2017; 31: 329–334.
 32. Kini SG, Hin LC, and Haniball J. Lateral cortex blowout during PFNA blade insertion in a subtrochanteric fracture—should bone quality determine the type of nail used. *Chin J Traumatol* 2015; 18: 116–119.
 33. Carulli C, Piacentini F, Paoli T, et al. A comparison of two fixation methods for femoral trochanteric fractures: a new generation intramedullary system vs sliding hip screw. *Clin Cases Miner Bone Metab* 2017; 14: 40–47.