

Single-stage medial open reduction and Pemberton acetabuloplasty in developmental dysplasia of the hip

Mehmet Emre Baki, Celal Baki, Hafız Aydın, Bünyamin Arı and Murat Özcan

In this study, we aimed to evaluate the long-term clinical and radiological results of single-stage open reduction through a medial approach and Pemberton acetabuloplasty in developmental dysplasia of the hip. We treated 32 hips (22 patients) with developmental dysplasia by a single-stage open reduction through Ferguson's medial approach and Pemberton acetabuloplasty. The procedure was performed bilaterally in 10 patients. The mean age of the patients at the time of the operation was 19.8 months (16–24 months). The mean follow-up period was 10.9 years (7–19 years). Group I avascular necrosis according to the Kalamchi and MacEwen classification was observed in two hips and group II in one hip. Radiologically, 90.6% of the hips were classified as Severin class I and 9.4% of the hips were classified as Severin class II. At the latest follow-up, 30 hips were assessed clinically as excellent and two hips as good. No

patient required subsequent surgery. We conclude that single-stage medial open reduction and Pemberton acetabuloplasty represent an effective method for developmental dysplasia of the hip in children older than 15 months of age. *J Pediatr Orthop B* 25:504–508 Copyright © 2016 Wolters Kluwer Health, Inc. All rights reserved.

Journal of Pediatric Orthopaedics B 2016, 25:504–508

Keywords: developmental dysplasia of the hip, medial open reduction, Pemberton osteotomy

Department of Orthopaedics and Traumatology, Karadeniz Technical University School of Medicine, Trabzon, Turkey

Correspondence to Mehmet Emre Baki, Assistant Professor, Department of Orthopaedics and Traumatology, Karadeniz Technical University School of Medicine, 61080 Trabzon, Turkey
Tel: +90 462 377 56 60; e-mail: bakiemre61@yahoo.com

Introduction

The medial approach for open reduction of developmental dysplasia of the hip was first described by Ludloff in 1908 [1]. In 1973, Ferguson modified this approach by using a more posterior interval [2]. Open reduction through a medial approach has been used in children younger than 24 months of age [2]. This method has been described as a simple and atraumatic procedure that enables bloodless access to the medial and inferior sections of the hip joint [2–4].

The pericapsular acetabuloplasty was described by Pemberton in 1965 [5]. This is a reshaping incomplete iliac osteotomy in which the acetabular roof is hinged on the triradiate cartilage. Thus, the lower fragment of the ilium is rotated forward, downward and outward [5]. Pemberton acetabuloplasty (PA) enables greater correction of acetabular dysplasia by providing further lateral and anterior acetabular coverage than the Salter osteotomy [6].

In our centre, the Ferguson medial approach has been applied as a first treatment option for dislocations presenting after six months of age or where splintage has failed. PA was administered in patients older than 15 months of age who had an acetabular angle greater than 35° on preoperative radiographs or instability at the end of medial open reduction.

In this retrospective study, we present our experience with open reduction through a medial approach and PA in a single session in patients older than 15 months of age. To our knowledge, this is the first report of a combination of Ferguson medial open reduction with PA in a single-stage operation.

Patients and methods

We retrospectively reviewed the records of 22 patients (32 hips) who underwent a single-stage open reduction through the medial approach and PA for developmental dysplasia of the hip between 1995 and 2007. Neuro-muscular or teratologic hip dislocations were not included in the study. This study was approved by the institutional ethics committee. No patient had received any previous treatment. There were 21 girls and one boy. Both hips were affected in 10 patients, the right hip in 15 patients and the left hip in 17. In patients who had bilaterally dislocated hips, bilateral medial open reduction and bilateral PA were performed during the same session. PA was performed in 26 hips that had an acetabular angle greater than 35° on preoperative radiographs and six hips that had instability at the end of medial open reduction. Femoral shortening osteotomy was not performed in any patient. All operations were performed by the senior author (C.B.). The mean age of the patients at the time of the operation was 19.8 months (16–24). The mean follow-up period was 10.9 years (7–19).

This is an open-access article distributed under the terms of the Creative Commons Attribution-Non Commercial-No Derivatives License 4.0 (CCBY-NC-ND), where it is permissible to download and share the work provided it is properly cited. The work cannot be changed in any way or used commercially.

Operative technique

A medial approach was applied through the interval between the adductor longus and the gracilis. The lesser trochanter was identified with blunt dissection and iliopsoas tenotomy was performed. The joint capsule was carefully opened inferomedially and great care was taken to avoid damage to the medial femoral vessels. In all patients, the ligamentum teres and the pulvinar were removed. After the open reduction, a PA was performed through an anterior iliofemoral approach without capsular dissection and capsulorrhaphy. A curved cut was made on the medial and lateral walls of the acetabulum and extended down to the posterior wing of the triradiate cartilage. After the osteotomy, the lower fragment was rotated anterolaterally. A triangular bone graft was taken from the ipsilateral iliac bone and placed into the osteotomy site. No internal fixation was used. The stability of the hip was checked in different positions. Then, a hip spica cast was applied at 20° of flexion, 30° of abduction and 10° of internal rotation for 6 weeks. After the removal of the cast, an abduction brace was used at all times for 6 weeks.

At the final follow-up, clinical and radiological evaluations were performed using the modified McKay [7] and Severin [8] classification systems. The position of the femoral capital ossification centre on preoperative radiographs was assessed using the method of Tönnis [9]. Avascular necrosis was classified on the basis of the criteria of Kalamchi and MacEwen [10]. To evaluate the development of the acetabulum and the proximal femur, we measured the acetabular angle, the centre–edge angle and the neck–shaft angle of the femur on radiographs taken preoperatively, at the end of the first, third and fifth years, and at the final follow-up. The film focal length was 110 cm in all cases. All preoperative and postoperative radiographs were evaluated by the same author (M.E.B.) using the same goniometer.

The statistical analyses were carried out using the IBM SPSS Statistics for Windows, version 22 (IBM Corp., Armonk, New York, USA). Percentage, rate, average and SD were used as descriptive statistics. The compliance of the quantitative data with normal distribution was evaluated using the Kolmogorov–Smirnov test. The parametric data were compared using the Student *t*-test. The χ^2 -test was used to assess the correlation between preoperative Tönnis hip scores and the presence of avascular necrosis at the latest follow-up. *P* value less than 0.05 was considered to be statistically significant.

Results

According to the Tönnis classification system, 20 hips were classified as grade II, nine were grade III and three were grade IV on the basis of the preoperative radiographs. There was no redislocation, loss of concentric reduction, infection or graft extrusion postoperatively. No patient required subsequent surgery (Fig. 1).

At the final follow-up, clinical results were excellent in 30 hips (93.8%) and good in two (6.2%). Radiological assessment showed that 29 hips (90.6%) were rated as class I and three hips (9.4%) were class II (Fig. 2). The mean preoperative and postoperative radiological measurements are shown in Table 1.

Postoperatively, only three hips (9.3%) showed evidence of avascular necrosis. Two hips were classified as group I and one hip as group II according to the classification system of Kalamchi and MacEwen. All three hips showed very good radiological features at the final follow-up (two Severin class I and one Severin class II). At the latest follow-up, the centre–edge angles of the operated hips (mean 37.6°) were significantly higher than those of the unaffected hips (mean 29.5°) in unilateral operated patients ($P < 0.0001$). There was no statistically significant difference between the acetabular angles of the operated hips (mean 10.8°) and those of the unaffected hips (mean 14.4°) in unilateral operated patients ($P = 0.427$).

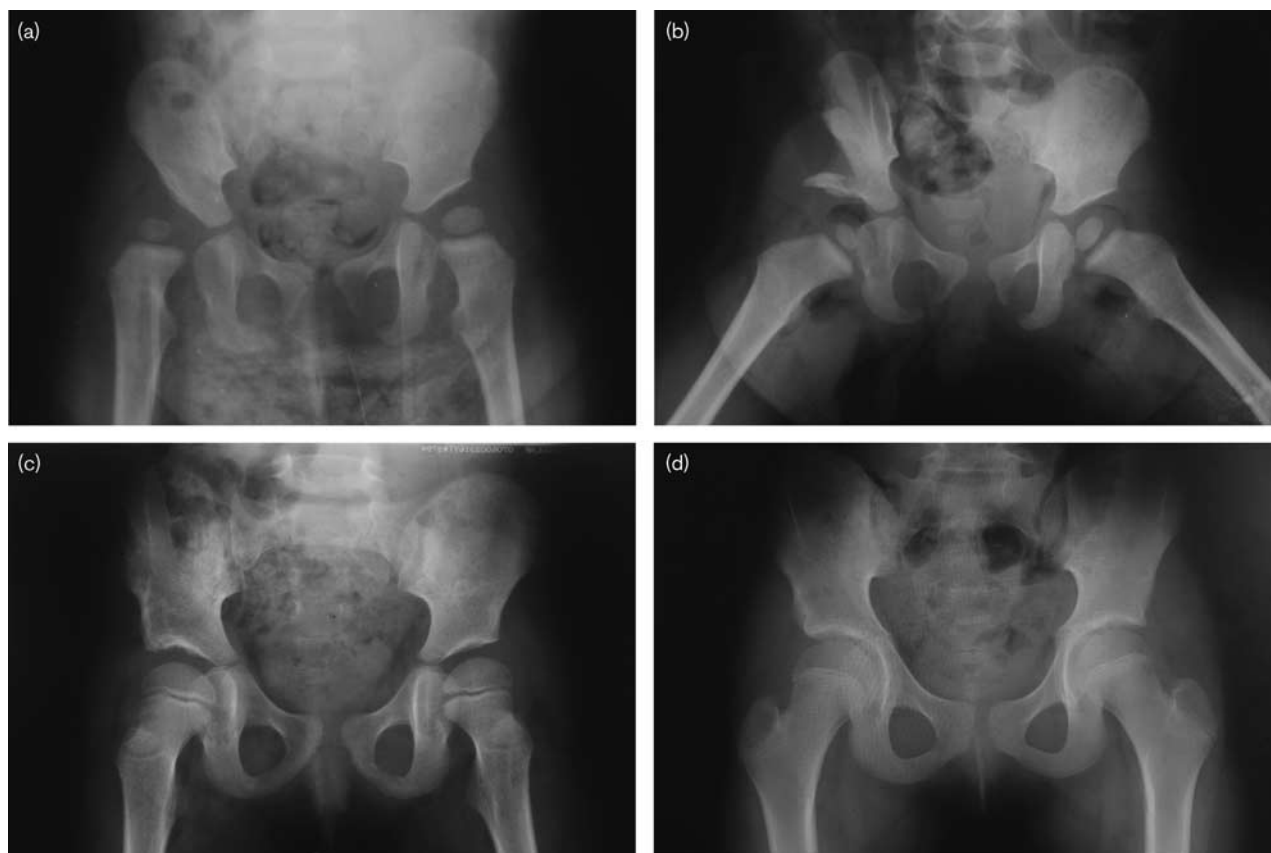
Discussion

The basic goal of the treatment in developmental dysplasia of the hip is to achieve a stable concentric reduction and to maintain the reduction during childhood and adolescence.

Open reduction through a medial approach enables direct access to the main obstacles to concentric reduction, such as tight iliopsoas tendon, inferomedial joint capsule, hypertrophied ligamentum teres and hypertrophied pulvinar. Thus, an intervention to correct for this obstacle can easily be performed with a medial approach. In our clinic, we have been using the Ferguson medial approach for 35 years and we believe that a medial approach is easier than an anterolateral approach for an experienced surgeon [11,12].

Avascular necrosis is one of the most feared complications of the treatment for developmental dysplasia of the hip. Reported rates of the incidence of avascular necrosis after medial open reduction vary from 0 to 67% [2,3,11–15]. Extensive capsular dissection, T-shaped capsular incision and ligation of femoral circumflex vessels during the operation were considered responsible for increasing the incidence of avascular necrosis [11]. However, some recent studies have reported that the risks of avascular necrosis are not significantly different between medial open reduction and anterolateral open reduction at early to mid-term follow-up periods [16,17]. Avascular necrosis was acceptably low, with a 9.3% rate, in our study. We took great care to avoid damaging the medial circumflex vessels and we only performed a longitudinal inferomedial capsular incision. Moreover, no patient received previous failed treatment, the ossific nucleus was present before the operation in all hips and we practiced the PA without capsular dissection. We believe that all these

Fig. 1



Anteroposterior pelvis views of a 17-month-old girl with right hip dysplasia. (a) Preoperative view. (b) After open reduction through the medial approach and PA. (c) Three years' postoperative view. (d) Nine years later, with excellent clinical and radiological results. PA, Pemberton acetabuloplasty.

precautions contributed towards the low avascular necrosis rates.

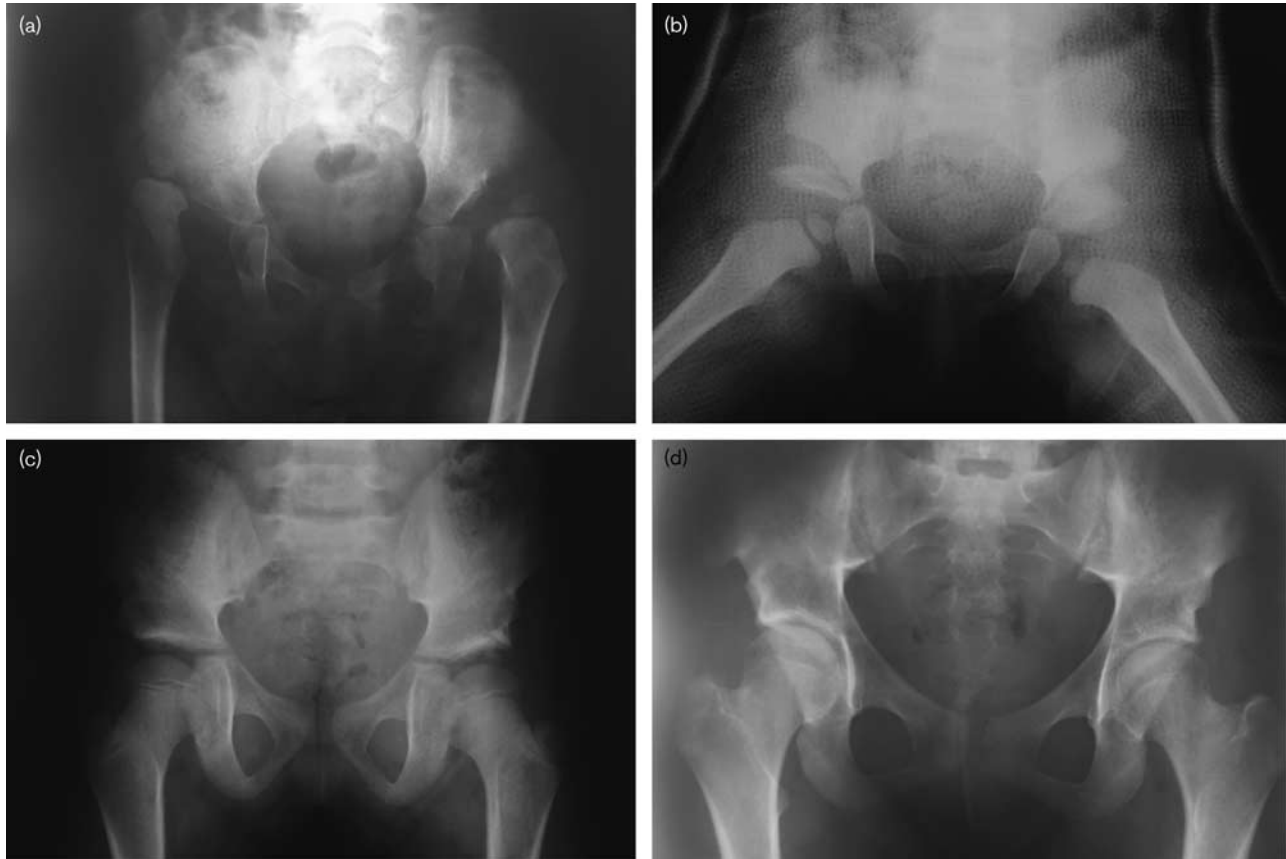
One criticism of the medial approach is that it may require secondary interventions for residual dysplasia. The rate of additional operations varies in the literature. Kiely *et al.* [18] reported that 22.4% of hips reduced using a Ferguson medial approach required further pelvic or femoral osteotomies over a mean 82-month follow-up period. Koizumi *et al.* [14] reported a 45.7% rate of additional operations after open reduction through a medial approach. Similarly, Sener *et al.* [19] have found the incidence of secondary procedures after medial open reduction of up to 70% in children older than 18 months of age. Salter and Dubos [20] recommended a pelvic osteotomy at the time of open reduction for correction of residual dysplasia because they believed that the potential for acetabular remodelling declines rapidly after 18 months of age [21]. In contrast, Albinana *et al.* [22] reported that acetabular improvement may continue up to 6 years after reduction. Baki *et al.* [11] had previously reported satisfactory results of single-stage medial open reduction and Salter innominate osteotomy in our clinic.

They reported no secondary interventions for residual dysplasia or redislocation over a mean 9.6-year follow-up period. Furthermore, it was shown that adding a pelvic osteotomy after the open reduction in the same session for the treatment of developmental dysplasia of the hip significantly reduced the incidence of subsequent surgery [23,24].

We combined the medial open reduction with PA in a single-stage procedure in patients who had an acetabular angle greater than 35° on the preoperative radiograph or instability after medial open reduction for preventing residual dysplasia. To our knowledge, this is the first report of a combination of Ferguson medial open reduction with PA in a single-stage operation.

PA also has the advantage that patients with bilateral dislocations can be operated bilaterally in a single session, in contrast with the Salter osteotomy. A disadvantage of the Ferguson medial approach is the inability to perform a capsulorrhaphy; this can increase the risk of instability. In six hips, there was an instability after open reduction in our series. In all unstable hips, the acetabular angle

Fig. 2



Anteroposterior pelvis views of a 20-month-old girl with bilateral hip dislocation. (a) Preoperative view. (b) After bilateral open reduction through a medial approach and bilateral PA in a single session. (c) Five years after the operation. (d) 14 years later, with excellent clinical and radiological results. PA, Pemberton acetabuloplasty.

Table 1 Mean (range) acetabular, centre-edge and neck-shaft angles before and after surgery

	Acetabular angle	CE angle	Neck-shaft angle
Preoperative	40.1 (30–52)	–	152.9 (139–171)
Postoperative (years)			
1	12.6 (7–25)	31.2 (27–38)	146.3 (136–160)
3	10.1 (6–20)	32.6 (28–40)	143.3 (135–154)
5	9.6 (5–18)	34.1 (28–41)	141.2 (135–150)
At the final follow-up	8.9 (5–16)	35.5 (28–43)	139.1 (132–149)

was greater than 30° . According to the literature, the combination of instability and acetabular dysplasia may increase the requirement for additional corrective operations in this age group [13–15]. Therefore, we preferred PA instead of capsuloplasty in these unstable hips to avoid subsequent operations. In our series, no patient required subsequent operation for subluxation, redislocation or residual dysplasia. We consider that PA provides sufficient stability to the hip joint and removes the disadvantage of the absence of capsulorrhaphy in the Ferguson medial approach.

Femoral shortening osteotomies were usually performed if the surgeon judged the reduction to be under excessive tension [25]. Furthermore, femoral shortening was recommended in older patients (>36 months of age) and high dislocations [26]. We did not perform femoral shortening in any patient because our eldest patient was 24 months of age. Also, there was no abnormal tension in any hip joint after open reduction and PA.

According to Mc Kay's classification system, an excellent result is painless, stable hip with a negative Trendelenburg test and full range of motion. Clinically, 93.8% of patients were classified as showing an excellent result at the final follow-up in our series. Performing the PA without anterior open reduction enables a smaller anterolateral incision and less extensive anterior dissection (no anterior capsular dissection). We believe that these features may prevent the formation of fibrosis and adhesions around the hip joint. The disadvantage of this combined technique is the use of two separate incisions.

We conclude that satisfactory clinical and radiological results can be achieved with a single-stage Ferguson

medial open reduction and PA after the age of 15 months for the treatment of developmental dysplasia of the hip.

Acknowledgements

Conflicts of interest

There are no conflicts of interest.

References

- Ludloff K. The open reduction of the congenital hip dislocation by an anterior incision. *Am J Orthop Surg* 1913; **10**:438–454.
- Ferguson AB Jr. Primary open reduction of congenital dislocation of the hip using a median adductor approach. *J Bone Joint Surg Am* 1973; **55**:671–689.
- Konigsberg DE, Karol LA, Colby S, O'Brien S. Results of medial open reduction of the hip in infants with developmental dislocation of the hip. *J Pediatr Orthop* 2003; **23**:1–9.
- Mankey MG, Arntz GT, Staheli LT. Open reduction through a medial approach for congenital dislocation of the hip. A critical review of the Ludloff approach in sixty-six hips. *J Bone Joint Surg Am* 1993; **75**:1334–1345.
- Pemberton PA. Pericapsular osteotomy of the ilium for treatment of congenital subluxation and dislocation of the hip. *J Bone Joint Surg Am* 1965; **47**:65–86.
- Wang CW, Wu KW, Wang TM, Huang SC, Kuo KN. Comparison of acetabular anterior coverage after Salter osteotomy and Pemberton acetabuloplasty: a long-term followup. *Clin Orthop Relat Res* 2014; **472**:1001–1009.
- Berkeley ME, Dickson JH, Cain TE, Donovan MM. Surgical therapy for congenital dislocation of the hip in patients who are twelve to thirty-six months old. *J Bone Joint Surg Am* 1984; **66**:412–420.
- Severin E. Contribution to the knowledge of congenital dislocation of the hip joint: late results of closed reduction and arthrographic studies of recent cases. *Acta Chir Scand* 1941; **63** (Suppl):84.
- Tönnis D. *Congenital dysplasia and dislocation of the hip in children and adults*. Berlin: Springer-Verlag; 1987.
- Kalamchi A, MacEwen D. Avascular necrosis following treatment of congenital dislocation of the hip. *J Bone Joint Surg Am* 1980; **62**:876–888.
- Baki C, Sener M, Aydin H, Yildiz M, Saruhan S. Single-stage open reduction through a medial approach and innominate osteotomy in developmental dysplasia of the hip. *J Bone Joint Surg Br* 2005; **87**:380–383.
- Citlak A, Saruhan S, Baki C. Long-term outcome of medial open reduction in developmental dysplasia of hip. *Arch Orthop Trauma Surg* 2013; **133**:1203–1209.
- Okano K, Yamada K, Takahashi K, Enomoto H, Osaki M, Shindo H. Long-term outcome of Ludloff's medial approach for open reduction of developmental dislocation of the hip in relation to the age at operation. *Int Orthop* 2009; **33**:1391–1396.
- Koizumi W, Moriya H, Tsuchiya K, Takeuchi T, Kamegaya M, Akita T. Ludloff's medial approach for open reduction of congenital dislocation of the hip. A 20-year follow-up. *J Bone Joint Surg Br* 1996; **78**:924–929.
- Altay M, Demirkale I, Senturk F, Firat A, Kapicioglu S. Results of medial open reduction of developmental dysplasia of the hip with regard to walking age. *J Pediatr Orthop B* 2013; **22**:36–41.
- Tarassoli P, Gargan MF, Atherton WG, Thomas SR. The medial approach for the treatment of children with developmental dysplasia of the hip. *Bone Joint J* 2014; **96-B**:406–413.
- Hoellwarth JS, Kim YJ, Millis MB, Kasser JR, Zurakowski D, Matheny TH. Medial versus anterior open reduction for developmental hip dislocation in age-matched patients. *J Pediatr Orthop* 2015; **35**:50–56.
- Kiely N, Younis U, Day JB, Meadows TM. The Ferguson medial approach for open reduction of developmental dysplasia of the hip. A clinical and radiological review of 49 hips. *J Bone Joint Surg Br* 2004; **86**:430–433.
- Sener M, Baki C, Aydin H, Yildiz M, Saruhan S. The results of open reduction through a medial approach for developmental dysplasia of the hip in children above 18 months of age. *Acta Orthop Traumatol Turc* 2004; **38**:247–251.
- Salter RB, Dubos JP. The first fifteen years' personal experience with innominate osteotomy in the treatment of congenital dislocation and subluxation of the hip. *Clin Orthop Relat Res* 1974; **98**:72–103.
- Pospischill R, Weninger J, Ganger R, Altenhuber J, Grill F. Does open reduction of the developmental dislocated hip increase the risk of osteonecrosis? *Clin Orthop Relat Res* 2012; **470**:250–260.
- Albinana J, Dolan LA, Spratt KF, Morcuende J, Meyer MD, Weinstein SL. Acetabular dysplasia after treatment for developmental dysplasia of the hip. Implications for secondary procedures. *J Bone Joint Surg Br* 2004; **86**:876–886.
- Haidar RK, Jones RS, Vergrosen DA, Evans GA. Simultaneous open reduction and Salter innominate osteotomy for developmental dysplasia or the hip. *J Bone Joint Surg Br* 1996; **78**:471–476.
- Carsi B, Al-Hallao S, Wahed K, Page J, Clarke NM. Incomplete periacetabular acetabuloplasty. *Acta Orthop* 2014; **85**:66–70.
- Holman J, Carroll KL, Murray KA, Macleod LM, Roach JW. Long-term follow-up of open reduction surgery for developmental dislocation of the hip. *J Pediatr Orthop* 2012; **32**:121–124.
- Sankar WN, Tang EY, Moseley CF. Predictors of the need for femoral shortening osteotomy during open treatment of developmental dislocation of the hip. *J Pediatr Orthop* 2009; **29**:868–871.