

Anterior Tibial Artery Perforator Plus Flaps: Role in Coverage of Posttumor Excision Defects Around the Knee Joint and Upper Leg

Harshvardhan Sahijwani¹, Vikas Warikoo², Abhijeet Ashok Salunke², Jaymin Shah², Preetish Bhavsar³, Rahul Wagh², Subodh Pathak⁴

¹Plastic Surgeon, Divine Plastic and Cosmetic Surgery Centre, Ahemdabad, ²Department of Oncosurgery, Gujarat Cancer Research Institute, Ahemdabad, Gujarat, ³Plastic Surgeon, Lakshmi Hospital, Dombivali, Mumbai, Maharashtra, ⁴Orthopedic Surgeon, Pramukswami Medical College, Anand, Gujarat, India



Corresponding author: Abhijeet Ashok Salunke, MBBS, DNB (Ortho)

Fellow Orthopedic Oncosurgery (NUH Singapore), Consultant Orthopedic Oncosurgeon, Gujarat Cancer Research Institute, Ahemdabad, India

Tel: +091 9726500263; Fax: +91 9726500263

E-mail: drabhijeetsalunke@gmail.com

Received: March 06, 2017, Accepted: May 01, 2017

ABSTRACT

Objective: Posttumor excision defects can be very large, and many do require postoperative radiotherapy. It is therefore important to provide stable and durable wound coverage to provide ability to withstand radiotherapy as well as providing cover to vital structures. **Methods:** Between July 2014 and June 2016, eight females and six male patients with defects around the knee were operated upon using a perforator plus flap from the anterior tibial artery perforator. In all except two patients, the defects were the result of posttumor extirpation, while in the latter, it was due to impending implant exposure following bone tumor excision and tibial prosthesis. A constant perforator at the neck of the fibula was found using hand-held Doppler. The base of the flap was always kept intact. The flap was then transposed toward the defect and inset in a tensionless

manner. **Results:** The average flap dimension was 14 cm × 5.5 cm. The mean follow-up was 11 months (6–20 months). All the flaps survived well except in one patient who developed partial tip necrosis, providing stable coverage of the wound. Two patients developed local recurrence and had to undergo above-knee amputation. **Conclusions:** The planning for the reconstruction of defects following tumor resection is to be done in accordance with a multidisciplinary team approach involving oncosurgeon, reconstructive plastic surgeons, and radiation specialist. The perforator plus flap is an excellent choice in defects around the knee to cover neurovascular structures, bone, or implant.

Key words: Anterior tibia artery, bone tumor, extirpation defect, knee, perforator plus flaps

Access this article online

Quick Response Code:



Website: www.apjon.org

DOI:
10.4103/apjon.apjon_32_17

This is an open access article distributed under the terms of the Creative Commons Attribution-NonCommercial-ShareAlike 3.0 License, which allows others to remix, tweak, and build upon the work non-commercially, as long as the author is credited and the new creations are licensed under the identical terms.

For reprints contact: reprints@medknow.com

Cite this article as: Sahijwani H, Warikoo V, Salunke AA, Shah J, Bhavsar P, Wagh R, *et al.* Anterior tibial artery perforator plus flaps: Role in coverage of posttumor excision defects around the knee joint and upper leg. *Asia Pac J Oncol Nurs* 2017;4:342-7.

Introduction

Reconstruction of posttumour excision defects around the knee joint is a great challenge for surgeons. The defect size is usually very large, and important structures such as popliteal neurovascular bundle, the tibia bone, and implant prosthesis are exposed. In the presence of unperturbed periosteum, split thickness grafts may be applied. However, it is not the optimal treatment because mobile knee joint is vulnerable to graft loss. The requirement of radiotherapy following tumor excision may lead to skin breakdown at the site of skin graft and then cause delayed or nonwound healing.

Before free flaps came into existence, only few reconstructive options were present, such as conventional local flaps and cross-leg flaps, which required immobilization for weeks.^[1] Several muscle or musculocutaneous flaps have been used to repair the soft tissue defects around the knee.^[2-4] However, they are bulky and may lead to varying degrees of functional loss. The random cutaneous and conventional fasciocutaneous flaps though simple and reliable and also provide a durable pliable coverage with a better donor site esthesia and less morbidity are restricted by a limited length: width ratio, along with need of delays and limited mobility and reach.

The delicate relationship between the flap vascularity and the reach in the lower limb was somewhat achieved with the advent of islanded perforator flaps.^[5,6] There is minimal functional compromise and better esthesia of the donor site. However, the biggest drawback is the chance of venous compromise. This is due to the fact that thin-walled veins with lower vessel wall elasticities and intraluminal pressures are more sensitive to the torsional forces than the perforator artery during the flap transfer and inset.^[7,8]

The failure rates of pedicled perforator flaps can be drastically curtailed with the use of the “perforator plus” concept in which the blood supply to a flap from a perforator is augmented by blood supply from the flap base.^[9] This method involves raising of the peninsular fasciocutaneous flaps, thus including and retaining one or more perforators in their base.^[10,11] This provides a dual blood supply through the perforator and the subdermal plexus, as well as it reinforces the venous drainage. The pedicle may be narrowed by back cuts to facilitate the mobility and a tension-free inset.^[11] It has been determined that the perforator plus fasciocutaneous flaps can be safely used in the knee and the upper and middle thirds of the leg.^[12,13] In the current study, we have analyzed the results of anterior tibial artery-based perforator plus flap for coverage of posttumour excision defects around knee joint and upper leg.

Methods

Between July 2014 and June 2016, fourteen patients with defects around the knee and upper one-third leg following treatment of tumor were included in this study. These patients underwent reconstruction with a perforator plus flap coverage based on the anterior tibial artery perforator at the lateral aspect of the knee joint.

The clinical records of these patients were reviewed. The clinical features reviewed were size of the defect, presence of implant or cement and bone exposure, range of movement [ROM] of the affected extremity. The ROM was evaluated both preoperatively and during follow-up period. There were eight females and six males. The mean age was 35 (8–51) years. The study was approved by the ethics committee of Gujarat Cancer Research Institute. Informed written consent was obtained from all patients prior to their enrollment in this study.

Surgical technique

All the patients were operated on under spinal anesthesia. An approximate size of the defect was assessed of the expected deficit of skin cover after considering adequate margins depending on the type and size of the tumor [Figure 1]. The perforator was located on the lateral aspect of the leg using a hand-held Doppler. In the case no. 1, it was an intraoperative decision to do the perforator plus flap after we realized that the gastrocnemius muscle was too small to cover the defect. After the defect is created by the oncosurgeon [Figure 2], the horizontal length of the expected defect was marked in a vertical direction along the length of the flap using the location of the perforator as a fulcrum for flap transposition. Planning in reverse was done in all the cases. Then, we applied the tourniquet without exsanguinating the limb. The fasciocutaneous flap was then raised after marking from distal to proximal until the selected perforator was reached using loupe magnification [Figures 3 and 4]. Marking of perforator plus flap design showing anterior tibial artery perforator located through hand-held Doppler device and elevated flap with perforator [Figures 3 and 4]. Additional perforators encountered during elevation of the flap were ligated. The dissection was done down till the deep fascia which too was incorporated in the flap, and

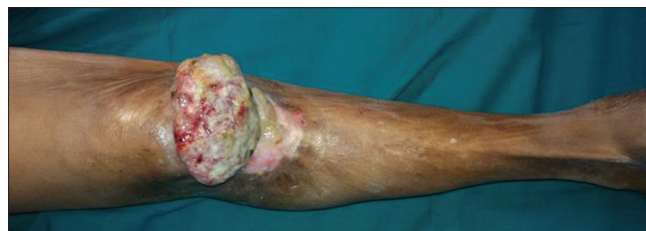

Figure 1: Clinical picture of fungating tumor over right knee joint

the superficial peroneal nerve was always saved, which lay at close proximity. The base of the flap was always kept intact, and the flap was then transposed and inset in a tensionless manner using absorbable braided sutures. The donor site was covered with a split-thickness skin graft (STSG) [Figure 5]. The dimensions of the elevated flap varied from 10 to 18 cm in length and from 4 to 7 cm in width. Postoperatively, the flaps were not subjected to any form of special monitoring, and no anticoagulant pharmacological agents such as aspirin or clopidogrel were used except in case no. 6 wherein dextran 40 was used for 3 days at rate of 20 ml/h since the distal most edge did not bleed as well as in previous cases. In the case no. 5, owing to a very large defect and due to deformity of feet, in addition to the flap, STSG was also done since the periosteum was intact throughout the length of the exposed bone.

Results

The mean size of flap used for coverage of posttumors excision defect was 14×5.5 (range, 10×4 – 18×7) [Table 1]. The mean follow-up was 11 months (6–20 months). Two patients developed local recurrence and had to undergo above-knee amputation.

An 8-year-old female child and a 12-year-old male child with Ewing's sarcoma of tibia with excision of tumor with megaprosthesis had an impending exposure. In ten

patients due to exposed metallic implant or bone cement and exposed tibia in two cases. In one patient, the flap was supplemented with skin graft to cover raw areas.

The flap settled well in all patients and enabled a good wound cover [Figure 6]. The range of movements of the hand was functionally restricted in one patient.

Two patients had local recurrence after 6 months of primary surgery and underwent above-knee amputation. One of the patients had wound infection and was treated with debridement and antibiotics and the infection healed uneventfully. One patient had flap tip necrosis and was treated conservatively [Table 1]. All the flaps survived well except in one patient who developed partial tip necrosis, providing stable coverage of the wound. Knee range of motion exercises was started in all patients after 2 weeks of surgery. The mean flexion of the knee joint was 100° (80° – 120°), and extension was 7° (0° – 20°) [Table 2].

Discussion

Primary flap reconstructions after bone and soft tissue tumor surgery are often performed in for various reasons. Reconstruction methods allow a complete tumor excision with adequate margins. Flap coverage around the knee joint provides vascularized tissue for covering the defect and improves healing. It provides durability to newly introduced coverage as well as ability to bear the breakdown from the

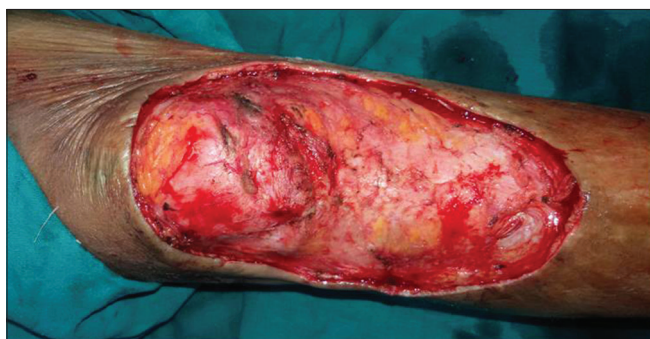

Figure 2: Defect of size 18 cm \times 8 cm following tumor excision

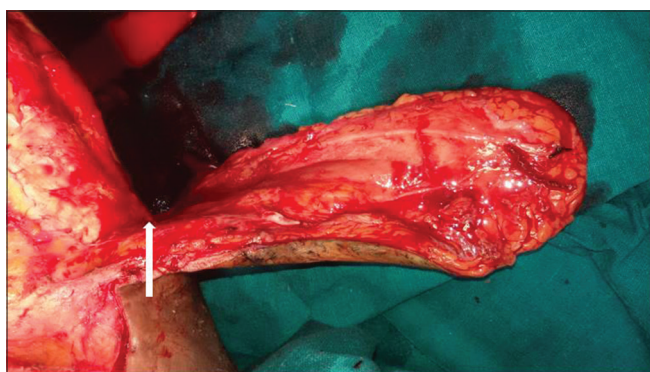


Figure 4: Elevated flap with perforator (white arrow)

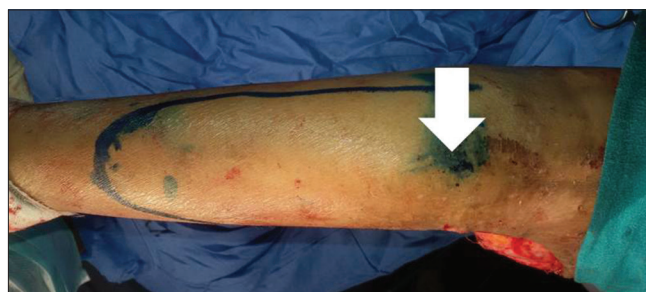

Figure 3: Marking of perforator plus flap design showing anterior tibial artery perforator located through hand-held Doppler device (white arrow)

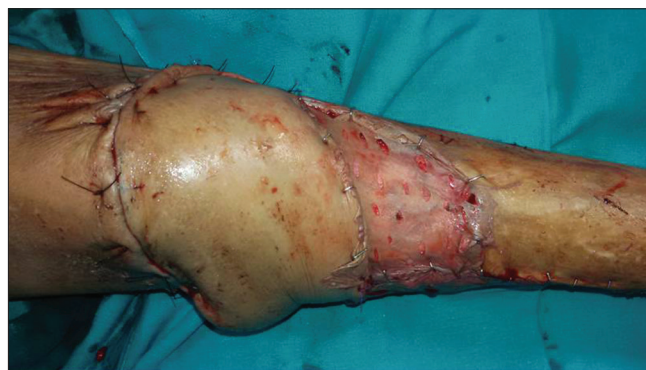

Figure 5: Immediate postoperative picture showing defect coverage with flap and split-thickness skin graft

Table 1: Patient characteristics and flap details

Pt No.	Age	Sex	Pathology	Side	Flap size in cm	Perforator distance from fibular head (in cm)	Post op status of the flaps	Followup in months	Oncologic Outcome
1	8	F	Ewing's sarcoma	Left	11x5	1.6	Survived	18	Alive with amputation
2	51	M	SCC	Right	14x5	2.4	Survived	10	NED
3	12	M	Ewing's sarcoma	Left	10x4	1.5	Survived	20	NED
4	37	F	Spindle cell sarcoma	Left	14x6	2.1	Survived	14	NED
5	41	F	Marjolin's ulcer	Right	18x7	1.9	Survived	16	NED
6	49	F	Osteogenic sarcoma	Right	16x7	2.3	Survived	7	Alive with amputation
7	50	M	SCC	Left	16x6	2.0	Tip necrosis	12	NED
8	19	F	Ewing's sarcoma	Left	13x5	1.9	Survived	10	NED
9	22	M	Ewing's sarcoma	Right	15x6	2.2	Survived	11	NED
10	47	M	Marjolin's ulcer	Left	16x6	1.9	Survived	8	NED
11	10	F	Spindle cell sarcoma	Right	11x5	1.9	Survived	9	NED
12	41	F	SCC	Right	17x7	2.0	Survived	7	NED
13	58	F	Marjolin's ulcer	Left	15x6	2.1	Survived	6	NED
14	39	M	Spindle cell sarcoma	Left	14x5	2.3	Survived	6	NED

Table 2: Functional assessment of the patients following surgery

Sr. No.	Knee joint Flexion range in degrees	Knee joint extension range in degrees	Pain score
1	100	20	4
2	135	0	0
3	120	10	2
4	110	10	2
5	110	0	1
6	120	0	1
7	90	20	3
8	135	0	0
9	135	0	1
10	100	10	0
11	90	20	5
12	100	10	2
13	100	20	1
14	110	0	1

effects of radiation. Flap reconstruction helps to protect implants and megaprosthesis and avoid deep infection. The soft tissue reconstruction allows early mobilization and returns to activities of daily living. The team of oncosurgeon and oncoplastic surgeon and trained oncology nurse is required at a dedicated cancer center to achieve good oncologic results with functional outcomes.

The role of nursing in oncology practice is enormous, and it achieves very significant importance in the surgical field. The oncology trained nursing staffs help in achieving a wide exposure of surgical area and good blood-free field. To prevent spasm of perforator, constant irrigation of saline and lignocaine is achieved with help of nursing personnel. The postoperative management of flap and its contour is checked round the clock with help of the assistance of staff personnel and play an important role in constant monitoring of the flap.

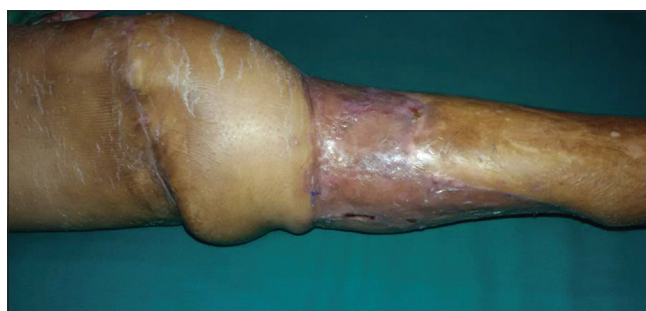

Figure 6: Clinical picture showing healed flap with full knee extension

Musculocutaneous and fasciocutaneous flaps, i.e., gastrocnemius flap, anterior tibial artery perforator are used for coverage of defects around knee joint.^[14] Fasciocutaneous flaps are having better utility because no muscle is sacrificed, and the long-term results are equivalent to musculocutaneous flap coverage. Free flaps and pedicled flaps provide excellent results with the cost of sacrifice of a major vessel.^[15] Locoregional flaps have a limited arc of rotation, and free flaps are labor intensive and time consuming, and microvascular failure leads to total flap loss.^[15]

According to Taylor and Palmer's^[16] concept of the angiosome, almost all the tissues of an angiosome can be harvested on one adequate perforator. Such perforators originate from one of the main axial vessels and course through a muscle or septa, pierce the fascia, and ramify in the suprafascial level within subcutaneous fat. Perforator-based flaps have the advantage of having reliable perfusion, shorter time of surgery, and no requirement of sacrifice of any important structure.

The perforator plus flap concept improves flap vascularity and venous return by maintaining the cutaneous pedicle.^[15,17-19] These flaps are of great value because the located perforator may not be accompanied

by a vein in all cases.^[11] By extending the dissection up to the level of the perforator, a wider limit of the flap can be achieved. The area in the upper lateral part of the leg is supplied by the anterior tibial artery and its recurrent branch whereas the peroneal artery takes over as it goes down the leg.^[18] We used this principle to elevate this flap in which a perforator from the anterior tibial recurrent artery just below the fibular head was used as the chief supply to our flaps.

Our experience shows that reconstructive plastic surgery can play an integral role in the multimodal treatment concept including radiation and chemotherapy. Proper flap selection is crucial in sarcoma defect reconstruction. About 12% complications following free-flap reconstruction have been described in literature.^[20-22] In the current study, the number of early complications was 7%, and but only 14% of the patients required revision surgery. The benefits of using this flap include the provision of a tissue possessing a good color and texture match, which allows for optimal contouring of the knee joint and causes minimal donor site morbidity.^[9,19] The defect created by raising the flap requires coverage with a STSG only over a well-vascularized bed of muscles. Operating times are less, and this flap is easy to teach and has minimal morbidity so far in our case series. Close attention should be paid to the superficial peroneal nerve which, because of its proximity to the flap, may be injured during the dissection, although no such injury occurred in our series.

Chances of local recurrence are a comparatively higher following flap reconstruction in the setting of advanced and high-grade sarcomas.^[19,22] In the current study, wide excision was achieved in all cases, and local recurrence was observed in 14%. López *et al.* results of primary flap reconstruction of tissue defects after sarcoma surgery showed recurrence rate of 19%.^[22]

The limitations of the current study are the retrospective nature of the research and the heterogeneity of the study population. Furthermore, tumor type and chemotherapy regime were different in the tumor subgroups.

Conclusion

Primary flap reconstruction plays major role in the management of tumor resection. The planning for the reconstruction of defects following tumor resection is to be done in accordance with a multidisciplinary team approach involving oncologist, reconstructive plastic surgeons, and radiation specialist. The perforator plus flap is an excellent choice in defects around the knee to cover neurovascular structures, bone, or implant.

Financial support and sponsorship

Nil.

Conflicts of interest

There are no conflicts of interest.

References

- Jayes PH. Cross-leg flaps; a review of 60 cases. *Br J Plast Surg* 1950;3:1-5.
- Cormack GC, Lamberty BG. The blood supply of thigh skin. *Plast Reconstr Surg* 1985;75:342-54.
- Laitung JK. The lower posterolateral thigh flap. *Br J Plast Surg* 1989;42:133-9.
- Maruyama Y, Iwahira Y. Popliteo-posterior thigh fasciocutaneous island flap for closure around the knee. *Br J Plast Surg* 1989;42:140-3.
- Koshima I, Soeda S. Inferior epigastric artery skin flaps without rectus abdominis muscle. *Br J Plast Surg* 1989;42:645-8.
- Koshima I, Moriguchi T, Soeda S, Kawata S, Ohta S, Ikeda A. The gluteal perforator-based flap for repair of sacral pressure sores. *Plast Reconstr Surg* 1993;91:678-83.
- Ghali S, Bowman N, Khan U. The distal medial perforators of the lower leg and their accompanying veins. *Br J Plast Surg* 2005;58:1086-9.
- Topalan M, Bilgin SS, Ip WY, Chow SP. Effects of torsion on microarterial anastomosis patency. *Microsurgery* 2003;23:55-9.
- Mehrotra S. Perforator-plus flaps: A new concept in traditional flap design. *Plast Reconstr Surg* 2007;119:590-8.
- Sharma RK, Mehrotra S, Nanda V. The perforator "plus" flap: A simple nomenclature for locoregional perforator-based flaps. *Plast Reconstr Surg* 2005;116:1838-9.
- Mehrotra S. Perforator plus flaps: Optimizing results while preserving function and esthesia. *Indian J Plast Surg* 2010;43:141-8.
- Wong CH, Tan BK. Perforator-sparing transposition flaps for lower limb defects: Anatomic study and clinical application. *Ann Plast Surg* 2007;58:614-21.
- Wong CH, Tan BK. Perforator-plus flaps or perforator-sparing flaps: Different names, same concept. *Plast Reconstr Surg* 2007;120:1746-7.
- Chowdri NA, Darzi MA. Z-lengthening and gastrocnemius muscle flap in the management of severe postburn flexion contractures of the knee. *J Trauma* 1998;45:127-32.
- Adhikari S, Bandyopadhyay T, Saha JK. Anterior tibial artery perforator plus flaps for reconstruction of post-burn flexion contractures of the knee joint. *Ann Burns Fire Disasters* 2012;25:86-91.
- Taylor GI, Palmer JH. The vascular territories (angiosomes) of the body: Experimental study and clinical applications. *Br J Plast Surg* 1987;40:113-41.
- Taylor GI, Pan WR. Angiosomes of the leg: Anatomic study and clinical implications. *Plast Reconstr Surg* 1998;102:599-616.
- Geddes CR, Tang M, Yang D. Anatomy of the integument of the lower extremity. In: Blondeel PN, Morris SF, Hallock GG, *et al.*, editors. *Perforator Flaps: Anatomy, Technique and Clinical Applications*. St. Louis, MO: QMP; 2006. p. 541-78.
- Liu CY, Yen CC, Chen WM. Soft tissue sarcoma of extremities: The prognostic significance of adequate surgical margins in primary operation and reoperation after recurrence. *Ann Surg Oncol*. 2010; 17:2102-11.
- Cordeiro PG, Neves RI, Hidalgo DA. The role of free tissue

- transfer following oncologic resection in the lower extremity. *Ann Plast Surg* 1994;33:9-16.
21. Pisters PW, Leung DH, Woodruff J, Shi W, Brennan MF. Analysis of prognostic factors in 1,041 patients with localized soft tissue sarcomas of the extremities. *J Clin Oncol* 1996;14:1679-89.
22. López JF, Hietanen KE, Kaartinen IS, Kääriäinen MT, Pakarinen TK, Laitinen M, *et al.* Primary flap reconstruction of tissue defects after sarcoma surgery enables curative treatment with acceptable functional results: A 7-year review. *BMC Surg* 2015;15:71.