

Appraising the spectrum of firework trauma and the related laws during Diwali in North India

Ramesh Venkatesh, Prachi Gurav, Shailja Tibrewal, Manisha Agarwal, Suneeta Dubey, Umang Mathur, Suma Ganesh, Sima Das

Purpose: To evaluate the epidemiological characteristics and outcomes of ocular injuries resulting from the use of firecrackers during the Diwali festival in all age groups. **Materials and Methods:** A single-center, retrospective, hospital-based case series presenting with ocular trauma consequent to fireworks usage in a tertiary eye care center in North India during the 5 days of Diwali festival from 2011 to 2015 was conducted. **Results:** A total of 53 eyes of 45 patients were included in the study, out of which the vast majority (39/87%) were males. The mean age was 20.55 years. Almost an equal number of bystanders (25/55.5%) were affected as compared to people handling the fireworks (20/44.44%). Five (9.43%) eyes had open-globe injury, whereas 48 (90.56%) eyes had closed-globe injury. Eighteen (33.96%) eyes underwent surgical intervention. Thirty-three (62.26%) eyes had final vision >20/200 with eight (15.09%) eyes being vision <3/60 in the affected eye. **Conclusion:** Firework-related ocular trauma can lead to serious visual impairment. Mandatory legislative laws pertaining to the manufacture, sale, and use of fireworks and creating public awareness can reduce the incidence of this preventable cause of blindness in the society. Initiating new policies for retailers involved in sale of these firecrackers can also bring in decrease of such morbidities.

Key words: Diwali, eye injuries, fireworks, prevention, trauma

Conventionally, fireworks are a part of festivals in India especially Diwali. As it is popularly called “festival of lights” bringing mirth to Indian minds, it does not take long to turn this joyful celebration into a humanmade disaster due to sheer negligence of rules and lack of awareness. Eighteen percent of the ocular injuries can be attributed to the use of firecrackers.^[1] The purpose of this study is to assess the ocular morbidities attributable to fireworks and their final visual outcome during the festive days of Diwali in the past 5 years. This study adds valuable information related to firework-related eye injuries and creates awareness among the people regarding the dangers of fireworks.

Materials and Methods

This is a retrospective, observational, consecutive case series conducted in a tertiary eye care hospital in North India. The study was approved by the Institutional Review Board. All patients with history of fireworks-related injuries, who attended the emergency eye care services and outpatient services during the 5 days of the Diwali festival - 2 days before Diwali, day of Diwali, and 2 days after Diwali - for 5 consecutive years from 2011 to 2015, were included in this study. Maximum firecrackers are burst by the people during these 5 days of the festival. All patients underwent comprehensive ophthalmic examination. All relevant data related to age, sex, laterality, type of firework, whether user or bystander, baseline visual acuity (VA), details of injuries, diagnosis, whether requiring surgical or conservative management, and final best-corrected

Department of Retina and Vitreous, Dr. Shroff Charity Eye Hospital, New Delhi, India

Correspondence to: Dr. Ramesh Venkatesh, Dr. Shroff Charity Eye Hospital, 5027, Kedarnath Road, Daryaganj, New Delhi - 110 002, India. E-mail: vramesh80@yahoo.com

Manuscript received: 04.07.16; Revision accepted: 28.12.16

Access this article online

Website:

www.ijo.in

DOI:

10.4103/ijo.IJO_527_16

Quick Response Code:



VA (BCVA) at the last follow-up were recorded. Ultrasound B-scan and computed tomogram scan were done if needed. Patients with lid tears, corneal tears, scleral tears, and intraocular foreign body (IOFB) were admitted and were given immediate medical and surgical attention, while those with nonpenetrating injuries were treated on an outpatient basis. The immediate management of ocular burns comprised thorough eye wash with normal saline, removal of dust, soot particles and debris, and finally ruling out open-globe injury. The corneal status and presence of limbal ischemia were assessed. Depending on the severity of ocular injury, patients were started on copious lubricants, topical antibiotics, and steroid combination eye drops and cycloplegics.

Results

A total of 53 eyes of 45 patients were seen during the 5 consecutive days of Diwali festival from 2011 to 2015. There were 39 (87%) males and 6 (13%) females. The mean age of presentation was 20.55 years (range: 3–53 years). Thirty-four patients were in the age range of 0–30 years [Fig. 1], of which 13 were children. The right eye was affected in 30 eyes, while in 23, the left eye was affected. Eight patients had involvement of both eyes. The characteristics of injury at presentation are summarized in Table 1. Among the patients who could

This is an open access article distributed under the terms of the Creative Commons Attribution-NonCommercial-ShareAlike 3.0 License, which allows others to remix, tweak, and build upon the work non-commercially, as long as the author is credited and the new creations are licensed under the identical terms.

For reprints contact: reprints@medknow.com

Cite this article as: Venkatesh R, Gurav P, Tibrewal S, Agarwal M, Dubey S, Mathur U, *et al.* Appraising the spectrum of firework trauma and the related laws during Diwali in North India. *Indian J Ophthalmol* 2017;65:140-3.

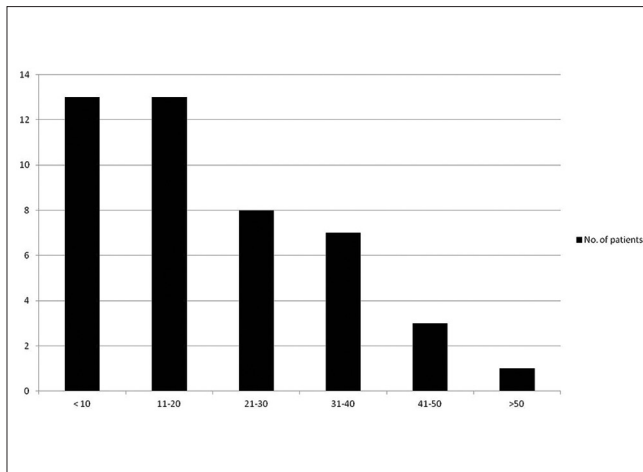


Figure 1: Age distribution of patients presenting with fireworks-related ocular injuries

recall the type of the firecracker causing injury, bombs were the most common. Twenty-five patients were bystanders and twenty patients ignited the fireworks themselves. The severity of ocular damage was more among the patients who ignited the fireworks themselves than the bystanders [Table 1]. Two (4.44%) patients had only periocular injury. Five eyes (9.43%) had an open-globe injury while 48 (90.56%) had closed-globe injury. Six patients had undergone primary treatment elsewhere and were referred to our hospital for further management. One patient with corneal epithelial defect required amniotic membrane transplant and glue with bandage contact lens. Eighteen (33.96%) eyes underwent surgical management at our institute, 34 (64.15%) eyes were managed conservatively, and only 1 (1.88%) eye was advised primary enucleation.

Out of the 18 surgically managed eyes, three eyes underwent corneal tear repair, one eye underwent scleral tear repair, cataract extraction with posterior chamber intraocular lens implantation, and lensectomy in one eye each. Pars plana vitrectomy for the management of vitreous hemorrhage, retinal detachment, and IOFB removal was done in 5, 2, and 1 eyes, respectively. Scleral fixated intraocular lens implantation was advised to the patient who underwent lensectomy.

Twenty-two eyes had BCVA of 6/6 at final follow-up, 11 eyes had between 6/60 and 6/9, <6/60 to perception of light (PL+) in 7 eyes, and no PL in 1 eye [Table 2]. Three eyes developed irreparable retinal detachment. Five eyes eventually developed phthisis bulbi, of which three eyes underwent secondary enucleation with ball implant and ocular prosthesis. VA could not be assessed in 12 injured eyes, of which three patients (6 eyes) were of the pediatric age group. Three patients (6 eyes) were lost to follow-up.

Discussion

“Diwali or Deepawali” is described as a festival to celebrate Lord Rama’s return from exile. This 5-day festival is also called the “festival of lights,” where people light their homes with “lamps” and celebrate with firecrackers. This gesture brings out a feeling of joy and happiness and an expression of gratitude to the Lord.

Table 1: Characteristics of ocular injury

Site of injury	Total n (%), bystanders/direct injury (number of cases)
Lid and adnexa	
Lid burns	9 (17), 6/3
Lid edema	7 (13), 5/2
Charred eyelashes	8 (15), 6/2
Face burns	2 (4), 0/2
Anterior segment	
Conjunctival burn	2 (4), 1/1
Conjunctival chemosis	1 (2), 0/1
Conjunctival congestion	6 (11), 5/1
Conjunctival tear	3 (6), 3/0
Corneal epithelial defect	18 (34), 12/6
Corneal SPKs	6 (11), 4/2
Corneal edema	6 (11), 4/2
Corneal foreign body	13 (25), 10/3
Limbal ischemia	1 (2), 0/1
Scleral tear	1 (2), 0/1
Iridodialysis	3 (6), 1/2
Uveal tissue prolapse	1 (2), 0/1
Traumatic mydriasis	1 (2), 1/0
Anterior chamber cells	1 (2), 1/0
Hyphema	10 (19), 7/3
Angle recession	1 (2), 1/0
Cataract	1 (2), 0/1
Lens subluxation	1 (2), 0/1
Posterior segment	
Vitreous hemorrhage	5 (9), 2/3
Traumatic optic neuropathy	1 (2), 0/1
Berlins edema	1 (2), 1/0
Traumatic macular hole	2 (4), 1/1
Choroidal detachment	2 (4), 0/2
Retinal detachment	2 (4), 0/2
Choroidal rupture	2 (4), 0/2
Intraocular foreign body	1 (2), 1/0

SPKs: Superficial punctate keratitis

Table 2: Visual outcome following ocular firecracker injury

VA categories	Initial VA (number of eyes)	Final VA (number of eyes)
6/6	8	22
6/9-6/18	16	11
6/24-6/60	4	0
5/60-3/60	2	0
<3/60 to PL+	13	7
No PL	1	1
Not recorded	9	12

VA: Visual acuity, PL: Perception of light

Approximately Rs. 1000 crores of firecrackers are burnt during the Diwali season. The firecracker industry gives livelihood to over 0.3 million people directly and indirect

employment to about 1 million people. Sound and dust pollution and firework-related burn injuries are the most common problems related to the use of firecrackers.^[2] Horrifying industrial accidents arising from the manufacture of fireworks have also been reported. Ocular injuries constitute about 20% of firecracker injuries.^[1,3]

Our study was a hospital-based, single-center, retrospective case series of firecracker injuries documented over a 5-day long period during Diwali over the past 5 years. Our hospital is a tertiary eye care hospital located in the central district of the state of New Delhi. We cater our services to a large population of Northern and Central India including the adjoining states of Haryana, Rajasthan, Uttar Pradesh, and Punjab.

In our study, the age range was 3–53 years with mean age of 20.55 years. Among the 45 patients, the majority (39) were males, consistent with findings from previous studies,^[4,5] probably reflecting the males to be more adventurous and aggressive. More than half of the injured were innocent bystanders. A similar study was conducted in a multispecialty hospital located in the Vellore district, Tamil Nadu, by John *et al.*,^[6] which included patients <18 years during the 3 days of Diwali over the past 5 years. Eighty-four children presented with firework-related ocular injuries during the study period, of which 44% required hospitalization. The prevalence of unilateral blindness in children due to fireworks was 8%. In our study, 53 eyes of 45 patients presented with firework-related eye injuries. Twenty-six patients were below the age of 20 years. Eighteen (33.96%) eyes needed surgical intervention. We included patients of all age groups and all cases who presented to our hospital during the 5 days of Diwali in the past 5 years. The possible reasons for the lesser incidence of firework-related injuries in our study were as follows: (1) Our hospital is a tertiary eye care center where only cases related to eye pathologies are referred. (2) Our hospital is surrounded by Muslim-dominated population who do not celebrate the Hindu festival of Diwali. (3) The urban location of our hospital may be one of the reasons for the fewer cases being reported. There are multiple tertiary referral centers in the city that are capable of managing ocular trauma-related cases. (4) More firecracker manufacturing industries are located in South India; increased risk of fireworks-related trauma. (5) Better awareness regarding safety and legislation related to fireworks among the urban population.

In our study, only one eye (1.88%) with ocular injuries did not have even PL while seven eyes (13.2%) had vision worse than 3/60. Three eyes developed irreparable retinal detachment. Five eyes had phthisis bulbi – three eyes following irreparable retinal detachment, one eye following severe ocular hypotony, and one eye following a failed retinal detachment surgery. Three eyes underwent secondary enucleation with ball implant and ocular prosthesis. Similarly, in the study by John *et al.*, three children (5.1%) with ocular injuries did not have even PL while 10 (11.9%) children had vision worse than 3/60 in the injured eye. This clearly demonstrates the extent of ocular morbidity and visual loss due to firecracker injuries. In our study, unaware bystanders accounted for 50% of the cases. This is similar to that reported by Patel and Mukherjee.^[7] Serious ocular injuries occur due to the sudden appearance of unpredictable firecrackers before a person can deploy any defense mechanism. The most common types of firecracker causing injury were bombs

as reported by other Indian studies. High-velocity fireworks such as rockets and bombs are more frequently associated with facial lacerations, IOFB, endophthalmitis, and subsequently, poorer visual outcome.^[8] Sparklers are considered to be safe and less dangerous.

In the current study, closed-globe injuries accounted for 64.15% of all the injuries. A study from China documenting fireworks-related injuries during the spring festival have reported a higher preponderance of open-globe injuries.^[9] In our study, corneal abrasions, corneal foreign body, and hyphema were the most common findings involving the anterior segment, while the most common posterior segment finding was vitreous hemorrhage. Unfortunately, fireworks-related ocular trauma can be vision-threatening and can cause permanent facial disfigurement. Eight out of 53 (15%) eyes had a poor vision <3/60.

New Delhi is one of the most polluted cities of the world. The Central Pollution Control Board estimates that 95% of firecrackers violate noise and pollution norms. In India, the manufacture, sale, and use of firecrackers generating noise levels exceeding 125 dB or 145 dB are prohibited. The Supreme Court has banned setting off firecrackers between 10 p.m. and 6 a.m. during festival seasons.^[10] However, in India, laws regarding displays and celebrations involving firecrackers and those regulating bursting of firecrackers by individual members of the public are virtually absent. Deregulating the sale of fireworks can cause increased burden of firework related morbidity as seen in studies from Northern Ireland and South Africa. Chan *et al.* reported tripling of ocular injuries after the removal of a ban on fireworks in 1996 in Ireland.^[11] This emphasizes the need for stricter rules on the display of fireworks. Kuhn *et al.*^[12] showed a reduced incidence of firework related injuries, following the strict enforcement of fireworks ban at private places.

The limitation of our study was the retrospective method of capturing data and inclusion of cases that got injured only during the 5 days around Diwali. This would have resulted in missing out additional cases of firework-related eye trauma and underestimating the actual magnitude of this vision-threatening problem. Many more nationwide studies are needed to reflect the exact incidence of such injuries.

A significant percentage of patients end up losing their vision due to firework-related eye injuries. Immediate measures such as prohibiting the manufacture and sale of dangerous fireworks such as rockets and those which produce loud noise are required in the reducing significant ocular morbidity and noise pollution. Public awareness about the possible dangers, prophylactic measures, and expert primary ophthalmic care of the injured are the most realistic options available at present. Firework displays at public places by professionals should be encouraged during Diwali and other major celebrations.

Conclusion

Firework-related eye injuries are an important cause of preventable blindness, especially in the younger economically productive population. Ocular trauma from firecrackers when serious can lead to blindness, facial burns, and permanent disfigurement. In a country like India, festivals have their own social, cultural, and economic significance. With the concept of

cracker-free festival not working, it is better to have safe-cracker campaign. A combined approach of creating public awareness and strong legislation is required to regulate the manufacture, sale, and use of consumer fireworks to reduce this preventable cause of ocular morbidity.

Acknowledgments

We acknowledge Ms. Arti Saini and her team for providing the medical records for collecting information for the study.

Financial support and sponsorship

Nil.

Conflicts of interest

There are no conflicts of interest.

References

1. US Consumer Product Safety Commission. Estimated Firework Trauma. National Electronic Injury Surveillance System. Available from: <http://www.cpsc.gov/library/neiss.html>. [Last accessed on 2009 Jul 03].
2. Barman SC, Singh R, Negi MP, Bhargava SK. Ambient air quality of Lucknow City (India) during use of fireworks on Diwali Festival. *Environ Monit Assess* 2008;137:495-504.
3. Witsaman RJ, Comstock RD, Smith GA. Pediatric fireworks-related injuries in the United States: 1990-2003. *Pediatrics* 2006;118:296-303.
4. Toride A, Toshida H, Matsui A, Matsuzaki Y, Honda R, Ohta T, *et al.* Visual outcome after emergency surgery for open globe eye injury in Japan. *Clin Ophthalmol* 2016;10:1731-6.
5. Rishi E, Rishi P, Koundanya VV, Sahu C, Roy R, Bhende PS. Post-traumatic endophthalmitis in 143 eyes of children and adolescents from India. *Eye (Lond)* 2016;30:615-20.
6. John D, Philip SS, Mittal R, John SS, Paul P. Spectrum of ocular firework injuries in children: A 5-year retrospective study during a festive season in Southern India. *Indian J Ophthalmol* 2015;63:843-6.
7. Patel R, Mukherjee B. Crash and Burn: Ocular Injuries due to Fireworks. *Semin Ophthalmol* 2016;31:243-8.
8. Singh DV, Sharma YR, Azad RV. Visual outcome after fireworks injuries. *J Trauma* 2005;59:109-11.
9. Jing Y, Yi-Qiao X, Yan-Ning Y, Ming A, An-Huai Y, Lian-Hong Z. Clinical analysis of firework-related ocular injuries during Spring Festival 2009. *Graefes Arch Clin Exp Ophthalmol* 2010;248:333-8.
10. Judgment Implementation of the Laws for Restricting Use of Loudspeakers and High Volume Producing Sound Systems. Available from: <http://www.indiankanoon.org/doc/1709298/>. [Last accessed on 2016 Mar 09].
11. Chan WC, Knox FA, McGinnity FG, Sharkey JA. Serious eye and adnexal injuries from fireworks in Northern Ireland before and after lifting of the firework ban – An ophthalmology unit's experience. *Int Ophthalmol* 2004;25:167-9.
12. Kuhn FC, Morris RC, Witherspoon DC, Mann L, Mester V, Módis L, *et al.* Serious fireworks-related eye injuries. *Ophthalmic Epidemiol* 2000;7:139-48.