

Splendore–Hoepli phenomenon

Splendore–Hoepli phenomenon (asteroid bodies) is characterized by microorganisms (fungi, bacteria and parasites) or biologically inert substances surrounded by radiating intensely eosinophilic material. This morphologically unique reaction was first described in sporotrichosis by Splendore and in schistosomiasis by Hoepli.^[1] The eosinophilic material seen in Splendore–Hoepli reaction has been described to be due to deposition of antigen–antibody complexes and debris from the host inflammatory cells.^[2,3] Microscopically, Splendore–Hoepli reaction appears as strongly eosinophilic amorphous material with radiating star-like or club-shaped-like configurations [Figure 1] surrounding or adjacent to the causative agent.^[3,4]

It is often accompanied by inflammatory reaction rich in eosinophils, histiocytes, epithelioid cells and giant cells [Figure 2]. Occasionally, this reaction is seen in the midst of wide areas of degeneration and necrosis. In fungal infections, the reaction is demonstrated as eosinophilic cuff surrounding the hyphae [Figure 3] with a radius of up to 20 mm.^[5] Sometimes, it is even seen without any association to identifiable causative agent. In such cases, the reaction illustrates as granulomas with a necrotic eosinophilic center surrounded by a ring of epithelioid cells and giant cells.^[3,6]

The fungal infections which often demonstrate this phenomenon include sporotrichosis, pityrosporum folliculitis, zygomycosis, candidiasis, aspergillosis and blastomycosis. It is also seen in bacterial infections such as

botryomycosis, nocardiosis and actinomycosis, and parasitic conditions include orbital pythiosis, strongyloidiasis, schistosomiasis and cutaneous larva migrans. In addition, noninfective pathologies such as hypereosinophilic syndrome and allergic conjunctival granulomas have been shown to demonstrate this phenomenon occasionally.

The exact nature of the Splendore–Hoepli reaction is not completely known. However, it has been thought to represent deposition of antigen–antibody complexes and debris from host inflammatory cells.^[3] Alternatively, they may represent glycoproteins, lipid and calcium derived from host leukocytes.^[7] Further studies exploring the mechanism of this phenomenon are needed for the detailed portrayal of this reaction.

Differential diagnosis includes flame figures in Well's syndrome, actinomycotic sulfur granules, asteroid bodies in sarcoidosis, tophaceous lesions of gout, perivascular fibrin deposition and keratin granuloma.^[3] Flame figures are degranulated eosinophils that form aggregates of granular material which are surrounded by collagen and can also be seen in insect bites and drug eruption.^[7,8] The central branching filaments or diphtheroid forms are not visible in Splendore–Hoepli reaction and hence this absence assist to make a distinction from true actinomycotic sulfur granules.^[3] Asteroid bodies are eosinophilic stellate inclusions which are usually seen within the giant cells present in sarcoid granulomas and rarely in other granulomas.^[3] Gout granules appear as deposits of

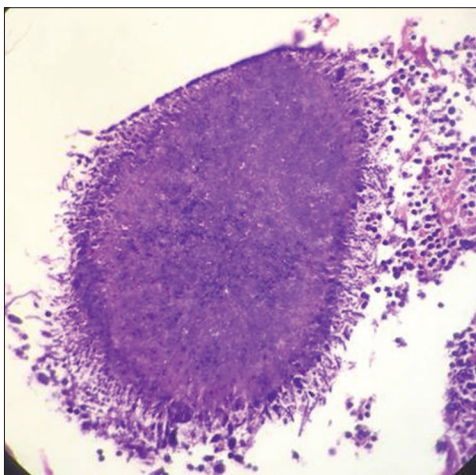


Figure 1: Histological features of Splendore–Hoepli phenomenon appearing as strongly eosinophilic amorphous material with star-like (asteroid) configuration

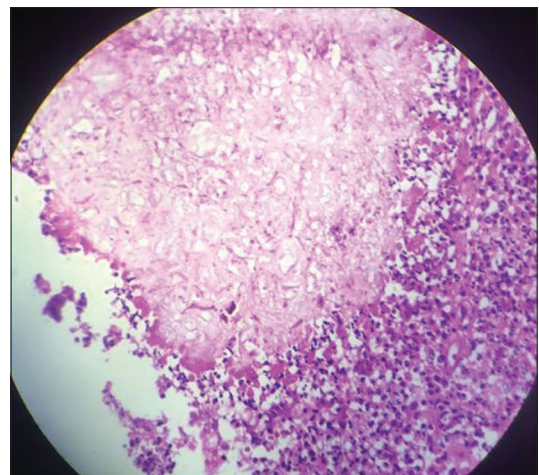


Figure 2: Splendore–Hoepli phenomenon amid granulomatous reaction composed of histiocytes and inflammatory cells and occasional giant cells



Figure 3: Hand-drawn illustration of the mechanism of Splendore–Hoepli phenomenon representing fungal hyphae surrounded deposition of antigen–antibody complexes, glycoprotein and debris from host inflammatory cells

amorphous material of varied sizes with parallel clefts and often these crystals have a brownish hue and are double refractile in polarized light.^[3]

Prompt identification of this reaction can play a significant role in understanding the underlying pathology when the histological presentation is not classic and overlapping conditions can otherwise hinder the diagnosis.

Financial support and sponsorship

Nil.

Conflicts of interest

There are no conflicts of interest.

Divya Gopinath

Department of Oral Rehabilitation, Faculty of Dentistry, University of Hong Kong, HK, China. E-mail: drdivyakmenon@gmail.com

REFERENCES

1. Kwangsukstith C, Vanittanakom N, Khanjanasthiti P, Uthammachai C. Cutaneous sporotrichosis in Thailand: First reported case. *Mycoses* 1990;33:513-7.
2. Liber AF, Choi HS. Splendore-Hoepli phenomenon about silk sutures in tissue. *Arch Pathol* 1973;95:217-20.
3. Hussein MR. Mucocutaneous Splendore-Hoepli phenomenon. *J Cutan Pathol* 2008;35:979-88.
4. Smith JH, Von Lichtenberg F. The Hoepli phenomenon in schistosomiasis. II. Histochemistry. *Am J Pathol* 1967;50:993-1007.
5. Miller RI, Campbell RS. The comparative pathology of equine cutaneous phycomycosis. *Vet Pathol* 1984;21:325-32.
6. Orhan D, Kiratli H, Kocabeyoglu S. Conjunctival Splendore-Hoepli phenomenon in a 3-year-old child. *Pediatr Dev Pathol* 2006;9:388-90.
7. Bhagavan BS, Ruffier J, Shinn B. Pseudoactinomycotic radiate granules in the lower female genital tract: Relationship to the Splendore-Hoepli phenomenon. *Hum Pathol* 1982;13:898-904.
8. Clinicopathologic conference: Systemic blastomycosis involving genitourinary tract and skin. *J Tenn Med Assoc* 1973;66:1141-2.

This is an open access journal, and articles are distributed under the terms of the Creative Commons Attribution-NonCommercial-ShareAlike 4.0 License, which allows others to remix, tweak, and build upon the work non-commercially, as long as appropriate credit is given and the new creations are licensed under the identical terms.

For reprints contact: reprints@medknow.com

Access this article online	
Quick Response Code:	Website: www.jomfp.in
	DOI: 10.4103/jomfp.JOMFP_79_18

How to cite this article: Gopinath D. Splendore–Hoepli phenomenon. *J Oral Maxillofac Pathol* 2018;22:161-2.