



Since January 2020 Elsevier has created a COVID-19 resource centre with free information in English and Mandarin on the novel coronavirus COVID-19. The COVID-19 resource centre is hosted on Elsevier Connect, the company's public news and information website.

Elsevier hereby grants permission to make all its COVID-19-related research that is available on the COVID-19 resource centre - including this research content - immediately available in PubMed Central and other publicly funded repositories, such as the WHO COVID database with rights for unrestricted research re-use and analyses in any form or by any means with acknowledgement of the original source. These permissions are granted for free by Elsevier for as long as the COVID-19 resource centre remains active.

Clinical Features and Management of COVID-19–Associated Hypercoagulability



Gianluca Massaro, MD^a, Dalgisio Lecis, MD^a, Eugenio Martuscelli, MD^{a,b}, Gaetano Chiricolo, MD^{a,b,*}, Giuseppe Massimo Sangiorgi, MD^{a,b}

KEYWORDS

- COVID-19 coagulopathy • Hypercoagulability • Venous thromboembolism • Arterial thrombosis
- Antithrombotic therapy

KEY POINTS

- COVID-19 is associated with blood coagulation changes leading to a prothrombotic state.
- Thrombotic complications affect more the venous than the arterial district.
- The incidence of thrombosis increases in more severe forms of the disease and is associated with high mortality.
- Management of hypercoagulability in COVID-19 is based on preventive measures in patients at risk or the treatment of manifest thrombotic complications.
- Anticoagulation is the most widely used therapy for the prevention and treatment of thrombosis associated with SARS-CoV-2 infection. Numerous trials are ongoing to define the best therapeutic strategy in the different clinical presentations of the disease.

INTRODUCTION

Coronavirus disease 2019 (COVID-19) is a viral illness caused by the severe acute respiratory syndrome coronavirus 2 (SARS-CoV-2). COVID-19 carries several important cardiovascular implications.^{1,2} Since this pandemic disease broke out, it has been observed an increasing occurrence of thromboembolic events in patients without a history of cardiovascular disease.³ The progressive acquisition of knowledge on the pathogenetic effects of SARS-CoV-2 infection has found a prominent role of the venous and arterial vascular system in the disease. Accumulated evidence has shown that coagulopathy is frequently observed in COVID-19 patients, especially in those with critical illness.⁴ Han and colleagues⁵ reported increased D-dimer values and fibrin/fibrinogen degradation products and reduced prothrombin

time (PT)-activity in patients with COVID-19. The increase in D-dimer is particularly marked in severe patients and can be used in patient triaging and disease monitoring. SARS-CoV-2 infection in severe forms triggers a vicious cycle that includes hypercoagulability, endothelial cell activation, and massive release of inflammatory mediators⁶ (Fig. 1). All this leads to an increased incidence of pulmonary and systemic thrombotic phenomena. A large series of autopsies documented an incidence of venous thromboembolism (VTE) of 42.5% and pulmonary embolism (PE) of 21%.⁷ Among the most feared systemic complications of SARS-CoV-2 infection is disseminated intravascular coagulation (DIC), primarily characterized by thrombotic phenomena, with a lower incidence of bleeding and thrombocytopenia than other viral infections. Autopsies also revealed thrombotic microangiopathy observed in the lungs, termed

G. Massaro and D. Lecis contributed equally to the article conception and writing.

^a Division of Cardiology, "Tor Vergata" University Hospital, v.le Oxford 81, Rome 00133, Italy; ^b Department of Biomedicine and Prevention, "Tor Vergata" University of Rome, Rome 00133, Italy

* Corresponding author. Division of Cardiology, "Tor Vergata" University Hospital, v.le Oxford 81, Rome 00133, Italy.

E-mail address: nucciochiricolo@gmail.com

Card Electrophysiol Clin 14 (2022) 41–52

<https://doi.org/10.1016/j.ccep.2021.10.005>

1877-9182/22/© 2021 Elsevier Inc. All rights reserved.

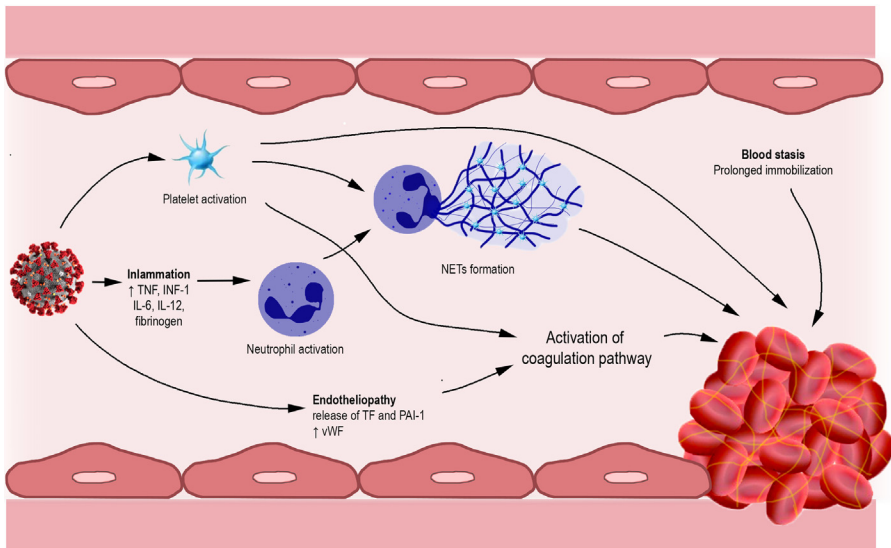


Fig. 1. Major mechanisms associated with the procoagulative state of COVID-19. SARS-CoV-2 exerts multiple effects systemically. Activation of the inflammatory response results in the recruitment of immune cells, including neutrophils. The virus can lead to a pathologic hyperactivation of platelets and endothelial damage that triggers the coagulation pathway.¹⁷ Some evidence points to a role of activated platelets in stimulating NETosis. NETs contribute to the onset of thrombotic phenomena. All this is favored by blood stasis, due to prolonged immobilization typical of the most severe forms of the disease.⁸⁷ IL-6, interleukin-6; IL-12, interleukin-12; INF-1, interferon-1; NET, neutrophil extracellular trap; PAI-1, plasminogen activator inhibitor-1; TNF, tumor necrosis factor; TF, tissue factor; vWF, Von-Willebrand factor.

“pulmonary intravascular coagulopathy”.⁷ In severe COVID-19, the “cytokine storm” is associated with abnormal coagulation parameters. It has been noticed that, in COVID-19 patients, higher interleukin (IL)-6 blood levels are directly related to fibrinogen levels predisposing to a hypercoagulable state and thromboembolic events.⁸ COVID-19-associated hypercoagulability can essentially be grouped into two main clinical manifestations: venous thrombotic events and arterial thrombotic events (ATEs) (Fig. 2).

PATHOPHYSIOLOGY OF HYPERCOAGULABILITY

A major cause of morbidity and mortality in COVID-19 patients is thromboinflammation (the coordinated activation of thrombosis and inflammation). Laboratory tests revealed, in a great percentage of patients hospitalized with COVID-19, the evidence of a coagulopathy resembling DIC with marked elevated levels of D-dimers in the plasma, a mild prolongation of the PT, and borderline thrombocytopenia.⁹ The postmortem examinations of COVID-19 patients showed extensive endothelial injury and diffuse microthrombosis.^{10–12} However, the etiology of COVID-19-associated coagulopathy is still controversial and is

likely to be heterogeneous, involving many different cell types. Indeed, observational studies and case series showed that not all the COVID-19 patients admitted to the ICU fulfilled the ISTH criteria for DIC (elevation of D-dimer levels, moderate-to-severe thrombocytopenia, prolongation of PT time, and decreased fibrinogen levels). Goshua and colleagues observed that, in a cohort of critically ill patients with COVID-19, the platelet counts were typically normal or mildly elevated and fibrinogen levels were markedly increased: findings that are inconsistent with coagulopathy of consumption such as DIC.¹³ The global interpretation from these diverse reports is that although COVID-19-associated coagulopathy has some shared pathophysiological features with DIC, the coagulopathy observed in patients with COVID-19 can be considered as a distinct entity. In COVID-19, the variable state of hypercoagulability depends both on the type of cell involvement (eg, endothelial cells, platelets, leukocytes) and the time of sample collection during the disease process. In patients with severe COVID-19, elevated levels of inflammatory markers (such as C-reactive protein, ferritin, erythrocyte sedimentation rate, and cytokines, including IL-1 β , IL-6, and TNF) lead to a hyperinflammatory response known as “cytokine storm,” which is

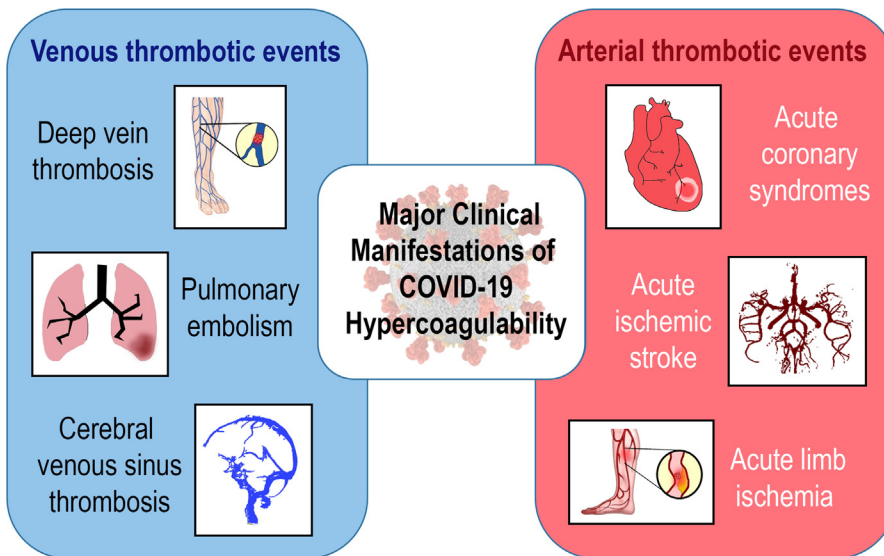


Fig. 2. Major thrombotic complications associated with COVID-19. Thromboses affect both arterial and venous districts. The latter are more frequent.

associated with poor outcomes. Jose and colleagues showed the correlation between elevated circulating levels of inflammatory cytokines and abnormal coagulation parameters.¹⁴ The IL-6 levels have been shown to correlate directly with fibrinogen levels in patients with COVID-19,⁸ as well as the levels of prothrombotic acute phase reactants (fibrinogen, vWF, and factor VIII) are increased in patients with COVID-19 compared with healthy individuals.^{15,16} In a recent review, Gu and colleagues¹⁷ identified platelets and endothelial cells as the two main cell types whose dysfunction contributes to the inflammation and coagulopathy associated with COVID-19, leading to thrombosis and eventually death. In the context of cardiovascular risk factors (diabetes mellitus, obesity, aging, and smoking), the mechanism of thrombocytopeny and endotheliopathy has been well represented. These findings are in line with the evidence that COVID-19 patients with cardiovascular risk factors have a high incidence of vascular complications (such as VTE, arterial thrombosis, and thrombotic microangiopathy), which contribute to the high mortality.^{18–20}

Thrombocytopeny and Endotheliopathy in COVID-19

Contrary to what was thought in the past regarding their limited functions, platelets interact with many other cell types, including circulating blood cells and endothelial cells, either directly or through the release of signaling molecules, thus functioning as a blood component that bridges the

immune system (through interactions with various leukocytes) and thrombosis (via platelet activation and release of hemostatic and inflammatory mediators).²¹ Manne and colleagues demonstrated that platelets are hyperactivated in patients with COVID-19.²² Activated platelets express on their surface some molecules involved in the stimulation of the immune system (such as P-selectin and CD40 L). Moreover, activated platelets can release α -granules, complement C3, and various cytokines (CCL2, IL-1 β , IL-7, and IL-8), thus triggering the immune system activation camp.^{23,24} Another cause of platelets hyperactivation is hypoxia,²⁵ a condition widely documented in COVID-19 patients who develop mild to severe hypoxia with peripheral blood oxygen desaturation. In addition, platelets dysfunction could be associated with a direct viral infection. ACE2, the cell-entry receptor for SARS-CoV-2, is expressed in the respiratory epithelium and endothelial cells,²⁶ but SARS-CoV-2 RNA traces were detected in platelet.²² Other potential methods of SARS-CoV-2 entry into platelets independent of ACE2 are emerging.²⁷ At last, a potential mechanism for platelet hyperactivation and thrombocytopenia consists in the formation of immune complexes similar to that seen in heparin-induced thrombocytopenia (HIT) with the consequence of an increased platelet clearance.²⁸

Endotheliopathy is a critical feature of severe COVID-19 across multiple studies. The endothelial damage and microvascular thrombosis are the results of both the direct viral infection of endothelial cells by SARS-CoV-2 and the endothelial cell

response to the inflammatory process associated with COVID-19. In critically ill patients with COVID-19, it is possible to reveal increased circulating levels of markers of endothelial cell damage, including thrombomodulin, angiopoietin 2, and vWF.²⁹ Della Rocca and colleagues showed an increased number of schistocytes in the peripheral blood smear of patients hospitalized with COVID-19 at different stages of disease severity, thus identifying a new biomarker to reveal a high-risk subpopulation with latent systemic microvascular damage irrespective of respiratory symptoms.³⁰ It has been well documented that age is the major risk factor for COVID-19-related death. Aging is strictly associated with endothelial dysfunction because of oxidative and nitrosative stress. In aged endothelial cells, the accumulation of reactive oxygen species can decrease the availability of nitric oxide (NO), a potent vasodilator with antiplatelet properties and cardioprotective effects.³¹ One of the most important functions of the vascular endothelium is to maintain a balance between proinflammatory and anti-inflammatory factors. In the elderly, the simultaneous invasion of the endothelium by SARS-CoV-2 via the angiotensin-converting enzyme 2 (ACE2) receptor can exacerbate endothelial dysfunction and damage, further promoting vascular inflammation and thrombosis.

VENOUS THROMBOTIC EVENTS IN COVID-19

A high incidence of thrombotic events, particularly deep vein thrombosis (DVT) and PE, has been documented in COVID-19 patients. As described in many studies, elevated D-dimer level is a common finding in COVID-19 patients. Anyway, high D-dimer levels meet low specificity in the absence of overt VTE clinical manifestations. Then, it is essential to recognize some "red flags" that can increase VTE suspicion in COVID-19 patients. The occurrence of typical DVT symptoms (asymmetric limb pain or edema), the increasing supplemental oxygen requirement, and hemodynamic instability in the setting of imaging findings inconsistent with worsening COVID-19 pneumonia or the onset of acute unexplained right ventricular dysfunction can be considered clinical manifestations of VTE.³² Several scoring risk systems have been developed to help the clinician in the identification of VTE (**Table 1**). The most used are the Padua prediction score (including factors such as previous VTE, active cancer, reduced mobility, known thrombophilic condition, recent trauma or surgery, age ≥ 70 years, respiratory/cardiac failure, acute myocardial infarction/stroke, acute infection, obesity, and ongoing hormonal treatment; <4 : low risk of VTE; ≥ 4 : high risk of VTE), the International

Medical Prevention Registry on Venous Thromboembolism (IMPROVE) score (7 risk factors: active cancer, previous VTE, thrombophilia, lower limb paralysis, immobilization < 7 days, intensive care unit/coronary care unit stay, age > 60 years; more than one positive factor increases the risk of symptomatic VTE to 7.2%), and the Wells' score (clinical signs/symptoms of DVT, PE most likely diagnosis, tachycardia [>100 bpm], immobilization/surgery in previous 4 weeks, prior DVT/PE, hemoptysis, active malignancy).³³ These tools are helpful to identify patients estimated at a higher risk for VTE and start prevention with a standard dose of subcutaneous unfractionated heparin (UFH) or low-molecular-weight heparin (LMWH) according to the published guidelines.

Laboratory Parameters in VTE

The most consistent hemostatic abnormalities with COVID-19 include, as mentioned earlier, increased D-dimer levels.³⁴ A prospective study comparing coagulation parameter disorders among patients with COVID-19 and healthy controls suggested that the D-dimer levels (10.36 vs 0.26 ng/L; $P < .001$), fibrin/fibrinogen degradation products (33.83 vs 1.55 mg/L; $P < .001$), and fibrinogen (5.02 vs 2.90 g/L; $P < .001$), in all SARS-CoV-2 cases, were substantially higher than those in healthy controls. Moreover, these biomarkers, especially D-dimer and fibrinogen degradation products, were higher in patients with severe SARS-CoV-2 infection than those with mild disease.⁵ Another common finding is mild thrombocytopenia. A meta-analysis showed that patients with severe disease were found to have a significantly lower platelet count (mean difference: $-31 \times 10^9/L$; 95% confidence interval [CI], -35 to $-29 \times 10^9/L$), and thrombocytopenia was associated with a 5-fold higher odds of having the severe disease (odds ratio: 5.13; 95% CI, 1.81–14.58).³⁵ Other hemostatic abnormalities variably associated with COVID-19 severity are the prolongation of the PT, international normalized ratio (INR),^{13,14} and thrombin time.³⁶ A trend toward shortened activated partial thromboplastin time (aPTT) is variably associated with the disease severity.^{37,38} Tang and colleagues³⁹ assessed 183 patients with COVID-19, 21 (11.5%) of whom died. The patients who died showed increased levels of D-dimer and fibrin degradation products (w3.5- and w1.9-fold, respectively) and PT prolongation (by 14%) ($P < .001$) when compared with survivors. Among the patients who died, 71% fulfilled the International Society on Thrombosis and Haemostasis (ISTH) criteria⁴⁰ for DIC, compared with only 0.6% among survivors. Taken all together, these

Table 1
Scoring systems commonly used for the assessment of the risk of venous thromboembolism and pulmonary embolism.

Items	Score
Padua Risk Score	
Active cancer (metastases and/or chemoradiotherapy in the previous 6 mo)	3
Previous VTE (with the exclusion of superficial vein thrombosis)	3
Bedrest for ≥ 3 d	3
Thrombophilia	3
Recent (≤ 1 mo) trauma and/or surgery	2
Elderly age (≥ 70 y)	1
Heart and/or respiratory failure	1
Acute myocardial infarction or ischemic stroke	1
Acute infection and/or rheumatologic disorder	1
Obesity (BMI ≥ 30 kg/m ²)	1
Ongoing hormonal treatment	1
High risk of VTE: ≥ 4 points	
IMPROVE score	
Previous VTE	3
Known thrombophilia	2
Current lower limb paralysis or paresis	2
History of cancer	2
ICU/CCU stay	1
Complete immobilization ≥ 1 d	1
Age ≥ 60 y	1
High-risk indication for prophylaxis if score ≥ 3	
Well's score	
Clinical signs/symptoms of DVT	3
PE is most likely diagnosis	3
Tachycardia (>100 bpm)	1.5
Immobilization/surgery in previous 4 wk	1.5
Prior DVT/PE	1.5
Hemoptysis	1
Active malignancy (trt w/in 6 mo)	1
Total score > 4 : PE likely	Total score < 4 : PE unlikely

Abbreviations: BMI, body mass index; CCU, cardiac care unit; DVT, deep venous thrombosis; ICU, intensive care unit; PE, pulmonary embolism; VTE, venous thromboembolism.

hemostatic abnormalities indicate some forms of coagulopathy that may predispose to thrombotic events. However, the underlying mechanism leading to the clinical manifestations of VTE is still unknown.

Nevertheless, it is uncertain whether these hemostatic changes are a specific effect of SARS-CoV-2 infection or are a consequence of the cytokine storm that precipitates the onset of systemic inflammatory response syndrome (SIRS) as documented in other severe viral diseases.^{41,42} A recent study reported 3 cases with severe COVID-19 and cerebral infarction, with one associated with bilateral limb ischemia, in the setting of elevated antiphospholipid antibodies.⁴³ The presence of antiphospholipid antibodies (eg, anti-cardiolipin IgA, anti- $\beta 2$ -glycoprotein I IgA, and IgG) has been described in the serum of COVID-19 patients. This finding may contribute to an increased risk of both venous and arterial thrombosis.^{44,45} However, some studies have highlighted that in setting a high degree of inflammation, like in SIRS, and an increased level of inflammatory markers, those antibodies can be falsely positive.⁴⁶ Whether antiphospholipid antibodies play a significant role in the pathophysiology of thrombosis associated with COVID-19 requires further investigation.

Imaging for VTE

To yield a definitive diagnosis of VTE, imaging studies can be helpful. The American Heart Association guidelines on managing massive and submassive PE recommend performing computed tomography pulmonary angiography (CTPA) in all patients with intermediate or high pretest probability or a positive D-dimer.⁴⁷ Referring to COVID-19, some studies have shown the usefulness of compression ultrasonography and CTPA in this setting of patients.^{48,49} An Italian study showed that 16 (36%) of 44 consecutive symptomatic patients had VTE on imaging, and 10 (33%) of 30 patients had a PE at CTPA. Half of the thromboembolic events were diagnosed within 24 h of hospital admission, highlighting the significance of early diagnosis and treatment in patients with COVID-19.⁵⁰ The decision to perform an imaging study for diagnosing DVT should be based on clinical judgment. The feasibility of these imaging modalities (mainly ultrasound imaging) in COVID-19 is a matter of concern because of the prolonged health care assistants' exposition time. Therefore, the role of bedside point-of-care ultrasound is essential in aiding diagnosis, reducing the exposition time. In a recent multicenter study, a 100% sensitivity and a 95.8%

specificity have been showing resorting to point-of-care ultrasound for the diagnosis of DVT.⁵¹ At last, in patients with high clinical suspicion of PE, a bedside cardiac ultrasound also assists with the diagnosis by rapid assessment of right ventricular size and function.

ATEs IN COVID-19

The relationship between viral respiratory infections and arterial thrombosis, especially acute coronary syndrome (ACS), is clearly described⁵² Cases of ACS have been previously described with influenza or other viral illness. They have been attributed to a combination of SIRS as well as localized vascular or plaque inflammation.⁵³ During the COVID-19 pandemics, small series of patients with coronary, cerebrovascular, and peripheral ATEs have also been reported, but their true incidence and consequences are not well described. In a series of 18 patients with COVID-19 and ST-segment elevation, in more than 50% of them, the origin was considered to be noncoronary.⁵⁴ Acute limb ischemia has been reported in 2 young COVID-19 patients with occlusion of major arteries of the upper and lower limbs.⁵⁵ In the systematic review and meta-summary of Tan and colleagues, it has been reported that the incidence of acute ischemic stroke in COVID-19 patients ranges from 0.9% to 2.7%. From this meta-summary, it has been observed that acute ischemic stroke severity in COVID-19 patients is typically at least moderate (NIHSS score 19 ± 8), with a high prevalence (40.9%) of large vessel occlusion. Notably, a significant number of cases tested positive for antiphospholipid antibodies. Although it is reported that antiphospholipid antibodies are commonly found in COVID-19 infections, the true prevalence of antiphospholipid-antibody positivity in the general population is not known. It has also been detected in healthy individuals. Hence, the significance of antiphospholipid antibodies in the pathogenesis of acute ischemic stroke in COVID-19 patients remains uncertain. It may be worthwhile for future studies to repeat and trend these serologic markers after the acute thrombotic setting.

At last, the mortality rate of COVID-19 patients experiencing acute ischemic stroke has been reported high (38.0%).⁵⁶ Recently, Cantador and colleagues⁵⁷ observed the 1% incidence of systemic ATEs in a large cohort of 1419 COVID-19 patients, with a death rate of 28.6%. In this study, the incidence of thrombotic events, at least for cerebrovascular, seems to be higher than expected with very serious consequences. A meta-analysis

conducted by Lippi and colleagues showed that cTnI concentration is only marginally increased in all patients with SARS-CoV-2 infection, whereby values exceeding the 99th percentile in the upper reference limit can only be observed in 8% to 12% of positive cases. Furthermore, higher troponin levels are associated with severe COVID-19.⁵⁸ Hence, it is reasonable to hypothesize that initial measurement of cardiac damage biomarkers immediately after hospitalization for SARS-CoV-2 infection, and longitudinal monitoring during the hospital stay may help identify a subset of patients with possible cardiac injury and thereby predict the progression of COVID-19 toward a worse clinical picture.⁵⁹ However, not all such events are due to thrombotic ACS. These data, taken all together, suggest that, although COVID-19 may favor the occurrence of thrombotic events, the destabilization and thrombosis of atherosclerotic plaques do not seem to be a frequent mechanism that warrants the need for specific systematic preventive measures. Nevertheless, a high level of suspicion and clinical surveillance should undoubtedly be maintained.

MANAGEMENT OF COVID-19–ASSOCIATED HYPERCOAGULABILITY

Coagulopathy associated with SARS-CoV-2 infection has peculiar characteristics compared with that associated with conventional sepsis, as evidenced by the difference in coagulation parameters described earlier. This is confirmed by the evidence of reduced mortality in patients with COVID-19 and elevated D-dimer undergoing anticoagulation than non-COVID-19 patients.⁶⁰

COVID-19 disease is associated with a higher incidence of thrombotic than hemorrhagic complications, which is the rationale for pharmacologic schemes targeting the coagulation pathway.

In the early stages of the pandemic, the absence of randomized clinical trials (RCTs) forced physicians to take an empirical approach to the use of anticoagulant regimens. Early evidence of different clinical pictures and numerous variables characterizing COVID-19 disease led to the realization that the "one-size-fits-all" strategy was not feasible.

To date, more than 75 RCT testing anticoagulant regimens in different clinical settings have been designed.⁶¹ The choice of drug and dosage in RCTs depends on the expected rate of thrombotic events in the study population: the use of prophylactic or intermediate doses has been preferred in trials of patients with mild COVID-19, whereas patients with critical illness or requiring intensive care have been treated with higher-dose regimens.

Given the higher incidence of thrombosis in venous versus arterial districts,^{48,62} clinical trials have tested more pharmacologic regimens to prevent and treat VTE. The use of such strategies in different types of patients will be discussed in the following section.

Pharmacologic Approaches

The main approaches used in RCTs for the prevention and treatment of thrombotic complications of COVID-19 include UFH, LMWH, fondaparinux, direct oral anticoagulants (DOACs), antiplatelet drugs, direct parenteral thrombin inhibitors, fibrinolytic agents, and drugs less commonly used in clinical practice such as dociparstat, dipyridamole, and nafamostat. The most significant evidence is with heparins and antiplatelet drugs.

Data on head-to-head comparisons between different drugs are lacking, so the choice is often driven by practical considerations.

Their wide use, mainly in the hospital setting, has made heparins the most studied anticoagulant drugs to treat COVID-19 coagulopathy. In addition to its anticoagulant effect, heparin also has anti-inflammatory properties and protective effects on the endothelium.⁶³

In prophylactic anticoagulation, once-daily LMWH is preferred over twice-daily subcutaneous UFH administration to reduce health care worker exposure. Therapeutic anticoagulation with UHF has the advantage that it can be temporarily discontinued and shows utility, especially in patients who are candidates for invasive procedures. However, frequent blood draws to check that aPTT is in the therapeutic range favor LMWH for the reasons already stated.

The antiviral and anti-inflammatory effects of heparin provide the rationale for the use of nebulized forms of UFH. Three trials are ongoing to test the efficacy and safety of this formulation compared to standard-of-care (INHALE-HEP and PACTR2020076032743) or prophylactic LMWH (NEBU-HEPA)

Direct anticoagulants represent an unquestionable advantage, especially in outpatients, to reduce the continuous recourse to INR assessment. However, their intrahospital use is limited by numerous interactions with other medications that are used to treat COVID-19 disease and the inability to use them in patients under orotracheal intubation or with dysphagia.

The use of antiplatelet drugs in the prophylaxis of thrombotic complications in patients with COVID-19 disease has been evaluated in both mild and severe forms of the disease. However,

unlike heparins, antiplatelet drugs have not demonstrated effects on "endotheliopathy."¹⁷

Prevention of VTE in Patients with Mild COVID-19

Patients with mild COVID-19 generally do not require hospitalization and should maintain home isolation. There are several ongoing clinical trials on the use of LMWH,⁶¹ DOAC, or aspirin in these patients. The only clinical trial published to date tested the use of sulodexide in the early stages of the disease in 243 patients in preventing hospitalizations and the use of oxygen therapy. The treatment arm showed a reduction in hospitalizations (relative risk: 0.60; 95% CI, 0.37–0.96; $P = .03$) and in the need for oxygen support (relative risk: 0.71; 95% CI, 0.50–1.00; $P = .05$) compared with placebo, with no significant difference in mortality.

Current recommendations do not indicate antithrombotic prophylaxis in all patients. However, in subjects at high risk of VTE (immobility, procoagulative status, previous VTE), antithrombotic prophylaxis should be considered, also taking into account the risk of bleeding.

Prevention and Treatment of VTE in Hospitalized Patients

When the pandemic began its spread in Europe, in China, Tang and colleagues⁶⁴ demonstrated that, in patients hospitalized for COVID-19 and with high D-dimer or high sepsis-induced coagulopathy (SIC) score, 28-day mortality was lower among those receiving anticoagulation than among those not receiving it. Most of the treated patients had received LMWH at prophylactic doses. Therefore, the international societies agreed that prophylactic dose LMWH should be considered in all patients (including noncritically ill) who require hospital admission for COVID-19 infection in the absence of any contraindications.⁶⁵

Anticoagulant dosing for the prevention of VTE is not well defined. Some clinicians use a therapeutic-dose anticoagulant regimen in the prevention of thrombotic complications in all hospitalized patients, whereas others reserve it for patients at high thrombotic risk, based on D-dimer or SIC score values. As already discussed, some evidence shows that SARS-CoV-2 disease has distinctive features compared with other forms of sepsis. Hadid and colleagues⁶⁶ have proposed a specific score for COVID-19 called CIC (COVID-19-induced coagulopathy) score, which adds the D-dimer value to the previous SIC score. Although not yet validated, this score can be helpful to

estimate the risk of thrombotic complications and start more intensive anticoagulation in patients with severe disease.

An observational study in the United States showed a better outcome in hospitalized patients treated with treatment-dose of anticoagulants than in those treated with prophylactic-dose.⁶⁷ HESACOVID, a randomized phase 2 clinical trial, showed improved gas exchange and reduced need for mechanical ventilation in patients with severe COVID-19 receiving therapeutic enoxaparin compared with the group receiving prophylactic anticoagulation.⁶⁸

Numerous clinical trials are ongoing to evaluate the use of different anticoagulant regimens in patients with severe disease. The design of the trials involves the use of more intense anticoagulation. In some studies, the administration of fibrinolytic agents is tested in patients with very severe forms, despite the rather limited sample size.

A complication observed in patients with severe forms of COVID-19 is DIC. Traditionally, DIC is characterized by thrombotic and hemorrhagic complications, whereas in the specific setting of SARS-CoV-2 disease, the former is more frequent than the latter. In patients with COVID-19 and DIC, prophylactic anticoagulation should be administered in the absence of overt bleeding. There is a tendency to recommend a less intense anticoagulation regimen in these patients; however, the individual risk of VTE and significant bleeding must be weighed.

Prevention of VTE in Postdischarge Patients

Some trials in acutely ill medical patients have shown that the extension of anticoagulation therapy after discharge is associated with reducing thromboembolic events at the cost of increased bleeding.⁶⁹ Given the particular tendency to hypercoagulability of patients with COVID-19, some trials evaluate the use of different pharmacologic regimens, including DOACs.^{70,71}

Treatment of Arterial Thromboembolic Complications

Arterial complications of SARS-CoV-2 infection have received less attention because of their lower incidence compared with their venous counterparts.^{48,62} A report from the New York City area shows that 57% of arterial thromboses, in patients with COVID-19 (upper- and lower limb ischemia, bowel ischemia, and cerebral ischemia), were treated with systemic anticoagulant therapy alone, 6% with administration of systemic tissue-plasminogen activator, 27% with revascularization, and 10% with amputation.⁷²

Patients with acute coronary thrombosis and concomitant SARS-CoV-2 infection have a higher thrombotic burden and a worse prognosis.⁷³ Hospital admissions for ST-segment elevation myocardial infarction (STEMI) were reduced during the pandemic, with a more extended treatment delay and hospitalization.⁷⁴ The treatment of patients with STEMI and established or suspected COVID-19 raised essential questions. The proposal to increase thrombolysis to protect health care workers⁷⁵ was not adopted by the European Association of Percutaneous Cardiovascular Interventions (EAPCI). Primary percutaneous coronary intervention (PCI) was confirmed as the gold-standard therapy for STEMI, whereas thrombolysis can be helpful when the catheterization laboratory is not available or timely primary PCI cannot be achieved.⁷⁶

For patients with COVID-19 and ischemic stroke, the use of thrombolysis and thrombectomy should be continued. There are some difficulties in managing neurologic rehabilitation, mostly related to organizational issues and risk of infection.⁷⁷

Acute limb thrombosis associated with COVID-19 is characterized by greater clot burden and increased rate of amputation and death.⁷⁸ As for myocardial infarction and ischemic stroke, treatment involves prompt intervention, characterized first by therapeutic anticoagulation, preferably with UFH, and then by an assessment based on the stability and viability of the limb on the most appropriate approach.

COAGULOPATHY AND VACCINES

A turning point in the fight against COVID-19 has been the development of vaccines, whose efficacy, especially against severe forms of the disease, and safety profile has led to a rapid "conditional marketing authorization" by the main regulatory agencies.⁷⁹

Abnormal activation of the coagulation system has been implicated in the pathogenesis of some severe adverse reactions related to the administration of anti-COVID-19 vaccines. After the marketing authorization, there have been increasing reports, albeit rare, of thrombotic complications at unusual sites, associated with thrombocytopenia, arising mainly after the administration of viral vector vaccines (Vaxzevria by AstraZeneca AB and COVID-19 Vaccine Janssen by Janssen-Cilag International NV). The incidence of this complication, named Vaccine-associated Immune Thrombosis and Thrombocytopenia (VITT) syndrome, remains largely unknown and appears to be between 1 in 125,000 and 1 in 1,000,000.⁸⁰

In April 2021, the New England Journal of Medicine reports a total of 39 cases of thrombosis, observed after administration of the Vaxzevria vaccine, in different descriptive studies.^{81–83} Clinical manifestations appear between 5 and 24 days after the first administration of the Astra-Zeneca serum. The affected population is predominantly female with an age of less than 50 years. In some cases (25.9%), affected women were using oral contraceptives. In most cases, thrombosis involved cerebral veins, although cases of involvement of the splanchnic venous district and PE have been described. Of note, severe thrombocytopenia (platelet count $<25,000/\text{mm}^3$) was present in 52.6% of the cases evaluated. The concomitance of thrombocytopenia and thrombosis suggested an autoimmune mechanism in the pathogenesis of the syndrome. A German group led by Andreas Greinacher shed light on the pathogenesis of VITT, highlighting its similarities to the condition known as HIT.⁸⁴ HIT is due to the formation of autoantibodies directed against a complex epitope formed by platelet-derived factor 4 (PF4) and heparin or another polyanionic molecule. These autoantibodies can bind the Fc γ IIa receptor (FcR γ IIa) present at the platelet surface causing intense intravascular platelet activation and aggregation.⁸⁵ They have also been found in VITT, even in the absence of previous heparin exposure.⁸¹ The cause of the formation of these antibodies in patients with VITT is unclear.

Cases of platelet count reduction associated with bleeding in the absence of thrombotic phenomena have been described in persons vaccinated with mRNA vector vaccines (Comirnaty by BioNTech Manufacturing GmbH and COVID-19 Vaccine Moderna by Moderna Biotech Spain, SL). Although it is not yet clear whether there is a causal link between this condition and the vaccine, an autoimmune-type mechanism has been hypothesized here too.⁸⁶

SUMMARY

Coagulopathy is common in acute sepsis. However, hypercoagulability associated with SARS-CoV-2 infection has peculiar features.

COVID-19 is associated with a high rate of thrombotic complications, mainly in the venous district. The "thromboinflammation" that characterizes the disease is evident in the alterations of laboratory parameters and some clinical manifestations characterized by a high mortality rate. Numerous clinical trials are ongoing to define the best preventive and therapeutic strategy in the management of thrombosis from COVID-19.

CLINICAL CARE POINTS

- In the management of patients with COVID-19, attention must be paid to the occurrence of arterial and venous thromboembolic complications, which appear to be frequently associated with the disease
- COVID-19 is associated with changes in coagulation parameters, which are more evident in severe forms of the disease (increased D-dimer, lengthening of PT and INR, thrombocytopenia, and shortening or sometimes lengthening of aPTT).
- The diagnosis of thrombotic complications such as DVT or PE cannot be derived solely from laboratory parameters but needs to be correlated with symptoms and must be supported by imaging methods such as CT angiography or ultrasound. Some scoring systems can be useful (see [Table 1](#))
- Current recommendations do not indicate antithrombotic prophylaxis in all COVID-19 patients. However, in subjects at high risk of VTE (immobility, procoagulative status, and previous VTE), antithrombotic prophylaxis should be considered.
- Low-molecular-weight heparin at prophylactic dosage should be considered in all patients (including noncritically ill) who require hospital admission for COVID-19 infection in the absence of any contraindications.
- The rare cases of thrombotic complications related to the administration of anti-COVID-19 vaccines, especially those using a viral vector, should not cast doubt on the advantages of vaccination. Epidemiologic data on adverse reactions and an understanding of the pathogenetic mechanisms may be helpful in limiting the incidence of such complications.

DISCLOSURE

The authors have nothing to disclose.

REFERENCES

1. Clerkin KJ, Fried JA, Raikhelkar J, et al. COVID-19 and cardiovascular disease. *Circulation* 2020; 141(20):1648–55.
2. Madjid M, Safavi-Naeini P, Solomon SD, et al. Potential effects of coronaviruses on the cardiovascular system: a review. 2020. *JAMA Cardiol* 2020;5(7): 831–40.

3. Driggin E, Madhavan MV, Bikdeli B, et al. Cardiovascular considerations for patients, health care workers, and health systems during the COVID-19 pandemic 2020;75:21.
4. Iba T, Levy JH, Levi M, et al. Coagulopathy in COVID-19. *J Thromb Haemost* 2020;18:2103–9.
5. Han H, Yang L, Liu R, et al. Prominent changes in blood coagulation of patients with SARS-CoV-2 infection. *Clin Chem Lab Med CCLM* 2020;58:1116–20.
6. Gerotziafas GT, Catalano M, Colgan M-P, et al, Scientific Reviewer Committee. Guidance for the management of patients with vascular disease or cardiovascular risk factors and COVID-19: position paper from VAS-European independent Foundation in Angiology/vascular medicine. *Thromb Haemost* 2020;120:1597–628.
7. Edler C, Schröder AS, Aepfelbacher M, et al. Dying with SARS-CoV-2 infection—an autopsy study of the first consecutive 80 cases in Hamburg, Germany. *Int J Legal Med* 2020;134:1275–84.
8. Ranucci M, Ballotta A, Di Dedda U, et al. The procoagulant pattern of patients with COVID-19 acute respiratory distress syndrome. *J Thromb Haemost* 2020;18:1747–51.
9. Guan W, Ni Z, Hu Y, et al. Clinical characteristics of coronavirus disease 2019 in China. *N Engl J Med* 2020;382:1708–20.
10. Dolhnikoff M, Duarte-Neto AN, Almeida Monteiro RA, et al. Pathological evidence of pulmonary thrombotic phenomena in severe COVID-19. *J Thromb Haemost* 2020;18:1517–9.
11. Carsana L, Sonzogni A, Nasr A, et al. Pulmonary post-mortem findings in a series of COVID-19 cases from northern Italy: a two-centre descriptive study. *Lancet Infect Dis* 2020;20:1135–40.
12. Menter T, Haslbauer JD, Nienhold R, et al. Postmortem examination of COVID-19 patients reveals diffuse alveolar damage with severe capillary congestion and variegated findings in lungs and other organs suggesting vascular dysfunction. *Histopathology* 2020;77:198–209.
13. Goshua G, Pine AB, Meizlish ML, et al. Endotheliopathy in COVID-19-associated coagulopathy: evidence from a single-centre, cross-sectional study. *Lancet Haematol* 2020;7:e575–82.
14. Jose RJ, Manuel A. COVID-19 cytokine storm: the interplay between inflammation and coagulation. *Lancet Respir Med* 2020;8:e46–7.
15. Panigada M, Bottino N, Tagliabue P, et al. Hypercoagulability of COVID-19 patients in intensive care unit: a report of thromboelastography findings and other parameters of hemostasis. *J Thromb Haemost* 2020;18:1738–42.
16. Escher R, Breaky N, Lämmle B. Severe COVID-19 infection associated with endothelial activation. *Thromb Res* 2020;190:62.
17. Gu SX, Tyagi T, Jain K, et al. Thrombocytopeny and endotheliopathy: crucial contributors to COVID-19 thromboinflammation. *Nat Rev Cardiol* 2021;18:194–209.
18. Cui S, Chen S, Li X, et al. Prevalence of venous thromboembolism in patients with severe novel coronavirus pneumonia. *J Thromb Haemost* 2020;18:1421–4.
19. Zhang L, Feng X, Zhang D, et al. Deep vein thrombosis in hospitalized patients with COVID-19 in Wuhan, China: prevalence, risk factors, and outcome. *Circulation* 2020;142:114–28.
20. Nahum J, Morichau-Beauchant T, Daviaud F, et al. Venous thrombosis among critically ill patients with coronavirus disease 2019 (COVID-19). *JAMA Netw Open* 2020;3:e2010478.
21. Koupenova M, Freedman JE. Platelets and immunity: going viral. *Arterioscler Thromb Vasc Biol* 2020;40:1605–7.
22. Manne BK, Denorme F, Middleton EA, et al. Platelet gene expression and function in patients with COVID-19. *Blood* 2020;136:1317–29.
23. Fitch-Tewfik JL, Flaumenhaft R. Platelet granule exocytosis: a comparison with chromaffin cells. *Front Endocrinol*, 2013;4(77).
24. Sut C, Tariket S, Aubron C, et al. The non-hemostatic aspects of transfused platelets. *Front Med* 2018;5:42.
25. Tyagi T, Ahmad S, Gupta N, et al. Altered expression of platelet proteins and calpain activity mediate hypoxia-induced prothrombotic phenotype. *Blood* 2014;123:1250–60.
26. Ackermann M, Verleden SE, Kuehnel M, et al. Pulmonary vascular endothelialitis, thrombosis, and angiogenesis in covid-19. *N Engl J Med* 2020;383:120–8.
27. Hoffmann M, Kleine-Weber H, Schroeder S, et al. SARS-CoV-2 cell entry depends on ACE2 and TMPRSS2 and is blocked by a clinically proven Protease inhibitor. *Cell* 2020;181:271–80.e8.
28. Perdomo J, Leung HHL, Ahmadi Z, et al. Neutrophil activation and NETosis are the major drivers of thrombosis in heparin-induced thrombocytopenia. *Nat Commun* 2019;10:1322.
29. Pine AB, Meizlish ML, Goshua G, et al. Circulating markers of angiogenesis and endotheliopathy in COVID-19. *Pulm Circ* 2020;10. 204589402096654.
30. Della Rocca DG, Magnocavallo M, Lavalle C, et al. Evidence of systemic endothelial injury and microthrombosis in hospitalized COVID-19 patients at different stages of the disease. *J Thromb Thrombolysis* 2021;51:571–6.
31. Lakatta EG, Levy D. Arterial and cardiac aging: major Shareholders in cardiovascular disease enterprises: Part II: the aging Heart in health: links to Heart disease. *Circulation* 2003;107:346–54.
32. Bikdeli B, Madhavan MV, Jimenez D, et al. COVID-19 and thrombotic or thromboembolic disease:

- implications for prevention, antithrombotic therapy, and follow-up. *J Am Coll Cardiol* 2020;75:2950–73.
33. Obi AT, Barnes GD, Wakefield TW, et al. Practical diagnosis and treatment of suspected venous thromboembolism during COVID-19 pandemic. *J Vasc Surg Venous Lymphat Disord* 2020;8:526–34.
 34. Lippi G, Favaloro EJ. D-Dimer is associated with severity of coronavirus disease 2019: a pooled analysis. *Thromb Haemost* 2020;120:876–8.
 35. Lippi G, Plebani M, Henry BM. Thrombocytopenia is associated with severe coronavirus disease 2019 (COVID-19) infections: a meta-analysis. *Clin Chim Acta* 2020;506:145–8.
 36. Gao Y, Li T, Han M, et al. Diagnostic utility of clinical laboratory data determinations for patients with the severe COVID-19. *J Med Virol* 2020;92:791–6.
 37. Huang C, Wang Y, Li X, et al. Clinical features of patients infected with 2019 novel coronavirus in Wuhan, China. *The Lancet* 2020;395:497–506.
 38. Lippi G, Salvagno GL, Ippolito L, et al. Shortened activated partial thromboplastin time: causes and management. *Blood Coagul Fibrinolysis* 2010;21:459–63.
 39. Tang N, Li D, Wang X, et al. Abnormal coagulation parameters are associated with poor prognosis in patients with novel coronavirus pneumonia. *J Thromb Haemost* 2020;18:844–7.
 40. Levi M, Toh CH, Thachil J, et al. Guidelines for the diagnosis and management of disseminated intravascular coagulation. *Br J Haematol* 2009;145:24–33.
 41. Ramacciotti E, Agati LB, Aguiar VCR, et al. Zika and Chikungunya virus and risk for venous thromboembolism. *Clin Appl Thromb* 2019;25:107602961882118.
 42. Smither S, O'Brien L, Eastaugh L, et al. Haemostatic changes in five patients infected with Ebola virus. *Viruses* 2019;11:647.
 43. Zhang Y, Xiao M, Zhang S, et al. Coagulopathy and antiphospholipid antibodies in patients with Covid-19. *N Engl J Med* 2020;382:e38.
 44. Mendoza-Pinto C, García-Carrasco M, Cervera R. Role of infectious diseases in the antiphospholipid syndrome (including its Catastrophic variant). *Curr Rheumatol Rep* 2018;20:62.
 45. Abdel-Wahab N, Talathi S, Lopez-Olivo MA, et al. Risk of developing antiphospholipid antibodies following viral infection: a systematic review and meta-analysis. *Lupus* 2018;27:572–83.
 46. Salluh JIF, Soares M, Meis ED. Antiphospholipid antibodies and multiple organ failure in critically ill cancer patients. *Clinics* 2009;64:79–82.
 47. Jaff MR, McMurtry MS, Archer SL, et al. Management of massive and submassive pulmonary embolism, iliofemoral deep vein thrombosis, and chronic thromboembolic pulmonary hypertension: a scientific statement from the American Heart association. *Circulation* 2011;123:1788–830.
 48. Klok FA, Kruip MJHA, van der Meer NJM, et al. Confirmation of the high cumulative incidence of thrombotic complications in critically ill ICU patients with COVID-19: an updated analysis. *Thromb Res* 2020;191:148–50.
 49. Grillet F, Behr J, Calame P, et al. Acute pulmonary embolism associated with COVID-19 pneumonia detected with pulmonary CT angiography. *Radiology* 2020;296:E186–8.
 50. Lodigiani C, Iapichino G, Carenzo L, et al. Venous and arterial thromboembolic complications in COVID-19 patients admitted to an academic hospital in Milan, Italy. *Thromb Res* 2020;191:9–14.
 51. Fischer EA, Kinnear B, Sall D, et al. Hospitalist-operated compression ultrasonography: a point-of-care ultrasound study (HOCUS-POCUS). *J Gen Intern Med* 2019;34:2062–7.
 52. Kwong JC, Schwartz KL, Campitelli MA, et al. Acute myocardial infarction after laboratory-confirmed influenza infection. *N Engl J Med* 2018;378:345–53.
 53. Corrales-Medina VF, Madjid M, Musher DM. Role of acute infection in triggering acute coronary syndromes. *Lancet Infect Dis* 2010;10:83–92.
 54. Bangalore S, Sharma A, Slotwiner A, et al. ST-segment elevation in patients with covid-19 — a case series. *N Engl J Med* 2020;382:2478–80.
 55. Perini P, Nabulsi B, Massoni CB, et al. Acute limb ischaemia in two young, non-atherosclerotic patients with COVID-19. *The Lancet* 2020;395:1546.
 56. Tan Y-K, Goh C, Leow AST, et al. COVID-19 and ischemic stroke: a systematic review and meta-summary of the literature. *J Thromb Thrombolysis* 2020;50:587–95.
 57. Cantador E, Núñez A, Sobrino P, et al. Incidence and consequences of systemic arterial thrombotic events in COVID-19 patients. *J Thromb Thrombolysis* 2020;50:543–7.
 58. Yang X, Yu Y, Xu J, et al. Clinical course and outcomes of critically ill patients with SARS-CoV-2 pneumonia in Wuhan, China: a single-centered, retrospective, observational study. *Lancet Respir Med* 2020;8:475–81.
 59. Lippi G, Lavie CJ, Sanchis-Gomar F. Cardiac troponin I in patients with coronavirus disease 2019 (COVID-19): evidence from a meta-analysis. *Prog Cardiovasc Dis* 2020;63:390–1.
 60. Yin S, Huang M, Li D, et al. Difference of coagulation features between severe pneumonia induced by SARS-CoV2 and non-SARS-CoV2. *J Thromb Thrombolysis* 2021;51:1107–10.
 61. Talasaz AH, Sadeghipour P, Kakavand H, et al. Recent randomized trials of antithrombotic therapy for patients with COVID-19: JACC state-of-the-art review. *J Am Coll Cardiol* 2021;77:1903–21.
 62. Fournier M, Faillie D, Dossier A, et al. Arterial thrombotic events in Adult Inpatients with COVID-19. *Mayo Clin Proc* 2021;96:295–303.

63. Poterucha TJ, Libby P, Goldhaber SZ. More than an anticoagulant: do heparins have direct anti-inflammatory effects? *Thromb Haemost* 2017;117:437–44.
64. Tang N, Bai H, Chen X, et al. Anticoagulant treatment is associated with decreased mortality in severe coronavirus disease 2019 patients with coagulopathy. *J Thromb Haemost* 2020;18:1094–9.
65. Thachil J, Tang N, Gando S, et al. ISTH interim guidance on recognition and management of coagulopathy in COVID-19. *J Thromb Haemost* 2020;18:1023–6.
66. Hadid T, Kafri Z, Al-Katib A. Coagulation and anticoagulation in COVID-19. *Blood Rev* 2021;47:100761.
67. Paranjpe I, Fuster V, Lala A, et al. Association of treatment dose anticoagulation with in-hospital Survival among hospitalized patients with COVID-19. *J Am Coll Cardiol* 2020;76:122–4.
68. Lemos ACB, do Espírito Santo DA, Salvetti MC, et al. Therapeutic versus prophylactic anticoagulation for severe COVID-19: a randomized phase II clinical trial (HESACOVID). *Thromb Res* 2020;196:359–66.
69. Schindewolf M, Weitz JI. Broadening the categories of patients eligible for extended venous thromboembolism treatment. *Thromb Haemost* 2020;120:014–26.
70. Available at: <https://clinicaltrials.gov/ct2/show/NCT04662684>. Accessed September 25, 2021.
71. Available at: <https://clinicaltrials.gov/ct2/show/NCT04650087>. Accessed September 25, 2021.
72. Etkin Y, Conway AM, Silpe J, et al. Acute arterial thromboembolism in patients with COVID-19 in the New York city area. *Ann Vasc Surg* 2021;70:290–4.
73. Choudry FA, Hamshere SM, Rathod KS, et al. High thrombus burden in patients with COVID-19 presenting with ST-segment elevation myocardial infarction. *J Am Coll Cardiol* 2020;76:1168–76.
74. De Luca G, Verdoia M, Cercek M, et al. Impact of COVID-19 pandemic on mechanical reperfusion for patients with STEMI. *J Am Coll Cardiol* 2020;76:2321–30.
75. Zeng J, Huang J, Pan L. How to balance acute myocardial infarction and COVID-19: the protocols from Sichuan Provincial People's Hospital. *Intensive Care Med* 2020;46:1111–3.
76. Chieffo A, Stefanini GG, Price S, et al. EAPCI position statement on invasive management of acute coronary syndromes during the COVID-19 pandemic. *Eur Heart J* 2020;41:1839–51.
77. Venketasubramanian N, Anderson C, Ay H, et al. Stroke care during the COVID-19 pandemic: international expert panel review. *Cerebrovasc Dis Basel Switz* 2021;50:245–61.
78. Goldman IA, Ye K, Scheinfeld MH. Lower-extremity arterial thrombosis associated with COVID-19 is characterized by greater Thrombus burden and increased rate of amputation and death. *Radiology* 2020;297:E263–9.
79. Available at: <https://www.ema.europa.eu/en/human-regulatory/overview/public-health-threats/coronavirus-disease-covid-19/treatments-vaccines-covid-19>. Accessed September 28 2021.
80. Franchini M, Liumbruno GM, Pezzo M. COVID-19 vaccine-associated immune thrombosis and thrombocytopenia (VITT): Diagnostic and therapeutic recommendations for a new syndrome. *Eur J Haematol* 2021;107:173–80.
81. Greinacher A, Thiele T, Warkentin TE, et al. Thrombotic thrombocytopenia after ChAdOx1 nCov-19 vaccination. *N Engl J Med* 2021;384:2092–101.
82. Schultz NH, Sørvoll IH, Michelsen AE, et al. Thrombosis and thrombocytopenia after ChAdOx1 nCoV-19 vaccination. *N Engl J Med* 2021;384:2124–30.
83. Scully M, Singh D, Lown R, et al. Pathologic antibodies to platelet factor 4 after ChAdOx1 nCoV-19 vaccination. *N Engl J Med* 2021;384:2202–11.
84. Oldenburg J, Klamroth R, Langer F, et al. Diagnosis and management of vaccine-related thrombosis following AstraZeneca COVID-19 vaccination: guidance statement from the GTH. *Hämostaseologie*. 2021;41:184–9.
85. Linkins L-A. Heparin induced thrombocytopenia. *BMJ* 2015;350:g7566.
86. Lee E, Cines DB, Gernsheimer T, et al. Thrombocytopenia following Pfizer and Moderna SARS-CoV -2 vaccination. *Am J Hematol* 2021;96:534–7.
87. Ortega-Paz L, Capodanno D, Montalescot G, et al. Coronavirus Disease 2019–Associated Thrombosis and Coagulopathy: Review of the Pathophysiological Characteristics and Implications for Antithrombotic Management [cited 2021 Jul 15];10. *J Am Heart Assoc* 2021. Available at: <https://www.ahajournals.org/doi/10.1161/JAHA.120.019650>.