



Original Article

Prevalence of abnormal upper limb arterial anatomy and its correlation with access failure during transradial coronary angiography

Sripad V. Khairnar*, Ranjit Kumar Nath, Balram Yadav, Kakasaheb Bhosale, Sulabh Chandraker

Department of Cardiology, ABVIMS & Dr. Ram Manohar Lohia Hospital, New Delhi 110001, India



ARTICLE INFO

Article history:

Received 5 November 2019

Accepted 20 November 2020

Available online 24 November 2020

Keywords:

Abnormal upper limb arterial anatomy

Access failure

Coronary angiography

Transradial

ABSTRACT

Objective: The study aimed at to find out prevalence of abnormal upper limb arterial anatomy and its correlation with access failure during transradial coronary angiography.

Method: This was a prospective observational study of 1512 patients who had undergone transradial coronary angiography (CAG). Angiographic assessment of upper limb arterial tree was performed when the angiographic guidewire or the diagnostic catheter followed an abnormal path or got stuck in its course.

Results: About 5.29% patients (80/1512) were noted to have abnormal upper limb arterial anatomy. The most common abnormality detected were radio-ulnar loop in 22 (1.46%) patients, tortuous upper limb arteries 19 (1.25%) and abnormal high origin of radial artery 10 (0.66%) patients. Access failure was encountered in 4.4% (67/1512) of total patients and 64.17% (43/67) access failure was due to abnormal upper limb arterial anatomy.

Conclusion: Abnormal upper limb arterial anatomy was the most common cause of access failure in transradial coronary angiography in this study.

© 2020 Cardiological Society of India. Published by Elsevier B.V. This is an open access article under the CC BY-NC-ND license (<http://creativecommons.org/licenses/by-nc-nd/4.0/>).

1. Introduction

Coronary angiography (CAG) is the most common procedure performed in the cardiac catheterization laboratory. CAG can be done by transfemoral, transradial, transbrachial or transulnar route. Till few years ago transfemoral was the most commonly utilized approach for all cardiac catheterizations, but for last 2 decades there has been a growing interest in transradial approach for all coronary diagnostic and therapeutic interventions. Radner et al was the first to describe transradial catheterization using radial artery cut-down in 1948.¹ The advantages of the radial approach are reduction in access site complications including bleeding, reduced length of hospital stay and increased patient comfort. Mortality benefits are also noted when used for primary Percutaneous Transluminal Coronary Angioplasty (PTCA) in ST-elevation acute myocardial infarction (STEMI).² Access site failure and access site

cross over rates are some of the most common hurdles in TRA. Access site cross over rate have been reported from 4.6% to 10%.² Few previous studies also documented transradial access failure in 1%–5% of cases.³ But when brachial access was used for intervention, the failure to access was less common.⁴ This discrepancy can be explained in part due to the smaller diameter radial artery and variations in radial artery anatomy. A study by Louvard Y et al have found that access failure was primarily due to anatomical abnormalities in radial artery like radial loops and tortuosities in its course.⁵ Most of the present literatures are on radial artery abnormalities and variations hampering the TRA. Hence there is a constant need for evaluation of the upper limb arterial anatomical abnormalities (radial, brachial, axillary and subclavian artery) and its correlation with access failure for transradial interventions.

2. Methodology

This prospective observational study was conducted in the Department of Cardiology, Dr. RML Hospital, New Delhi. Consecutive patients undergoing transradial coronary angiography (CAG)

* Corresponding author. Room no.309, Doctors Hostel, Dr RML hospital campus, Baba kharadk singh marg, New Delhi 10001, India.

E-mail address: sripad.khairnar1101@gmail.com (S.V. Khairnar).

were included. All patients of more than 18 years old and had given consent were included in the study. Patients with previous history of transradial CAG, right upper limb trauma or surgery, and not willing to give consent were excluded. The study protocol was approved by the Institutional Ethics Committee. A total of 1560 patients were enrolled, but 48 patients were excluded for reasons mentioned above. All procedures were performed through right radial artery access. Before transradial CAG, hand perfusion was assessed using the modified Allen's test.

2.1. Radial artery cannulation angiography procedure

The right arm was positioned beside the body with the wrist hyperextended over a block. With proper aseptic precautions ventral part of the right wrist was prepared and draped. Local anaesthesia was administered with 2% lidocaine. The radial artery was cannulated using the standard Seldinger technique. The radial artery was punctured with a 20 gauge needle at 45° angle proximal to the styloid process. A 0.025" straight soft tip guidewire was inserted through the needle. After removing the needle a 5 Fr sheath (length 7 cm) was introduced gently into the radial artery over the guidewire. After the removal of the dilator of the introducer sheath and the guidewire, the sheath was flushed with first heparinized saline followed by vasodilator solution containing verapamil and nitroglycerine. Heparin (60 IU/kg) was administered via peripheral intra-venous line after the sheath was introduced. Coronary angiography was completed with 5 Fr radial Optitorque Tiger catheter (Terumo Corporation, Tokyo, Japan) introduced over a 0.035" J-tip Teflon guidewire or a radifocus guidewire, if the J-tip Teflon guidewire was difficult to advance. After the completion of the procedure, the sheath was immediately removed and manual compression bandage was applied with the help of sterile gauze and adhesive bandage for about 3 h.

2.2. Evaluation of the upper limb arterial anatomy

The route and advancement of the J-tip guidewire and diagnostic catheter was observed under fluoroscopy while introducing them from the access site to ascending aorta. Note was made of any abnormal path or obstruction along which the guide wire or catheter travelled and evaluation was done by angiography. Failure to complete the coronary angiography via this route was considered as access failure. Angiographic evaluation of right upper limb

arteries was done mostly by retrograde angiography using the same diagnostic catheter and if needed or retrograde angiography didn't delineate the problem, antegrade angiography was performed via femoral access and going to the nearest possible point of abnormality or obstruction. Techniques like wire and catheter manipulation were used to overcome anatomic abnormalities and obstruction. If manipulation lead to successful CAG, the cases were included in anatomical variation but not in access failure. If transradial CAG was unsuccessful, femoral route was used to complete the procedures. If the guidewire and catheter did not follow an abnormal route and pass without any obstruction, then these patients were considered to have normal upper limb arterial anatomy and, in such cases, no further angiographic evaluation were done. Inability to do or complete transradial CAG due to radial artery spasm, requiring catheter exchange, operator-related inability, coronary artery variations, or dilated aortic root etc. were not included as access failure.

2.3. Identification of right upper limb arterial anatomy and its abnormality

Burzotta et al⁶ have given definitions of the upper limb arterial anomalies and these have been adopted by different investigators for bringing uniformity in reporting. These definitions have been applied in our study also. These definitions are mentioned in Table 1. Hypoplastic radial artery was defined as when radial pulse was palpable but sheath could not be inserted in the radial artery despite adequate use of vasodilators.

3. Results and observations

A total of 1512 patients were evaluated and their findings were included for final analysis. Mean age of the cohort was 54.9 years (range 22–89 years). There were 1103 (72.9%) males and 409 (27.1%) females. Successful procedure was done in 1445 (95.6%) patients and access failure was noted in a total of 67 (4.4%) patients.

3.1. Right upper limb arterial anatomy by angiography

Right upper limb arterial anatomy was normal in 1432 (94.71%) patients. In 80 (5.29%) patient's anatomical abnormality was noted in the right upper limb arteries. Frequency of occurrence of various abnormalities in the right upper limb arteries are as noted in Table 2.

3.2. Access failure

CAG could not be completed through transradial approach in 67 (4.4%) patients (Table 3) due to different reasons that include radial

Table 1
Definitions of abnormal upper limb arterial system.

Variation	Definition
Congenital absence of the artery	Absent radial artery
Stenotic radial artery	>50% luminal narrowing
Tortuous radial artery	bending >45°
Radial artery loop	loop of 360° in the artery which is not at anastomotic sites
Radio-ulnar loops	loop of 360° at the anastomosis with brachial-ulnar artery
Brachial artery loops	loop in the brachial artery of 360° not at anastomotic sites
High origin of the radial artery	origin of radial artery from brachial or axillary artery with a normal brachial artery which branches into ulnar and interosseous arteries
Stenotic brachial artery	>50% luminal narrowing
Tortuous brachial artery	bending >45°
Subclavian tortuosity	more than 90° bent in the vessel
Subclavian stenosis	>50% luminal narrowing
Arteria lusoria	Retro-esophageal right subclavian artery

Table 2
Upper limb arterial anatomy by angiography.

Radial artery anatomy	Number (n)	Percentage (%)
Normal	1432	94.71
Tortuous radial artery (image 1a)	11	0.73
Brachial or axillary artery stenosis (image 1b)	8	0.53
Radial or Radioulnar loop (image 1c and 1d)	22	1.46
Tortuous subclavian artery (image 2a)	3	0.20
Tortuous brachial artery (image 2b)	5	0.33
Abnormally high origin of the radial artery	10	0.66
Arteria lusoria (image 2c)	5	0.33
Radial artery stenosis	6	0.40
Subclavian artery stenosis (image 2d)	6	0.40
Hypoplasia of radial artery	4	0.26
Total	1512	100

Table 3
Access failure.

Type of anatomic abnormality	Number	Access failure (%)
Normal	1432	24 (1.67)
Radial or Radioulnar loop	22	8 (36.36)
Tortuous radial artery	11	5 (45.45)
Abnormally high origin of the radial artery	10	5 (50)
Subclavian artery stenosis	6	6 (100)
Brachial or axillary artery stenosis	8	7 (87.5)
Radial artery stenosis	6	6 (100)
Hypoplasia of radial artery	4	4 (100)
Arteria lusoria	5	0 (0)
Tortuous brachial artery	5	1 (20)
Tortuous subclavian artery	3	1 (33.33)
Total	1512	67 (4.43)

artery spasm, operator related inability, coronary artery variations, dilated aortic root or abnormal upper limb arterial anatomy. Out of these 67 patients, there were 43 patients where abnormal upper limb arterial anatomy was the cause of access failure. So, abnormal upper limb arterial anatomy was the cause of access failure in about 64.17% of patients. Causes of access failure other than abnormal upper limb arterial anatomy were not evaluated systematically. Access failure rates were 100% in radial artery stenosis, hypoplastic radial artery, and subclavian artery stenosis, 87.5% in brachial artery stenosis, 45.5% in tortuous radial artery, 36.4% in radial and

radioulnar loop, 50% in high origin radial artery, 20% in tortuous brachial artery, and 33.3% in tortuous subclavian artery.

4. Discussion

This prospective observational study included 1512 patients undergoing diagnostic transradial coronary angiography in a tertiary care centre in North India. Mean age of the study population was 54.97 ± 11.24 years. There were 72.9% male patients and 27.1% female patients. Successful CAG was done in 95.6% patients by TRA. Access failure occurred in about 4.4% patients. Previous studies have reported access failure via the radial artery in 1%–5% of cases.^{3,5}

4.1. Upper limb arterial anatomy

There were 5.3% patients with abnormal right upper limb arterial anatomy. It was found that the most common abnormalities were radioulnar loop, found in 22 (1.46%) patients, followed by tortuous radial artery in 11 (0.73%) patients and abnormal high origin of radial artery in 10 (0.66%) patients. Study by Garg N et al noted 9.7% patients with abnormal upper limb arterial anatomy in their study.⁷ Another study by Khanra D et al⁸ found abnormal variation in radial artery in 11% patients. In these studies, they performed angiography of each patient and every notable abnormality was documented. In our study angiographic assessment of upper limb arterial tree was done only when the guidewire or the

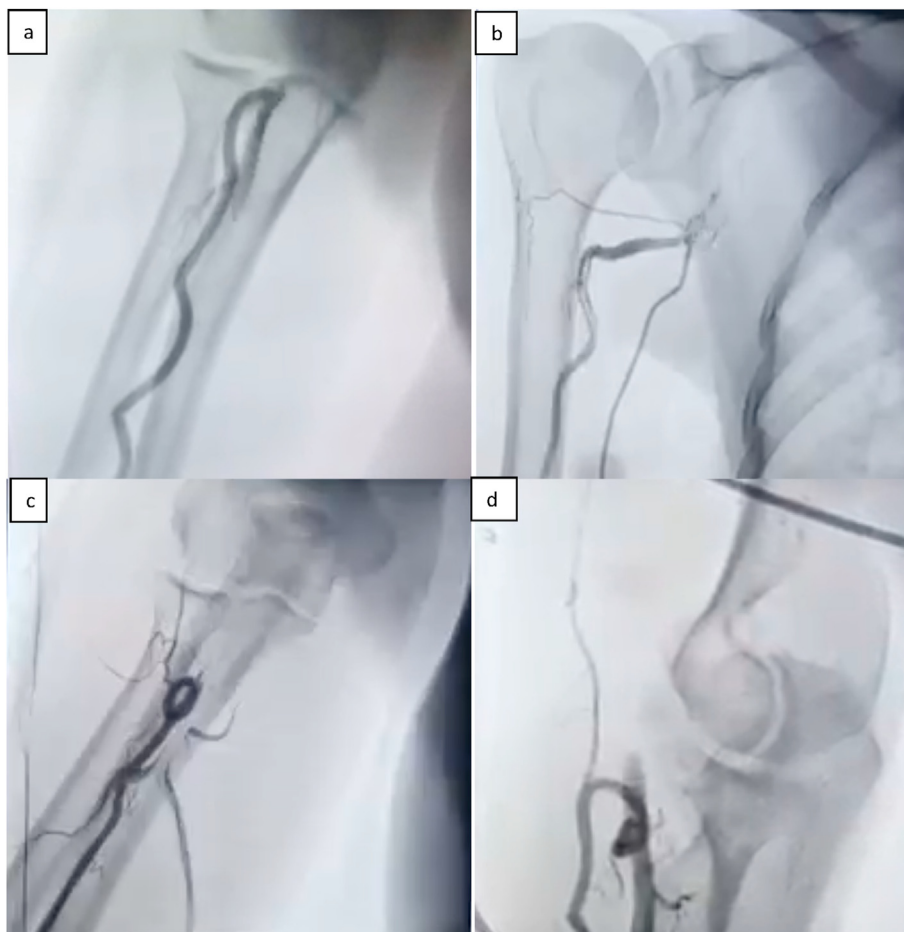


Fig. 1. Different anomalies of arterial course in right upper limb. (a) Tortuous. radial artery, (b) stenotic axillary artery, (c) Radial artery loop, (d) Radio-ulnar loop.

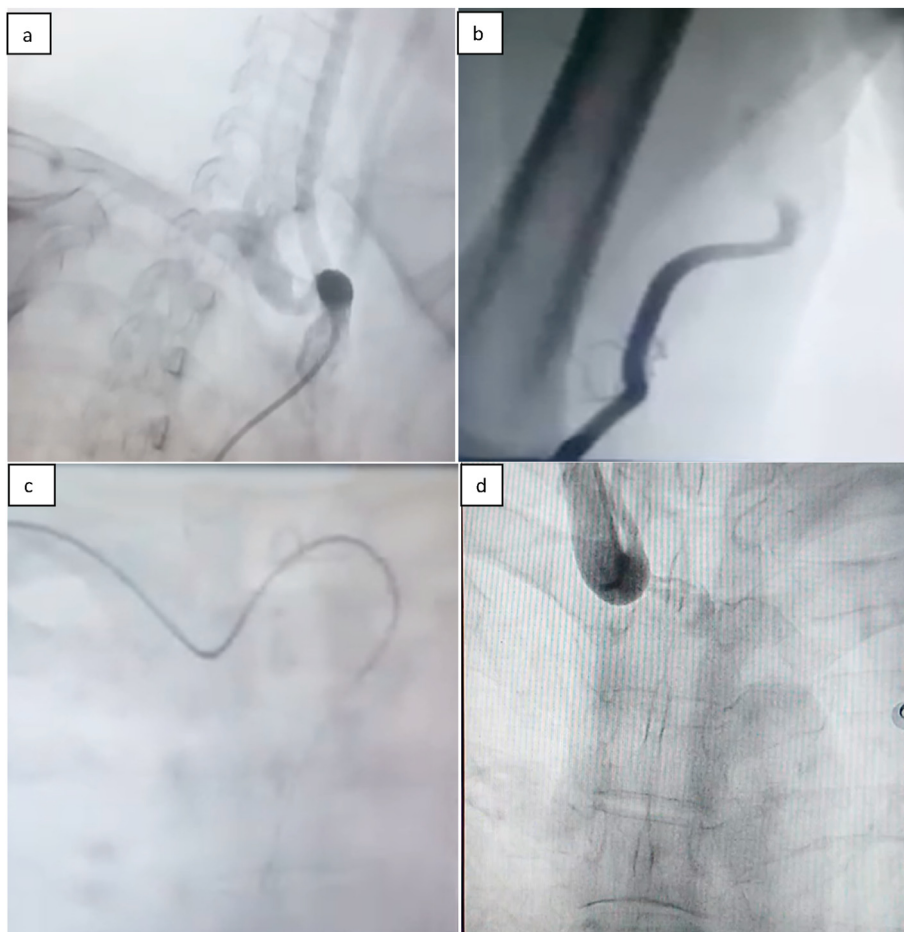


Fig. 2. Different anomalies of arterial course in the proximal part of right hand and neck. (a) Tortuous and stenotic subclavian artery, (b) Tortuous brachial artery, (c) Catheter course in Arteria lusoria, and (d) Severely stenotic subclavian artery.

diagnostic catheter followed an abnormal path or got stuck in its course, hence only significant and clinically relevant abnormalities were noted. This may be the reason for our study having a lower incidence of abnormal upper limb arterial anatomy.

4.2. Radioulnar and radial loop

Radioulnar loop (Fig. 1d) or radial loop (Fig. 1c) was the most common abnormality found in our study. It was found in 1.46% patients and was associated with access failure in 36.4% cases. In the study by Khanra D et al⁸ radial loop was noted in 1.17% patients and was the cause of access failure in 45.3% cases. To ascertain the extent of the loop, angiographic or coronary angioplasty guidewire can be used. It was found that radial loop can be straightened with wire relatively easily but doing so in radioulnar loop is difficult.

4.3. Tortuous radial, brachial and subclavian artery

Significant tortuous radial artery (Fig. 1a) was found in 0.73% patients, tortuous brachial artery (Fig. 2b) was noted in 0.33% patients, and tortuous subclavian artery (Fig. 2a) was found in 0.20% patients. A large difference in the frequency of tortuosities is evident from different studies. Yoo et al⁹ reported these abnormalities in 4.2% cases, Yokoyama et al¹⁰ in 5.6% cases, Burzotta et al⁶ in 5.9% cases and Khanra D et al⁸ in 2.29% cases. Some authors considered tortuosity as acquired abnormality and excluded it from analysis.⁷ The explanation for these variations is that there is no

universal definition of tortuous vessel and the frequency of tortuosities increases almost linearly with advancing age. They also noted it as a cause of access failure in 23.2% cases.⁸ In our study radial, brachial and subclavian tortuosity together count for 1.25% of the cases and was associated with 36.8% failure rate.

4.4. Radial, brachial, axillary and subclavian stenosis and hypoplastic radial artery

Burzotta et al⁶ defined radial stenosis as >50% radial artery narrowing and reported angiographic incidence of 0.4% in their study. Radial artery has a significantly smaller diameter, 2.69 ± 0.40 mm in men and 2.43 ± 0.38 mm in women, compared to 6 mm of femoral artery diameter.¹¹ In our study 0.4% patients were diagnosed to have radial artery stenosis and associated with failure to access in 100% cases. Brachial or axillary artery stenosis (Fig. 1b) and subclavian artery stenosis (Fig. 2d) were noted in 0.53% and 0.40% patients respectively. These were associated with access failure in 87% and 100% respectively. These atherosclerotic stenosis were most commonly encountered in the elderly population.

4.5. High origin of radial artery

High radial take-off, a remnant radial or slender hypoplastic radial artery existed in a few cases. Such a slender hypoplastic radial artery may be too small even for a 4 Fr catheter to negotiate. Catheter advancement through this artery is often painful and

associated with spasm and an increased risk of perforation. Ability to pass the guidewire easily but difficulty in advancing the catheter over the normal appearing course of the guidewire above elbow level can be a clue to the diagnosis of high origin of radial artery. We found this abnormality in 0.66% patients in our study. Access failure was seen in about 50% of these patients. Burzotta et al⁶ reported 3.4% patients with high radial artery origin. An Indian study has reported this as the most common abnormality but was not a cause of procedure failure.⁷ Another study reported it in 6.84% cases and it was associated with access failure in 17.9% patients.⁸ Evaluation of patients only with stuck catheter might have decreased the incidence in our study.

4.6. Arteria lusoria

As defined by Burzotta et al.⁶ Arteria lusoria is found when right subclavian artery arises from the horizontal part of the aortic arch at its junction with the descending aorta, mostly from distal and posterior region and less frequently from the proximal descending aorta. This abnormality is the commonest cause of inability to reach ascending aorta from right femoral artery access site after reaching the aorta (Fig. 2c), but It is not very common and found in about 0.1% of population. In our study it was found in only 5 patients.

5. Abnormal upper limb arterial anatomy and access failure

Previous studies have documented access failure rate of 1–10%.^{2,3} We found it in 4.4% patients in our patients. The difference in percentage of abnormal upper limb arterial anatomy and access failure can be explained with the help of following reasons.

1. Due to improved hardware, smaller sheath, and smaller catheter size there can be marked improvement in access rate.
2. Increasing the use of trans-radial access increases the operator related success rate. The access failure rate dropped from 10.3% to 1.7% with increasing operator experience.⁵
3. Increased and improved understanding of abnormal variation in upper limb artery anatomy increases the operator's maneuverability, leading to reduction in access failure rate.
4. Rather than congenital variation or abnormal anatomy of arteries, increasing age related atherosclerotic variation leading to tortuosity, luminal narrowing increases failure to access rate.

6. Limitations of our study

- 1) The study sample size was small.
- 2) Ours is an observational study and thus prone for observer bias.
- 3) Not every patient was evaluated for each and every possible variation in upper limb arterial system. Instead we chose to identify the patient with major variations that are clinically significant.
- 4) Only the right arm was evaluated and not the left arm.
- 5) Demographic variations within India were not taken into account in this study.
- 6) Only diagnostic CAG was done with the help of 5F catheter, use of larger sheath and catheter might have led to increased access failure rate.

7. Conclusion

In this angiographic study of abnormal right upper limb arterial anatomy in Indian population, significant anatomical abnormality was noticed in 5.3% population and transradial CAG failure rate was 64.17% in cases with abnormal upper limb arterial anatomy. We can conclude that abnormal upper limb arterial anatomy is the most common cause of access failure. Knowledge of such anatomical abnormality and taking proper and preemptive care can help to guide the procedure and avoid complications.

8. Practical Applications of our study

1. Prevalence of abnormal upper limb arterial anatomy in Indian population.
2. Evaluation of abnormal upper limb arterial anatomy as a cause of access failure

Funding sources

None.

Declaration of competing interest

None.

Acknowledgement

None.

References

1. Radner S. Thoracic aortography by catheterization from the radial artery; preliminary report of a new technique. *Acta Radiol.* 1948 Feb 28;29(2):178–180.
2. Mason PJ, Shah B, Tamis-Holland JE, et al. An update on radial artery access and best practices for transradial coronary angiography and intervention in acute coronary syndrome: a scientific statement from the American heart association. *Circ Cardiovasc Interv.* 2018;11(9), e000035.
3. Kiemeneij F, Laarman GJ, de Melker E. Transradial artery coronary angioplasty. *Am Heart J.* 1995 Jan;129(1):1–7.
4. Kiemeneij F, Laarman GJ, Odekerken D, et al. A randomized comparison of percutaneous transluminal coronary angioplasty by the radial, brachial and femoral approaches: the access study. *J Am Coll Cardiol.* 1997 May;29(6):1269–1275.
5. Louvard Y, Lefevre T, Morice MC. Radial approach: what about the learning curve? *Cathet Cardiovasc Diagn.* 1997 Dec;42(4):467–468.
6. Burzotta F, Trani C, De Vita M, Crea F. A new operative classification of both anatomic vascular variants and physiopathologic conditions affecting transradial cardiovascular procedures. *Int J Cardiol.* 2010 Nov 5;145(1):120–122.
7. Garg N, Sagar P, Kapoor A, et al. TCT-793 arterial anomalies of upper limb and its influence on transradial coronary procedures. *J Am Coll Cardiol.* 2019 Oct 1;74(13):B777.
8. Khanra D, Tiwari P, Sinha SK, et al. Radial anomalies in North Indian patients undergoing trans-radial catheterization: a prospective observational study (RAIN-TRAC study). *Heart India.* 2019 Dec 11;7:137–144.
9. Yoo B-S, Yoon J, Ko J-Y, et al. Anatomical consideration of the radial artery for transradial coronary procedures: arterial diameter, branching anomaly and vessel tortuosity. *Int J Cardiol.* 2005 Jun 8;101(3):421–427.
10. Yokoyama N, Takeshita S, Ochiai M, et al. Anatomic variations of the radial artery in patients undergoing transradial coronary intervention. *Catheter Cardiovasc Interv Off J Soc Card Angiogr Interv.* 2000 Apr;49(4):357–362.
11. Brzezinski M, Luisetti T, London MJ. Radial artery cannulation: a comprehensive review of recent anatomic and physiologic investigations. *Anesth Analg.* 2009 Dec;109(6):1763–1781.