



Published in final edited form as:

*Am J Med Case Rep.* 2020 ; 8(8): 253–256.

## Quadricuspid Aortic Valve: A Case Report and Review

Pramod Theetha Kariyanna<sup>1</sup>, Jonathan Francois<sup>1</sup>, Amog Jayarangaiah<sup>2</sup>, Yuvraj Singh Chowdhury<sup>1</sup>, Richard Grodman<sup>3</sup>, Moro O. Salifu<sup>1</sup>, Isabel M. McFarlane<sup>1,\*</sup>

<sup>1</sup>Department of Internal Medicine, State University of New York, Downstate Medical Center, Brooklyn NY 11203, USA

<sup>2</sup>Trinity School of Medicine, Ratho Mill, Ribishi, St. Vincent and Grenadines

<sup>3</sup>Richmond University Medical Center, Department of Cardiology, Staten Island, New York, United States

### Abstract

Quadricuspid aortic valve (QAV) is a rare congenital valvular abnormality with less than 200 cases reported to date. The first QAV was reported in 1862 by Balington. Clinical manifestations of patients with a QAV depend on the functional status of the QAV and the associated cardiac disorders. Most QAV are asymptomatic and are incidentally found. Severe aortic regurgitation and/or stenosis can develop overtime, requiring aortic valve replacement or repair. Transesophageal echocardiography is the preferred modality to diagnose QAV. We present a case of QAV which was incidentally diagnosed in a 43-year-old woman who presented with gastroenteritis.

### Keywords

Quadricuspid aortic valve; congenital variant of aortic valve; Hurwitz and Robert's classification

## 1. Introduction

Quadricuspid aortic valve (QAV) is a rare congenital valvular abnormality, with an estimated incidence of <0.05% [1,2]. The first case of QAV was reported in 1862 by Balington [3]. To our knowledge, there is less than 200 cases reported in the literature however, the actual incidence is likely underreported. Advances in cardiac imaging have permitted that more cases be reported. Most QAV are incidental findings. QAV is most often isolated but can be associated with other cardiac abnormalities and complicated with a progressive aortic valve regurgitation [4]. We present a case of QAV which was incidentally recognized in a 43-year-old female who presented with gastroenteritis.

## 2. Case Report

A 43-year-old female with a history of hypertension, diabetes and myomectomy (for a leiomyoma 14 years ago) presented to the emergency department after having over 20 episodes of non-bloody non-bilious vomiting for two days prior to presentation. She had not been able to either eat any food or take her medications. Her symptoms had begun 5-6 hours after eating a creamy potato salad in her cafeteria at work. Her family history was significant for diabetes in her mother and siblings and coronary artery disease on her father (myocardial infarction at the age of 68). Patient's two daughters had no medical issues. There had been no congenital abnormalities diagnosed on the patient or her family members. Her home medications included Amlodipine 10 mg PO daily, Atenolol 50 mg PO daily, Losartan- Hydrochlorothiazide 50 mg-12.5 mg daily, Insulin Apart 11 UI thrice daily, Insulin Degludec 34 IU SC daily, Gabapentin 300 mg thrice daily and ferrous sulphate 325 mg daily. On examination, blood pressure was 167/81 mm of Hg, heart rate 105 beats per min, temperature 98.9°F and was saturating 99% on room air. She was symptomatic for lightheadedness on standing. Examination revealed a fatigued woman with dry mucus membranes. She had a rapid regular pulse and no murmurs on auscultation. Her lungs were clear to auscultation and the abdomen was non tender to palpation. She had hyperactive bowel sounds on auscultation. Initial panel of lab tests revealed a troponin of 0.020 ng/ml (normal <0.015 ng/ml) and creatinine of 1.2 mg/dl (bloodwork at her primary physician's office a month ago had showed a creatinine of 0.8 mg/dl) (Table 1). She was diagnosed with staphylococcal toxin-mediated gastroenteritis and was treated with intravenous hydration and metoclopramide as needed to which she responded very well. Within 24 hours of her stay she was able to tolerate an oral diet and her acute kidney injury resolved. Her mild troponin elevation was diagnosed as a Type II elevation likely as a result of her acute kidney injury related troponin retention. Given her risk factors of hypertension and diabetes she also had an echocardiogram performed. The study demonstrated an incidental finding of a Hurwitz and Roberts classification type A QAV (Figure 1). There were no associated valvular abnormalities or dilatation of the aorta seen. She was discharged home with a plan to follow.

## 3. Discussion

The bicuspid aortic valve is the most common aortic valve abnormality (2% of general population) followed by unicuspid valve [5,6]. QAV is a rare congenital cardiac defect with an incidence of 0.008% and 0.043% in autopsies and echocardiographic studies, respectively [1,2,7]. The incidence in aortic valve surgery for pure aortic insufficiency is 1% [8]. QAV has a male predominance with a male: female ratio of 1.61: 1 [9]. Balington in 1862 was the first to report QAV [3].

During week 5 of embryogenesis, two mesenchymal ridges manifest in the cephalad portion of the truncus arteriosus. These ridges fuse and descend in a spiral fashion into the ventricles forming aorticopulmonary septum. At the junction of the conus and truncus three mesenchymal swellings appear and subsequently grow to form triangular-shaped valves. These swellings with their covering endothelium become excavated on their distal aspect to form the cusps. This process is usually completed by week 9 of gestation [2].

The embryological mechanism leading to QAV remains unknown, but a variety of mechanisms have been described. The suggested mechanisms are the following: an inflammatory episode leading to the separation of normal valve cushion, anomalous septation of the conotruncus, removal of one of the valve cushions and the division of one of the three mesenchymal ridges [2,10,11,12]. It is also possible that the formation of QAV may be related to an abnormality in the development of coronary arteries as the aortic valves develop right after the development of coronary arteries [13]. Furthermore, true QAV must be distinguished from Pseudo-QAV, which presents following infective endocarditis or rheumatic heart disease. The differentiating factor is the presence of corpus arantii on each cusp, found in congenital QAV [10].

Hurwitz and Roberts described the seven most common types of QAV, based on the size of the valve leaflets. The description and distribution of the types are found in Table 2 and Figure 2 [11]. Type A, B and C make 85% of all cases. A more recent classification has been published by Nakamura et al, based on the position of accessory cusps (Table 3) [14]. Based on these classifications our patient had Hurwitz type A QAV.

Clinical manifestations of QAV are unspecific - palpitations, dyspnea, fatigue, chest pain and features of congestive heart failure have all been reported, but young patients are mostly asymptomatic. Unequal stress distribution, fibrous thickening, and abnormal leaflet coaptation of QAV results in clinical manifestations, usually in the 5<sup>th</sup> or 6<sup>th</sup> decade of life [15]. The most common complication of QAV is aortic regurgitation in 75% of cases, aortic stenosis and aortic regurgitation in 9% of cases and normal functioning valve in only 16% of cases [15]. The prevalence of isolated aortic stenosis remains unclear, it is reported to be 0.7% or between 7% and 12% [7,16]. QAV usually presents as an isolated congenital anomaly, but it has been reported to be associated with other cardiac abnormalities in approximately 18-32% of cases, including nonobstructive cardiomyopathy [17], ventricular septal defect [11], supraaortic stenosis with left coronary artery atresia [18], pulmonary valve stenosis [19], Ehlers'-Danlos syndrome [20] and patent ductus arteriosus [21]. Infective endocarditis occurs in 1.4% of patients with QAV [11,22,23].

Echocardiography is the most used imaging modality to diagnose QAV. More than half of reported QAV were detected by echocardiography (51%), followed by surgery (22.6%), autopsy (15.6%) and aortography (6.5%) [24]. Transesophageal echocardiography is the preferred diagnostic tool of QAVs as it provides accurate assessment of valvular anatomy and visualizes correctly the coronary ostia [2,11].

QAV's management depends on symptoms and associated complications. Surgical indications are severe aortic stenosis, severe aortic regurgitation, or QAV valvular dysfunction associated with other clinically significant abnormalities [25,26]. The treatment of choice is generally aortic valve replacement. However, successful aortic valve repair by tricuspidization and bicuspidization techniques have been reported [26,27]. During the repair procedure, due precautions should be taken in regards to the location of the coronary ostia to avoid ostial obstruction at the time of valve replacement or repair [2,7]. Perioperative complications are rare and the survival rate after 5 and 10 years follow up, is 89.9% and

84.9% respectively [25]. This is the second QAV case report that we have encountered, the prior reported case was a Hurwitz and Roberts classification type B QAV.

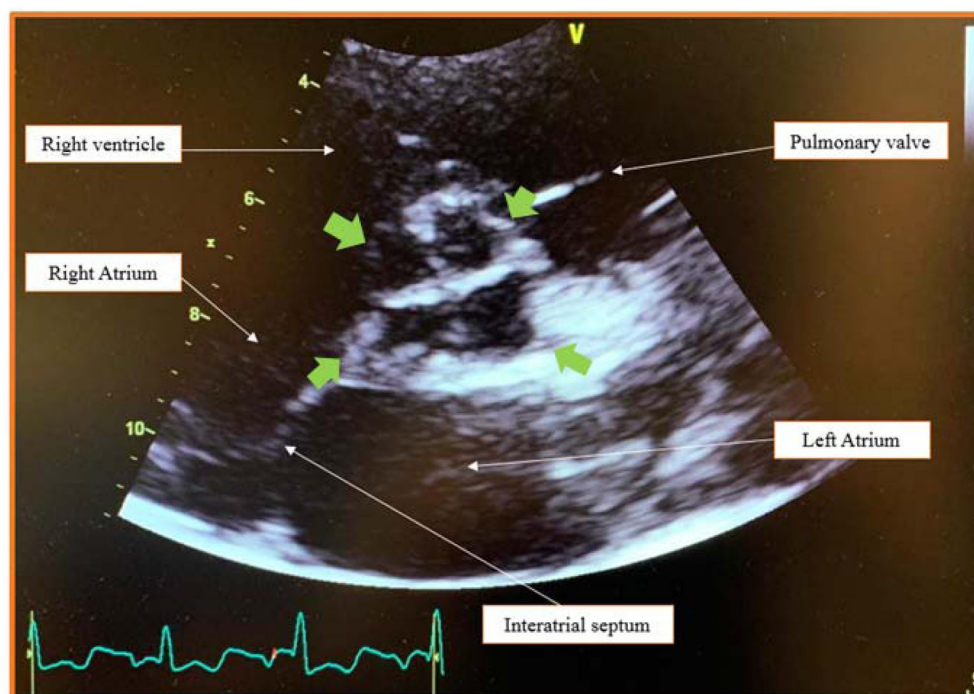
## Acknowledgements

This work is supported, in part, by the efforts of Dr. Moro O. Salifu M.D., M.P.H., M.B.A., M.A.C.P., Professor and Chairman of Medicine through NIH Grant No. S21MD012474.

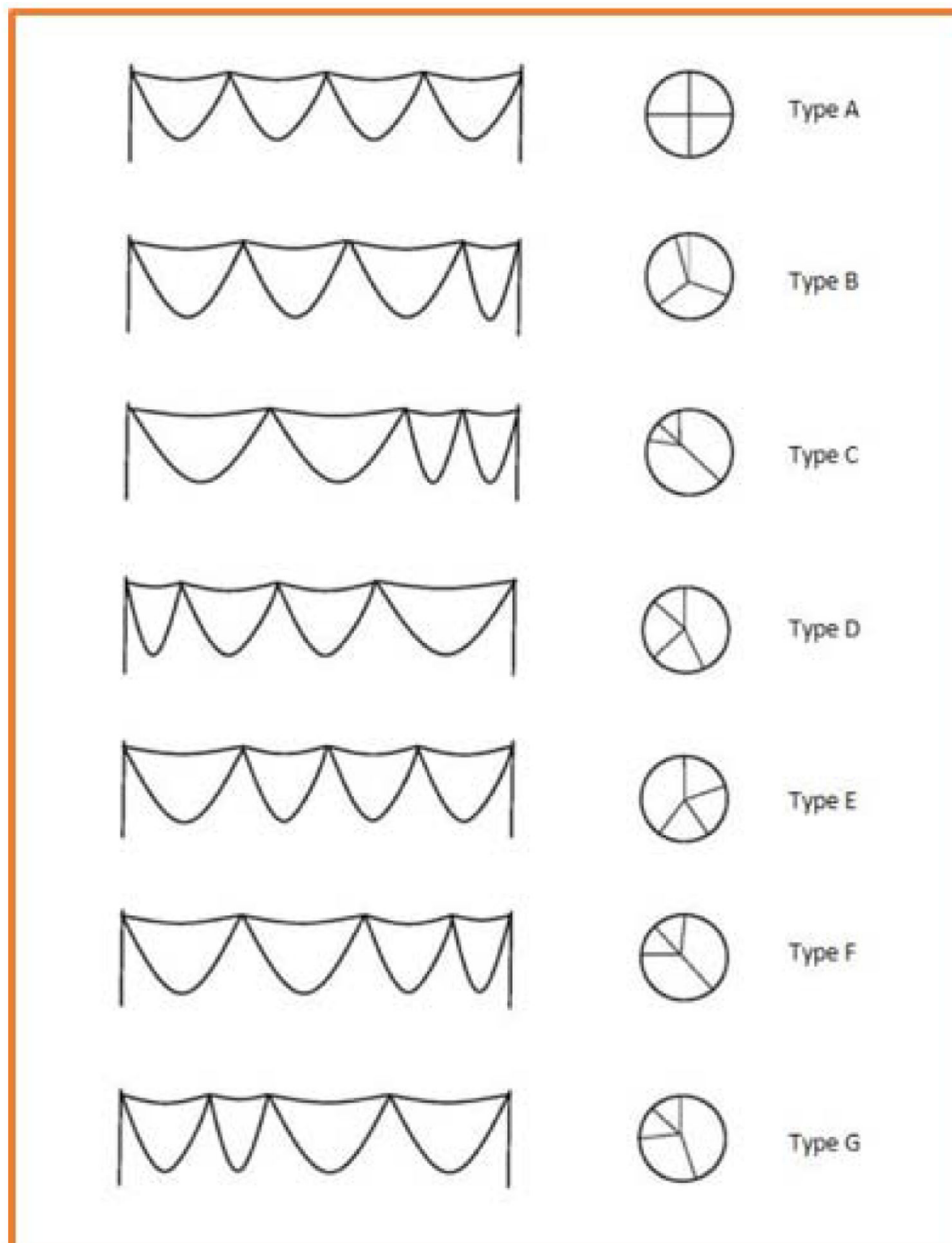
## References

- [1]. Feldman BJ, Khandheria BK, Warnes CA, Seward JB, Taylor CL, Tajik AJ. Incidence, description and functional assessment of isolated quadricuspid aortic valves. *Am J Cardiol* 1990; 65: 937–8. [PubMed: 2181849]
- [2]. Timperley J, Milner R, Marshall AJ, Gilbert TJ. Quadricuspid aortic valves. *Clin Cardiol* 2002; 25: 548–52. [PubMed: 12492123]
- [3]. James KB, Centorbi LK, Novoa R. Quadricuspid aortic valve. Case report and review of the literature. *Tex Heart Inst J* 1991; 18: 141–3. [PubMed: 15227499]
- [4]. Khan SK, Tamin SS, Araoz PA. Quadricuspid aortic valve by cardiac magnetic resonance imaging: a case report and review of the literature. *J Comput Assist Tomogr* 2011; 35: 637–41. [PubMed: 21926862]
- [5]. Roberts WC. The congenitally bicuspid aortic valve. A study of 85 autopsy cases. *Am J Cardiol* 1970; 26: 72–83. [PubMed: 5427836]
- [6]. Falcone MW, Roberts WC, Morrow AG, Perloff JK. Congenital aortic stenosis resulting from a unicommissural valve. Clinical and anatomic features in twenty-one adult patients. *Circulation* 1971; 44: 272–80. [PubMed: 5562562]
- [7]. Yotsumoto G, Iguro Y, Kinjo T, Matsumoto H, Masuda H, Sakata R. Congenital quadricuspid aortic valve: report of nine surgical cases. *Ann Thorac Cardiovasc Surg* 2003; 9: 134–7. [PubMed: 12732093]
- [8]. Olson LJ, Subramanian R, Edwards WD. Surgical pathology of pure aortic insufficiency: a study of 225 cases. *Mayo Clin Proc* 1984; 59: 835–41. [PubMed: 6503364]
- [9]. Tutarel O. The quadricuspid aortic valve: a comprehensive review. *J Heart Valve Dis* 2004; 13: 534–7. [PubMed: 15311857]
- [10]. Peretz DI, Changfoot GH, Gourlay RH. Four-cusped aortic valve with significant hemodynamic abnormality. *Am J Cardiol* 1969; 23: 291–3. [PubMed: 5772949]
- [11]. Hurwitz LE, Roberts WC. Quadricuspid semilunar valve. *Am J Cardiol* 1973; 31: 623–6. [PubMed: 4698133]
- [12]. Simonds J. Congenital malformation of aortic and pulmonary valves. *American Journal of the Medical Sciences* 1923; 166(4): 584–95.
- [13]. Bogers AJJC, Gittenberger-de Groot AC, Poelmann RE, Peault BM, Huysmans HA. Development of the origin of the coronary arteries, a matter of ingrowth or outgrowth? *Anatomy and Embryology* 1989; 180: 437–441. [PubMed: 2619086]
- [14]. Nakamura Y, Taniguchi I, Saiki M, Morimoto K, Yamaga T. Quadricuspid aortic valve associated with aortic stenosis and regurgitation. *Jpn J Thorac Cardiovasc Surg* 2001; 49: 714–6. [PubMed: 11808094]
- [15]. Tutarel O. Quadricuspid aortic valves and anomalies of the coronary arteries. *J Thorac Cardiovasc Surg* 2004; 127: 897; author reply 897.
- [16]. Mecozzi G, Pratali S, Milano A, Nardi C, Bortolotti U. Severe quadricuspid aortic valve stenosis after mediastinal irradiation. *J Thorac Cardiovasc Surg* 2003; 126: 1198–9. [PubMed: 14566274]
- [17]. Janssens U, Klues HG, Hanrath P. Congenital quadricuspid aortic valve anomaly associated with hypertrophic non-obstructive cardiomyopathy: a case report and review of the literature. *Heart* 1997; 78: 83–7. [PubMed: 9290407]

- [18]. Rosenkranz ER, Murphy DJ, Cosgrove DM. Surgical management of left coronary artery ostial atresia and supra-aortic stenosis. *The Annals of Thoracic Surgery* 1992; 54: 779–781. [PubMed: 1417243]
- [19]. Possati F, Calafiore AM, Di Giammarco G et al. [Quadricuspid aortic valve and pulmonary valve stenosis. A rare combination in the adult]. *Minerva Cardioangiologica* 1984; 32: 815–8. [PubMed: 6531087]
- [20]. Robicsek F, Sanger PW, Daugherty HK, Montgomery CC. Congenital quadricuspid aortic valve with displacement of the left coronary orifice. *Coll Works Cardiopulm Dis* 1968; 14: 87–90. [PubMed: 5712396]
- [21]. Seol SH, Kim U, Cho HJ, Kim DK, Kim DI, Kim DS. Quadricuspid aortic valve with patent ductus arteriosus. *Tex Heart Inst J* 2010; 37: 726–7. [PubMed: 21224958]
- [22]. Matsukawa T, Yoshii S, Hashimoto R, Muto S, Suzuki S, Ueno A. Quadricuspid aortic valve perforation resulting from bacterial endocarditis--2-D echo- and angiographic diagnosis and its surgical treatment. *Jpn Circ J* 1988; 52: 437–40. [PubMed: 3045360]
- [23]. Takeda N, Ohtaki E, Kasegawa H, Tobaru T, Sumiyoshi T. Infective endocarditis associated with quadricuspid aortic valve. *Jpn Heart J* 2003; 44: 441–5. [PubMed: 12825812]
- [24]. Godefroid O, Colles P, Vercauteren S, Louagie Y, Marchandise B. Quadricuspid aortic valve: a rare etiology of aortic regurgitation. *Eur J Echocardiogr* 2006; 7: 168–70. [PubMed: 15908279]
- [25]. Tsang MY, Abudiyab MM, Ammash NM et al. Quadricuspid Aortic Valve: Characteristics, Associated Structural Cardiovascular Abnormalities, and Clinical Outcomes. *Circulation* 2016; 133: 312–9. [PubMed: 26635401]
- [26]. Yuan SM. Quadricuspid Aortic Valve: A Comprehensive Review. *Braz J Cardiovasc Surg* 2016; 31: 454–460. [PubMed: 28076624]
- [27]. Luciani GB, Morjan M, Faggian G, Mazzucco A. Repair of quadricuspid aortic valve by bicuspidization: a novel technique. *Interact Cardiovasc Thorac Surg* 2010; 11: 348–50. [PubMed: 20573648]
- [28]. Kariyanna PT, Jayarangaiah A, Seshadri S, Adrah R, Sharma A, Rozin A. A rare case of quadricuspid aortic valve. *Research* 2016; 3: 1488.



**Figure 1.** Hurwitz and Roberts's classification type A valve noted in transthoracic echocardiography (Short axis aortic valve level). Arrows pointing at the four valves. Also Note The plus (+) shaped commissure



**Figure 2.**  
Hurwitz and Roberts classification of Quadricuspid Aortic Valves (below) [11]



**Table 1**

Laboratory data	Admission	Discharge	Units
WBC	11.7	9.5	k/ul
Hgb	13.8	12.4	g/dl
Platelets	416	365	k/ul
Na	135	139	mmol/L
K	3.5	3.8	mmol/L
Cl	102	104	mmol/L
HCO <sub>3</sub>	24	26	mmol/L
BUN	23	15	mg/dL
Creatinine	1.2	0.9	mg/dL
Glucose	187	148	mg/dL
Troponin	0.020	<0.015	ng/mL



**Table 2.**

Hurwitz and Robert's classification of Quadricuspid Aortic Valves [11]

QAV Type	Description	Prevalence of subtype
A	Four equal cusps	32%
B	Three equal cusps, one smaller cusps	41%
C	Two equal larger cusps, two equal smaller cusps	15%
D	One large, two intermediate and one small cusps	3%
E	Three equal cusps, one large cusps	2%
F	Two equal larger cusps, two equal smaller cusps	2%
G	Four unequal cusps	5%

Table 3.

Nakamura classification of Quadricuspid Aortic Valves [ 14]

QAV Type	Description
Type I	Supernumerary cusp lies between the left and right coronary cusps
Type II	Supernumerary cusp lies between the right and noncoronary cusps
Type III	Supernumerary cusp lies between the left and noncoronary cusps
Type IV	Supernumerary cusp cannot be identified as there are 2 equal sized smaller cusps