

New Surgical Technique: Bidirectional Forehead Narrowing and Eyebrow Lifting Using Regional Flap Mobility

Jae B. Kim, MD, PhD
Sang W. Kim, MD, PhD
Jae Y. Chung, MD, PhD

Background: We describe our experience with **bidirectional forehead narrowing** and **eyebrow lifting** (BiNaLi), a surgical technique we have been practicing for several years to correct facial esthetic issues of patients such as long forehead, high hairline, and low eyebrow level, which helps us achieve forehead height reduction with eyebrow lifting, using 1 incision line in a one-stage procedure.

Methods: We divided 576 patients who visited our institution between March 2014 and February 2019 into 4 groups: long forehead only (group I), low eyebrow level (groups II and IV), and M-shaped hairline (groups III and IV); BiNaLi operation was performed as appropriate for each group.

Results: The preoperative length of the median area of the forehead was 7.3 cm, and the mean postoperative change in the length of the same was 1.4 cm. The lateral forehead length was also measured for groups III and IV. The mean preoperative length was 7.7 cm, and the mean postoperative change in the length was 1.7 cm. Eyelid length was also measured for groups II and IV. The mean preoperative length was 0.7 cm, and the mean postoperative change in the length was 0.3 cm. More than 90% of the patients gave a score of 4.0 or higher for esthetic satisfaction.

Conclusions: We designed a BiNaLi technique to satisfy patients' facial esthetic needs using changes in flap movement direction, adjustment in the range of skin excision, and differences in flap dissection. A single operation can have various effects, including achieving forehead shortening, clear double-fold line through eyebrow lifting, and correction of a mild M-shaped hairline. (*Plast Reconstr Surg Glob Open* 2020;8:e2836; doi: 10.1097/GOX.0000000000002836; Published online 21 May 2020.)

INTRODUCTION

The standards for an attractive and beautiful face vary depending on age, ethnicity, race, sex, and personal preferences. In addition to the individual beauty of each facial region, such as eyes and nose, the overall facial proportion is also an important criterion in facial esthetics.^{1,2} A 1:1:1 ratio of hairline to eyebrow, eyebrow to nasal tip, and nasal tip to chin has long been considered an ideal vertical ratio for achieving a beautiful face (Fig. 1). However, because a smaller forehead compared with other areas of the face makes the face look smaller and younger, this has recently become a trend.^{3,4} Further,

the length of the eyelids is crucial in achieving an attractive face. Short eyelids lead to an unclear double-fold (DF) line, which undermines the clarity of the eyes, thus making the face less attractive. The forehead length and the eyelid length of the upper face play an important role in achieving an attractive face.

Younger adults in their 20s and 30s who congenitally have a long forehead, high hairline, and low eyebrows, or adults in their 40s and older with superior migration of the hairline and inferior migration of the eyebrow as a result of the aging process show a vast interest in forehead reduction surgery to achieve a more attractive face.^{5,6} The reason is presumably that esthetic standards now account for a greater percentage of their quality of life in today's modern society.

Extensive research has been conducted on this topic. Various surgical techniques have been developed for the forehead area, including direct forehead shortening surgical techniques using bicoronal incision and hairline incision, and eyebrow lift surgical techniques using endoscopy.^{5,7-9} However, there are limited studies

From the Lavian Plastic Surgery Center, Seoul, Korea.

Received for publication February 24, 2020; accepted March 19, 2020.

Copyright © 2020 The Authors. Published by Wolters Kluwer Health, Inc. on behalf of The American Society of Plastic Surgeons. This is an open-access article distributed under the terms of the [Creative Commons Attribution-Non Commercial-No Derivatives License 4.0 \(CCBY-NC-ND\)](#), where it is permissible to download and share the work provided it is properly cited. The work cannot be changed in any way or used commercially without permission from the journal.

DOI: 10.1097/GOX.0000000000002836

Disclosure: The authors have no financial interest to declare in relation to the content of this article.

METHODS AND SURGICAL TECHNIQUE

Five hundred seventy-six patients who visited our institution between March 2014 and February 2019 were divided into 4 groups according to the aforementioned criteria, and BiNaLi operation was performed as appropriate for each group (Table 1). Before surgery, the forehead length was checked by actually measuring the length from the hairline to the eyebrow and analyzed in consideration of the overall facial ratio. Surgery was only performed when the forehead to midface ratio was 0.9:1 or greater (Fig. 1). Patients with a history of surgery and procedure on the forehead area (eg, fat graft, filler, hair transplant) or with a disease on the forehead and scalp were excluded from the study because these factors could affect the displacement of the forehead and scalp flap. For measuring the length in the outcome analysis, a horizontal line was drawn at the highest point of the eyebrow as the reference line, and the length was measured from the median and temporal crest line for outcome analysis. For the eyelids, a vertical line was drawn from the center of the pupil while the patient opened the eyes comfortably and gazed at a far distance; the distance from the gray line to the eyebrows was analyzed (Fig. 1 and Table 2).

Preoperative Design

After confirming the range of skin excision in consideration of skin laxity using a finger gliding test, the skin excision amount was determined in consideration of patient’s need and face ratio. The incision line was drawn from 3mm behind the marked hairline to consider the transition zone for thin hair and thick hair in the hair line margin. A 1.2- to 1.5-cm-thick wave shape was used in consideration of the blood circulation and potential scarring (Fig. 2A). The design for the temporal crest lateral area varied depending on whether the M-shaped hairline required correction or not. About 3mm of additional skin excision was planned in the lateral area of the temporal crest compared with the medial area for groups III and IV to correct the M-shaped hairline (Fig. 2B). (An excision >3mm was not performed because it is highly likely to induce scar widening.)

Operative Procedure

Incision

Skin excision was performed via the trichophytic incision method using a #15 blade along the preplanned line to minimize damage to hair follicles.⁷ When excising skin including the subcutaneous fat layer, nerves visible to eye

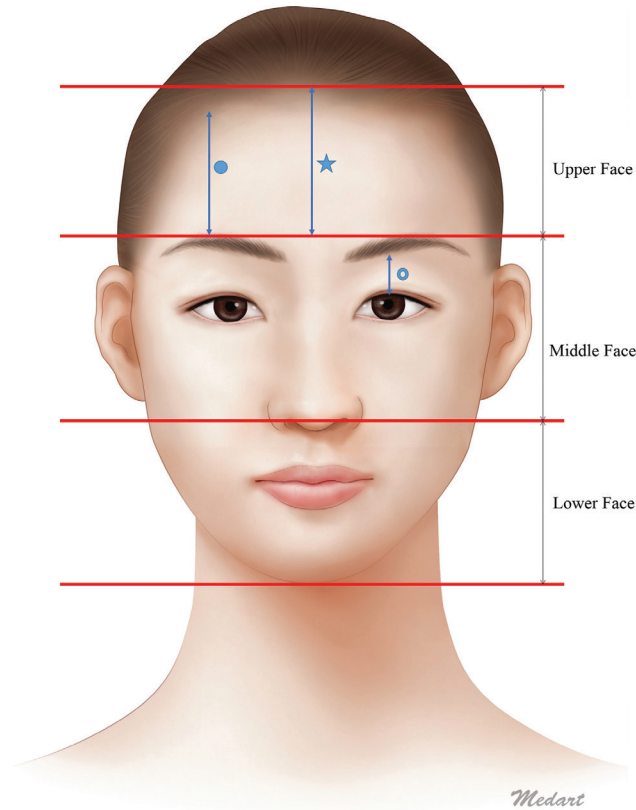


Fig. 1. Standard for dividing face ratio and point of measuring forehead length. Upper face: from hairline to eyebrow; middle face: from eyebrow to nasal tip; and lower face: from nasal tip to chin. Star indicates forehead median length; circle indicates forehead temporal crest line length; and double circle indicates eyelid length.

concurrently examining forehead shortening and eyebrow lifting.

We have researched such methods for forehead height reduction and eyebrow lifting in a one-stage operation using a single incision line by using the changes in flap movement direction, adjustment with the range of skin excision, and differences in flap dissection in consideration of patients’ hairlines and eyebrow levels. Here, we introduce the **bidirectional forehead narrowing and eyebrow lifting (BiNaLi)** technique, a surgical technique developed by our institution to promote concurrent forehead hairline correction and eyebrow lifting.

Table 1. Criteria for Dividing into 4 Groups and the Number of Patients in Each Group

	Group I	Group II	Group III	Group IV	Total
Patients in need of forehead narrowing	○	○	○	○	
Patients in need of eyebrow lifting		○		○	
Patients in need of M-shaped hair line correction			○	○	
Patients lost to follow-up before 5 mo	46	22	13	12	93
No. patients for outcome analysis	151	124	94	114	483
Total	197	146	107	126	576

Patients were divided into 4 groups according to the need of forehead shortening: group I, only forehead shortening without adjusting hairline shape or eyebrow level; group II, forehead shortening with elevation of eyebrows while maintaining hairline; group III, requiring correction of M-shape hairline and forehead shortening without adjusting eyebrow level; and group IV, require correction of M-shape hairline, elevation of eyebrow level, and forehead shortening. Circles (“○”) indicate what type of forehead shortening is involved; empty cells indicate “not applicable.”

Table 2. Demographic and Clinical Information of All Patients

Variables	Group I	Group II	Group III	Group IV	Total
No. patients	151	124	94	114	483
Sex					
Male	9	0	35	12	56
Female	142	124	59	102	427
Age (y)					
Mean	41.2	43.8	42.8	44.2	42.8
Range	19–52	24–69	21–51	27–74	19–74
Follow-up period (mo)					
Mean	7.8	9.1	8.4	13.4	9.6
Operative findings (cm)					
Preoperative median forehead length (all group)	7.2	7.2	7.0	7.4	7.3
Postoperative median forehead length (all group)	5.9	5.9	5.8	5.9	5.9
Shortened median forehead length (all group)	1.3	1.3	1.2	1.5	1.4
Preoperative lateral forehead length (group III, IV)	—	—	7.4	7.9	7.4
Postoperative lateral forehead length (group III, IV)	—	—	5.9	6.1	6.0
Shortened lateral forehead length (group III, IV)	—	—	1.5	1.8	1.7
Preoperative eyelid length (group II, IV)	—	0.8	—	0.7	0.7
Postoperative eyelid length (group II, IV)	—	1.0	—	1.0	1.0
Shortened eyelid length (group II, IV)	—	0.2	—	0.3	0.3

were preserved as much as possible to minimize sensory loss by preserving the sensory nerves in the frontal muscle belly of the bilateral area.^{10,11}

Flap Dissection

Following skin excision, a 1-cm dissection was made toward the cephalic direction in the subdermal layer to enhance the mobilization of the scalp flap. Then, galeatotomy was performed on a 4 × 1.5 cm area between the bilateral frontalis muscle belly to create a window to elevate the scalp flap and forehead flap (Fig. 2C). Flap dissection was performed via the window opening, and the direction of dissection varied according to the need of patient groups.

1. Group I: To advance the scalp flap in the caudal direction, the scalp flap was dissected in the subperiosteal layer in the cephalic direction from the incision line to beyond the occipital protuberance and temporal fusion area (Fig. 3A).
2. Group II: To advance the forehead flap in the cephalic direction for eyebrow elevation, a caudal direction dissection was performed on the medial area, with reference to the frontal muscle, in the subperiosteal layer to the orbital rim area. For forehead shortening, the lateral area, including the frontal muscle, was dissected toward the cephalic direction in the subperiosteal layer to advance the scalp flap in the caudal direction (Fig. 3B).

3. Group III: First, perform dissection with the group I method. Next, additional dissection was performed in the subgaleal and subperiosteal layers in the additional excision range of about 3 mm of the lateral area for the correction of the M-shaped hairline to reduce the tension. If the tension still remained, it was further lowered with a horizontal scoring incision on the periosteum (Fig. 3C).

4. Group IV: First, perform dissection with the group II method. Next, additional dissection was performed in the subgaleal and subperiosteal layers in the additional excision range of about 3 mm of the lateral area for the correction of the M-shaped hairline to reduce the tension. If the tension still remained, it was further lowered with a horizontal scoring incision on the periosteum (Fig. 3D).

Wound Closure

When advancing the forehead and scalp flap from the incision line, we confirmed that the flap was tension-free. If there was tension, additional dissection was performed in the subdermal layer. Thereafter, the wound was closed using 4-0 polydioxanone, 6-0 nylon.

Patient Satisfaction Survey

Outcome assessment was performed 6 months postoperatively. First, changes in the forehead length (median,

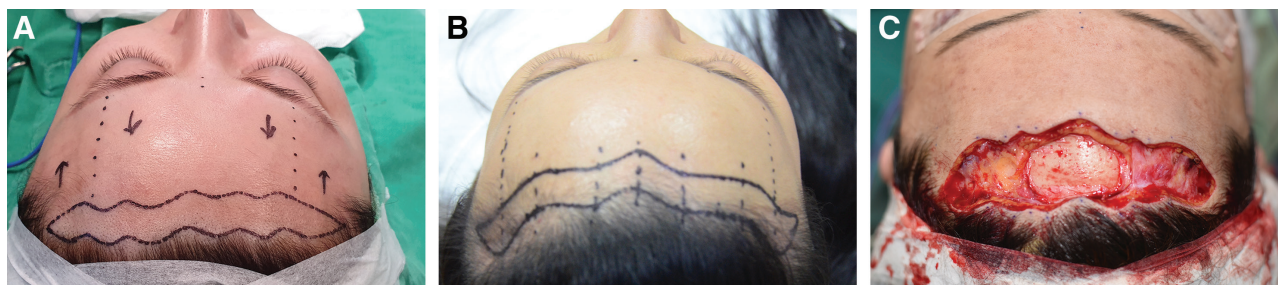


Fig. 2. Design and surgical techniques of bidirectional forehead shortening and eyebrow lifting. A, Design of group I for forehead shortening. B, Design of groups III and IV for forehead shortening and M-shape correction. C, Galeatotomy procedure performed on a 4 × 1.5 cm range.

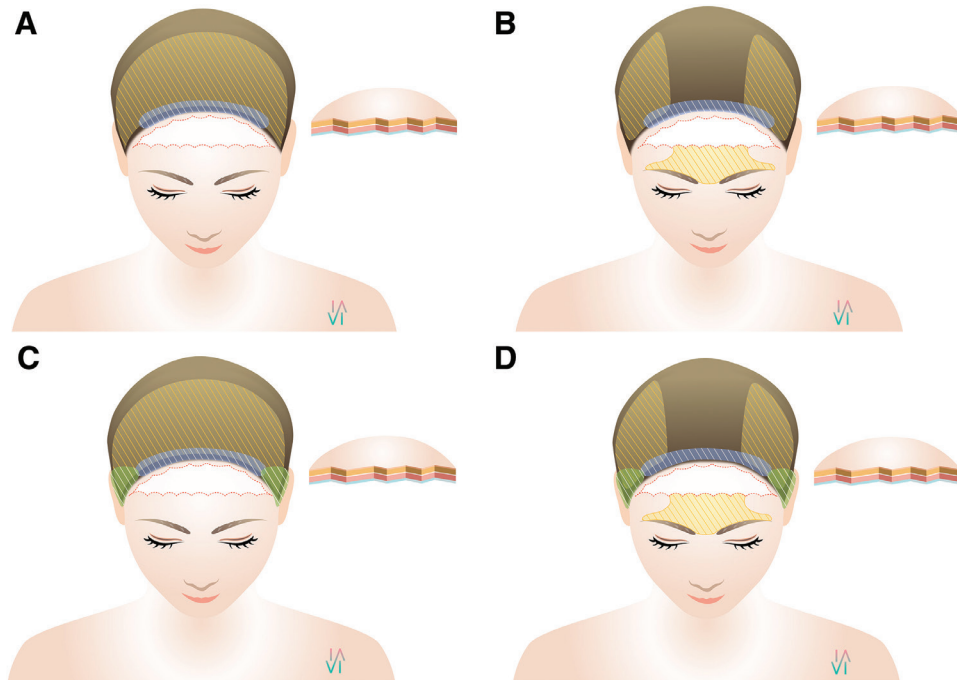


Fig. 3. Flap dissection layer and area: (A) group I, (B) group II, (C) group III, and (D) group IV. Yellow color indicates subperiosteal layer; green color indicates subgaleal layer; and blue color indicates subdermal layer.

lateral line), M-shaped hairline, and eyelid length were compared among the groups. A satisfaction survey was conducted, which included overall cosmetic satisfaction, satisfaction with scar, and complications pertaining to sensory loss as a result of forehead shortening (Table 3).

RESULTS

Of the 576 patients who visited our institution from March 2014 to February 2019, the outcomes of 483 patients (56 men, 427 women) were analyzed after excluding 93 patients who were lost to follow-up within 5 months. The mean age was 42.8 years (19–74 years), and the mean follow-up period was 9.6 months (6–27 months). The mean preoperative length of the median area of the forehead was 7.3 cm (5.9–8.2 cm), and the mean postoperative change in length was 1.4 cm (0.9–2.3 cm). Lateral forehead length was additionally measured for groups III and IV, which had an M-shaped hairline. The mean preoperative length was 7.7 cm (6.3–8.0 cm), and the mean postoperative change in the length was 1.7 cm (0.9–2.7 cm).

Eyelid length was measured for groups II and IV, which had eyebrow ptosis. The mean preoperative length was 0.7 cm, and the mean postoperative change in the length was 0.3 cm (Table 2).

In the patient satisfaction survey, >90% of the patients marked a satisfaction score of 4.0 or higher for items 1, 2, and 3 that asked about cosmetic satisfaction (Table 3). Regarding complications, >80% of the patients considered their scars to be acceptable. However, 5 patients who developed focal alopecia (2 in group III and 3 in group IV) and 34 patients who had scar widening and discoloration complained of discomfort from the scars. In 4 out of 5 patients who developed focal alopecia, the condition was observed in the lateral area, the area affected by an M-shaped hairline, since 1 month postoperatively. An injection of diluted triamcinolone was given on the site from the first month, and gradual improvements were observed from 5 months with good outcomes after 9 months. However, 1 patient underwent hair transplantation for correction of focal alopecia. Twenty-nine out of 34 patients who had scar

Table 3. Patient Satisfaction Survey

	Satisfaction Score				
	5	4	3	2	1
Cosmetic aspect (%)					
Did the forehead narrowing and change of facial ratio after surgery have anti-aging effects? (all groups)	38	56	3	0	1
Are you satisfied with the changes on your DF line achieved with eyebrow elevation after surgery? (group II, IV)	44	52	4	0	0
Are you satisfied with the changes in your M-shaped hairline after surgery? (group III, IV)	33	48	18	0	1
Complication aspect (%)					
How much are you satisfied with the scar from surgery?	32	49	12	2	5
How much are you satisfied with postoperative pain and sensory loss compared with that before surgery?	29	55	11	0	5

A 5-point score indicates complete satisfaction, and 1 point indicates complete dissatisfaction.

widening and discoloration underwent scar revision for correction at 6 months postoperatively, and the remaining 5 patients decided to be followed-up on observation upon patient's request. Regarding sensory loss, which is reported as a major complication of forehead shortening operation, patients complained about some discomfort generally in the median area of the forehead and scalp, but >95% of the patients did not have complaints of sensory loss at 6 months postoperatively.

Case 1: Group II

A 24-year-old female patient with a forehead median length of 6.7 cm showed concern that her eyelids above the DF line were looking thick and were unclear due to eyebrow ptosis. Based on the gliding test, we determined the excision range as 1.5 cm and performed the BiNaLi operation. Twelve months postoperatively, the forehead length was 5.5 cm, and the facial ratio was altered. The eyebrow level that had been low was elevated, leading to a clearer DF line with improvements in the thick-looking eyelids (Fig. 4).

Case 2: Group IV

A 26-year-old female patient with a forehead median length of 7.3 cm and a lateral forehead length of 7.8 cm with a mild M-shaped hairline was concerned that her eyebrows at a level lower than that of the orbital rim, making the DF line unclear and causing a triple-fold and sunken eye. Based on the gliding test, we determined the excision range as 1.5 cm and performed the BiNaLi operation. Five months after the surgery, the forehead median length was 5.9 cm, and the lateral area was 6.2 cm, confirming that the vertical length of the forehead was shortened, and that the M-shaped hairline was corrected. Further, the eyebrow

level was elevated, and as a result, the triple-fold and sunken eye was lost, and the DF line became clear (Fig. 5).

DISCUSSION

Persons with a high ratio of the forehead to the entire face and unclear DF lines due to low eyebrow levels look older than their actual age, which makes the face unattractive. Moreover, posterior migration of the forehead hairline or a congenitally formed M-shaped hairline aggravates these problems.¹²⁻¹⁴

To resolve these issues, we developed the BiNaLi technique. The patients were divided into 4 groups, and the technique enabled meeting the different needs of the groups by simply adjusting the dissection area and the direction of the flap.

If only forehead shortening is needed, as in group I, the scalp flap is dissected in the cephalic direction at the subperiosteal level and then moved in the caudal direction. If eyebrow lifting is needed, as in groups II and IV, the forehead flap is dissected at the subperiosteal level in the caudal direction to the orbital rim through an opening in the medial area of the frontal muscle and moved toward the cephalic direction. For the scalp flap, the lateral area of the frontal muscle is dissected in the cephalic direction at the subperiosteal level and moved toward the caudal direction. In these groups, cephalic movement of the forehead flap led to not only eyebrow lifting but also forehead shortening due to caudal movement of the undissected medial area of the scalp flap. Although the medial area of the scalp flap was not dissected, the laxity of tissues in the skin and fat layers superior to the galea layer enabled forehead shortening. If correction of an M-shaped hairline is required, as in groups III and IV, an additional 3 mm of dissection range was set during the design, and the flap

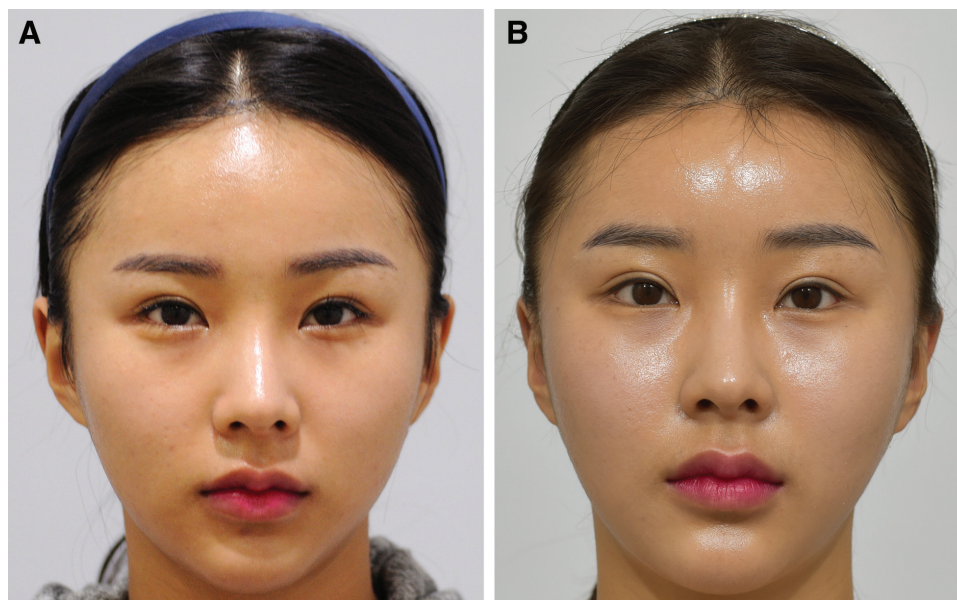

Fig. 4. Case 1: a 24-year-old female patient with a forehead median length of 6.7 cm and a facial ratio of 1:1:0.9 was concerned about her eyelids above the double-fold line looking thick and unclear due to eyebrow ptosis. A, Preoperative photograph. B, Photograph taken 12 months after the operation.

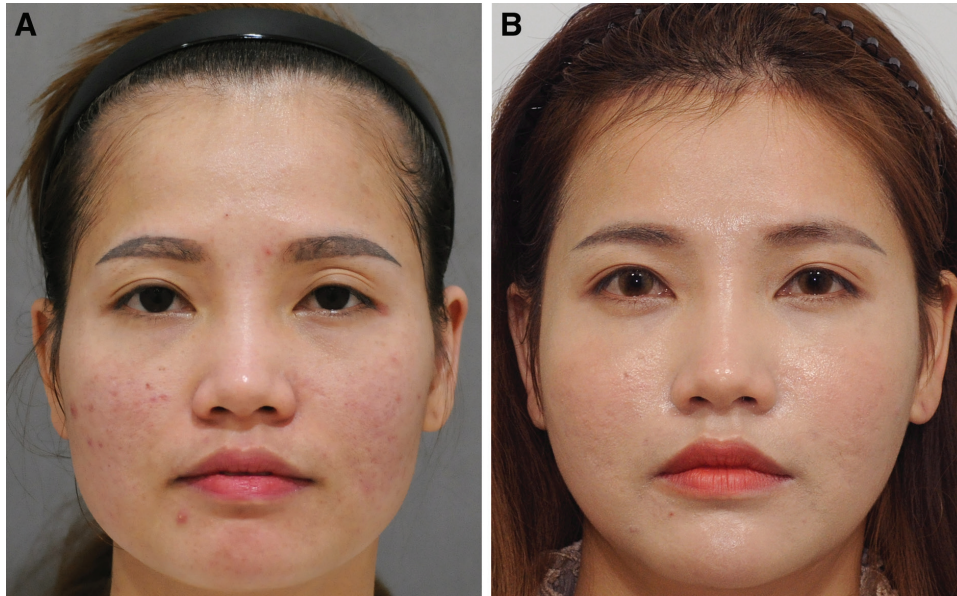


Fig. 5. Case 2: a 26-year-old female patient with a forehead median length of 7.3 cm and a lateral forehead length of 7.8 cm with a mild M-shaped hairline was concerned about her eyebrows being at a level lower than that of the orbital rim, which made the double-fold line unclear and caused a triple-fold and sunken eye. A, Preoperative photograph. B, Photograph 5 months after the operation.

was dissected toward the cephalic direction at the level of the subgaleal and subperiosteal layers to increase the mobility of the area and correct the hairline.

The BiNaLi technique differs in one critical way from the existing forehead surgical methods in that good outcomes can be achieved even without fixing the flap onto a bone. Indeed, in the early stages of BiNaLi, we also fixed the scalp flap on the desired site by using a screw or polydioxanone suture (PDS) 1-0 to that the moved scalp flap adheres at the desired site.¹⁵ However, after postoperatively palpating the site, we confirmed that using a screw or other fixation device does not play a marked role in the movement or fixation of the flap. Subsequently, we omitted the fixation of flap in our surgery. We believe that in contrast to an endoscopic eyebrow lift surgery, excision into the subcutaneous layer including the skin allows moving the flap so that it adheres to the site even without a fixation device. Ensuring sufficient mobility of the forehead flap by adequately releasing the periosteum of the orbital rim is crucial for eyebrow lifting, and we believe that adequately performing this step led to the satisfactory outcomes even without a fixation device. We proceeded with a forehead shortening surgery without fixing the flap and confirmed that the flap was maintained at the desired site and that the desired outcomes were achieved in the forehead area. In light of this finding, we further developed and advanced the BiNaLi technique based on an adjustment in the direction of the dissection, the flap movement, and the amount of skin excised by elevating the flap, which needs to be movable without altering the existing tissue and flap position.

However, the technique has a few limitations. First, the range of the lift was difficult to establish in patients who required eyebrow lifting (groups II and IV). Techniques

such as endoscopic and bicoronal eyebrow lifting are only focused on eyebrow lifting, and the range of lifting can be relatively accurately established on the basis of the movement of the forehead flap. However, the BiNaLi technique must take into consideration the bidirectional movements of the scalp and forehead flaps. Moreover, because the mobility of both flaps and the possible range of excision, which is determined by a gliding test, differ among patients, the range of eyebrow lifting is difficult to accurately establish. However, as shown in cases 1 and 2, it is still an adequate technique for resolving dissatisfaction with the DF line caused by a low eyebrow level (eg, unclear line, triple-fold). Hence, we believe that this limitation is not significant.

Furthermore, the amount of correction of an M-shaped hairline was also limited. Even if the mobility of the lateral portion of the scalp flap is increased by dissecting the lateral temporal area, the range of movement can only be increased to a certain extent. Thus, we explained to the patients that the BiNaLi technique is not suitable for making a correction of >5 mm and recommended hair transplantation in such cases. However, the technique was still effective in correcting M-shaped hairline to a certain extent, as proved by the satisfactory responses from >80% of the patients.

In addition, the problem of scarring remains. Surgical techniques without flap fixation to enable bidirectional flap movement, such as the BiNaLi technique, are highly likely to cause scar widening due to the bidirectional tension. Thus, we set the range of dissection as wide as possible to secure sufficient range of flap movement without tension, and the range was set even wider near the temporal crest. As a result, >80% of the patients were highly satisfied with their scars at 6 months after operation. However, in 6% of the cases ($n = 29$), scar revision had to be performed because of excessive scarring as a result of high tension despite checking with a

gliding test; revision was also necessary in patients in groups III and IV, who were more vulnerable to tension in the lateral forehead area. These cases improved within a period of 6 months after scar revision with the patients considering the resultant scar to be acceptable.

Finally, evaluation was only performed at the 6-month follow-up, and longer-term follow-up evaluation would have been ideal; however, >6-month follow-up is difficult depending on the nature of esthetic surgery. When patients experience no side effects or are satisfied with the outcome of the surgery, the number of patients who visit the clinic for follow-up after >6 months decreases dramatically. Thus, in consideration of the maturation period of the scar at the surgical site and the period during which most patients could be followed-up, the evaluation time point was compromised to be 6 months.

The BiNaLi surgical technique, which achieves desired outcomes by adjusting the direction of flap movement by varying the area of dissection, has the following benefits. First, it is less invasive than the existing surgeries for the forehead area because it does necessitate drilling into the bone or fixation of a screw. Further, owing to its simpler procedure, the surgery duration is shortened. In addition, several objectives can be attained through a single operation, including a youthful and attractive face through forehead shortening, a clear DF line through eyebrow lifting, and correction of a mild M-shaped hairline.

Jae Y. Chung, MD, PhD

Lavian Plastic Surgery Center
W Building, 3rd Floor
805 Seolleung-ro
Gangnam-gu
Seoul 06019, Korea

E-mail: jyoung.chung@gmail.com

ACKNOWLEDGMENT

The authors thank Editage (www.editage.co.kr) for English language editing.

PATIENT CONSENT STATEMENT

Patients provided written consent for the use of their images.

REFERENCES

1. Rhee SC, Dhong ES, Yoon ES. Photogrammetric facial analysis of attractive Korean entertainers. *Aesthetic Plast Surg.* 2009;33:167–174.
2. Pallett PM, Link S, Lee K. New “golden” ratios for facial beauty. *Vision Res.* 2010;50:149–154.
3. Park JH, You SH, Kim N. Frontal hairline lowering with hair transplantation in Asian women with high foreheads. *Int J Dermatol.* 2019;58:360–364.
4. Marten TJ. Hairline lowering during foreheadplasty. *Plast Reconstr Surg.* 1999;103:224–236.
5. Guyuron B, Rowe DJ. How to make a long forehead more aesthetic. *Aesthet Surg J.* 2008;28:46–50.
6. Spiegel JH. Scalp advancement and the pretrichial brow lift. *Facial Plast Surg.* 2018;34:145–149.
7. Owsley TG. Subcutaneous trichophytic forehead browlift: the case for an “open” approach. *J Oral Maxillofac Surg.* 2006;64:1133–1136.
8. Piovano L, D’Ettorre M. Forehead and brow rejuvenation: definition of a surgical algorithm. *Eur J Plast Surg.* 2017;41:285–292.
9. Kang MS, Park JW, Kang YW, et al. Shortening foreheadplasty; minimization of the tension of scalp flap. *Arch Aesthetic Plast Surg.* 2013;19:34–40.
10. Ahn YS, Park YY, Chang JW. Multiplane forehead shortening: sparing the frontalis muscle and supraorbital nerve. *Plast Reconstr Surg.* 2019;143:405–413.
11. Seery GE. Surgical anatomy of the scalp. *Dermatol Surg.* 2002;28:581–587.
12. Ramirez AL, Ende KH, Kabaker SS. Correction of the high female hairline. *Arch Facial Plast Surg.* 2009;11:84–90.
13. Guyuron B, Gatherwright J, Totonchi A, et al. Cessation of hairline recession following open forehead rejuvenation. *Plast Reconstr Surg.* 2014;133:1e–6e.
14. Park JH. Novel principles and techniques to create a natural design in female hairline correction surgery. *Plast Reconstr Surg Glob Open.* 2015;3:e589.
15. Min JH, Jung BK, Roh TS, et al. Hairline lowering surgery with bone tunneling suture fixation: effectiveness and safety in 91 patients. *Aesthet Surg J.* 2019;39:NP97–NP105.