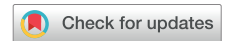

# Left Atrial Tachycardia and Third-Degree Atrioventricular Block in a Dog



Etienne Côté, DVM, M. Lynne O'Sullivan, DVM, DVSc,  
Deepmala Agarwal, BVSc, MVSc, PhD, and Roberto Santilli, DVM, PhD, *Charlottetown, Prince Edward Island, Canada; Varese, Italy; and Ithaca, New York*

## INTRODUCTION

Cardiac pacemaker implantation for therapeutic purposes in dogs was first reported in 1968,<sup>1</sup> and the transvenous approach has been standard practice since the 1990s.<sup>2</sup> A dog that had received a transvenous bipolar, ventricular paced, ventricular sensed, inhibited (VVI) pacemaker for syncopal third-degree atrioventricular (AV) block at age 2 years was reevaluated periodically. At age 6 years, a supraventricular tachycardia (SVT) was identified, and the arrhythmia was confined to the left atrium (LA), as confirmed with transthoracic two-dimensional (2D) and spectral Doppler echocardiography. An SVT confined to the LA has not been documented previously in dogs.

## CASE PRESENTATION

During a routine veterinary cardiology follow-up appointment, a 6-year-old female border terrier dog was found to have an SVT that was confined to the LA. When the dog was 2 years old, the dog's owner had reported seeing the dog collapse into a recumbent position and be unresponsive for 10-15 seconds after light exercise. These syncopal episodes then had recurred four times in 2 weeks. An electrocardiogram (ECG) had revealed third-degree AV block, with an atrial rate of 180/minute and ventricular and junctional escape complexes occurring at a rate of 40-60/minute. Although this was young for developing third-degree AV block (mean age in dogs,  $8 \pm 3$  years),<sup>3</sup> the arrhythmia had been considered idiopathic; there had been no evidence of systemic illness that could be associated with myocarditis on physical examination, complete blood count, serum biochemistry profile, or thoracic radiographs. Serologic titers for infectious diseases had not been performed given the lack of clinical signs to suggest such diseases and their very low prevalence in the dog's home area.

From the Department of Companion Animals, Atlantic Veterinary College, University of Prince Edward Island (E.C., L.O., D.A.), Charlottetown, Prince Edward Island, Canada; Clinica Veterinaria Malpensa (R.S.), Samarate, Varese, Italy; and College of Veterinary Medicine, Cornell University (R.S.), Ithaca, New York.

Keywords: Canine, Atrial dissociation, Supraventricular tachycardia, Veterinary, Cardiovascular

Special Note: CASE is grateful to Boehringer Ingelheim Animal Health for their generous support to cover the processing fee for this case report.

Conflicts of interest: The authors reported no actual or potential conflicts of interest relative to this document.

Correspondence: Dr. Etienne Côté, Department of Companion Animals, Atlantic Veterinary College, University of Prince Edward Island, 550 University Avenue, Charlottetown, Prince Edward Island C1A4P3, Canada (). (E-mail: [vetcardio@upei.ca](mailto:vetcardio@upei.ca)).

Copyright 2021 by the American Society of Echocardiography. Published by Elsevier Inc. This is an open access article under the CC BY-NC-ND license (<http://creativecommons.org/licenses/by-nc-nd/4.0/>).

2468-6441

<https://doi.org/10.1016/j.case.2021.12.001>

Echocardiography at first admission had revealed an increased indexed diastolic volume of the left ventricle (LV), a normal indexed systolic volume of the LV, an increased left ventricular ejection fraction, and an increased indexed LA diameter (Table 1).<sup>4</sup> The right atrium and ventricle subjectively had appeared to have similar changes, and all had been attributed to bradycardia-associated volume overload of cardiac chambers. Small amounts of diastolic but not systolic mitral and tricuspid regurgitation had been identified and attributed to third-degree AV block. The dog had been treated with transvenous VVI pacemaker implantation (Figure 1).

Recovery from pacemaker implantation had been uneventful, and no episode of collapse had occurred thereafter. Three months postoperatively, a follow-up echocardiogram had shown that the right-sided and LV changes had resolved but the indexed LA diameter had remained slightly increased. Progressive LA enlargement had been noted on every echocardiogram subsequent to the first recheck echocardiogram performed after pacemaker implantation. Two-dimensional echocardiography at 6 years of age revealed dyssynchronous motion of the mitral and tricuspid valves. There was a rapid fluttering motion of the mitral valve (Video 1) associated with supraventricular fibrillatory conduction (600/minute) on ECG<sup>5</sup> (Figure 2). A small amount of systolic mitral regurgitation was apparent on color flow Doppler interrogation (Video 2). By contrast, the motion of the tricuspid valve (Video 1) was consistent with respiratory sinus arrhythmia, third-degree AV block, and ventricular pacing. Trace tricuspid regurgitation was attributed to the presence of the pacemaker lead across the valve. On pulsed-wave Doppler interrogation of transmitral flow, high-frequency (600/minute), small (<0.2 m/sec) A waves were apparent, dissociated from E waves (Figure 3). Conversely, transtricuspid interrogation revealed no evidence of rapid A waves; rather, the amplitude and rate of the A waves were within physiologic limits for respiratory sinus arrhythmia in dogs. A lack of association between transtricuspid E and A waves likewise was consistent with AV dissociation, as expected with VVI pacing. Overall, these Doppler findings were congruent with 2D findings, and both were consistent with SVT confined to the LA (atrial dissociation), third-degree AV block, and ventricular pacing. The dog was not receiving any medications. The dog was active, without evidence of exercise intolerance. These findings were again present on a recheck evaluation performed 3 months later.

At the time of preparation of this report, the dog is 8.5 years old (6.5 years postop), active, and free of syncope and signs of congestive heart failure, despite marked LA enlargement and a dramatic increase in diastolic left ventricular volume when last evaluated (Table 1).

## DISCUSSION

Most dogs that require cardiac pacing have third-degree AV block or sinus node dysfunction.<sup>1,2</sup> The atrial rhythm in dogs with third-degree

## VIDEO HIGHLIGHTS

**Video 1:** Left apical four-chamber echocardiographic view showing a rapid fluttering motion of the mitral valve and normal motion of the tricuspid valve for a dog with third-degree AV block and VVI pacing. There is marked left atrial enlargement, normal 2D appearance of mitral and tricuspid valve structure, and subjectively normal right and left ventricular systolic function. The pacemaker lead occasionally is seen in the right ventricle. This video clip has been flipped horizontally after acquisition (mirror image from its original acquisition) to match the standard for this view.

**Video 2:** Left apical four-chamber echocardiographic view showing mild mitral regurgitation and other findings as noted in Video 1.

View the video content online at [www.cvcasejournal.com](http://www.cvcasejournal.com).

AV block that require permanent pacemaker implantation typically is sinus rhythm; atrial fibrillation and atrial standstill also have been reported in dogs with third-degree AV block.<sup>3</sup>

In this dog, spontaneous supraventricular fibrillatory conduction (a term indicating fibrillation that does not affect both atria)<sup>5</sup> was documented to have begun in association with cardiac chamber enlargement and several years after the onset of the dog's third-degree AV block. The echocardiogram demonstrated that atrial dissociation was present because the tachyarrhythmia involved only the LA: spectral Doppler interrogation identified changes consistent with the arrhythmia across the mitral valve but not across the tricuspid valve. Artifact was considered as a possible cause of the transmitral spectral Doppler signals but was considered unlikely given the repeatability of the finding and the similar rate of the A waves compared with both the ECG findings and the excursions of the mitral valve on the 2D echocardiogram.

The present case is unusual because SVTs seldom are reported to be confined to a single atrium in dogs. Cases have been reported of dogs with atrial standstill confined to the LA<sup>7</sup> and with atrial

dissociation during sinus rhythm.<sup>8</sup> Doppler echocardiographic profiles associated with such rhythm disturbances have been documented,<sup>7-9</sup> whereas changes like those noted in the present case have not. Atrial fibrillation that is confined to one atrium has been documented in humans, including with Doppler echocardiographic confirmation as in the present case.<sup>10</sup>

The cause of the dog's structural and functional cardiac changes remains unknown. It could have been suspected initially that this dog had an atrial myopathy. A breed-associated atrial myopathy has been described in the English springer spaniel<sup>11-13</sup>; an association between the border terrier breed and a specific type of atrial myopathy has not been demonstrated, but this could be partly because the border terrier is not a common breed (97th of 193 breeds listed in 2021).<sup>14</sup> An infectious cause was unlikely given the low prevalence in the dog's home area of infectious diseases that can affect the heart and lack of relevant abnormalities on physical examination, but myocarditis has been documented in a dog with third-degree AV block and concurrent atrial flutter.<sup>9</sup> The presence of LV dilation indicates a cardiac disease process that involved more than just the LA. Differential diagnoses include pacemaker syndrome and cardiomyopathy.

## CONCLUSION

In this dog with severe LA enlargement, an SVT developed and concurrent atrial dissociation caused the tachyarrhythmia to be confined to the LA. The dog's third-degree AV block provided a fortuitous protective mechanism to prevent the SVT from affecting the ventricles. This case illustrates the central role that echocardiography can play in the identification of abnormal mechanical atrial function and atrial dyssynchrony in dogs. This case also shows that animal models of human disease, which traditionally have revolved around changes induced in an experimental setting, can exist with spontaneously occurring cardiovascular disorders identified in veterinary practice.

## SUPPLEMENTARY DATA

Supplementary data related to this article can be found at <https://doi.org/10.1016/j.case.2021.12.001>.

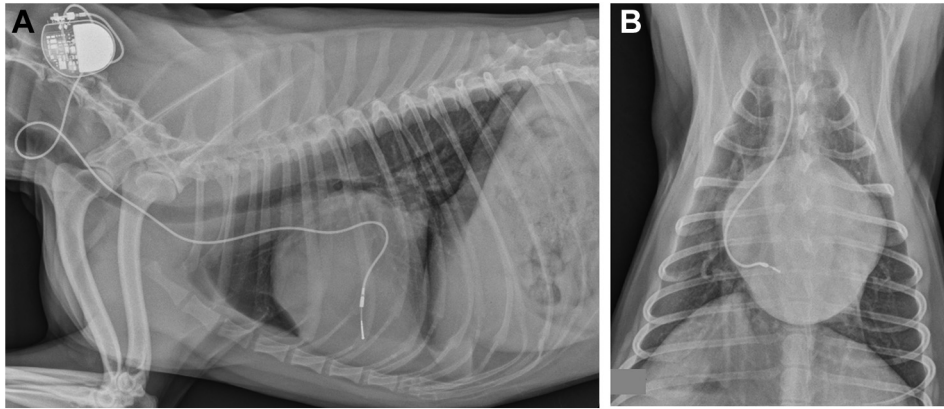
**Table 1** Echocardiographic measurements

	Dog's age, years						
	2*	2.25	2.5	4.5	5.5	6.5†	8.25
LVDd, mL/kg	3.75	2.41	3.4	3.65	3.61	3.44	7.2
95% ref int, mL/kg	1.45-2.99						
LVDs, mL/kg	0.62	0.61	1.04	1.21	1.43	1.87	1.86
95% ref int, mL/kg	0.4-1.35						
LVEF, %	83	75	69	67	60	46	74
95% ref int, %	46.7-80.7						
LAD-LAX/weight <sup>0.309</sup>	1.87	1.62	1.96	2.16	2.31	2.36	3.34
95% ref int, cm/kg <sup>0.309</sup>	1.19-1.56						

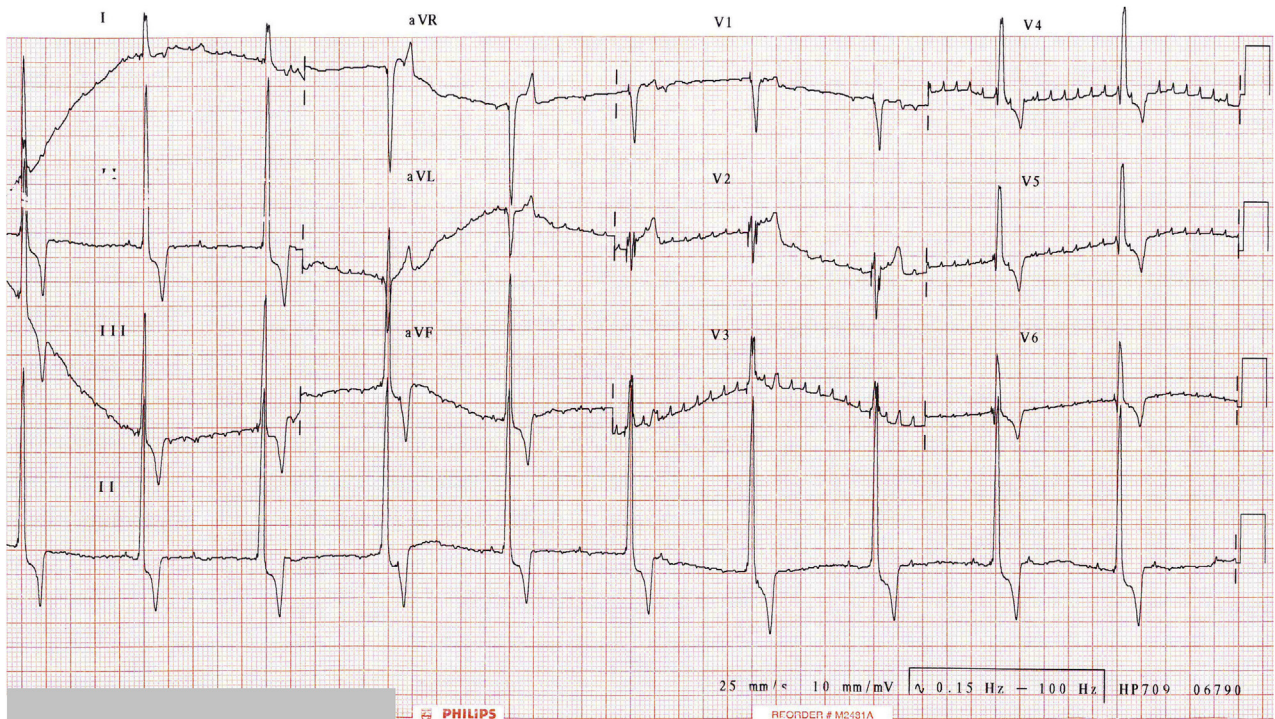
LAD-LAX, Left atrial diameter measured on the right parasternal long-axis four-chamber view; LVEF, left ventricular ejection fraction; LVDd, diastolic left ventricular volume, calculated using Simpson's rule and indexed to body weight; LVDs, systolic left ventricular volume, calculated using Simpson's rule and indexed to body weight; ref int, reference interval.

\*Initial evaluation due to syncopal third-degree AV block, immediately followed by pacemaker implantation.

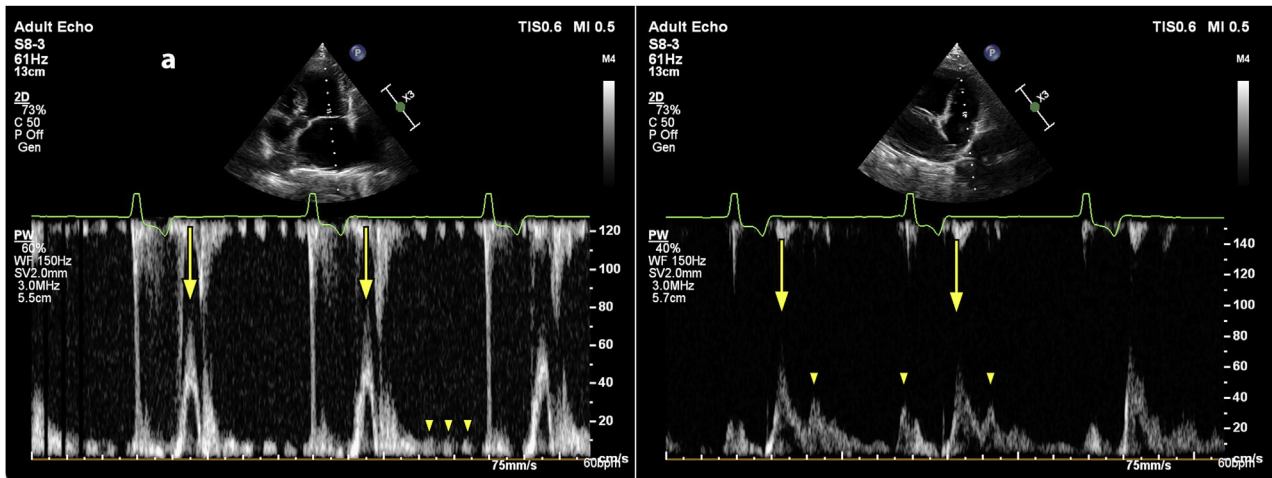
†Tachycardia diagnosed.



**Figure 1** Lateral (A) and posterior-anterior (dorsoventral) (B) thoracic radiographs obtained when SVT was identified (age 6.5 years), showing the typical appearance of a transvenous pacemaker in a dog. The lateral image is shown in standard veterinary orientation, with anterior (ventral) at the bottom of the image and superior (cranial) to the left. The lead enters the circulation through the right external jugular vein, the generator is placed in a subcutaneous pocket over the posterior neck (where it cannot be scratched at by a hind limb), and abundant redundancy is evident in the segment of the lead within the right atrium to reduce the risk of lead dislodgment from wide head excursions in a longer-necked species of patient. Evidence of marked left atrial enlargement is apparent on both projections.



**Figure 2** Twelve-lead ECG<sup>6</sup> showing supraventricular fibrillatory conduction (600/minute) in a dog with third-degree AV block and bipolar VVI pacing at 60/minute. P waves are visible in leads II and III (rate, 120/minute); 25 mm/sec, 1 cm = 1 mV.



**Figure 3** Pulsed-wave Doppler interrogation of transmittal **(A)** (left apical five-chamber view) and transtricuspid **(B)** (left cranial long-axis view) flow. **(A)** Transmittal E waves (arrows) consistent with ventricular pacing at 60 beats/minute, and high-frequency, low-amplitude A waves (arrowheads, 600/minute) are apparent. **(B)** Transtricuspid E (arrows) and A (arrowheads) waves are present, indicating AV dissociation; there is no evidence of fibrillatory conduction.

## REFERENCES

- Buchanan JW. First pacemaker in a dog: a historical note. *J Vet Intern Med* 2003;17:713-4.
- Sisson D, Thomas WP, Woodfield J, Pion PD, Luethy M, DeLellis LA. Permanent transvenous pacemaker implantation in forty dogs. *J Vet Intern Med* 1991;5:322-31.
- Santilli RA, Porteiro Vázquez DM, Vezzosi T, Perego M. Long-term intrinsic rhythm evaluation in dogs with atrioventricular block. *J Vet Intern Med* 2016;30:58-62.
- Visser LC, Ciccozzi MM, Sintov DJ, Sharpe AN. Echocardiographic quantitation of left heart size and function in 122 healthy dogs: a prospective study proposing reference intervals and assessing repeatability. *J Vet Intern Med* 2019;33:1909-20.
- Saoudi N, Cosio F, Waldo AE, Chen SA, Iesaka Y, Lesh M, et al. A classification of atrial flutter and regular atrial tachycardia according to electrophysiological mechanisms and anatomical bases. A statement from a Joint Expert Group from the Working Group of Arrhythmias of the European Society of Cardiology and the North American Society of Pacing and Electrophysiology. *Eur Heart J* 2001;22:1162-82.
- Santilli RA, Porteiro Vázquez DM, Gerou-Ferriani M, Lombardo SF, Perego M. Development and assessment of a novel precordial lead system for accurate detection of right atrial and ventricular depolarization in dogs with various thoracic conformations. *Am J Vet Res* 2019;80:358-68.
- Wesselowski S, Abbott J, Borgarelli M, Tursi M. Presumptive partial atrial standstill secondary to atrial cardiomyopathy in a greyhound. *J Vet Cardiol* 2017;19:276-82.
- Scollan K, Bulmer BJ, Heaney AM. Electrocardiographic and echocardiographic evidence of atrial dissociation. *J Vet Cardiol* 2008;10:53-5.
- Baron Toaldo M, Romito G, Cipone M, Diana A, Tursi M. Electrocardiographic, echocardiographic, and left atrial strain imaging features of a dog with atrial flutter and third-degree atrioventricular block. *J Vet Cardiol* 2017;19:462-8.
- Ker J. Unilateral atrial fibrillation—how common is atrial divorce? *J R Coll Physicians Edinb* 2017;47:135-7.
- Holland CT, Canfield PJ, Watson AD, Allan GS. Dyserythropoiesis, polymyopathy and cardiac disease in three related English springer spaniels. *J Vet Intern Med* 1991;5:151-9.
- Lai SR. Atrioventricular muscular dystrophy in a 5-month-old English springer spaniel. *Can Vet J* 2009;50:1286-7.
- Fonfara S, Loureiro JF, Swift S, James RA, Pereira YM, Lopez-Alvarez, et al. English springer spaniels with significant bradyarrhythmias: presentation, troponin I and follow-up after pacemaker implantation. *J Small An Pract* 2010;51:155-61.
- American Kennel Club. The most popular dog breeds of 2020. Available at: <https://www.akc.org/expert-advice/dog-breeds/2020-popular-breeds-2019/>. Accessed June 11, 2021.