

## Lumen-apposing metal stent gastrojejunostomy for biliary drainage of an obstructive biliodigestive anastomosis

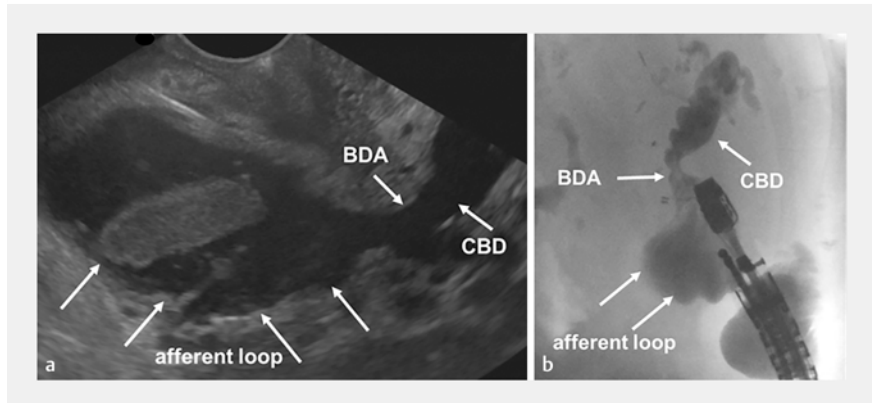
OPEN  
ACCESS

A 68-year-old woman with pancreatic adenocarcinoma was referred to our department with jaundice and poor general condition. Surgical exploration 2 years previously had revealed an unresectable pancreatic head tumor and a biliodigestive anastomosis had been created. At presentation, the patient was receiving third-line chemotherapy and had locally advanced disease and peritoneal carcinomatosis. A computed tomography scan showed progressive disease, with obstruction of the biliodigestive anastomosis and consequent dilatation.

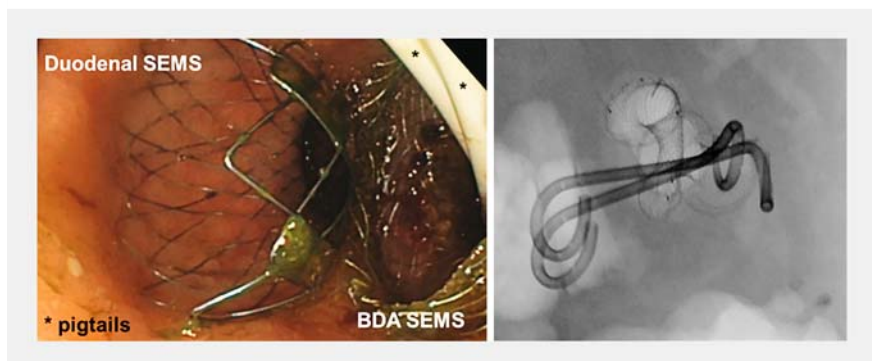
As the established endoscopic and surgical interventions were limited, the patient underwent transgastric endoscopic ultrasound-guided placement of a lumen-apposing metal stent (LAMS) into the afferent jejunal loop (► Fig. 1 a). The correct positioning of the needle in the biliodigestive anastomosis was verified with contrast-enhanced radiography (► Fig. 1 b). Thereafter, the LAMS was implanted under fluoroscopic guidance. Because of the duodenal obstruction, two plastic pigtail stents (10Fr, 11-cm long) were placed through the LAMS to avoid obstruction and to secure the access before an uncovered self-expandable metal stent (SEMS) was positioned in the pars descendens duodeni (► Fig. 2 a). Neither stent interfered with the other and they were successfully located beside each other in the antrum (► Fig. 2; ► Video 1).

After the intervention, the patient's cholestatic parameters decreased substantially and, following her discharge, chemotherapy was initially readministered in the outpatient setting. However, 2 months later, the patient's general condition deteriorated and, after receiving best-supportive care, she died 2 months later.

This case report demonstrates an alternative route for biliary drainage in palliative patients with cholestasis caused by ste-



► Fig. 1 Appearance before the procedure showing: a on endoscopic ultrasonography, the biliodigestive anastomosis (BDA), dilated common bile duct (CBD), and afferent loop; b on fluoroscopy, the distribution of the contrast agent within the dilated BDA and CBD caused by a malignant stenosis of the afferent loop.



► Fig. 2 Final position of the stents on: a gastroscopic image showing the duodenal and biliodigestive anastomosis (BDA) self-expandable metal stents (SEMSs) and the two plastic pigtail stents (\*) that were passed through the lumen-apposing metal stent to secure the access and outflow in case there was pressure from the duodenal SEMS; b fluoroscopic overview.

nosis of a malignant biliodigestive anastomosis.

Endoscopy\_UCTN\_Code\_TTT\_1AS\_2AD

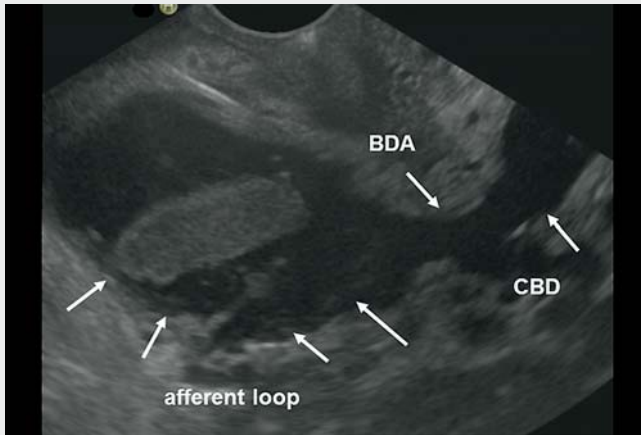
### Competing interests

The authors declare that they have no conflict of interest.

### The authors

Moritz Haase, Jonas Rosendahl, Sebastian Krug

Department for Internal Medicine I, Martin-Luther University Halle/Wittenberg, Halle, Germany



**Video 1** Lumen-apposing metal stent gastrojejunostomy is performed for biliary drainage of an obstructive biliodigestive anastomosis.

## ENDOSCOPY E-VIDEOS

<https://eref.thieme.de/e-videos>



*Endoscopy E-Videos* is an open access online section, reporting on interesting cases and new techniques in gastroenterological endoscopy. All papers include a high quality video and all contributions are freely accessible online. Processing charges apply (currently EUR 375), discounts and waivers acc. to HINARI are available.

This section has its own submission website at <https://mc.manuscriptcentral.com/e-videos>

### Corresponding author

**Sebastian Krug, MD**

Department for Internal Medicine I, Ernst-Grube-Straße 40, 06120 Halle (Saale), Germany  
moritz.haase@uk-halle.de

### Bibliography

Endoscopy 2023; 55: E336–E337

DOI 10.1055/a-1986-7377

ISSN 0013-726X

published online 19.12.2022

© 2022. The Author(s).

This is an open access article published by Thieme under the terms of the Creative Commons Attribution-NonDerivative-NonCommercial License, permitting copying and reproduction so long as the original work is given appropriate credit. Contents may not be used for commercial purposes, or adapted, remixed, transformed or built upon. (<https://creativecommons.org/licenses/by-nc-nd/4.0/>)

Georg Thieme Verlag KG, Rüdigerstraße 14, 70469 Stuttgart, Germany

