

Available online at [www.sciencedirect.com](http://www.sciencedirect.com)

ScienceDirect

journal homepage: [www.elsevier.com/locate/radcr](http://www.elsevier.com/locate/radcr)

## Case report

# A case report describing the successful separation of ischiopagus tetrapus conjoined twins in Vietnam ☆☆☆

Truong Quang Dinh, MD, PhD<sup>a,1,\*</sup>, Nguyen Minh Duc, MD, MSc<sup>b,c,d,1,\*</sup>,  
Ho Tan Thanh Binh, MD, PhD<sup>e,1</sup>, Ta-Thi Thuy Hang, MD<sup>f</sup>, Nguyen-Thi Cam Xuyen, MD<sup>a</sup>,  
Thieu-Thi Tra My, MD<sup>b</sup>, Mai Tan Lien Bang, MD<sup>d</sup>, Pham Minh Thong, MD, PhD<sup>b</sup>

<sup>a</sup> Department of General Surgery, Ho Chi Minh City Children's Hospital, Ho Chi Minh City, Vietnam

<sup>b</sup> Department of Radiology, Hanoi Medical University, Ha Noi, Viet Nam

<sup>c</sup> Department of Radiology, Pham Ngoc Thach University of Medicine, Ho Chi Minh City, Viet Nam

<sup>d</sup> Department of Radiology, Children's Hospital 2, Ho Chi Minh City, Viet Nam

<sup>e</sup> Department of Neonatal Intensive Care, Ho Chi Minh City Children's Hospital, Ho Chi Minh City, Vietnam

<sup>f</sup> Department of Anesthesiology, Ho Chi Minh City Children's Hospital, Ho Chi Minh City, Vietnam

## ARTICLE INFO

## Article history:

Received 12 June 2021

Revised 14 June 2021

Accepted 16 June 2021

## Keywords:

Ischiopagus tetrapus

Conjoined twins

Twin separation surgery

## ABSTRACT

Ischiopagus conjoined twinning is a rare congenital defect. The surgical separation of conjoined twins is difficult because of the complex anatomy and physiology. Careful preoperative assessment, planning, and effective surgical teams are critically important for achieving a good outcome. We describe the successful separation of ischiopagus tetrapus conjoined twins as a representative case demonstrating the growth of pediatric surgery in southern Vietnam.

© 2021 The Authors. Published by Elsevier Inc. on behalf of University of Washington.

This is an open access article under the CC BY-NC-ND license

(<http://creativecommons.org/licenses/by-nc-nd/4.0/>)

## Introduction

Conjoined twins (also known as Siamese twins) are the result of a rare medical phenomenon. The incidence of conjoined twinning is estimated at 1 in 50,000–100,000 births, and approximately 60% of cases are either stillborn or die early

after birth [1]. Conjoined twins are classified depending on the anatomical site at which they are joined [2], with only 6%–11% of all conjoined twins classified as the ischiopagus type [3]. Ischiopagus twins are joined at the pelvis and share lower gastrointestinal systems, genitals, and urinary

☆ Funding: Self-financed.

☆☆ Competing Interests: The authors do not report any conflicts of interest.

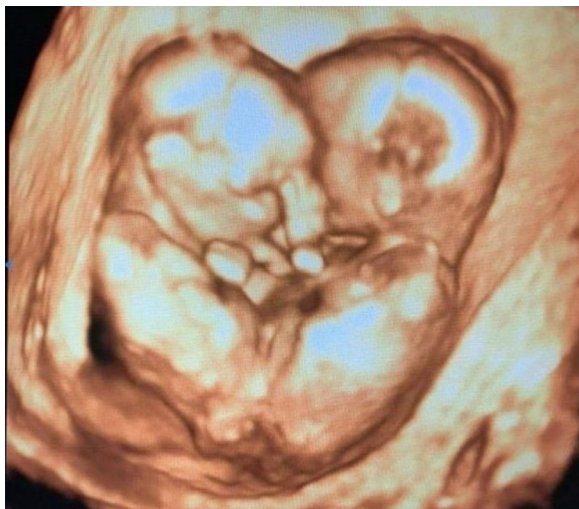\* Corresponding authors.

E-mail addresses: [truongdinhnd2@gmail.com](mailto:truongdinhnd2@gmail.com) (T.Q. Dinh), [bsnguyenminhdudc@pnt.edu.vn](mailto:bsnguyenminhdudc@pnt.edu.vn) (N.M. Duc).

<sup>1</sup> These authors contributed equally to this article as co-first authors.

<https://doi.org/10.1016/j.radcr.2021.06.048>

1930-0433/© 2021 The Authors. Published by Elsevier Inc. on behalf of University of Washington. This is an open access article under the CC BY-NC-ND license (<http://creativecommons.org/licenses/by-nc-nd/4.0/>)



**Fig. 1 – Conjoined twins viewed on 3D prenatal ultrasound.**

tracts, and the genitourinary system is often doubled in these types of twins [4]. Ischiopagus twins can be further classified depending on the number of legs that develop, as tetrapus (four), tripus (three), or bipus (two), among which tetrapus twins are the most common [2]. The first separation of ischiopagus tetrapus conjoined twins was reported in 1966 by Eades and Thomas [4]; since then, a few cases have been reported around the world, with only one case reported in Vietnam. We present our experience with the preoperative evaluation, surgical planning, and postoperative treatment of a pair of female ischiopagus tetrapus conjoined twins who were separated at the City Children's Hospital in Vietnam.

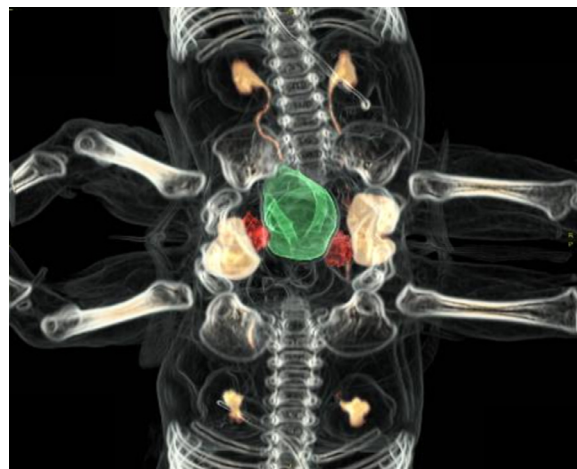### Case report

A pair of fused twin girls were born by cesarean delivery at 33 weeks of gestation to a healthy gravida 1, para 1 woman. At the gestational age of 16 weeks, a monochorionic, monoamniotic, conjoined twin pregnancy was discovered on sonography (Fig. 1). At birth, the twins were face-to-face with fusion in the lower halves of the bodies at an angle of 10 degrees. Each twin was normal above the fused area, starting at the level of the umbilicus. Each twin had two normal-looking lower limbs. The total birth weight was 3,200 g. The twins were designated as “Twin 1” and “Twin 2” (Fig. 2).

The twins were transferred to our intensive care unit when they were 1 day old. Both developed respiratory distress syndrome shortly after birth and were treated with surfactant and mechanical ventilation for four days. Physical examination revealed that both twins were approximately equal in size. Twin 1 had an imperforate anus, a duplicated vagina, and an external urethral orifice. Twin 2 had an anus, a duplicated vagina, and a urethral opening.



**Fig. 2 – Twelve-month-old ischiopagus tetrapus conjoined twins.**



**Fig. 3 – CT view of the ischiopagus conjoined twins (the rectum was green, the bladders was next to the rectum and orange in color).**

### Preoperative evaluation

The twins had normal and separate stomachs but shared a portion of the small intestines and a single colon. The small intestines in the twins joined at the terminal ileum and entered the common colon, which was connected to the anus in Twin 2. Intravenous pyelograms, retrograde cystograms, computed tomography angiography (CTA) (Fig. 3), and magnetic resonance imaging (MRI) revealed four kidneys, with two in each child, and two bladders. However, each girl presented with 2 ureters, 1 ureter that drained to her own bladder, and one that drained into the contralateral bladder. No communication existed between the two bladders. All kidneys showed satisfactory function and appeared normal in size and shape but vesicoureteral reflux was noted in the left side to twin 1. Two uteruses, four ovaries, and uterine tubes were observed in the common pelvis. Both twins had uterus didelphys with two vaginas.

About blood supply, we used abdomen-pelvis CTA to evaluate. In the first time, we used an injection of contrast material into both twin at the same time under general anaesthesia. The results showed that the common pelvic organs were supplied by both twins and there was the complex cross circulation between the twins. In the second time, we performed CTA for each twin individually. The individual intestines were supplied by the superior mesenteric artery (SMA) of each twin,

but the shared intestine was supplied by the SMA, the inferior mesenteric artery, and the middle sacral artery that arised from both twins. With the genitourinary organs, twin 2 supplied blood equally to both the left and right sides of the common pelvis, twin 1 supplied primarily blood to its right side.

The bony pelvis formed a ring and joined with the normal lower extremities. Each normal lower extremity was controlled by the child on that side. The spinal columns were complete and separate, and the twins featured two sacra and two symphyses pubis.

### Preoperative course and management

Before the operation, several conferences were conducted. All individuals involved in the operation attended these conferences, and a rehearsal, using a model, was performed two days before the actual separation.

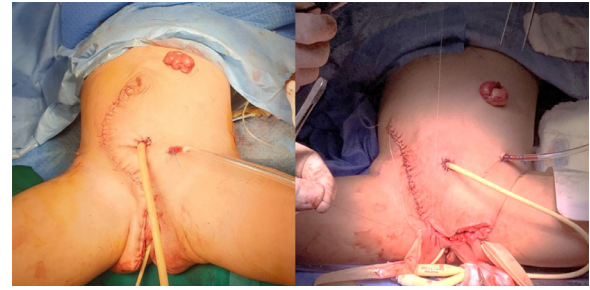
### Operation

The surgery was ultimately scheduled. The infants were 13 months old, with a combined body weight of 15 kg. The multidisciplinary team consisted of personnel from the following departments: pediatric general, urologic, orthopedic, plastic surgery, and anesthesia; all personnel were separated into “red” and “blue” teams, which focused on Twin 1 and Twin 2, respectively. The twins were placed on two adjoining tables. Each infant was attended by two anesthesiologists. After intubation, temperature, respiratory rate, heart rate, blood pressure, central venous pressure, electrocardiogram, partial pressure of carbon dioxide (pCO<sub>2</sub>), partial pressure of oxygen (pO<sub>2</sub>), and pH were monitored. Two Foley bladder catheters were inserted.

Surgery began with the plastic surgeons creating a lazy S incision across the anterior abdominal wall. Exploration revealed that each infant had a normal stomach, duodenum, gallbladder, pancreas, spleen, and small intestine. Both small intestines were a normal length and joined together approximately 30 cm away from the cecum. A Meckel’s diverticulum in Twin 1 was located in the ileum, near the junction of the two small intestines. A single appendix was identified. The common colon was 60 cm in length and freely movable, without any fixation. The colon received a double blood supply from the mesenteries of both children. The separation of the intestinal tract was the first step in this procedure. After assessing the colonic blood supply, the terminal ileum of Twin 2 was transected at the junction, where it joined the common terminal ileum. The colon was divided into two equal parts. The proximal half of the colon and the blood supply from Twin 1 were given to Twin 1, whereas the distal half and the anus, together with the blood supply from Twin 2, were given to Twin 2. Each patient received a colostomy.

Ureteroureterostomy was performed in both twins. After dividing the crossed ureters (we retained approximately 2 cm of the distal end of each ureter), we rotated the bladder of each twin into the correct position and performed a ureteroureterostomy. The right bladder, uterus, and ovaries of Twin 1 were given to Twin 1, and the others were given to Twin 2.

The bilateral separated pubic bones were approximated anteriorly by orthopedic surgeons, and the pelvic floor was



**Fig 4 – Twin 1 and Twin 2 following separation and reconstruction.**

reconstructed using an artificial tendon. To facilitate closure and pelvic stabilization, iliac osteotomies were performed on each twin. Fascial and skin closure of the abdomen was performed easily on the twins without any tension. Each child received a colostomy and a vesicostomy (Fig. 4). The total operating time was 8 hours, and the total blood loss was measured at approximately 50 ml in Twin 1 and 100 ml in Twin 2.

### Postoperative course

Both twins were transferred to the intensive care unit after the operation and were discharged 3 months after the operation. Twin 2 was subsequently re-admitted for a close colostomy when she was 22 months. A 1-year follow-up showed that they were active, intelligent children. They continue to undergo intensive physical and occupational therapy, and both twins are able to walk with a relatively normal gait.

### Discussion

The incidence of conjoined twins is 1 in 50,000 to 100,000, only 6%–11% of which are classified as the ischiopagus type [1]. To our knowledge, based on the existing published literature, just over 20 cases have been reported worldwide [5]. The separation of conjoined twins has long remained a surgical challenge because the specific anatomy of each pair of conjoined twins is unique; frequently, death occurs before an operation can be attempted. In Vietnam, the separation of ischiopagus conjoined twins had been performed two times. The first case was performed by A Dong Tran in 1988 [6], and the twins were separated with the assistance of the Japanese Red Cross after one twin went into a coma. Our separation surgery was completely successful in 2020.

The timing of separation depends on the performance of adequate preoperative studies and sufficient preparation to ensure the health and safety of the twins. During the neonatal period, the twins were not deemed suitable for undergoing a long operation due to prematurity and associated symptoms. The timing of a separation operation and the modes of treatment require tailoring to the local circumstances and the organs shared by each individual pair. O’Neill et al. [7] reported that a survival rate of 50% was achievable when separation

was performed during the neonatal period, whereas a survival rate of 90% could be achieved when the separation occurred later than 4 months of age. In our case, the separation could have been attempted earlier, when the twins were 10 months old. The twins were well-prepared with clear imaging examinations, and detailed planning had been performed. However, due to the effects of the coronavirus disease 2019 pandemic, we were forced to delay the operation for five months. In our opinion, the separation should be performed before the twins reach the age of 2 years to maximize available function and quality of life.

The internal organs that are shared by ischiopagus tetrapus twins typically include the liver, lower gastrointestinal tract, and genitourinary organs [7]. Plain film, intravenous pyelogram, barium enema and upper gastrointestinal series, ultrasonography, echocardiography, CTA, and MRI were performed for preoperative evaluation. In addition to traditional imaging examinations, the use of 3-dimensional (3D) modeling has also been reported for use in the separation of conjoined twins [8,9]. These 3D models can provide precise locations and other details regarding the anatomy of fused organs and the extent of cross circulation. In this case, 3D modeling not only confirmed that the twins shared a common colon but also delineated the location of the small intestinal junction between the twins. Advanced imaging techniques are amazingly efficient for depicting complex fusions, allowing for their recognition, diagnosis, and consideration when planning successful separation strategies.

Based on the blood supply, we decided that the proximal half of the colon, in continuity with the ileum, should be given to Twin 2, and the distal half was given to Twin 1. Each twin was left with a colostomy, with Twin 1 receiving the ileocecal valve and a colonic segment and Twin 2 retaining the anatomic anus. This method is likely to avoid postoperative complications associated with short bowel syndrome and unsafe anastomosis. Anastomosis leakage has been reported following the separation of conjoined twins; therefore, a colostomy operation was selected as the safest method for this case [10,11].

To the genitourinary organs, the choice of the left or the right organs for each twin was determined by many factors. The unsuited choice would lead to organ injury after separation. CTA, arteriography or excretory urography could provide more information for this problem. Ellen Shapiro et al showed that the division based on the spinal curvature, excretory urography [12]. In this report, based on the blood supply, the right genitourinary organs to twin 1 were given to twin 1 and similar to twin 2. In addition, giving the right normal ureter and dividing the left ureter with vesicoureteral reflux to twin 1 would be satisfactory for urological function after separation.

Last, this case was managed entirely by a team of Vietnamese surgeons without assistance from foreign surgeons, which is a significant achievement for the Vietnamese medical community. The unique efforts required to choreograph and rehearse each stage of the procedure with cooperation among multiple surgical specialties and teams set a new standard of complexity for multidisciplinary surgical care in Vietnam. The factors that contributed to the successful separation included careful planning and detailed systemic

investigations performed before the operation, in addition to the experience and skill of the surgical team.

Although the surgical separation was an important accomplishment, the long-term follow-up and management of such patients will be equally important. At the one-year postoperative follow-up, the results of the surgery appeared to be good. However, continuous follow-up will remain necessary throughout the patients' childhood to identify any delayed complications associated with urological or orthopedic sequelae.

---

## Conclusions

The separation of conjoined twins is a technically difficult procedure requiring multidisciplinary expertise. The success of this operation in southern Vietnam represents an important milestone indicative of the effective and sustainable expansion of this surgical approach.

---

## Author contributions

Truong QD, Nguyen MD, and Ho TTB contributed equally to this article as co-first authors. All authors have read the manuscript and agree to the contents.

---

## Ethical statement

Appropriate written informed consent was obtained for the publication of this case report and accompanying images.

---

## Patient consent

Informed consent for patient information to be published in this article was obtained.

---

## REFERENCES

- [1] Mian A, Gabra NI, Sharma T, Topale N, Gielecki J, Tubbs RS. Conjoined twins: from conception to separation, a review. *Clin Anat* 2017;30(3):385–96.
- [2] Mathew RP, Francis S, Basti RS, Suresh HB, Rajarathnam A, Cunha PD. Conjoined twins - role of imaging and recent advances. *J Ultrason* 2017;17(71):259–66.
- [3] Kumar-Duara B, Baruah P, Ray-Choudhury P, Agarwal S, Bharati A. A rare variety of ischiopagus tetrapus conjoined twins. *Eur J Anat* 2015;19(2):201–3.
- [4] Eades JW, Thomas CG. Successful separation of ischiopagus tetrapus-conjoined twins. *Ann Surg* 1966;164(6):1059–72.
- [5] Zhang XS, Feng ZG, Xiong QX, Li MJ, Tang DX. Successful separation of ischiopagus tetrapus conjoined twins. *World J Pediatr* 2007;3(3):228–31.

- 
- [6] Tran DA. Successful separation of ischiopagus tripus conjoined twins with one twin suffering from brain damage. *J Pediatr Surg* 1993;28(7):965–8.
- [7] O'Neill JA Jr, Holcomb GW 3rd, Schnauffer L, Templeton JM Jr, Bishop HC, Ross AJ 3rd. Surgical experience with thirteen conjoined twins. *Ann Surg* 1988;208(3):299–312.
- [8] Liu X, Dong K, Zheng S, Xiao X, Shen C, Dong C. Separation of pygopagus, omphalopagus, and ischiopagus with the aid of three-dimensional models. *J Pediatr Surg* 2018;53(4):682–7.
- [9] Wood BC, Sher SR, Mitchell BJ, Oh AK, Rogers GF, Boyajian MJ. Conjoined twin separation: integration of three-dimensional modeling for optimization of surgical planning. *J Craniofac Surg* 2017;28(1):4–10.
- [10] Rochadi R. Separation of ischiopagus tetrapus conjoined twins in Dr. Sardjito Hospital, Yogyakarta. *Paediatr Indones* 2016;48(6):381–4.
- [11] Carlson TL, Daugherty R, Miller A, Gbulie UB, Wallace R. Successful separation of conjoined twins: the contemporary experience and historic review in Memphis. *Ann Plast Surg* 2018;80(6):333–9.
- [12] Shapiro E, Fair WR, Ternberg JL, Siegel MJ, Bell MJ, Manley CB. Ischiopagus tetrapus twins: urological aspects of separation and 10-year followup. *J Urol* 1991;145(1):120–45.