

A novel strategy to perform endoscopic full-thickness resection at the ileocecal valve and securing the orifice with a double-pigtail catheter

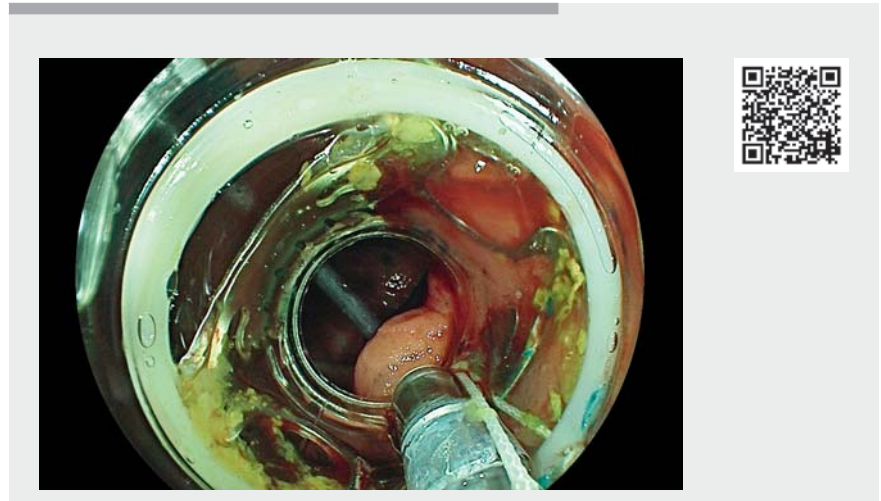
OPEN
ACCESS

A 68-year-old woman was referred to our clinic for evaluation of endoscopic resection of a flat polyp on the ileocecal valve. The initial colonoscopy showed a flat colonic adenoma, Paris IIa 2×2 cm, on the distal lip of the ileocecal valve (► **Fig. 1**). Owing to the non-lifting character after endoscopic submucosal injection, we decided to perform endoscopic full-thickness resection (EFTR). Colorectal endoscopic submucosa dissection (ESD) is an effective alternative to EFTR; however, ESD in the cecum is associated with a higher risk of perforation and delayed bleeding [1, 2].

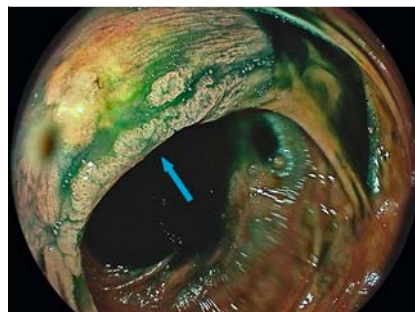
During EFTR we used a novel stenting technique in order to secure the ileocecal valve orifice (IVO), and to optimize orientation and visualization.

We first placed a Jagwire (Boston Scientific, Marlborough, Massachusetts, USA) through the working channel of a colonoscope, which allowed insertion of a double-pigtail catheter (7 Fr; MTW-Endoskopie W Haag Kg, Wesel, Germany) into the IVO (► **Video 1**). After marking the resection borders with coagulation current (Erbe, Tuebingen, Germany), the resection was performed using the EFTR System (Ovesco, Tuebingen, Germany) by using the high cut mode (Erbe Endo Cut Q; effect: setting 1; cutting duration: setting 4; cutting interval: setting 1). The 3×3 cm resected specimen was pinned onto a cork plate and sent for pathological assessment. At the end of the procedure (► **Fig. 2**), the double-pigtail catheter was extracted from the ileocecal valve using the biopsy forceps.

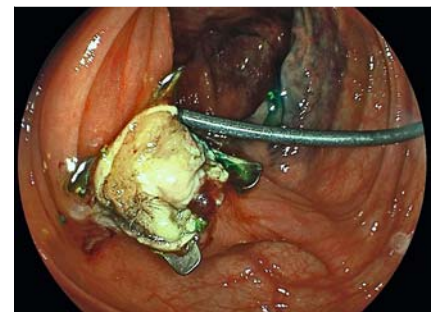
The histopathological evaluation revealed an adenoma with low grade intraepithelial neoplasia and microscopic complete resection (R0). After endoscopic resection, no complications occurred, and the patient could be discharged from the hospital after 3 days.



► **Video 1** Endoscopic full-thickness resection of a flat colonic adenoma at the ileocecal valve, using a double-pigtail catheter to secure the orifice.



► **Fig. 1** Colonic adenoma (arrow), Paris IIa 2×2 cm, on the distal lip of the ileocecal valve.



► **Fig. 2** Macroclip and double-pigtail stent in the ileocecal valve orifice following endoscopic full-thickness resection.

In conclusion, this new technique can be considered a safe procedure for EFTR close to the ileocecal valve region to optimize visibility [3,4] and prevent accidental closure of the IVO by the macroclip.

Endoscopy_UCTN_Code_TTT_1AQ_2AD

Competing interests

The authors declare that they have no conflict of interest.

The authors

Moritz Meiborg, Nicolae-Catalin Mechie, Tobias Blasberg, Marie Weber, Edris Wedi
Department of Gastroenterology,
Gastrointestinal Oncology and Interventional
Endoscopy, Sana Klinikum, Offenbach, Germany

Corresponding author

Edris Wedi, MD

Department of Gastroenterology,
Gastrointestinal Oncology and
Interventional Endoscopy, Sana Klinikum
Offenbach GmbH, Starkenburgring 66,
Offenbach 63069, Germany
edriswedi@gmail.com

References

- [1] Kim E, Chang D. Management of complications of colorectal submucosal dissection. *Clin Endosc* 2019; 52: 114–119
- [2] Falt P, Zapletalová J, Urban O. Endoscopic full-thickness resection versus endoscopic submucosal dissection in the treatment of colonic neoplastic lesions ≤30 mm – a single-center experience. *Surg Endosc* 2021; 36: 2062–2069
- [3] Wedi E, Orlandini B, Gromski M et al. Full-thickness resection device for complex colorectal lesions in high-risk patients as a last-resort endoscopic treatment: initial

clinical experience and review of the current literature. *Clin Endosc* 2018; 51: 103–108

[4] Kuellmer A, Mueller J, Caca K et al. Endoscopic full-thickness resection for early colorectal cancer. *Gastrointest Endosc* 2019; 89: 1180–1189

Bibliography

Endoscopy 2023; 55: E375–E376
DOI 10.1055/a-1986-7240
ISSN 0013-726X
© 2023. The Author(s).

This is an open access article published by Thieme under the terms of the Creative Commons Attribution-NonDerivative-NonCommercial License, permitting copying and reproduction so long as the original work is given appropriate credit. Contents may not be used for commercial purposes, or adapted, remixed, transformed or built upon. (<https://creativecommons.org/licenses/by-nc-nd/4.0/>)

Georg Thieme Verlag KG, Rüdigerstraße 14,
70469 Stuttgart, Germany



ENDOSCOPY E-VIDEOS

<https://eref.thieme.de/e-videos>



Endoscopy E-Videos is an open access online section, reporting on interesting cases and new techniques in gastroenterological endoscopy. All papers include a high quality video and all contributions are freely accessible online. Processing charges apply (currently EUR 375), discounts and waivers acc. to HINARI are available.

This section has its own submission website at
<https://mc.manuscriptcentral.com/e-videos>