

[CASE REPORT]

An Elderly Patient with Pulmonary Cryptococcosis with Mediastinal Lymphadenopathy Who Was Successfully Treated with Amphotericin B and Flucytosine

Shusaku Fujimoto, Naohiro Oda, Yusuke Fujioka, Reo Mitani and Ichiro Takata

Abstract:

Pulmonary cryptococcosis develops not only in immunocompromised patients but also in immunocompetent patients. However, lymph node involvement is relatively rare in immunocompetent patients. We herein report the case of an 80-year-old man who was not in an apparent immunocompromised state but was diagnosed with pulmonary cryptococcosis with mediastinal lymphadenopathy. The patient was resistant to fluconazole and voriconazole monotherapy; thus, his lung lesions significantly worsened. He eventually responded well to a combination therapy of amphotericin B and flucytosine, which was administered according to the treatment strategy for disseminated diseases.

Key words: pulmonary cryptococcosis, mediastinal lymphadenopathy, fluconazole resistance, amphotericin B, flucytosine, elderly

(Intern Med 59: 2547-2551, 2020)

(DOI: 10.2169/internalmedicine.4753-20)

Introduction

Pulmonary cryptococcosis caused by *Cryptococcus neoformans* or *C. gattii* develops not only in immunocompromised patients but also in immunocompetent patients (1). A cryptococcal infection is acquired by inhaling fungal spores (2). After inhalation, *Cryptococcus* causes a focal pneumonitis that may or may not be symptomatic, and host immunity affects the subsequent course of infection regardless of whether the pneumonitis resolves or progresses to disseminated disease (3). In immunocompetent patients, solitary or multiple pulmonary nodules are the common radiographic findings of pulmonary cryptococcosis; however, mediastinal lymph node involvement is rare (4-6). Moreover, pulmonary cryptococcosis without central nervous system (CNS) involvement is usually treated with fluconazole in immunocompetent patients (1).

We herein report the case of an 80-year-old man who was not in an apparent immunocompromised state but was diagnosed with pulmonary cryptococcosis with mediastinal lymphadenopathy. The patient was resistant to fluconazole and

voriconazole monotherapy but responded well to combination therapy with amphotericin B and flucytosine.

Case Report

An 80-year-old man was referred to our department due to pulmonary nodules detected on a computed tomography (CT) scan during follow-up after a distal pancreatectomy for an intraductal papillary mucinous neoplasm (IPMN). He presented with cough and yellow sputum. The patient was a former smoker (5 pack-years) and had a history of hypertension, left nephrectomy for a kidney stone, and distal pancreatectomy for IPMN. No abnormal physical findings were observed aside from a low-grade fever. The patient's complete blood count results were normal. However, the C-reactive protein (CRP) levels were increased at 0.53 mg/dL. Moreover, the following laboratory test results were obtained: serum creatinine level, 0.73 mg/dL; estimated glomerular filtration rate, 77.83 mL/min/1.73 m²; plasma glucose level, 103 mg/dL; hemoglobin A1c level, 6.3%; and serum soluble interleukin-2 receptor and angiotensin-converting enzyme levels, normal ranges. A chest CT scan

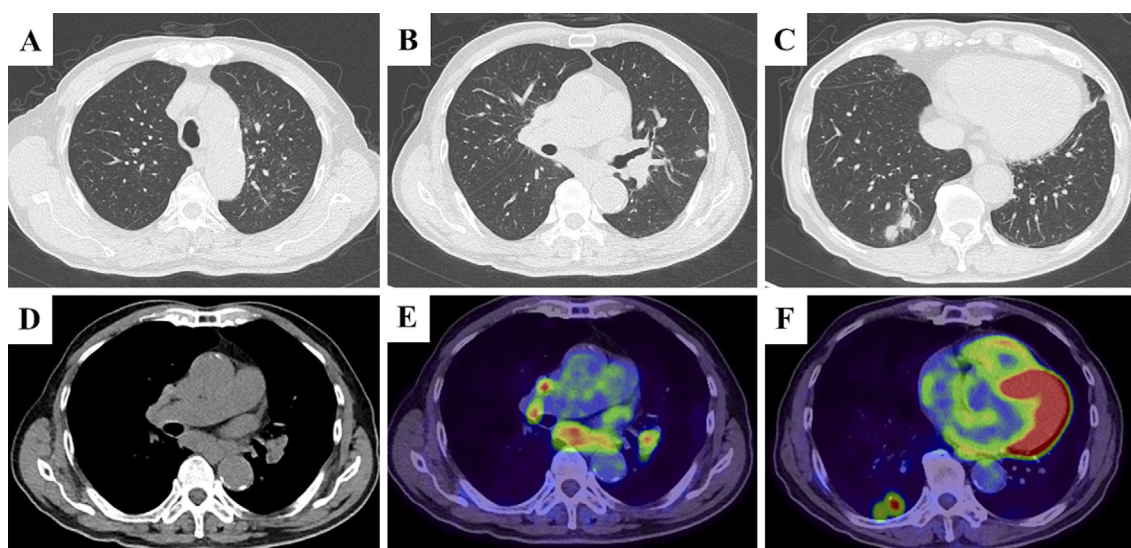


Figure 1. A computed tomography (CT) scan revealed multiple pulmonary nodules in both lungs, ground-glass opacities in the left upper lung (A-C), and bilateral hilar and mediastinal lymphadenopathies (D). A fluorodeoxyglucose positron emission tomography (FDG)/CT scan revealed multiple lesions with a high FDG uptake, pulmonary nodules, and hilar and mediastinal lymphadenopathies (E, F).

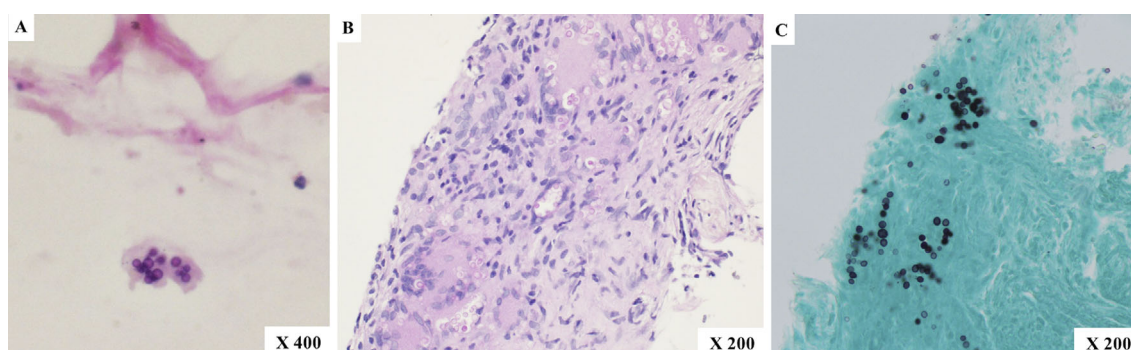


Figure 2. A cytological examination of the aspirated specimen of the mediastinal lymph node revealed periodic acid-Schiff (PAS)-positive yeast-like organisms (A). A pathological examination of the biopsy specimen of the pulmonary nodule revealed granulomas with multinucleated giant cells and PAS and Grocott stain positive yeast-like organisms (B, C).

revealed multiple pulmonary nodules in both lungs, ground-glass opacities in the left upper lobe, and bilateral hilar and mediastinal lymphadenopathies (Fig. 1). A fluorodeoxyglucose positron emission tomography (FDG-PET)/CT scan revealed multiple lesions with a high FDG uptake, pulmonary nodules, and hilar and mediastinal lymphadenopathies (Fig. 1). Endobronchial ultrasound-guided transbronchial needle aspiration (EBUS-TBNA) of a subcarinal mediastinal lymph node and CT-guided needle biopsy for a pulmonary nodule in the right lower lobe were performed. A cytological examination of the mediastinal lymph node revealed periodic acid-Schiff (PAS)-positive yeast-like organisms, which is morphologically consistent with a *Cryptococcus* infection (Fig. 2A). However, no malignant findings were observed. A pathological examination of the pulmonary nodule revealed granulomas with PAS-positive multinucleated giant cells and yeast-like organisms (Fig. 2B), and *C. neoformans* was iso-

lated in culture. The patient was positive for serum cryptococcal antigen but negative for anti-human immune deficiency virus (HIV) and anti-human T-cell lymphoma virus-1 antibodies. Moreover, the patient's serum total protein level, 7.6 g/dL; serum albumin level, 4.0 g/dL; α 1-globulin fraction, 2.6%; α 2-globulin fraction, 10.1%; β -globulin fraction, 9.9%; γ -globulin fraction, 20.7%, which showed his normal immunoglobulin levels. The patient was diagnosed with pulmonary cryptococcosis with mediastinal lymphadenopathy and was treated with fluconazole (400 mg/day) monotherapy. After treatment with fluconazole for 4 weeks, a CT scan revealed larger pulmonary nodules and diffuse infiltrates in the left lung, and his serum cryptococcal antigen titer was 1:16. Two weeks after switching the antifungal agent to intravenous voriconazole (700 mg/day on the first day and 460 mg/day after the second day), the CT scan findings worsened, and the laboratory test result revealed in-

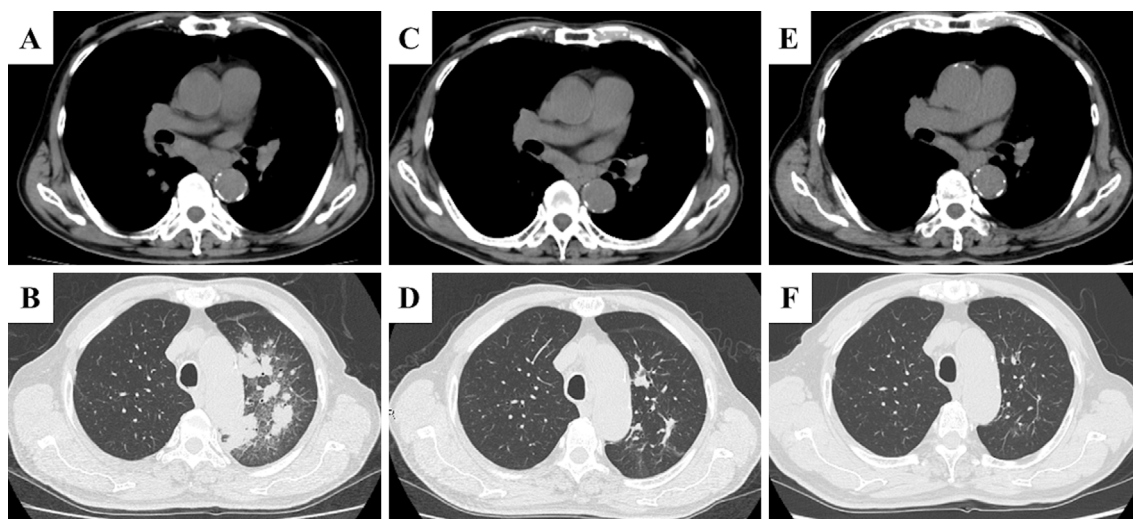


Figure 3. A computed tomography (CT) scan revealed diffuse infiltrates in the left lung after treatment with fluconazole and voriconazole (A, B). CT scans conducted 2 months (C, D) and 12 months (E, F) after the administration of amphotericin B and flucytosine revealed that diffuse infiltrates in the left lung had diminished, and the size of the subcarinal mediastinal lymph node had decreased.

creased CRP levels at 8.16 mg/dL (Fig. 3A, B). Considering the spread of cryptococcosis to extrapulmonary sites, a lumbar puncture was performed, but no findings indicative of meningitis were observed. After the initiation of liposomal amphotericin B (250 mg/day) and flucytosine (600 mg/day), a CT scan revealed gradually improving findings, and the patient's serum CRP level decreased (Fig. 3C-F). He was treated with liposomal amphotericin B and flucytosine for 3 weeks; thereafter, the patient received maintenance therapy with itraconazole (200 mg/day) for 11 months. The patient did not present with recurrence of pulmonary cryptococcosis 3 years after the discontinuation of antifungal therapy.

Discussion

The most common radiographic findings of pulmonary cryptococcosis in immunocompetent patients are solitary or multiple well-defined, noncalcified nodules predominantly in the subpleural region. Other radiographic findings include infiltration, hilar and mediastinal lymphadenopathy, and pleural effusion. However, these findings are relatively common in immunocompromised patients, particularly in HIV-positive patients (4-6). EBUS-TBNA is used to diagnose mediastinal lymphadenopathy due to not only lung cancer, malignant lymphoma, or sarcoidosis but also infectious diseases, including tuberculosis (7). Recently, some case reports have shown mediastinal lymph node involvement in patients with pulmonary cryptococcosis based on EBUS-TBNA (8-11). The current patient was suspected to have lung cancer with lymph node metastases due to a high FDG accumulation in both pulmonary nodules and hilar and mediastinal lymphadenopathies. According to a previous report, lung lesions with a high FDG uptake are observed in 88% of patients with pulmonary cryptococcosis (12). Pulmonary cryptococcosis is difficult to differentiate from lung cancer

on PET-CT scans; therefore, EBUS-TBNA, which is a minimally invasive and extremely effective procedure, is used to diagnose pulmonary cryptococcosis with mediastinal lymphadenopathy.

According to the Infectious Diseases Society of America guidelines, fluconazole monotherapy is the first choice of treatment for pulmonary cryptococcosis. Combination therapy with amphotericin B and flucytosine, followed by fluconazole, is recommended for severe pulmonary cryptococcosis (respiratory failure) or disseminated disease (e.g., involvement of at least two noncontiguous sites and cryptococcal antigen titer greater than 1:512), including CNS disease (1). In the current case, although the patient did not present with concomitant meningitis, he was resistant to fluconazole and voriconazole. His CT scan revealed that diffuse pulmonary infiltrates worsened within a short period of time, and the patient eventually required combination therapy with amphotericin B and flucytosine, which was administered according to the treatment strategy for disseminated diseases. The cause of the failure of treatment with fluconazole and voriconazole in the present case was not clearly identified; however, *C. neoformans* might have primary resistance to fluconazole and voriconazole. In a global surveillance of antifungal agents in 2007, *in vitro* susceptibility test has revealed that the rates of resistance to fluconazole and voriconazole among *Cryptococcus neoformans* isolated from patients with cryptococcosis are 10.8% and 1.8%, respectively (13). In particular, secondary resistance to fluconazole in HIV-positive patients with cryptococcosis is an emerging problem in some areas, including Africa, where low-dose treatment with fluconazole is the primary therapy or prophylaxis, and there is lack of access to amphotericin B, flucytosine, and antiretroviral therapy (14). One report demonstrated that the efficacy of fluconazole is reduced when its minimum inhibitory concentrations (MICs) are greater than

16 mg/mL (15). Voriconazole is recommended as salvage consolidation therapy for the relapse of cryptococcosis after induction therapy (1). Moreover, fluconazole-resistant pulmonary cryptococcosis without meningitis in patients who underwent renal transplantation is successfully treated with voriconazole combined with amphotericin B (16). However, voriconazole monotherapy was not effective in the present case. When the initial treatment with fluconazole is not successful in patients with cryptococcosis, an MIC test of antifungal agents should thus be considered.

Cell-mediated immunity, particularly an immune response caused by type 1 helper CD4 T (Th1) cells, is important for host-protective response to *Cryptococcus*, which is similar to *Mycobacterium tuberculosis*. Macrophages are activated by cytokines, such as interferon-gamma produced by Th1 cells, and granulomas containing fungi are formed (17). Immunocompromised patients are likely to develop hematogenous dissemination and/or lymphogenous progression resulting in hilar and mediastinal lymphadenopathies compared with immunocompetent patients (18). In the present case, the cryptococcal infection spread to the mediastinal lymph nodes as confirmed by a cytological examination using EBUS-TBNA; therefore, increasing treatment intensity may be required in patients with disseminated diseases. Similar to the present case, there are some reports about immunocompetent patients with pulmonary cryptococcosis with mediastinal lymphadenopathy without meningitis who were successfully treated with intensive therapy with high-dose fluconazole (800 mg/day) (19) or amphotericin B and flucytosine (9).

In the present case, the patient was not in an apparent immunocompromised state, which is caused by diseases, such as HIV infection, malignancy, liver disease, and diabetes mellitus; organ transplantation; and use of steroids and/or other immunosuppressive agents. However, decreased immunity, which results in the aggravation of pulmonary cryptococcosis, may occur with aging. The study about pulmonary cryptococcosis in HIV-negative patients has revealed that old age is significantly associated with meningitis and a poor prognosis (20). The influence of immunosenescence on cryptococcal infection has not been fully elucidated. Further investigations can help us to better understand the pathogenesis of pulmonary cryptococcosis in elderly patients.

In conclusion, we herein described the case of an elderly man with pulmonary cryptococcosis with mediastinal lymphadenopathy that was resistant to fluconazole and voriconazole but was successfully treated with amphotericin B and flucytosine.

The authors state that they have no Conflict of Interest (COI).

References

1. Perfect JR, Dismukes WE, Dromer F, et al. Clinical practice guidelines for the management of cryptococcal disease: 2010 update by the infectious diseases society of america. *Clin Infect Dis* **50**: 291-322, 2010.
2. Velagapudi R, Hsueh YP, Geunes-Boyer S, Wright JR, Heitman J. Spores as infectious propagules of *Cryptococcus neoformans*. *Infect Immun* **77**: 4345-4355, 2009.
3. Huffnagle GB, Traynor TR, McDonald RA, et al. Leukocyte recruitment during pulmonary *Cryptococcus neoformans* infection. *Immunopharmacology* **48**: 231-236, 2000.
4. Lindell RM, Hartman TE, Nadrous HF, Ryu JH. Pulmonary cryptococcosis: CT findings in immunocompetent patients. *Radiology* **236**: 326-331, 2005.
5. Fox DL, Müller NL. Pulmonary cryptococcosis in immunocompetent patients: CT findings in 12 patients. *AJR Am J Roentgenol* **185**: 622-626, 2005.
6. Yang CJ, Hwang JJ, Wang TH, et al. Clinical and radiographic presentations of pulmonary cryptococcosis in immunocompetent patients. *Scand J Infect Dis* **38**: 788-793, 2006.
7. Navani N, Molyneaux PL, Breen RA, et al. Utility of endobronchial ultrasound-guided transbronchial needle aspiration in patients with tuberculous intrathoracic lymphadenopathy: a multicentre study. *Thorax* **66**: 889-893, 2011.
8. Wong M, Loong F, Khong PL, Kwong YL, Leung AY. Mediastinal cryptococcosis masquerading as therapy-refractory lymphoma. *Ann Hematol* **90**: 601-602, 2011.
9. Okachi S, Wakahara K, Kato D, Umeyama T, Yagi T, Hasegawa Y. Massive mediastinal cryptococcosis in a young immunocompetent patient. *Respirol Case Rep* **3**: 95-98, 2015.
10. Chichra A, Lama KW, Koenig SJ. Respiratory failure with hilar mass: role of endobronchial ultrasound-guided transbronchial needle aspiration in the medical intensive care unit. *Lung India* **32**: 178-181, 2015.
11. Murakami Y, Oki M, Saka H, Kajikawa S, Murakami A, Ishida A. Disseminated cryptococcosis presenting as mediastinal and hilar lymphadenopathy in an immunocompetent patient. *Respirol Case Reports* **4**: e00167, 2016.
12. Wang SY, Chen G, Luo DL, et al. 18F-FDG PET/CT and contrast-enhanced CT findings of pulmonary cryptococcosis. *Eur J Radiol* **89**: 140-148, 2017.
13. Pfaller MA, Diekema DJ, Gibbs DL, et al. Global Antifungal Surveillance Group. Results from the ARTEMIS DISK Global Antifungal Surveillance Study, 1997 to 2007: 10.5-year analysis of susceptibilities of noncandidal yeast species to fluconazole and voriconazole determined by CLSI standardized disk diffusion testing. *J Clin Microbiol* **47**: 117-123, 2009.
14. Cheong JW, McCormack J. Fluconazole resistance in cryptococcal disease: emerging or intrinsic? *Med Mycol* **51**: 261-269, 2013.
15. Aller AI, Martin-Mazuelos E, Lozano F, et al. Correlation of fluconazole MICs with clinical outcome in cryptococcal infection. *Antimicrob Agents Chemother* **44**: 1544-1548, 2000.
16. Fujioka K, Nagai T, Kinoshita Y, et al. Successful treatment with voriconazole combined with amphotericin B-liposome for fluconazole-resistant pulmonary cryptococcosis after renal transplantation. *CEN Case Rep* **8**: 261-265, 2019.
17. Hardison SE, Ravi S, Wozniak KL, Young ML, Olszewski MA, Wormley FL Jr. Pulmonary infection with an interferon-gamma-producing *Cryptococcus neoformans* strain results in classical macrophage activation and protection. *Am J Pathol* **176**: 774-785, 2010.
18. Cameron ML, Bartlett JA, Gallis HA, Waskin HA. Manifestations of pulmonary cryptococcosis in patients with acquired immunodeficiency syndrome. *Rev Infect Dis* **13**: 64-67, 1991.
19. Vawda F, Maharajh J, Naidoo K. Massive cryptococcal lymphadenopathy in an immunocompetent pregnant patient. *Br J Radiol* **81**: e53-e56, 2008.
20. Kohno S, Takeya H, Izumikawa K, et al. Clinical features of pulmonary cryptococcosis in non-HIV patients in Japan. *J Infect Chemother* **21**: 23-30, 2015.

The Internal Medicine is an Open Access journal distributed under the Creative Commons Attribution-NonCommercial-NoDerivatives 4.0 International License. To view the details of this license, please visit (<https://creativecommons.org/licenses/by-nc-nd/4.0/>).

© 2020 The Japanese Society of Internal Medicine
Intern Med 59: 2547-2551, 2020