

A case of asymptomatic large aortopulmonary window in an adult: Role of cardiac CT, CMRI, and 3D printing technology

Aniketh Vijay Balegadde, Vikrant Vijan, Rajesh Thachathodiyl, Mahesh Kappanayil
 Department of Cardiology, Amrita Institute of Medical Sciences, Amrita Vishwa Vidyapeetham University; Kerala-India

Introduction

Aortopulmonary window (APW) is a very rare congenital heart disease, representing approximately 0.2% to 0.4% of all cardiac malformations (1). Presently described is an unusual case of a large, unrepaired APW, causing severe pulmonary arterial hypertension (PAH), in a 32-year-old female who had been asymptomatic until 31 years of age.

Case Report

A 32-year-old, lean-built female presented with major complaints of heart failure (class II-III) ongoing for 4 months. She had experienced palpitations for 3 months, which was predominantly exertional, lasting for about 2 to 3 minutes, associated with dyspnea and sweating. No history of presyncope/syncope or cyanotic spells was observed, and no significant past medical history or family history was noted. Elsewhere, she had been diagnosed with severe PAH at 31 years of age, and was referred for further evaluation and management.

A physical examination yielded normal vital signs. An electrocardiogram revealed biventricular hypertrophy with right atrial enlargement. A chest X-ray showed cardiomegaly with bilaterally-dilated pulmonary arteries. A transthoracic echocardiogram revealed a dilated right atrium, right ventricle, and main pulmonary artery; severe tricuspid regurgitation; a pulmonary artery systolic pressure of 125 mm Hg; severe PAH (pulmonary vascular resistance index: $20 \text{ dyn.s/cm}^5.\text{m}^2$) with good left ventricular systolic function; and an intact interventricular/interatrial septum. Multi-detector computed tomography (CT) with CT pulmonary angiography of the chest revealed no evidence of pulmonary thromboembolism, but showed the presence of a large APW with severe PAH (Fig. 1a, 1b, Fig. 2a). Subsequent cardiac magnetic resonance imaging (CMRI) revealed a large APW (3 cm, type I Mori classification) with severe PAH and right ventricular dysfunction (Fig. 2b, 2c). Flow studies from the CMRI revealed a predominant left-to-right shunt. The patient was scheduled for a catheterization study, followed by device/surgical closure. To more precisely evaluate the anatomical defect and to assess

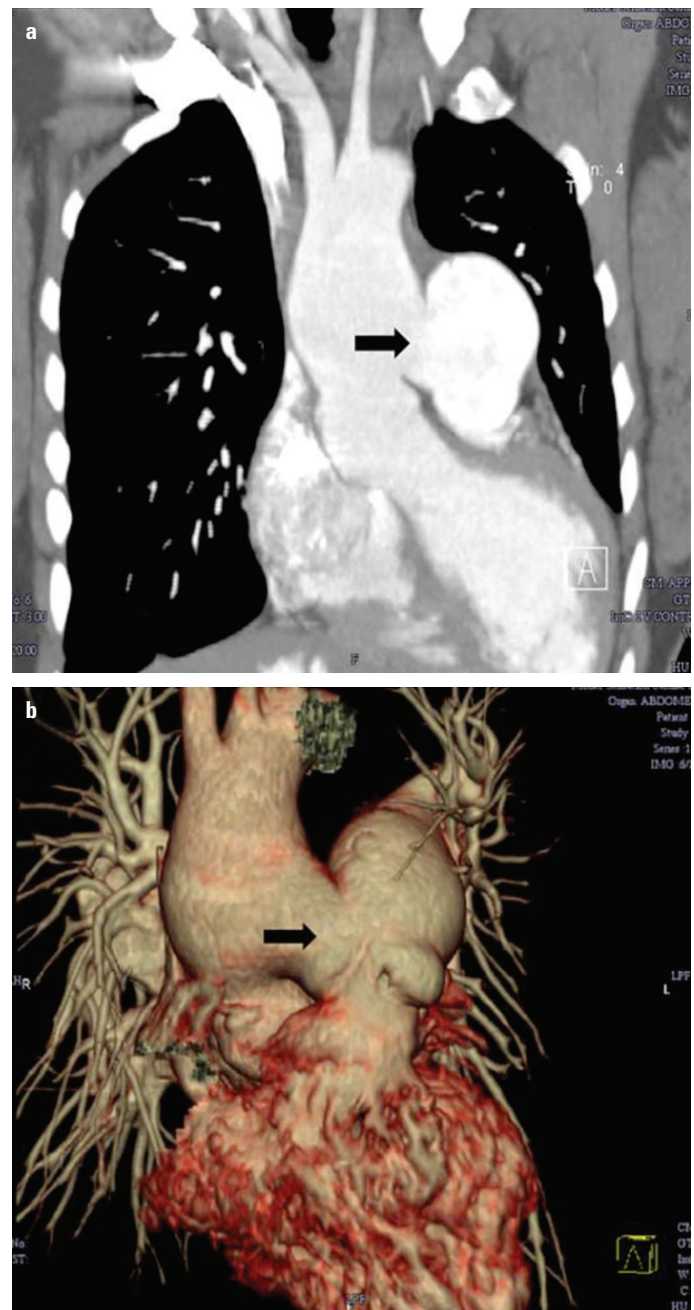


Figure 1. (a) Multi-detector computed tomography (MDCT) image of the chest with contrast showing a large aortopulmonary window (APW) (arrow mark). (b) Reconstructed MDCT images showing a large APW (arrow mark)

the feasibility of device closure/surgical closure, 3-dimensional (3D) printing technology (Anatomiz3D Healthcare, Mumbai, India) was utilized. The solid 3D anatomical model of the patient's heart (Fig. 3a, 3b) revealed that the anatomical defect did not have an inner rim (Fig. 3c) and was not ideal for device closure. This was of use in the decision to consider surgical closure. Accordingly, a catheterization study was done. However, the patient was not considered suitable for surgical closure, as she ex-

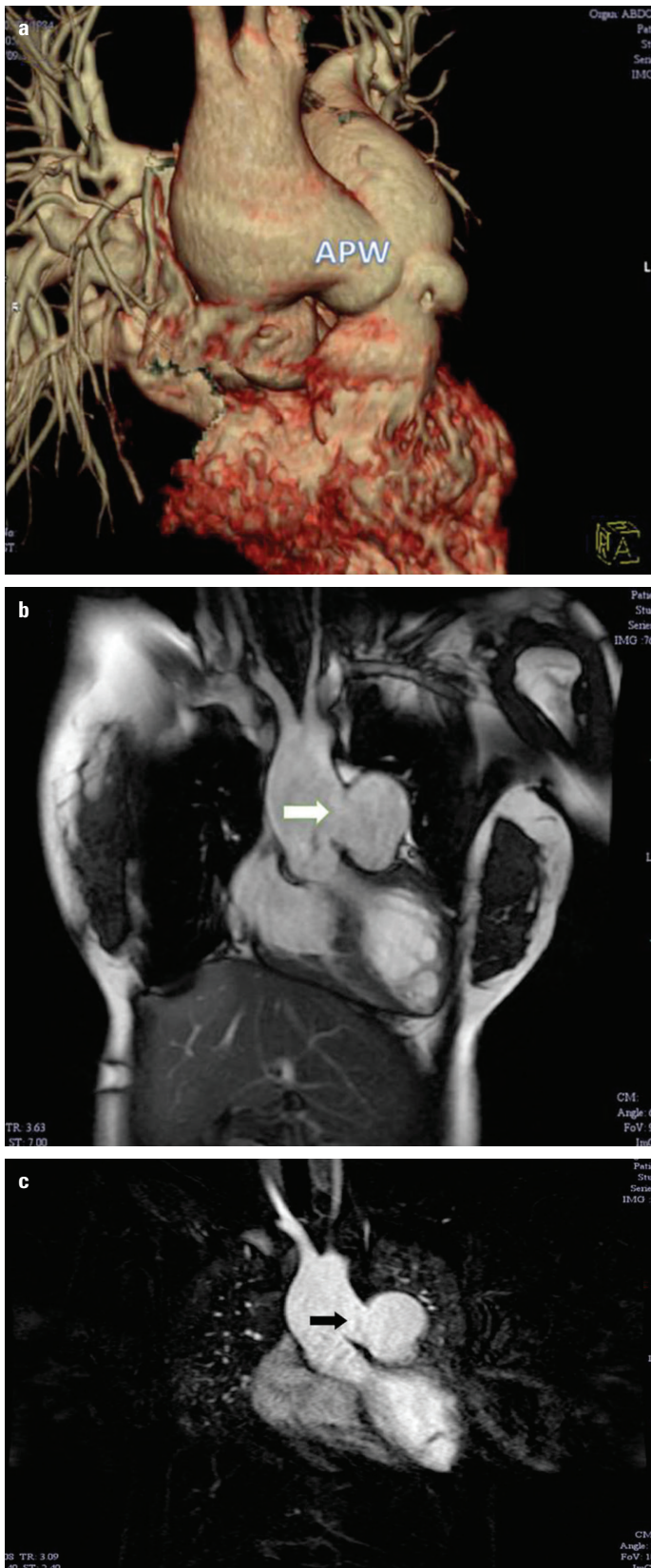


Figure 2. (a) Reconstructed MDCT images showing a large APW (arrow mark). (b) Cardiac magnetic resonance imaging (CMRI) showing the presence of a large APW (arrow mark; 3-cm defect). (c) CMRI flow study image




Figure 3. 3-dimensional (3D) anatomical model (exact replica of the patient's heart) prepared using 3D printing technology, showing (a) the anterior and the posterior part of the model; (b) the aortopulmonary window (APW) (arrow mark); (c) the presence of APW (blue arrow mark) and the absence of an inner rim in the defect (black arrow mark), which led to avoiding an attempt at device closure of the defect

hibited a high pulmonary vascular resistance index (PVRI) of 20, with good reversibility with dioxygen and nitrogen dioxide. Consequently, she was kept on phosphodiesterase type 5 inhibitors/ endothelin-receptor antagonists for 6 months, and then a repeat catheterization study was planned. She was lost to follow-up and

returned after 1 year. Re-catheterization again showed high PVRI and she had developed right-to-left shunting. Medical follow-up was continued and the probable need for heart-lung transplantation in the future was discussed.

Discussion

In this study, the APW patient had survived until the fourth decade of life. The literature suggests that APW is associated with a high mortality rate and the median survival of uncorrected APW is 33 years (2). Furthermore, APW patients usually become symptomatic, develop Eisenmenger syndrome, and show signs of progressive pulmonary arterial hypertension in the first month of life (2, 3). Conversely, our patient remained asymptomatic until 31 years of age and presented as non-Eisenmenger. To our knowledge, very few "asymptomatic" adult cases have been reported in the literature (2-5). APW patients usually have associated cardiac disorders, such as an atrial septal defect, patent ductus arteriosus, ventricular septal defect, coronary artery anomaly, or tetralogy of Fallot (1). However, our patient had an isolated APW. The present case is also very unique as it describes the role of 3D printing technology in the decision-making for the management of the APW. 3D printing technology has opened up new opportunities in cardiology and cardiac surgery (6-9). Conventionally, APW is diagnosed with echocardiography, cardiac CT, CMRI, and a catheterization study (2, 3). However, a 3D anatomical model of the patient's heart provided invaluable information compared to the conventional modalities used in our case. We strongly believe that 3D printing technology will play a significant role in the imaging, planning, and performance of cardiovascular interventions.

Conclusion

We report an unusual case of a 32-year-old female with a large, unrepaired APW causing severe pulmonary hypertension. The case is unique in terms of the asymptomatic period until the fourth decade of life, the long survival with an unrepaired APW, presentation as non-Eisenmenger, and an APW as an isolated congenital defect. Furthermore, to the best of our knowledge, this is the first case in literature to have utilized 3D printing technology to assess the fine details of the defect and to aid in the management of a patient with an APW.

References

- Chellappan S, Katewa A, Sathe YC. Transesophageal Echocardiography in a Distal Aortopulmonary Window. *J Cardiovasc Echogr* 2016; 26: 131-4.
- Kose M, Ucar S, Emet S, Akpınar TS, Yalın K. A Case of Aortopulmonary Window: Asymptomatic until the First Pregnancy. *Case Rep Cardiol* 2015; 2015: 935253.
- Aggarwal SK, Mishra J, Sai V, Iyer VR, Panicker BK. Aortopulmonary window in adults: diagnosis and treatment of late-presenting patients. *Congenit Heart Dis* 2008; 3: 341-6.
- Gowda D, Gajjar T, Rao JN, Chavali P, Sirohi A, Pandarinathan N, et al. Surgical management of aortopulmonary window: 24 years of experience and lessons learned. *Interact Cardiovasc Thorac Surg* 2017; 25: 302-9.
- Myers PO, Lador F, Hachulla AL, Bouchardy J, Noble S, Licker M, et al. Unrestrictive Aortopulmonary Window: Extreme Presentation as Non-Eisenmenger in a 30-Year-Old Patient. *Circulation* 2016; 133: 1907-10.
- Bartel T, Rivard A, Jimenez A, Mestres CA, Müller S. Medical three-dimensional printing opens up new opportunities in cardiology and cardiac surgery. *Eur Heart J* 2017 Feb 16; doi: 10.1093/eurheartj/ehx016.
- Bramlet M, Olivieri L, Farooqi K, Ripley B, Coakley M. Impact of Three-Dimensional Printing on the Study and Treatment of Congenital Heart Disease. *Circ Res* 2017; 120: 904-7.
- Olejník P, Nosal M, Havran T, Furdova A, Cizmar M, Slabej M, et al. Utilisation of three-dimensional printed heart models for operative planning of complex congenital heart defects. *Kardiol Pol* 2017; 75: 495-501.
- Vukicevic M, Mosadegh B, Min JK, Little SH. Cardiac 3D Printing and its Future Directions. *JACC Cardiovasc Imaging* 2017; 10: 171-84.

Address for Correspondence: Dr. Aniketh Vijay Balegadde

Department of Cardiology, Amrita Institute of Medical Sciences,
Amrita Vishwa Vidyapeetam University,

682041 Kochi; Kerala-India

Phone: +91-8762577777

E-mail: aniketh.vijay7@gmail.com

©Copyright 2018 by Turkish Society of Cardiology - Available online
at www.anatoljcardiol.com

DOI:10.14744/AnatolJCardiol.2017.7948

