

The versatility of lower eyelid blepharoplasty incision: In open reduction and fixation of zygomatic complex injuries

Chandran V. S. R.,
Candamourty R.¹,
Thangavelu A.²

Department of Oral and Maxillofacial Surgery, Best Dental College, Madurai, ¹Indira Gandhi Institute of Dental Sciences, Mahatma Gandhi Medical College and Research Institute Campus, Pillaiyarkuppam, Pondicherry, ²Rajah Muthiah Dental College and Hospitals, Annamalai University, Chidambaram, India

Address for correspondence:

Dr. Ramesh Candamourty, Professor and Head, Department of Oral and Maxillofacial Surgery, Indira Gandhi Institute of Dental Sciences, Mahatma Gandhi Medical College and Research Institute Campus, Pillaiyarkuppam, Pondicherry – 607 402, India. E-mail: ramesh_candy@rediffmail.com

Abstract

Introduction: A zygomatic complex fracture includes disruption of the four articulating sutures: zygomaticofrontal, zygomaticotemporal, zygomaticomaxillary and zygomaticosphenoidal sutures. All zygomatic complex fractures involve the orbital floor and therefore an understanding of orbital anatomic features is essential for those treating these injuries. **Aims and Objectives:** To analyze the efficacy and shortcomings of this approach. To evaluate the adequacy, role of tarsorrhaphy, difficulties, role of steroid in postoperative edema control in lower lid blepharoplasty approach. **Materials and Methods:** A total number of six patients were included in this study and all the patients were treated surgically under general anesthesia. All the patients were approached through lower eyelid blepharoplasty incision. The first skin crease in the lower eyelid region is selected for this incision. **Results:** All patients were administered with steroid injection. Frost sutures were placed in four cases and tarsorrhaphy was done in two patients. Three cases encountered immediate mild edema and immediate scar formation. Late scar was present only in two patients with a follow up of three months. **Conclusion:** Lower eyelid blepharoplasty incision is an excellent, non complicated, simple procedure in the management of fractures in the infraorbital region, orbital floor, which occurs as a part of zygomatic complex fractures.

Key words: Lower lid blepharoplasty, lateral middle third fractures, subciliary approach, zygomatic complex fractures

INTRODUCTION

Transconjunctival incision with lateral canthotomy is one of the commonly used incisions for access to the infraorbital rim and the floor of the orbit for esthetic, reconstructive and traumatic surgery. The three most commonly used cutaneous lower lid incisions are subtarsal, infraorbital and the lower blepharoplasty incision. Subciliary incision is made approximately 2 mm inferior to free margin of eyelid, subtarsal is made 5 to 7 mm inferior to lower eyelid whereas

infraorbital is made at the inferior orbital rim region.^[1]

The infraorbital skin crease incision is still very popular and widely practiced. It is safe, gives rise to relatively few surgical complications and is thus regarded as a relatively sound approach. Nevertheless, the main disadvantage of this approach may be noticeable scarring, which is particularly unacceptable in young people where such a scar usually increases in size with growth. The incision provides limited access to the lower aspect of the lateral orbital rim and wall. In order to improve access it can be extended too far laterally or in an upward direction, when it may cause lower lid lymph edema which subsequently lasts for a variable period.

The transconjunctival incision for exploration of the orbital rim and floor was introduced by Bourquet and has been popularized by Tessier.^[2] This approach produces superior cosmetic results when compared to any other commonly

Access this article online	
Quick Response Code:	Website: www.jnsbm.org
	DOI: 10.4103/0976-9668.101900

used incision. Its main disadvantage is the limited access to the orbital floor and thus should only be considered as an approach to the fractures of the orbital rim and floor where there is no need for extensive fixation procedures. It is an excellent approach for correction of pure orbital (inferior) blow out fractures. Sailer (1977) advocates the transconjunctival incision to approach fractures of the orbital rim and floor when he inserts staples for the fixation of bone fragments. Where it is necessary to improve access to the fracture site the transconjunctival incision can be extended laterally with the use of lateral canthotomy. In these situations, however, the extended lower blepharoplasty incision is the approach of choice. The lower blepharoplasty incision has been used as an approach to the orbital fractures since 1978.^[1]

Lower lid blepharoplasty incision was first described by Converse in 1944; the advantage of this approach owes adequate exposure to inferolateral orbital region. Floor reconstruction, infraorbital nerve decompression and plate fixation of the rim can be easily done through this approach. This approach results in minimal scarring, but vertical lower eyelid shortening, as evidenced by scleral show and ectropion may occur occasionally secondary to fibrosis from the dissection.^[3]

Hence a study was undertaken in division of Oral and Maxillofacial Surgery in Rajah Muthiah Dental College and Hospital during the year 2003 to 2006 to analyze the efficacy of lower eyelid blepharoplasty incision in surgical exposure of the lower orbital region and to analyze the shortcomings of this approach in isolated and complex mid-facial injuries involving the orbital skeleton.

MATERIALS AND METHODS

Materials

This study was conducted in the division of Oral and Maxillofacial Surgery, Rajah Muthiah Dental College and Hospital, from the year 2003 to 2006 after obtaining approval of the institutional ethics committee and informed consent of the participants. Patients selected for this study were between the age group of 20 and 40 years. The clinical examination was performed using standard protocols.

- All the patients were generally examined for associated injuries.
- All the patients were subjected to routine investigation, which includes routine blood investigation, radiographs (PNS and OPG). Advanced investigation like CT scan and rapid prototype are taken wherever necessary.

None of the patient was taken up for surgery immediately after the trauma. The time period was 4 to 7 days after the trauma. All of the patients included in this study had displaced fracture zygoma with or without associated facial bone fractures.

A total number of six patients were included in this study and all the patients were treated surgically under general anesthesia. All the patients were approached through lower eyelid blepharoplasty incision with the help of sterile instruments [Figure 1]. The first skin crease in the lower eyelid region is selected for this incision.

Methods

Blepharoplasty Approach to Infraorbital and Floor of The Orbit

Before the incision is placed, incision line is marked with sterile ink [Figure 2a] and frost bite is placed in the gray lines of the lower eyelids [Figures 2b, c]. This is to minimize postoperative edema and it also acts as an additional retraction other than the manual retraction of the surgical site.

The tissues were infiltrated with 2% lignocaine solution containing adrenaline (1:2,00,000 units). The skin incision was made 2 to 3 mm inferior to the gray line of the lower eyelid but always superior to the inferior palpebral fold. The incision runs parallel to the lid margin from the punctum medially to the orbital rim laterally. The lateral extent of the incision was tapered inferiorly within skin crease and along the whole length of the margins of the lower eyelid.

Dissection was either anterior or posterior to the orbicularis oculi muscle when the anterior dissection was used and the muscle was not disturbed at the level of incision, but was divided bluntly at the level of the infraorbital rim [Figure 2d]. In the posterior dissection, the muscle was sharply divided immediately beneath the incision line and then separated from the orbital septum until the outline of

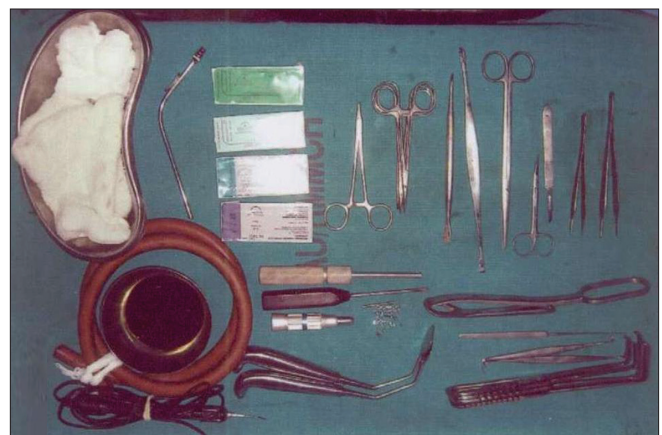


Figure 1: Armamentarium

the inferior orbital rim can be visualized. Care was taken not to penetrate the septum to avoid the problems of the prolapse of the fatty tissue into surgical field. When the orbital rim was exposed, the periosteum was incised 3 mm inferior to it to avoid postoperative tethering of the peri orbita and to facilitate good periorbital closure [Figure 3a]. The displaced infraorbital rim fracture was reduced under direct vision (4 cases) or indirectly by Gillie's temporal approach. The reduced fragment was held in the anatomical position using four hole stainless steel plates (1.5 mm) and screws [Figure 3b]. The surgical area was debrided and cleaned with saline and antiseptic (Betadine). The wound was closed in layers by using 3-0 Vicryl for the closure of the orbicularis oculi muscle and 5-0 silk or nylon was used for skin closure [Figures 3c, d]. Muscle and skin was closed from medial to lateral end without any tension. After recovery of the patients from general anesthesia, immediate ice fermentation was given to avoid postoperative edema formation. Pre- and postoperative radiographs were taken [Figures 4c, d].

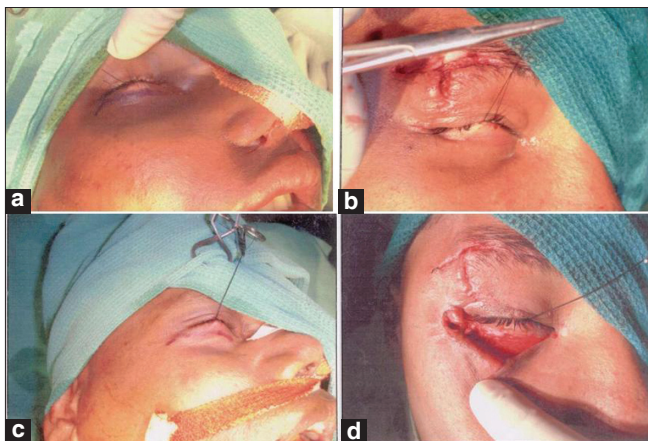


Figure 2: (a) Skin marking (b) Frost suture (c) Tarsorrhaphy (d) Exposure of orbicularis oculi muscle

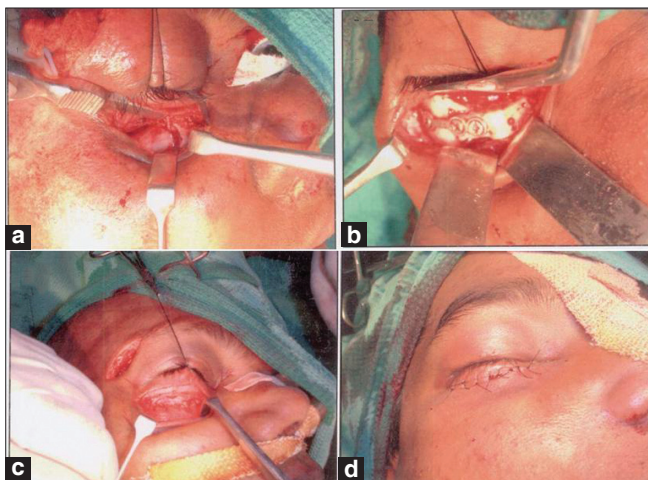


Figure 3: (a) Fracture site exposed (b) Miniplate fixation (c) Multilayer closure (d) Single layer closure

Postoperative phase

- Drugs like amoxicillin, Metrogyl, analgesic and single or tapering dose of steroid was given (depending upon postoperative edema) to control postoperative infections, edema and pain.
- Pressure dressing was given for 24 h to the operated site to control postoperative edema.
- Ice fermentation was given immediately after recovery of the patient from general anesthesia for two hours at the interval of every 20 min.
- Check chart was maintained for
 - Edema
 - Ectropion
 - Epiphora
 - Movement of the globe
 - Lagophthalmos
 - Injury to orbit and contents
 - Infraorbital nerve function
 - Hematoma
 - Asymmetry
 - Postoperative scar formation for a period of 8 weeks

Suture removal was done on the fourth postoperative day. Betadine dressing was given at the operated site and patient was discharged from the ward after five days from the day of surgery. Patient was reviewed every first week, first month and 3rd month postoperatively and found that the individuals responded well with minimal scar formation [Figures 4a, b].

RESULTS

The majority of the participants belonged to the age group of 20 to 32 years. Skin–muscle flap was used in majority of the cases. All patients were administered with steroid injection. Frost sutures were placed in

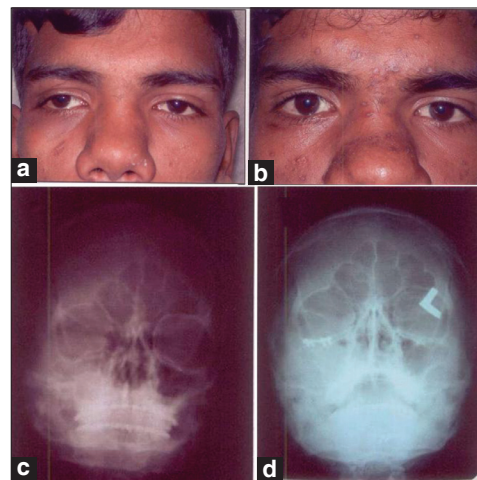


Figure 4: (a) Preoperative appearance (b) Postoperative appearance (c) Preoperative radiograph (d) Postoperative radiograph

four cases and tarsorrhaphy was done in two patients [Table 1]. In the postoperative phase, three cases encountered immediate mild edema and immediate scar formation. Late scar was present only in two patients with a follow up of three months [Table 2].

DISCUSSION

The zygoma is the main buttress between the maxilla and the cranium and is also the principle component of the superficial lateral pillar of a buttress system of platforms and pillars that surround and protect the orbit. Strong impact forces directed to the zygoma are usually absorbed by the fragmentation of the weaker bones with which the zygoma articulates. The frontozygomatic sutures suffer from a clean separation whereas the zygomaticomaxillary buttress area and the medial aspect of the inferior orbital rim will be comminuted. The zygomatic arch will suffer either a single telescoped fracture near its mid point or a double fracture that produces a displaced and possibly rotated central fragment. Therefore fracture dislocation of the zygoma may fragment both ends of the horizontal arc of contour and the lower end of the vertical arc. The degree of this disruption and the amount of displacement of the zygoma determine the severity of the injury and thus the complexity of the needed repair.^[4]

Paranasal sinus view is the most important X-ray to diagnose the infraorbital rim fracture. The possibilities that exist and may be confusing are 1) no fracture 2) pseudo fracture line and 3) fracture line not revealing correctly the amount of displacement. Campbell and Trapnell^[5] lines were used for interpretation of

paranasal sinus view. Hopper *et al.*^[6] and Kaufman Y *et al.*^[7] suggested that the use of conventional radiographs can be supplemented by coronal CT.

Gillie's temporal method is the most frequently used procedure with minimal morbidity and a short duration of general anesthesia.^[8] An additional exposure may be needed for direct fixation with miniplate in certain situations where care is needed to protect infraorbital nerve.^[9] Bradycardia was reported during the elevation of zygomatic arch, which could be due to trigemino-vagal reflex or oculo-cardiac reflex.^[10-12]

Surgical access to the orbital skeleton and periorbital structures through the eyelids and anterior orbit has been accomplished by an array of cutaneous approach. The incisions used for this anatomic area appear to have their origins at least partly in the treatment of zygomatico-orbital and cosmetic blepharoplasty.

Various cutaneous approaches and its indications has been proposed by various authors for approaching orbit, which includes medial brow, lateral brow, lateral canthotomy, upper lid blepharoplasty, bicoronal flap, medial crease, lynch, subciliary, lower lid blepharoplasty and inferior orbital rim incisions.^[13,14]

There are a variety of incisions advocated exclusively for exposure of the lower half of the bony orbit:

- The infraorbital incision made in a natural skin crease which is still commonly used by many surgeons;
- The orbital rim incision made directly over the infraorbital rim;

Table 1: Intraoperative and immediate postoperative assessment

Steroid	Frost	Tarsorrhaphy	Dissection	Suture material		Ice fermentation	Pressure pack
				Muscle	Skin		
8 mg (intra op)	Placed	-	Skin flap	3-0 Vicryl	5-0 silk	-	-
8 mg (intra op)	-	Placed	Skin flap	3-0 Vicryl	5-0 silk	-	-
8 mg (20 min before surgery)	Placed	-	Skin-muscle flap	3-0 Vicryl	5-0 silk	Given	-
8 mg (intra op)	Placed	-	Skin-muscle flap	3-0 Vicryl	5-0 silk	-	-
8 mg (20 min before surgery)	-	Placed	Skin-muscle flap	3-0 Vicryl	5-0 nylon	Given	Given
8 mg (20 min before surgery)	Placed	-	Skin-muscle flap	3-0 Vicryl	5-0 nylon	Given	Given

Table 2: Postoperative assessment

Case no	Edema		Epiphora		Ectropion		Movement of globe		Lagophthalmos		ION function		Hematoma		Scar	
	I	L	I	L	I	L	I	L	I	L	I	L	I	L	I	L
1	M	-	+	-	-	-	N	N	N	N	N	N	-	-	-	-
2	M	M	+	+	-	-	N	N	N	N	N	N	-	-	+	+
3	M	-	+	+	+	+	N	N	N	N	N	N	-	-	+	-
4	-	-	-	-	-	-	N	N	N	N	N	N	-	-	+	+
5	-	-	-	-	-	-	N	N	N	N	N	N	-	-	-	-
6	-	-	-	-	-	-	N	N	N	N	N	N	-	-	+	+

I = Immediate, (+) = Present, N = Normal, L = Late, (-) = Absent, ION = Infraorbital nerve, M = Mild

- The lower lid blepharoplasty incision which can be extended laterally and combined with either pre- or post-orbicularis dissection;
- The transconjunctival incision often combined with lateral canthotomy.

The lid incisions must be used with proper understanding and the orbital function must be assessed postoperatively. Meticulous attention should be given for the protection and care of anterior globe. The thinness of the tissues, edema and bruising may require more postoperative time.

Converse in 1944 introduced the use of subciliary incision for approaching the floor of the orbit and also described about skin–muscle flap technique and skin flap technique. The lower lid blepharoplasty approach allowed a good exposure of the orbital rim and fractures of the orbital floor. Fractures of the lower half of the lateral orbital rim could be reached by a lateral extension of the standard lower blepharoplasty incision. The flexibility of this approach achieved by this extension contrasted favorably with the more conventional infraorbital or orbital rim approach.^[15] The lower lid blepharoplasty post orbicularis approach offers excellent exposure to the lower half of the orbit and is therefore recommended for complicated wiring or plating procedures.^[16]

The skin incision is made 2–3 mm inferior to gray line but it should always be superior to the inferior palpebral fold. The dissection may be anterior or posterior to the orbicularis oculi and care needs to be taken not to penetrate orbital septum and when perforated resorbable sutures should be used to prevent prolapse of fatty tissue. When the rim is exposed, the periosteum is incised 3 mm inferior to it to avoid postoperative tethering of the periorbita and to facilitate good periosteal closure. Pospisil O.A *et al.*^[17] suggested that edema present on the day of operation is the main contributory factor to the development of ectropion and also recommended that operation be deferred until edema has subsided. Fractures of the zygoma are common maxillofacial injuries secondary to nasal fractures. While many of these are of minimal clinical significance, those that possess esthetic deformities or functional limitations demand surgical reduction. A simple towel clips can be used for reduction of isolated fractured zygoma. It is a simple, quick and effective technique with minimal invasive, carries little risk of infection or neurovascular injury and leaves no visible scarring.^[18,19] However, combination of transcutaneous reduction of non-comminuted zygoma, which can be stabilized by external pin fixation is more effective method for immobilization of zygoma.^[20]

The use of miniplates in unstable fractures of the malar complex will result in stable fixation and significantly

increases the greater chance of regeneration of the infraorbital nerve than stabilization of the zygoma with wire sutures.^[21] In case of comminuted zygomatic complex fracture, two-point rigid fixation should be done one at the frontozygomatic suture and another at the infraorbital rim.^[22] Cranial cavity penetration can occur while drilling in the frontozygomatic suture region. In order to avoid the risk of penetration, drilling can be done at an angle of 45 degrees, and 7 mm screws should be used at the frontozygomatic suture area and 5 mm screws should be used above the suture region.^[23]

Miniplates osteosynthesis showed a higher incidence of recovery of infraorbital nerve.^[24] Following reduction of the fractures, the wound is closed in three layers (periosteum, muscle and the skin). Periosteum and muscle are closed with resorbable material whereas skin should be with a fine monofilament suture. The frost suture helps in easier inspection and the insertion of antibiotic ointment to the affected eye.^[17,25] The frost and pressure pack helps to reduce postoperative edema formation.^[26]

A minor complication has been reported by Pospisil like hematoma, partial wound dehiscence, transient lymphedema and a transient or permanent ectropion. Park *et al.*^[27] reported foreign body reaction after placement of resorbable plates and screws.

Although exclusively elaborated to abstain the use of this incision in literature owing to time factor, despite its superior postoperative results, we in our study over a series of six patients (7 incisions) have found no such limitations associated with the use of this incision. The incision allowed for easy dissection, exposure of the infraorbital rim, adequate access to manipulate, reduce and stabilize the fractured segments. Postoperative sequelae was eventful in majority of cases, except for case (3) in which the patient had mild ectropion and epiphora. Scarring was noted in cases 2 and 4.

SUMMARY AND CONCLUSION

This study was undertaken in Rajah Muthiah Dental College and Hospitals between the years 2003 and 2006 to analyze the versatility of “lower eyelid blepharoplasty incision” as an approach in the open reduction and fixation in zygomatic complex injuries. The following conclusions were made:

- It is always indicated to perform a two-point fixation for unstable displaced zygoma fractures
- Lateral frontal and infraorbital fixation is advantageous as it can be performed under direct vision.
- Lower eyelid blepharoplasty incision and approach is

an excellent and adequate approach for exposure of infraorbital rim and floor of the orbit.

- Lower eyelid blepharoplasty incision is technically simple when compared to the other infraorbital approach like transconjunctival and subciliary incisions.
- The correct placement of incision, the stepwise dissection and a proper retraction plays a major role in the outcome of this approach.
- Placement of “frost suture” and “tarsorrhaphy” is a mandatory procedure that has to be followed prior to the incision of the lower eyelid.
- The “frost suture” helps in correct placement of lower eyelid blepharoplasty incision and dissection.
- Injection of steroid do not play a definitive role in postoperative edema control, but anyway a single dose of pre-operative or intraoperative injection of steroids definitively minimizes the postoperative edema.
- Lower eyelid blepharoplasty incision is advantageous in complete reconstruction of the orbital floor.
- The minimal entrapment of the extraocular muscle in the zygomatic complex fractures can be relieved and further prevented by approximate reduction and rigid fixation in the infraorbital region.
- Single layer or multilayer sutures do not really play a role in postoperative esthetic and functional outcome of this approach.
- When plate fixation is done in the infraorbital region, a multilayer suture provides an adequate cover and minimizes the chances of plate exposure.
- Postoperative pressure strips and immediate cold fermentation do minimize the postoperative edema and hematoma.
- Correct placement of incision, step dissection, multilayer closure and postoperative pressure strips minimizes the chances of “ectropion” and “epiphora” and immediate postoperative hematoma.
- Skin–muscle flap is comparatively easy to raise and also minimizes the postoperative edema and ectropion. It also maintains the viability of the flaps and reduces wound dehiscence.

So from the above-mentioned interferences, there is no doubt that lower eyelid blepharoplasty incision is an excellent, non-complicated, simple procedure in the management of fractures in the infraorbital region, orbital floor, which occurs as a part of zygomatic complex fractures.

This approach is adequate for inspection, reduction under direct vision and rigid fixation. The very few complications associated with this procedure can be easily prevented by adapting simple techniques like frost suturing, raising a skin muscle flap etc., when it comes to the principle of two-point fixation in zygomatic complex fractures. This approach can

be adapted, which helps in an appropriate surgical treatment in a minimal time and minimal complications with good esthetic and functional outcome.

REFERENCES

1. Timóteo CA, Chagas JF, Rapoport A, Denardin OV. Evaluation of palpebral subtarsal approach in surgical treatment of orbito-zygomatic fractures. *Rev Col Bras Cir* 2009;36:382-91.
2. Subramanian B, Krishnamurth S, Suresh Kumar P, Saravanan B, Padmanabhan M. Comparison of various approaches for exposure of infraorbital rim fractures of zygoma. *J Maxillofac Oral Surg* 2009;8:99-102.
3. Fonseca, Marciani, Turvey, editors. *Oral and Maxillofacial Surgery*, 2nd ed., Vol. 2. Philadelphia: Elsevier Inc; 2009. p. 190.
4. Evans BG, Evans GR. MOC-PSSM CME article: Zygomatic fractures. *Plast Reconstr Surg* 2008;121:1-11.
5. Booth PW, Schendel SA, Hausamen JE, editors. *Maxillofacial Surgery*, 2nd ed., Vol. 1. Philadelphia: Churchill Livingstone Elsevier Ltd; 2007. p. 278.
6. Hopper RA, Salemy S, Sze RW. Diagnosis of midface fractures with CT: What the surgeon needs to know. *Radiographics* 2006;26:783-93.
7. Kaufman Y, Stal D, Cole P, Hollier L Jr. Orbitozygomatic fracture management. *Plast Reconstr Surg* 2008;121:1370-4.
8. Obuekwe O, Owotade F, Osaiyuwu O. Etiology and pattern of zygomatic complex fractures: A retrospective study. *J Natl Med Assoc* 2005;97:992-6.
9. Olate S, Lima SM Jr, Sawazaki R, Moreira RW, de Moraes M. Surgical approaches and fixation patterns in zygomatic complex fractures. *J Craniofac Surg* 2010;21:1213-7.
10. Lübbers HT, Zweifel D, Grätz KW, Kruse A. Classification of potential risk factors for trigeminocardiac reflex in craniomaxillofacial surgery. *J Oral Maxillofac Surg* 2010;68:1317-21.
11. Joseph JM, Rosenberg C, Zoumalan CI, Zoumalan RA, White WM, Lisman RD. Oculocardiac reflex associated with a large orbital floor fracture. *Ophthal Plast Reconstr Surg* 2009;25:496-8.
12. Rippmann V, Scholz T, Hellmann S, Amini P, Spilker G. The oculocardiac reflex in blepharoplasties. *Handchir Mikrochir Plast Chir* 2008;40:267-71.
13. Fonseca, Marciani, Turvey, editors. *Oral and Maxillofacial Surgery*. 2nd ed., Vol. 2. Philadelphia: Elsevier Inc; 2009. p. 187.
14. Lee K, Snape L. Efficacy of Transcaruncular approach to reconstruct isolated medial orbital fracture. *J Maxillofac Oral Surg* 2010;9:142-5.
15. Booth PW, Schendel SA, Hausamen JE, editors. *Maxillofacial Surgery*, 2nd ed., Vol. 1. Philadelphia: Churchill Livingstone, Elsevier Ltd; 2007. p. 140.
16. Fonseca RJ, Walker RV, Betts NJ, Barber HD, Powers MP, editors. *Oral and Maxillofacial trauma*. 3rd ed., Vol. 2. USA: Elsevier; 2009. p. 655.
17. Pospisil OA, Fernando TD. Review of the lower blepharoplasty incision as a surgical approach to zygomatico-orbital fractures. *Br J Oral Maxillofac Surg* 1984;22:261-8.
18. Carter TC, Bagheri S, Dierks EJ. Towel clip reduction of the depressed zygomatic arch fracture. *J Oral Maxillofac Surg* 2005;63:1244-6.
19. Manzon S, Choudhary N, Philbert R. Towel clip reduction of the depressed zygomatic arch fracture. *J Oral Maxillofac Surg* 2006;64:1323-4.
20. Park BY, Song SY, Yun IS, Lee DW, Rah DK, Lee WJ. First percutaneous reduction and next external suspension with Steinmann pin and Kirschner wire of isolated zygomatic fractures. *J Craniofac Surg* 2010;21:1060-5.
21. Yonehara Y, Hirabayashi S, Tachi M, Ishii H. Treatment of zygomatic fractures without inferior orbital rim fixation. *J Craniofac Surg* 2005;16:481-5.
22. Lee PK, Lee JH, Choi YS, Oh DY, Rhie JW, Han KT, *et al.* Single transconjunctival incision and two-point fixation for the treatment of noncomminuted zygomatic complex fracture. *J Korean Med Sci*

- 2006;21:1080-5.
23. Chrcanovic BR, Cavalcanti YS, Reher P. Temporal miniplates in the frontozygomatic area-an anatomical study. *Oral Maxillofac Surg* 2009;13:201-6.
24. Sakavicius D, Juodzbaly G, Kubilius R, Sabalys GP. Investigation of infraorbital nerve injury following zygomaticomaxillary complex fractures. *J Oral Rehabil* 2008;35:903-16.
25. Sharabi SE, Koshy JC, Thornton JF, Hollier LH Jr. Facial fractures. *Plast Reconstr Surg* 2011;127:25e-34e.
26. Krishnan R, Izadi S, Morton CE, Marsh IB. Use of Frost sutures in an orbital trauma patient with extensive conjunctival oedema and pseudoproptosis. *Int J Oral Maxillofac Surg* 2007;36:649-51.
27. Park CH, Kim HS, Lee JH, Hong SM, Ko YG, Lee OJ. Resorbable skeletal fixation systems for treating maxillofacial bone fractures. *Arch Otolaryngol Head Neck Surg* 2011;137:125-9.

How to cite this article: Chandran V, Candamoury R, Thangavelu A. The versatility of lower eyelid blepharoplasty incision: In open reduction and fixation of zygomatic complex injuries. *J Nat Sc Biol Med* 2012;3:161-7.

Source of Support: Nil. **Conflict of Interest:** None declared.

Announcement

iPhone App



Download
iPhone, iPad
application

FREE

A free application to browse and search the journal's content is now available for iPhone/iPad. The application provides "Table of Contents" of the latest issues, which are stored on the device for future offline browsing. Internet connection is required to access the back issues and search facility. The application is Compatible with iPhone, iPod touch, and iPad and Requires iOS 3.1 or later. The application can be downloaded from <http://itunes.apple.com/us/app/medknow-journals/id458064375?ls=1&mt=8>. For suggestions and comments do write back to us.