

Thyrotoxic periodic paralysis associated with Graves' disease: a case series

S Ludgate¹, M Lin¹, M Mayadunne¹, J Steen¹ and K W Ho^{1,2,3}

¹Department of Diabetes and Endocrinology, Ryde Hospital, Eastwood, New South Wales, Australia, ²Department of Medicine, Macquarie University, Sydney, Australia, and ³Department of Medicine, University of Western Sydney, Sydney, Australia

Correspondence
should be addressed
to S Ludgate
Email
ludgates@tcd.ie

Summary

Thyrotoxic periodic paralysis (TPP) is a rare condition characterised by acute onset hypokalaemia and paralysis which most commonly affects men of Asian descent between the ages of 20 and 40 years (1, 2). It has been reported in approximately 2% of patients with thyrotoxicosis in China and Japan (1, 2, 3). Hypokalaemia in TPP results from a massive intracellular shift of potassium induced by the thyroid hormone sensitisation of Na⁺/K⁺-ATPase (4). Treatment of TPP includes prevention of this shift by using beta-blockade, rapid potassium replacement and treatment of the underlying hyperthyroidism. We present two cases of TPP with differing outcomes. In the first case, a 33-year-old Filipino gentleman presented to our emergency department (ED) with a 3-month history of recurrent proximal lower limb weakness. Serum potassium was 2.2 mmol/L (3.3–5.1) and he was given i.v. potassium replacement. Thyroid function tests (TFTs) and thyroid antibodies were consistent with Graves thyrotoxicosis. He was discharged home on carbimazole and remains well controlled on long-term medical therapy. In the second case, a 22-year-old Malaysian gentleman presented to our ED with new-onset bilateral lower limb painless paralysis. Serum potassium was 1.9 mmol/L with TFTs demonstrating Graves thyrotoxicosis. He was treated with i.v. potassium replacement and discharged home on carbimazole and propranolol. He represented to the hospital on two further occasions with TPP and was advised to consider total thyroidectomy given his refractory Graves' disease. These cases highlight the importance of prompt recognition of this rare life-threatening complication of Graves' disease, especially in patients of Asian descent.

Learning points:

- Thyrotoxic periodic paralysis is a rare condition characterised by hypokalaemia and acute painless muscle weakness in the presence of thyrotoxicosis.
- The signs and symptoms of thyrotoxicosis can be subtle in these patients.
- It is most commonly seen in Asian males between the ages of 20 and 40 and is most frequently caused by Graves' disease.
- Prompt recognition is essential as it is a life-threatening condition.
- Urgent i.v. potassium replacement and beta-blockade with a non-selective beta-blocker are the mainstays of treatment.
- i.v. potassium replacement should not be given in dextrose as this can potentiate hypokalaemia.

Background

Thyrotoxic periodic paralysis (TPP) is a form of familial hypokalaemic periodic paralysis that occurs in association with hyperthyroidism. Any aetiology of hyperthyroidism can be associated with TPP however it is most commonly due to Graves' disease (5). TPP is a rare, potentially life-threatening complication of hyperthyroidism, defined by three characteristic features: thyrotoxicosis, hypokalaemia and acute painless muscle weakness (1). TPP most commonly affects males and is most frequently seen in Asian populations (3). Onset is between the ages of 20 and 40 years in approximately 80% of cases (1). The incidence of TPP in Asian populations with hyperthyroidism has been reported as 2% compared with non-Asian populations, in which the incidence of TPP is estimated at 0.1–0.2% (1, 2, 6). Triggers for TPP include high carbohydrate meals, intense physical exercise, periods of high emotional stress, diarrhoea, and medications among others (7). It should be noted that signs and symptoms of thyrotoxicosis can be mild in TPP (8).

Case presentation

Case 1

A 33-year-old Filipino gentleman presented to our emergency department (ED) with difficulty in moving his lower limbs after waking from sleep. He reported multiple similar episodes over the previous 3 months occurring up to four times per week. This was associated with unintentional weight loss of 6 kg. There were no sensory disturbances, bowel/bladder dysfunction, back pain or fevers. Both his past medical history and family history were unremarkable.

Serum blood tests showed a potassium level of 2.2 mmol/L (3.3–5.1) with no other abnormalities of note (Table 1). ECG showed a prolonged QTc interval of 584 ms (Fig. 1). Lower limb neurological examination revealed proximal weakness but preserved tone, reflexes and sensation. It was noted that bilateral hand tremors, mild exophthalmos and a small goitre with bruit were present.

Hypokalaemic periodic paralysis was initially suspected however given the abnormal clinical signs thyroid function tests and thyroid antibodies were requested.

Case 2

A 22-year-old Malaysian gentleman presented to our ED having awoken from sleep with new-onset bilateral lower-limb paralysis. He did not report any pain or similar

previous episodes. In the weeks prior to this episode, he had been complaining of weight loss, tremors, night sweats and insomnia and had recently taken up running prior to his presentation.

His medical history was significant for hyperthyroidism diagnosed 2 years earlier by his general practitioner. He was treated with carbimazole but decided to stop it after 2 months as his symptoms of palpitations had improved.

Blood tests returned a potassium level of 1.9 mmol/L with no other abnormalities of note (Table 2). ECG showed sinus tachycardia with deep T wave inversion (Fig. 2). Clinical examination revealed absent power and reflexes of the lower limb with preserved tone and sensation. He was tachycardic with bilateral hand tremor. The thyroid gland was non-enlarged and there was no evidence of thyroid eye disease.

TPP was suspected and TFTs and thyroid antibodies were requested.

Investigation

Case 1

A diagnosis of Graves' hyperthyroidism was made following the results of his TFTs and positive thyroid-stimulating hormone (TSH) receptor antibodies (Table 3).

Case 2

Graves' hyperthyroidism was confirmed following the results of his TFTs and positive TSH receptor antibody (Table 4). Thyroid ultrasound showed mildly enlarged thyroid gland with heterogenous echotexture and diffusely increased vascularity (Fig. 3A, B, C and D). No discrete thyroid nodules were identified.

Table 1 Biochemistry results including potassium trend following replacement (case 1).

	D1 11:35	D1 19:07	D2 08:10
K ⁺ (mmol/L)	2.2 (3.3–5.1)	4.3	4.9
Na ⁺ (mmol/L)	142 (133–145)		
Creatinine (umol/L)	60 (50–120)		
Urea (mmol/L)	5.0 (3–7)		
Chloride (mmol/L)	107 (98–111)		
Bicarb (mmol/L)	24 (20–24)		
eGFR (mL/min/..)	125 (>59)		
Phosphate (mmol/L)	0.74 (0.8–1.5)		
Magnesium (mmol/L)	0.80 (0.65–1.05)		

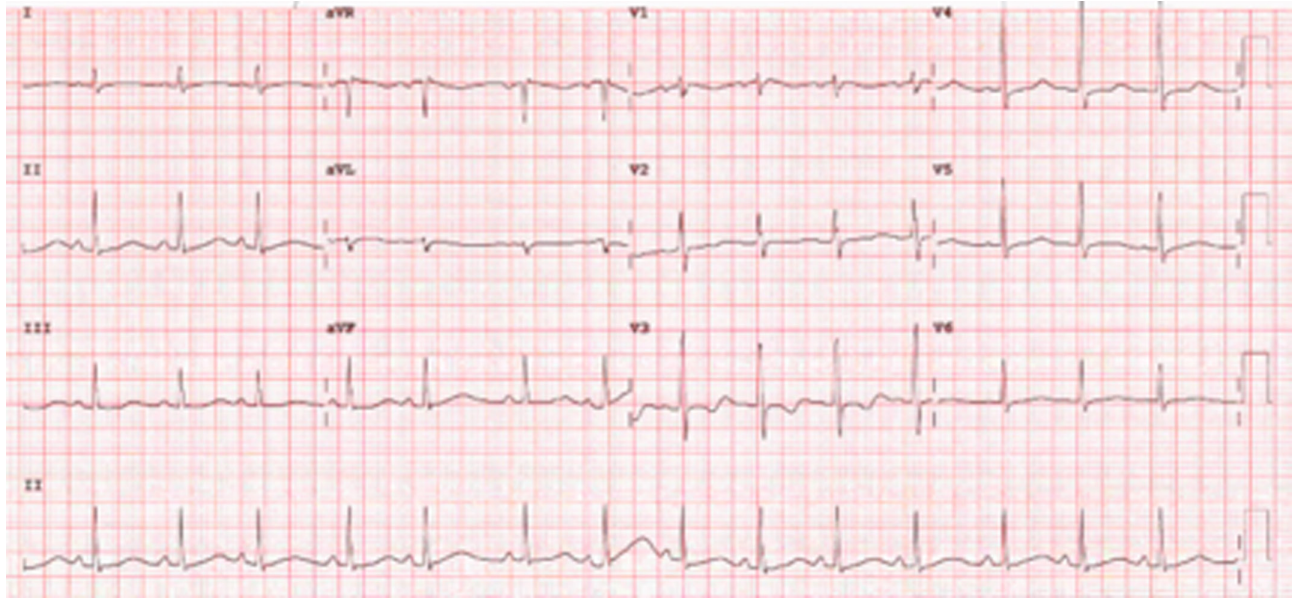


Figure 1
ECG showing QTc prolongations of 548 ms (case 1).

Treatment

Case 1

The patient was commenced on i.v. potassium replacement immediately. He was charted for three bags of 10 mmol potassium chloride in 100 mL 0.9% normal saline and serum potassium improved from 2.2 to 4.3 mmol/L (Table 1). He was maintained on oral potassium replacement (16 mmol twice daily) while inpatient.

His thyrotoxicosis was controlled with carbimazole 15 mg once daily. Full blood count and liver function tests were checked on admission, prior to the commencement of carbimazole, and he was found to have a normal white blood cell count and normal transaminases. He was mildly tachycardic (90–100 b.p.m.) but asymptomatic and did

not require regular beta-blocker therapy. He was discharged on day 2 of admission.

Case 2

Given the severe hypokalaemia of 1.9 mmol/L the patient was transferred to the high dependency unit in our facility. He received three bags of 10 mmol potassium chloride in 100 mL 0.9% normal saline. Serum potassium improved to 3.3 mmol/L following i.v. replacement and the patient regained full function in his lower limbs. He was maintained on oral potassium replacement (28 mmol three times daily).

His thyrotoxicosis was treated with carbimazole 15 mg twice daily, propranolol 10 mg twice daily and a 2-week course of prednisolone (25 mg daily for 7 days then 12.5 mg daily for 7 days). Full blood count and liver function tests were normal on admission. He was discharged home on day 2 of admission and booked for urgent endocrine follow-up. Oral potassium replacement was continued for a further week.

Table 2 Biochemistry results including potassium trend following replacement (case 2).

	D1 06:06	D1 10:45	D2 07:05	D3 07:21
K ⁺ (mmol/L)	1.9 (3.3–5.1)	3.3	3.8	4.1
Na ⁺ (mmol/L)	141 (133–145)			
Creatinine (umol/L)	55 (50–120)			
Urea (mmol/L)	6.1 (3–7)			
Chloride (mmol/L)	108 (98–111)			
Bicarb (mmol/L)	23 (20–24)			
eGFR (mL/min/..)	140 (>59)			
Phosphate (mmol/L)	0.50 (0.8–1.5)			
Magnesium (mmol/L)	0.78 (0.65–1.05)			

Outcome and follow-up

Case 1

The patient was followed up regularly in the endocrinology outpatient clinic. He regained the weight that he lost and his goitre resolved with minimal residual thyroid bruit. He was clinically and biochemically euthyroid. Carbimazole was reduced to 5 mg daily after 3 months.

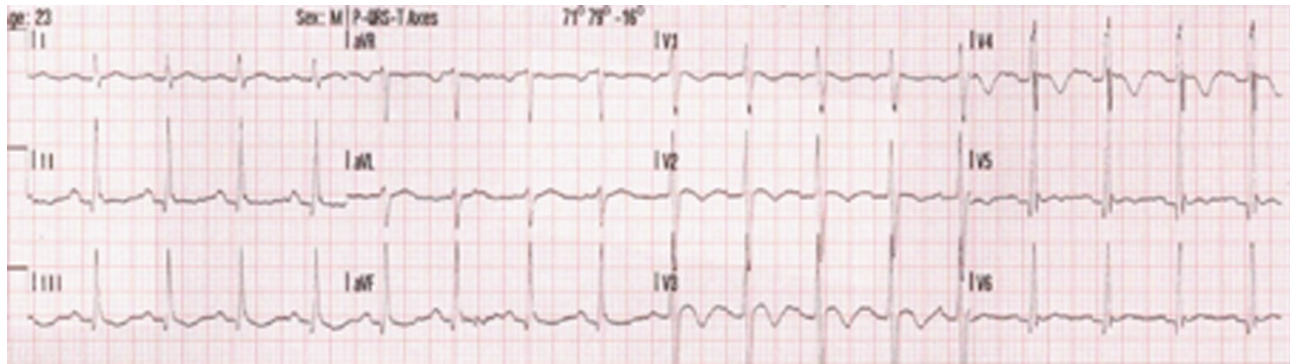


Figure 2
ECG showing sinus tachycardia with deep T wave inversion (case 2).

Over the next 2 years, he reported no further episodes of TPP. However, his TSH receptor antibody levels remained persistently elevated. After a discussion of the available definitive treatment options, the patient expressed that he would like to continue on anti-thyroid medications. He has been advised to continue carbimazole therapy indefinitely to prevent relapse of his Grave's disease which could trigger further episodes of TPP. He was also advised that definitive management could be re-visited in the future.

Case 2

The patient was seen in the endocrine outpatient clinic 4 weeks following discharge. He reported some weight gain and improved sleep. However, he still had ongoing mild tremor and occasional palpitations. Carbimazole was continued at 15 mg twice daily given his ongoing elevated free T4 and TSH receptor antibody.

Unfortunately, he presented to the hospital on two further occasions with episodes of TPP. The first recurrence was at 9 months post initial discharge where he reported generalised leg weakness and was found to have serum potassium of 2.1 mmol/L. He was treated with i.v. potassium replacement in the emergency department and discharged home on the same day on oral potassium replacement pro re nata (PRN) to take if he developed further leg weakness.

The second recurrence was at 10-month post initial discharge where he presented with lower-limb paralysis and serum potassium of 2.4 mmol/L. TSH remained suppressed at <0.004 mIU/L and free T4 was elevated at 53 pmol/L. Carbimazole was increased to 15 mg three times a day and

he was commenced on a 2-week course of prednisolone. He was advised to consider total thyroidectomy for definitive management of his Graves' disease however he moved overseas and was lost to follow up.

Discussion

As previously stated, TPP is rare with an incidence of 2% in Asian populations with hyperthyroidism compared with 0.1–0.2% in non-Asian populations (1, 2, 6). It is observed more frequently in males than in females, which is atypical for thyroid disease presentations (1).

Familial hypokalaemic periodic paralysis (FHPP) is a genetic condition characterised by episodes of muscle weakness associated with low serum potassium levels. Episodes typically involve weakness in the upper or lower limbs as seen in our case. FHPP is frequently caused by mutations in one of three known genes involved in the formation of ion channels in skeletal muscle; CACNA1S which encodes voltage-gated calcium channels, SCN4A which encodes sodium channels or KCNJ18 which encodes the inwardly rectifying potassium channel *Kir2.6*, and subunits of the Na/K-ATPase genes (9). Mutations in these genes impair the regulation of ion flow in skeletal muscle and this impairment can reduce the ability of the skeletal muscle to contract, leading to episodes of weakness/paralysis. These genes are inherited in an autosomal dominant manner (9). The skeletal muscle is the largest store of potassium in the body and plays a large role in the homeostasis of the electrolyte (4). It is important to note that not all people who are diagnosed with FHPP have one

Table 3 Thyroid function test and TSH receptor antibody levels (case 1).

TSH	Free T4	Free T3	TSH Receptor Ab
<0.004 mIU/L (0.27–4.2)	31.1 pmol/L (12–22)	17.3 pmol/L (3.1–6.8)	12 IU/L (<1.8 IU/L)

Table 4 Thyroid function test and TSH receptor antibody levels (case 2).

TSH	Free T4	Free T3	Anti-TPO Ab	TSH receptor Ab	Thyroglobulin Ab
<0.004 mIU/L (0.27–4.2)	60.0 pmol/L (12–22)	>46.1 pmol/L (3.1–6.8)	<5.6 kIU/L (<34)	19 IU/L (<1.8 IU/L)	16 kIU/L (<4)

of the above mutations, suggesting that other unidentified mutations may be involved.

While they have identical clinical presentations, the pathogenesis of hypokalaemia in TPP differs slightly from that of FHPP. Hypokalaemia in TPP results from a massive intracellular shift of potassium induced due to thyroid hormone sensitisation of sodium-potassium ATP pump activity (Na^+/K^+ -ATPase) in the cell wall as well as upregulating the transcription factors that encode this pump at a genomic level (4). Na^+/K^+ -ATPase drives potassium to the intracellular space and as a result, hypophosphatemia can also be observed, as was seen in case 2. It has been suggested that the same mutations that cause FHPP may be involved in TPP. While some studies have identified mutations in these genes in cases

of TPP, the mutations are not present in all cases; however, it does suggest that there may be a genetic component to TPP. Some studies have also shown mutations in the *KCNJ18* gene in patients with TPP which encodes inwardly rectifying potassium channel *Kir2.6* and put forward convincing evidence that these mutations may have a role in the condition by exacerbating hypokalaemia, leading to paralysis (4). Unfortunately, in our cases, it was not possible to send any screening tests for genetic mutations.

Thyroid hormone also increases tissue sensitivity to beta-adrenergic stimulation which potentiates the hypokalaemic effects of adrenaline and insulin (10). This is the reason for several triggers for TPP such as carbohydrate intake, emotional stress or exercise. The patient in our second case had recently taken up running which was

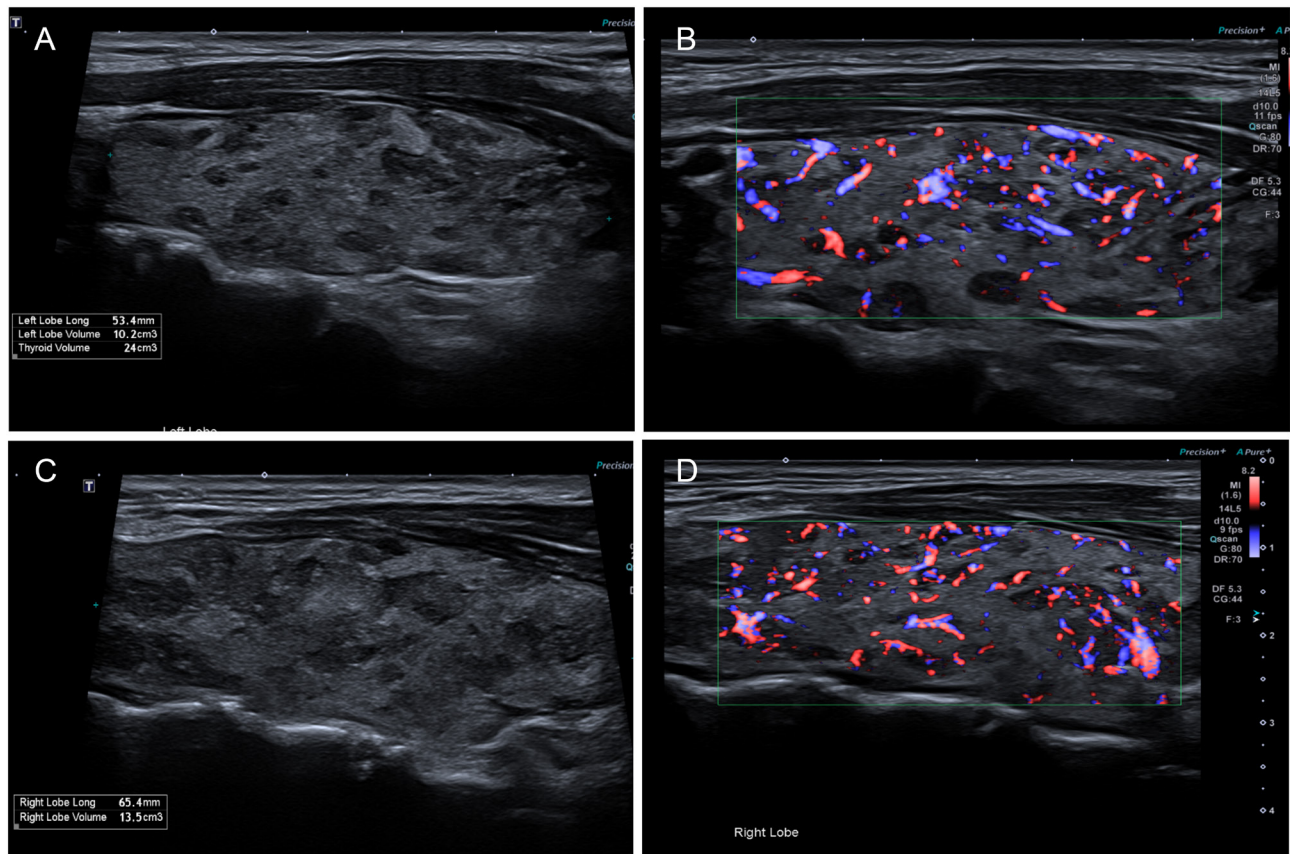


Figure 3

Thyroid ultrasound (A) and (B) Longitudinal views of the structurally normal left lobe with increased vascularity on colour Doppler, which can be seen in the setting of Graves' disease. (C) and (D) demonstrating the same findings in the right lobe (all case 2).



the likely trigger for his episode. Hyperinsulinemia has also been observed in TPP which suggests that the hypokalaemic effects of insulin can play a role. For this reason, it is important that i.v. potassium replacement should not be administered in dextrose as this can potentiate hypokalaemia due to insulin release. The pathogenesis for why this phenomenon is more commonly seen in males is not fully understood; however, it has been hypothesised that it may be caused by more androgen-induced Na⁺/K⁺-ATPase sensitisation or more pronounced hyper-insulinaemia in males (11). Comparatively higher sympathetic and catecholamine-induced Na⁺-K⁺ ATPase activity in males and increase of muscle mass in males have also been described as possible mechanisms (11).

The mainstays of treatment of TPP include prevention of the potassium shift using beta-blockade, rapid potassium replacement and treatment of the underlying hyperthyroidism (12). In our cases i.v. potassium replacement was administered immediately however the diagnoses of TPP were not initially recognised and so beta-blockade was not administered in the acute phase of treatment. Non-selective beta-blockers such as propranolol should be considered first line. It is important to note that hypokalaemia is caused by an intracellular shift rather than total body losses and so aggressive potassium replacement can result in rebound hyperkalaemia (11). The treatment of the underlying Graves' disease should follow recognised guidelines such as the European Thyroid Association Guidelines. They recommend anti-thyroid medications as a first-line treatment however radioactive iodine or total thyroidectomy is recommended for patients who remain hyperthyroid despite treatment with oral medication (13). Given the failed response to anti-thyroid drugs, the patient in our second case was offered total thyroidectomy to prevent further episodes of TPP.

Hyperthyroidism should be considered in all patients who present with acute painless muscle weakness. It is essential to be aware of the importance of beta-blockade in the initial treatment. Potassium should be replaced intravenously in a non-glucose-containing fluid. Given the life-threatening association of severe hypokalaemia, it is vitally important for endocrinologists and emergency physicians to recognise TPP as an important cause. It can be easy to miss TPP due to its rarity and complexities of diagnosis. With increasing rates of migration around the world, this condition will be seen more commonly in all geographic locations.

Declaration of interest

The authors declare that there is no conflict of interest that could be perceived as prejudicing the impartiality of the research reported.

Funding

This work did not receive any specific grant from any funding agency in the public, commercial or not-for-profit sector.

Patient consent

Both written and informed consent have been gained from the patients where possible and have been submitted along with the manuscript.

Author contribution statement

S Ludgate – Endocrinology Registrar involved in care of patients and responsible for first draft of the manuscript and literature review. M Lin – Endocrinology Registrar involved in care of patients and involved in drafting and review of manuscript. M Mayadunne – Endocrinology Registrar involved in care of patients and data collection for manuscript. J Steen – Registrar involved in care of patients and involved in drafting and review of manuscript. K W Ho – Consultant Endocrinologist responsible for care of both patients and review of and preparation of final draft of manuscript.

References

- 1 McFadzean AJ & Yeung R. Periodic paralysis complicating thyrotoxicosis in Chinese. *BMJ* 1967 **1** 451–455. (<https://doi.org/10.1136/bmj.1.5538.451>)
- 2 Okinaka S, Shizume K, Iino S, Watanabe A, Irie M, Noguchi A, Kuma S, Kuma K & Ito T. The association of periodic paralysis and hyperthyroidism in Japan. *Journal of Clinical Endocrinology and Metabolism* 1957 **17** 1454–1459. (<https://doi.org/10.1210/jcem-17-12-1454>)
- 3 Kung AW. Clinical review: Thyrotoxic periodic paralysis: a diagnostic challenge. *Journal of Clinical Endocrinology and Metabolism* 2006 **91** 2490–2495. (<https://doi.org/10.1210/jc.2006-0356>)
- 4 Lin SH & Huang CL. Mechanism of thyrotoxic periodic paralysis. *Journal of the American Society of Nephrology* 2012 **23** 985–988. (<https://doi.org/10.1681/ASN.2012010046>)
- 5 Ali Chaudhry MA & Wayangankar S. Thyrotoxic periodic paralysis: a concise review of the literature. *Current Rheumatology Reviews* 2016 **12** 190–194. (<https://doi.org/10.2174/1573397112666160404124822>)
- 6 Ober KP. Thyrotoxic periodic paralysis in the United States. Report of 7 cases and review of the literature. *Medicine* 1992 **71** 109–120. (<https://doi.org/10.1097/00005792-199205000-00001>)
- 7 Lulsegged A, Wlodek C & Rossi M. Thyrotoxic periodic paralysis: case reports and an up-to-date review of the literature. *Case Reports in Endocrinology* 2011 **2011** 867475. (<https://doi.org/10.1155/2011/867475>)
- 8 Bernard JD, Larson MA & Norris Jr FH. Thyrotoxic periodic paralysis in Californians of Mexican and Filipino ancestry. *California Medicine* 1972 **116** 70–74.
- 9 Weber F & Lehmann-Horn F. Hypokalemic periodic paralysis. *GeneReviews* 2002 [Updated 26 July 2018].
- 10 Williams LT, Lefkowitz RJ, Watanabe AM, Hathaway DR & Besch Jr HR. Thyroid hormone regulation of beta-adrenergic receptor number.



Journal of Biological Chemistry 1977 **252** 2787–2789. ([https://doi.org/10.1016/S0021-9258\(17\)40528-X](https://doi.org/10.1016/S0021-9258(17)40528-X))

- 11 Chakraborty J, Chakraborty S & Moitra R. Thyrotoxic periodic paralysis: an update. *Journal of Endocrinology and Metabolism* 2020 **10** 60–62. (<https://doi.org/10.14740/jem662>)
- 12 Lin SH & Lin YF. Propranolol rapidly reverses paralysis, hypokalemia, and hypophosphatemia in thyrotoxic periodic paralysis. *American*

Journal of Kidney Diseases 2001 **37** 620–623. (<https://doi.org/10.1053/ajkd.2001.22090>)

- 13 Kahaly GJ, Bartalena L, Hegedüs L, Leenhardt L, Poppe K & Pearce SH. 2018 European Thyroid Association guideline for the management of Graves' hyperthyroidism. *European Thyroid Journal* 2018 **7** 167–186. (<https://doi.org/10.1159/000490384>)

Received in final form 29 December 2021

Accepted 17 January 2022