



# Persistent pruritus following COVID-19 vaccination

C. Doyle<sup>1</sup> · Richard E. Watchorn<sup>1</sup>

Received: 11 February 2022 / Accepted: 15 February 2022  
© The Author(s), under exclusive licence to Royal Academy of Medicine in Ireland 2022

**Keywords** COVID · Drug rash · mRNA vaccine · Pfizer · Phototherapy · Vaccination

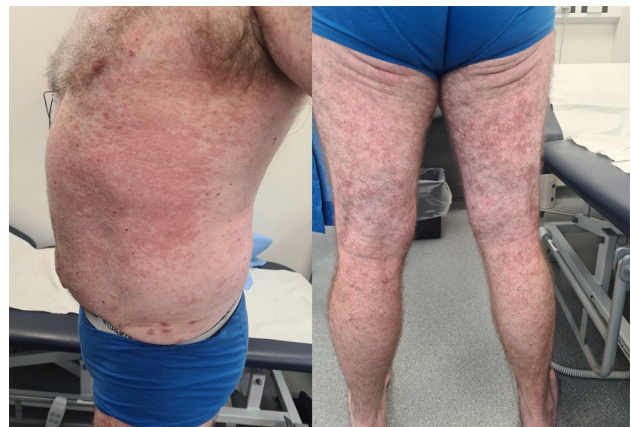Dear editor,

We report a case of a persistent pruritic morbilliform rash that occurred after receiving the second dose of the Pfizer-BioNTech COVID-19 mRNA vaccine. The patient ultimately required specialist dermatology input for treatment of his persistent pruritus.

## Case

A 59-year-old man presented with a widespread morbilliform rash after receiving the second dose of the Pfizer-BioNTech COVID-19 mRNA vaccine. He had no significant medical history and no known allergies. He did not take any regular medication. He had not taken any prescription or over the counter medication prior to this presentation. He had no dermatological history and had no family history of eczema or psoriasis. He developed widespread pruritus without rash four hours after his first vaccine. This resolved after 10 days without intervention. One day following his second dose, he developed an extensive pruritic morbilliform eruption on his trunk and limbs affecting 35% of his body surface area (Fig. 1). There was no mucous membrane involvement. He initially visited his general practitioner who commenced a short course of oral steroids in combination with potent topical steroids with no benefit. Four weeks after rash onset, he was reviewed by dermatology. Eosinophils were raised at 0.54, and liver function tests (LFTs) were normal. ANA and ENA were negative. Complement levels were normal. Histology showed mild epidermal acanthosis, spongiosis, and subcorneal vesicles. Within the superficial to mid dermis,

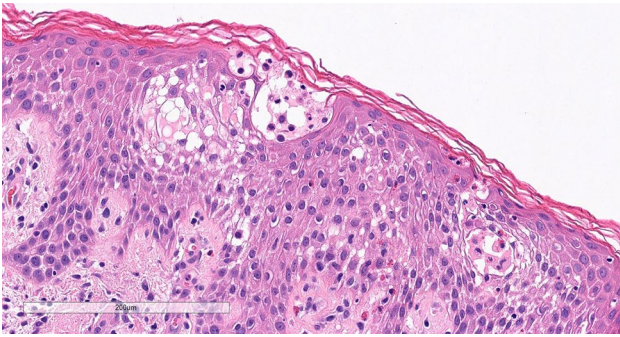
there was a mixed chronic inflammatory infiltrate comprising lymphocytes, plasma cells, neutrophils, and numerous eosinophils (Fig. 2). Direct immunofluorescence was negative. He received a tapering dose of oral prednisolone (initially 0.5mg/kg tapering by 5mg per week) in combination with mometasone topically. Despite substantial improvement with this regimen, his rash began to worsen 2 days following discontinuation of oral prednisolone. He was still using daily mometasone on cessation of oral steroids. He was trialled on oral doxycycline for 1 month, which leads to a significant improvement in his morbilliform rash. Despite improvement in the rash, the patient reported ongoing intense daily pruritus which was having a marked impact on his quality of life. Dermatology Quality of Life Index (DLQI) was 24 at this time. As his main issue was pruritus without rash, he was referred for narrowband UVB phototherapy (TL01). He completed 30 sessions of TL01 with 20% 2 increments without complication. His pruritus has now resolved following this course of TL01.



**Fig. 1** Morbilliform rash on trunk and lower limbs

✉ C. Doyle  
doylec32@tcd.ie

<sup>1</sup> Department of Dermatology, Beaumont Hospital, Beaumont Road, Dublin 9, Ireland



**Fig. 2** H&E stain showing mild epidermal acanthosis, spongiosis and sub-corneal vesicles. Eosinophils can be seen

## Discussion

Morbilliform eruptions have been reported as a cutaneous manifestation of COVID-19 [1] and as a side effect of mRNA vaccines [2]. Proposed mechanisms for the development of skin rashes post mRNA vaccines include viral protein expression following vaccination [3], prior infection with COVID-19 causing cross-reaction with the mRNA vaccine encoded antigen [4], and vaccine components acting as haptens inducing a Th2 inflammatory reaction characterised by IL-4 and IL-13 expression [4]. Drug-induced maculopapular eruptions typically resolve within 7–14 days on withdrawal of culprit medication [5]. The use of phototherapy to treat inflammatory dermatoses and pruritic conditions such as nodular prurigo is well described. The anti-pruritic effect of phototherapy is thought to work via modulation of both the neural pathways involved in itch and local immune cells in the skin [6].

The persistent nature in this case may imply a complex immune response. In this case, the rash persistent for 3 months with associated recalcitrant pruritus that ultimately required specialist dermatology input to ensure resolution.

This case highlights that phototherapy can be utilised in the treatment of cutaneous side effects that arise after COVID-19 vaccines. To the best of our knowledge, this case is one of the first to utilise narrowband UVB phototherapy to treat a cutaneous side effect of an mRNA vaccine. Reporting heterogeneous emerging reactions is a crucial step towards developing a better understanding of them and has the potential to influence vaccination strategies and public health policy.

## Declarations

**Competing interests** The authors declare no competing interests.

## References

1. Kulkarni RB, Lederman Y, Afiari A et al (2020) Morbilliform rash: an uncommon herald of SARS-CoV-2. *Cureus* 12(7):e9321. <https://doi.org/10.7759/cureus.9321> PMID:32850199; PMCID:PMC7444743
2. Jedlowski PM, Jedlowski MF (2021) Morbilliform rash after administration of Pfizer-BioNTech COVID-19 mRNA vaccine. *Dermatol Online J* 27(1). <https://doi.org/10.5070/D3271052044> <https://escholarship.org/uc/item/4xs486zg>
3. Ohsawa R, Sano H et al (2021) Clinical and histopathological views of morbilliform rash after COVID-19 mRNA vaccination mimic those in SARS-CoV-2 virus infection-associated cutaneous manifestations. *J Dermatol Sci Publish.* <https://doi.org/10.1016/j.jdermsci.2021.06.006>
4. Niebel D, Novak N, Wilhelmi J et al (2021) Cutaneous adverse reactions to COVID-19 vaccines: insights from an immuno-dermatological perspective. *Vaccines* 9:944. <https://doi.org/10.3390/vaccines909094>
5. Crisafulli G, Franceschini F, Caimmi S et al (2019) Mild cutaneous reactions to drugs. *Acta Biomed* 90(3-S):36–43. <https://doi.org/10.23750/abm.v90i3-S.8159>. Published 2019 Jan 28
6. Zhong CS, Elmariah SB (2020) Phototherapy for Itch. *Dermatol Clin* 38(1):145–155. <https://doi.org/10.1016/j.det.2019.08.008>

**Publisher's Note** Springer Nature remains neutral with regard to jurisdictional claims in published maps and institutional affiliations.