



CASE REPORT

REVISED Case Report: Isolated, unilateral oculomotor palsy with anti-GQ1b antibody following COVID-19 vaccination [version 2; peer review: 2 approved]

Takafumi Kubota , Takafumi Hasegawa , Kensuke Ikeda, Masashi Aoki

Department of Neurology, Tohoku University Graduate School of Medicine, Sendai, Miyagi, 980-8574, Japan

V2 First published: 11 Nov 2021, **10**:1142
<https://doi.org/10.12688/f1000research.74299.1>

Latest published: 05 Apr 2022, **10**:1142
<https://doi.org/10.12688/f1000research.74299.2>

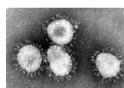
Abstract

Neurological complications following vaccinations are extremely rare, but cannot be eliminated. Here, we report the first case of unilateral oculomotor nerve palsy (ONP) with anti-GQ1b antibody after receiving the Pfizer-BioNTech COVID-19 (BNT162b2) mRNA vaccine.

A 65-year-old man developed diplopia and ptosis in the right eye 17 days after vaccination, without preceding infection. Neurological examination revealed mild blepharoptosis, limitation of adduction, and vertical gaze on the right side. Increased levels of anti-GQ1b ganglioside antibody in the serum and albuminocytologic dissociation in the cerebrospinal fluid were detected. Cranial magnetic resonance imaging showed swelling and enhancement of the right oculomotor nerve. The patient was diagnosed with right ONP accompanied with anti-GQ1b antibody, and intravenous immunoglobulin (IVIG) therapy for 5 days was administered. The limitation of adduction and vertical gaze improved, and ptosis markedly resolved after IVIG treatment. Given the temporal sequence of disease progression, laboratory findings, and a favorable response to IVIG, a causal relationship cannot be ruled out between the occurrence of ONP and COVID-19 immunization. Since immunomodulatory treatments significantly hasten the recovery and minimize the residual symptoms in anti-GQ1b antibody syndrome, clinicians should be aware of this clinical condition following COVID-19 vaccination.

Keywords

oculomotor nerve palsy, Miller Fisher syndrome, anti-GQ1b antibody, ganglioside, COVID-19, vaccination, IVIG



This article is included in the **Coronavirus** collection.

Open Peer Review

Approval Status

	1	2
version 2 (revision) 05 Apr 2022	 view	 view
version 1 11 Nov 2021	 view	 view

1. **Chieko Suzuki**, Hirosaki University, Hirosaki, Japan

2. **Miguel García-Grimshaw** , Instituto Nacional de Ciencias Médicas y Nutrición Salvador Zubirán, Mexico City, Mexico
 Hospital General Tijuana, Tijuana, Mexico

Any reports and responses or comments on the article can be found at the end of the article.

Corresponding author: Takafumi Hasegawa (thasegawa@med.tohoku.ac.jp)

Author roles: **Kubota T:** Conceptualization, Formal Analysis, Investigation, Methodology, Project Administration, Resources, Validation, Visualization, Writing – Original Draft Preparation; **Hasegawa T:** Conceptualization, Formal Analysis, Investigation, Methodology, Project Administration, Resources, Validation, Visualization, Writing – Original Draft Preparation; **Ikeda K:** Investigation; **Aoki M:** Supervision

Competing interests: No competing interests were disclosed.

Grant information: The author(s) declared that no grants were involved in supporting this work.

Copyright: © 2022 Kubota T *et al.* This is an open access article distributed under the terms of the [Creative Commons Attribution License](#), which permits unrestricted use, distribution, and reproduction in any medium, provided the original work is properly cited.

How to cite this article: Kubota T, Hasegawa T, Ikeda K and Aoki M. **Case Report: Isolated, unilateral oculomotor palsy with anti-GQ1b antibody following COVID-19 vaccination [version 2; peer review: 2 approved]** F1000Research 2022, 10:1142 <https://doi.org/10.12688/f1000research.74299.2>

First published: 11 Nov 2021, 10:1142 <https://doi.org/10.12688/f1000research.74299.1>

REVISED Amendments from Version 1

We added the information about the sensitivity and specificity of anti-GQ1b antibody in MFS patients in the 1st paragraph of introduction.

We added the data of oligoclonal bands and myelin basic protein in the diagnostic assessment section.

Since abnormal enhancement was occasionally observed in patients with diabetic oculomotor palsy, we deleted the corresponding sentence in the first paragraph of the discussion. In addition, we described the possible mechanism by which mRNA-based vaccine produce anti-GQ1b antibody and subsequent neurological deficits in the second paragraph of the discussion.

We added the patient's photographs of the last follow-up when he completely recovered on day 77 in [Figure 1 C](#).

Any further responses from the reviewers can be found at the end of the article

Introduction

Oculomotor nerve palsy (ONP) is a neurological condition that manifests as diplopia, ptosis, and pupillary mydriasis. The various etiologies of ONP include cerebrovascular disease, cerebral aneurysm, diabetes, tumor, infection, collagen disease, hyperthyroidism, and Tolosa-Hunt syndrome¹. In some cases, ONP can be caused by an aberrant immune response that develops directly against ganglioside GQ1b, a sialic acid-containing glycosphingolipid enriched in the paranodal region in the III (oculomotor), IV (trochlear), and VI (abducens) cranial nerves². The para-infectious, immune-mediated ONP, along with ataxia and loss of tendon jerks, was originally described by Charles Miller Fisher as a variant of Guillain-Barré Syndrome (GBS)³. Compared to control subjects without neurological complications, the sensitivity and specificity of anti-GQ1b antibody in the patients with MFS are very close to 100%^{2,4}. Since there are incomplete or atypical forms of Miller Fisher syndrome (MFS), an umbrella term, “anti-GQ1b antibody syndrome” has emerged to encompass these clinical conditions⁵.

In addition to an antecedent infectious illness, vaccine-mediated immunization can trigger GBS and MFS^{6–9}, for example, MFS following influenza^{7–9}, pneumovax⁹, and DPT (diphtheria, pertussis, tetanus toxoid) vaccination⁶ has been reported. GBS has been listed as a very rare neurological complication of the COVID-19 vaccine^{10–16}. However, to the best of our knowledge, there have been no case reports of isolated, unilateral ONP with anti-GQ1b antibody following vaccination. Here, we report an adult case of acute-onset right ONP with anti-GQ1b antibody following COVID-19 vaccination with a literature review.

Case description

A 65-year-old Asian male office worker began to notice persistent double vision without preceding upper respiratory or gastrointestinal infection. The diplopia worsened in the left gaze, and three days later, he developed right ptosis. He was vaccinated with a second dose of Pfizer-BioNTech COVID-19 (BNT162b2) mRNA vaccine 17 days before his presentation. His

medical history included a seven-year history of diabetes, glaucoma, and benign paroxysmal positional vertigo. He did not have diabetic retinopathy or neuropathy in his right eye. His medication included one tablet per day of Canalia® (teneligliptin and canagliflozin), a diabetic combination drug which the patient had been taking for one year and one drop per day of prostaglandin analogue eye drops for glaucoma (time taken for unknown).

The general medical condition of the patient on admission (day 22) was unremarkable. Neurological examination revealed mild blepharoptosis, limitation of adduction, and vertical gaze on the right side ([Figure 1A](#)) with convergence insufficiency. Pupils were slightly asymmetric (right: 3.5 mm, left: 3.0 mm) and the right pupil was slightly slowly reactive to light. The other cranial nerves were preserved normally. These findings were consistent with the diagnosis of right ONP. Gait was normal, with no evidence of muscle weakness, ataxia, or sensory disturbances. Deep-tendon reflexes are normally elicitable.

Diagnostic assessment, therapeutic intervention, follow-up, and outcomes

Routine hematological and biochemical analyses, including thyroid function, were normal except for the elevation in glucose concentration 162 mg/dL (normal range: 78–109 mg/dL) and HbA1c level 7.8% (normal range: 4.6–6.2%). Serological tests identified the presence of anti-GQ1b IgG antibody (1.82, normal cut-off index <1), a pathognomonic marker for MFS. Other antibodies against glycoconjugates, including ganglioside GM1, antinuclear antibodies, perinuclear antineutrophil

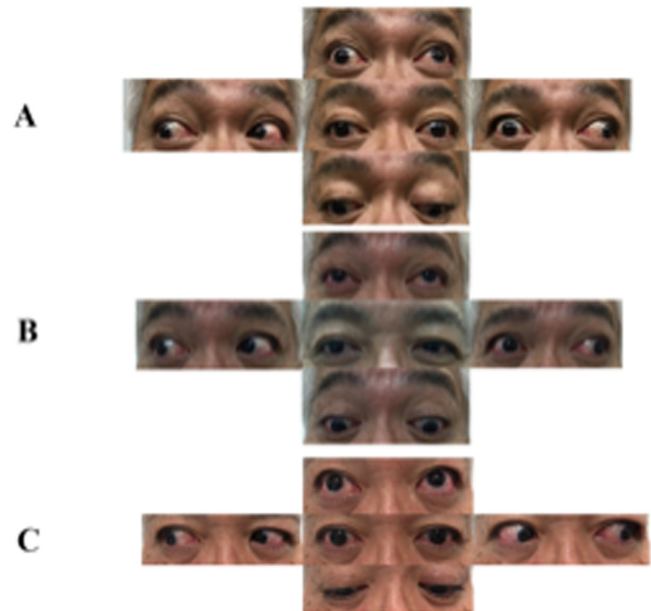


Figure 1. Eye movement of the patient demonstrating right oculomotor nerve palsy. (A) Mild blepharoptosis, limitation of adduction and vertical gaze on the right side on day 30. (B) The limitation of adduction and vertical gaze improved and ptosis completely resolved after IVIG treatment (day 52). (C) He completely recovered on day 71.

cytoplasmic antibody (ANCA), cytoplasmic ANCA, and acetylcholine receptor antibodies were negative. Cerebrospinal fluid showed mild albuminocytologic dissociation with protein levels of 52 mg/dL (normal range: 10–40 mg/dL) and 2 mononuclear cells/mm³ (normal range: 0–5 cells/mm³). Oligoclonal bands were negative and myelin basic protein was less than 31.3 pg/mL (normal range: < 102 pg/mL). High-resolution, constructive interference in steady-state magnetic resonance imaging (CISS-MRI) showed swelling with gadolinium enhancement in the right cavernous segment of the oculomotor nerve (Figure 2), but no signs of aneurysm, tumor, and inflammation in the cavernous sinus and orbital apex were noted. A nerve conduction study in the limbs was normal.

Based on these clinical and laboratory findings, we diagnosed the patient with isolated, unilateral ONP associated with anti-GQ1b antibody and administered intravenous immunoglobulin (IVIG, 400 mg/kg) for consecutive 5 days. On the fourth day of IVIG administration (day 36), the limitation of the vertical gaze and ptosis mildly improved. There were no adverse events during or after the IVIG treatment. The patient was discharged on day 40 and was followed up at an outpatient clinic on day 52. The limitation of the adduction and vertical gaze markedly improved and ptosis completely resolved on day 52 (Figure 1B). The patient also noticed an improvement in his diplopia. He completely recovered on day 71 (Figure 1C). The patient was afraid of receiving further vaccinations, including the COVID-19 vaccine. We explained to him that the incidence of GBS and MFS caused by vaccinations are extremely rare and the causal link between neurological complication and COVID-19 vaccinations is still unclear. It is undoubtedly true that benefits of vaccination outweigh the risks and the truth of the matter is that rare side effects shouldn't rule out vaccines. If he is going to be vaccinated in the future, we will carefully watch his condition and seek medical attention as soon as possible if he experiences any complications.

Discussion

We report the first case of isolated unilateral ONP with anti-GQ1b antibody following COVID-19 vaccination. Clinically,

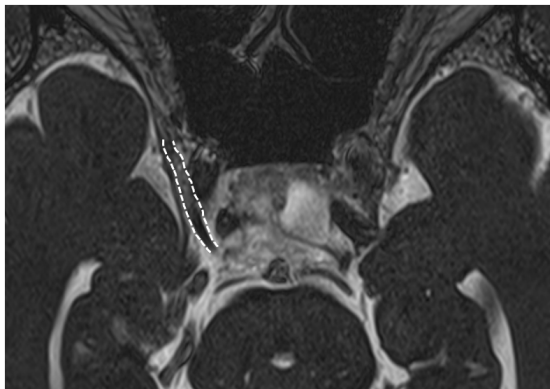


Figure 2. Contrast-enhanced CISS-MRI demonstrates the swelling and enhancement in the right oculomotor nerve (indicated by white dotted lines).

there were many similarities between our case and the previous four cases of unilateral ONP with anti-GQ1b antibody (Table 1)^{17–19}. First, all cases, including ours, had ptosis without ataxia, and three cases showed normal deep tendon reflexes. Second, three patients demonstrated albuminocytologic dissociation in the CSF. Third, all of the cases showed a normal pattern in the nerve conduction studies. Finally, four patients were successfully treated with IVIG and/or steroids, with different recovery periods ranging from 22 days to 6 months^{17–19}. From an etiopathological point of view, two cases of isolated ONP with anti-GQ1b antibody were preceded by acute upper respiratory tract infection or gastroenteritis within two weeks of onset^{18,19}. On the other hand, there have been no case reports of vaccine-induced, isolated ONP with anti-GQ1b antibody. Similar to GBS, the majority of MFS and other anti-GQ1b antibody-associated disorders showed a good response to immunotherapy, such as IVIG and plasmapheresis. However, if ONP is the sole manifestation of anti-GQ1b antibody syndrome, it can be difficult to diagnose, leading to a substantial therapeutic delay.

A growing concern among recent coronavirus vaccines is vaccine-related side effects. The most commonly observed adverse events with COVID-19 vaccines are fatigue, headache, muscle and joint pain, fever, pain at the site of injection, and to a much lesser degree, severe allergic reactions including anaphylaxis. The occurrence of these side effects can be predicted based on what is already known about the clinical trials of other vaccines. While not all reported side effects are directly related to vaccine administration, life-threatening side effects such as thromboembolism and neurological complications, including GBS, have also been reported following COVID-19 vaccines. In the United States, as of July 13, 2021 there were 100 preliminary reports of GBS after receiving the Janssen COVID-19 vaccine and 1 death after 12.5 million vaccine doses administered. GBS usually develops 3–22 days after the administration of COVID-19 vaccines^{10–16}. Although MFS following COVID-19 vaccination has not been reported so far, MFS can be observed from 5 to 21 days after immunization with influenza^{7–9}, pneumovax⁹, and DPT vaccines⁶. Similarly, our case also presented with unilateral ONP with elevated anti-GQ1b antibody 17 days after Pfizer-BioNTech COVID-19 (BNT162b2) vaccination without any preceding infection. Based on the temporal sequence of disease progression, laboratory findings, and a favorable response to immunotherapy, the possibility that preceding COVID-19 vaccination may provoke unfavorable immune responses, leading to ONP in our patient, cannot be ruled out. BNT162b2 vaccine of messenger RNA enter the body and export spike proteins on the cell, which provoke the production of antibodies and T cell reactions²⁰. These immunological alterations may produce neutralizing antibodies as well as anti-GQ1b antibody, thereby leading to unfavorable neurological complications.

It should be noted that ONP is the most common cranial neuropathy in patients with diabetes²¹. Diabetes not only causes ischemic neuropathy, but also induces chronic low-level

Table 1. Summary of previous reports and present case.

Author and year	Lee 2008	Lee 2008	Ichikawa 2002	Ueno 2017	Present case
Age (year)	27	30	47	68	65
Sex	Female	Male	Male	Male	Male
Preceding vaccination	(-)	(-)	(-)	(-)	COVID-19 (Pfizer)
Preceding infection	Gastroenteritis	URI	URI	Gastroenteritis	(-)
Time between preceding event and onset	NA	NA	14 days	8 days	17 days
Affected eye side	Right	Right	Left	Right	Right
Ptosis	(-)	(+)	(+)	(+)	(+)
Gage limitation	Vertical	Adduction and vertical	Adduction and vertical	Adduction and vertical	Adduction and vertical
Ataxia	(-)	(-)	(-)	(-)	(-)
Deep tendon reflex	Normal	Decreased	Normal	Decreased	Normal
CSF	Normal	Albuminocytologic dissociation	Albuminocytologic dissociation	Normal	Albuminocytologic dissociation
NCS	Normal	Normal	Normal	Normal	Normal
Contrast-enhanced MRI	NA	NA	NA	NA	Enhancement in oculomotor nerve
Treatment	IVIg or Steroid	IVIg or Steroid	IVIg and Steroid	No	IVIg
Recovery period	Follow up loss	6 months	28 days	44 days	36 days (mild improvement)

URI, upper respiratory infection; CSF, cerebrospinal fluid; NCS, Nerve conduction study; MRI, magnetic resonance imaging; NA, Not available; IVIG, intravenous immunoglobulin.

inflammation in peripheral nerves through the elevation of various inflammatory markers such as C-reactive protein, tumor necrosis factor, and interleukin-6²¹. Thus, one can imagine that the pre-existing diabetes in our case might impair oculomotor nerve function, thereby aggravating demyelinating oculomotor damage by the anti-GQ1b antibody. Indeed, diabetes has been reported as a risk factor for the exacerbation and poor outcomes of GBS^{22–24}.

Conclusion

Unilateral, isolated ONP with anti-GQ1b antibody was observed following COVID-19 vaccination. Insufficient recognition of this treatable condition often leads to misdiagnosis, which delays the receipt of adequate immunomodulatory therapy. Physicians should consider this rare clinical entity, even when the classical triad of MFS is absent. While the benefits of COVID-19 vaccination substantially outweigh the rare, possible

adverse events, healthcare professionals should carefully monitor the hazardous effects of all COVID-19 vaccines and continue to work closely to manage potential risks and to harness science and big data to drive feedback and recommendations.

Consent

Written informed consent was obtained from the patient for the publication of this case report and any associated images.

Data availability

All data underlying the results are available as part of the article and no additional source data are required.

Acknowledgments

We thank all the neurology medical wards and department staff of Tohoku University Hospital.

References

1. Raza HK, Chen H, Chansysouphanthong T, *et al.*: **The aetiologies of the unilateral oculomotor nerve palsy: a review of the literature.** *Somatosens Mot Res.* 2018; **35**(3–4): 229–239.
[PubMed Abstract](#) | [Publisher Full Text](#)
2. Chiba A, Kusunoki S, Shimizu T, *et al.*: **Serum IgG antibody to ganglioside GQ1b is a possible marker of Miller Fisher syndrome.** *Ann Neurol.* 1992; **31**(6): 677–679.
[PubMed Abstract](#) | [Publisher Full Text](#)
3. Fisher M: **An unusual variant of acute idiopathic polyneuritis (syndrome of ophthalmoplegia, ataxia and areflexia).** *N Engl J Med.* 1956; **255**(2): 57–65.
[PubMed Abstract](#) | [Publisher Full Text](#)
4. Willison HJ, Veitch J, Paterson G, *et al.*: **Miller Fisher syndrome is associated with serum antibodies to GQ1b ganglioside.** *J Neurol Neurosurg Psychiatry.* 1993; **56**(2): 204–206.
[PubMed Abstract](#) | [Publisher Full Text](#) | [Free Full Text](#)
5. Panda S, Tripathi M, Odaka M, *et al.*: **Anti-GQ1b IgG antibody syndrome: clinical and immunological range.** *J Neurol Neurosurg Psychiatry.* 2002; **72**(3): 418–419.
[PubMed Abstract](#) | [Publisher Full Text](#) | [Free Full Text](#)
6. Krämer HH, Niemöller U, Döring K, *et al.*: **Postvaccination Miller Fisher syndrome after combined pertussis, diphtheria and tetanus toxoid vaccine.** *J Infect.* 2013; **66**(5): 460–461.
[PubMed Abstract](#) | [Publisher Full Text](#)
7. Shoamanesh A, Chapman K, Traboulsée A: **Postvaccination Miller Fisher syndrome.** *Arch Neurol.* 2011; **68**(10): 1327–9.
[PubMed Abstract](#) | [Publisher Full Text](#)
8. Blanco-Marchite CI, Buznego-Suárez L, Fagúndez-Vargas MA, *et al.*: **[Miller Fisher syndrome, internal and external ophthalmoplegia after flu vaccination].** *Arch Soc Esp Ophthalmol.* 2008; **83**(7): 433–435.
[PubMed Abstract](#) | [Publisher Full Text](#)
9. Thaler A: **Miller Fisher syndrome in a 66-year-old female after flu and pneumovax vaccinations.** *J Am Med Dir Assoc.* 2008; **9**(4): 283–4.
[PubMed Abstract](#) | [Publisher Full Text](#)
10. Trimboli M, Zoleo P, Gennarina A, *et al.*: **Guillain-Barré syndrome following BNT162b2 COVID-19 vaccine.** *Neurol Sci.* 2021; **42**(11): 4401–4402.
[PubMed Abstract](#) | [Publisher Full Text](#) | [Free Full Text](#)
11. Waheed S, Bayas A, Hindi F, *et al.*: **Neurological Complications of COVID-19: Guillain-Barre Syndrome Following Pfizer COVID-19 Vaccine.** *Cureus.* 2021; **13**(2): 2–5.
[PubMed Abstract](#) | [Publisher Full Text](#) | [Free Full Text](#)
12. Razok A, Shams A, Almeer A, *et al.*: **Post-COVID-19 vaccine Guillain-Barré syndrome; first reported case from Qatar.** *Ann Med Surg (Lond).* 2021; **67**: 102540.
[PubMed Abstract](#) | [Publisher Full Text](#) | [Free Full Text](#)
13. Min YG, Ju W, Ha YE, *et al.*: **Sensory Guillain-Barre syndrome following the ChAdOx1 nCov-19 vaccine: Report of two cases and review of literature.** *J Neuroimmunol.* 2021; **359**: 577691.
[PubMed Abstract](#) | [Publisher Full Text](#) | [Free Full Text](#)
14. Introna A, Caputo F, Santoro C, *et al.*: **Guillain-Barré syndrome after AstraZeneca COVID-19-vaccination: A causal or casual association?** *Clin Neurol Neurosurg.* 2021; **208**: 106887.
[PubMed Abstract](#) | [Publisher Full Text](#) | [Free Full Text](#)
15. McKean N, Chircop C: **Guillain-Barré syndrome after COVID-19 vaccination.** *BMJ Case Rep.* 2021; **14**(7): e244125.
[PubMed Abstract](#) | [Publisher Full Text](#) | [Free Full Text](#)
16. Chan M, Han SC, Kelly S, *et al.*: **A case series of Guillain-Barré Syndrome following Covid-19 infection in New York.** *Neurol Clin Pract.* 2021; **11**(4): e576–e578.
[PubMed Abstract](#) | [Publisher Full Text](#) | [Free Full Text](#)
17. Lee SH, Lim GH, Kim JS, *et al.*: **Acute ophthalmoplegia (without ataxia) associated with anti-GQ1b antibody.** *Neurology.* 2008; **71**(6): 426–429.
[PubMed Abstract](#) | [Publisher Full Text](#)
18. Ichikawa H, Kamiya Y, Susuki K, *et al.*: **Unilateral oculomotor nerve palsy associated with anti-GQ1b IgG antibody.** *Neurology.* 2002; **59**(6): 957–958.
[PubMed Abstract](#) | [Publisher Full Text](#)
19. Ueno T, Kon T, Kurihara AI, *et al.*: **Unilateral oculomotor nerve palsy following campylobacter infection: A mild form of miller fisher syndrome without ataxia.** *Intern Med.* 2017; **56**(21): 2929–2932.
[PubMed Abstract](#) | [Publisher Full Text](#) | [Free Full Text](#)
20. Sahin U, Muik A, Derhovanessian E, *et al.*: **COVID-19 vaccine BNT162b1 elicits human antibody and T_H1 T cell responses.** *Nature.* 2020; **586**(7830): 594–599.
[PubMed Abstract](#) | [Publisher Full Text](#)
21. Hartge MM, Unger T, Kintscher U: **The endothelium and vascular inflammation in diabetes.** *Diab Vasc Dis Res.* 2007; **4**(2): 84–88.
[PubMed Abstract](#) | [Publisher Full Text](#)
22. Peric S, Bozovic I, Bjelica B, *et al.*: **Diabetes mellitus may affect short-term outcome of Guillain-Barré syndrome.** *J Peripher Nerv Syst.* 2017; **22**(2): 127–130.
[PubMed Abstract](#) | [Publisher Full Text](#)
23. Zhang Y, Zhao Y, Wang Y: **Prognostic factors of Guillain-Barré syndrome: a 111-case retrospective review.** *Chin Neurosurg J.* 2018; **4**: 14.
[PubMed Abstract](#) | [Publisher Full Text](#) | [Free Full Text](#)
24. Bae JS, Kim YJ, Kim JK: **Diabetes mellitus exacerbates the clinical and electrophysiological features of Guillain-Barré syndrome.** *Eur J Neurol.* 2016; **23**(3): 439–446.
[PubMed Abstract](#) | [Publisher Full Text](#)

Open Peer Review

Current Peer Review Status:  

Version 2

Reviewer Report 19 April 2022

<https://doi.org/10.5256/f1000research.123036.r129879>

© 2022 Suzuki C. This is an open access peer review report distributed under the terms of the [Creative Commons Attribution License](#), which permits unrestricted use, distribution, and reproduction in any medium, provided the original work is properly cited.



Chieko Suzuki

Department of Neurology, Graduate School of Medicine, Hirosaki University, Hirosaki, Japan

The manuscript has been revised well. I have no further comments.

Competing Interests: No competing interests were disclosed.

Reviewer Expertise: Neuropathy

I confirm that I have read this submission and believe that I have an appropriate level of expertise to confirm that it is of an acceptable scientific standard.

Reviewer Report 07 April 2022

<https://doi.org/10.5256/f1000research.123036.r129880>

© 2022 García-Grimshaw M. This is an open access peer review report distributed under the terms of the [Creative Commons Attribution License](#), which permits unrestricted use, distribution, and reproduction in any medium, provided the original work is properly cited.



Miguel García-Grimshaw 

¹ Department of Neurology and Psychiatry, Instituto Nacional de Ciencias Médicas y Nutrición Salvador Zubirán, Mexico City, Mexico

² Department of Neurology, Hospital General Tijuana, Tijuana, Mexico

I have no further comments. The author complied with the reviews of my first revision.

Competing Interests: No competing interests were disclosed.

Reviewer Expertise: Currently working on acute and long-term neurologic manifestations of

COVID-19 and neurologic adverse events following immunization against SARS-CoV-2.

I confirm that I have read this submission and believe that I have an appropriate level of expertise to confirm that it is of an acceptable scientific standard.

Version 1

Reviewer Report 22 March 2022

<https://doi.org/10.5256/f1000research.78037.r126605>

© 2022 García-Grimshaw M. This is an open access peer review report distributed under the terms of the [Creative Commons Attribution License](#), which permits unrestricted use, distribution, and reproduction in any medium, provided the original work is properly cited.



Miguel García-Grimshaw 

¹ Department of Neurology and Psychiatry, Instituto Nacional de Ciencias Médicas y Nutrición Salvador Zubirán, Mexico City, Mexico

² Department of Neurology, Hospital General Tijuana, Tijuana, Mexico

In this report, the authors describe the case of a male who developed an isolated unilateral oculomotor palsy following immunization with BNT162b2 and positivity anti-GQ1b antibody.

Real-world evidence (outside clinical trials) is essential to detect potential adverse events of these newly developed vaccines. However, this case does not fulfill the clinical diagnostic criteria for the Miller Fisher syndrome (MFS) variant of Guillain-Barré syndrome (GBS).

It would be interesting if the author could discuss the positivity of anti-GQ1b antibody in the general population patients (without clinical suspicion of GBS), including sensitivity and specificity of this antibody for diagnosing MFS.

In the discussion section, the author describes the possibility of diabetic cranial neuropathy. It would be interesting to know if the patient was tested for oligoclonal bands in the cerebrospinal fluid and serum anti-AQP-4 antibodies as part of unilateral optic neuritis differential diagnosis as his contrast-enhanced MRI demonstrates swelling and enhancement in the right oculomotor nerve.

Lastly, it would be interesting if the author could discuss or speculate on some of the pathophysiological mechanisms on how mRNA-based vaccines may be related to GBS or MFS.

Is the background of the case's history and progression described in sufficient detail?

Yes

Are enough details provided of any physical examination and diagnostic tests, treatment given and outcomes?

Partly

Is sufficient discussion included of the importance of the findings and their relevance to future understanding of disease processes, diagnosis or treatment?

Partly

Is the case presented with sufficient detail to be useful for other practitioners?

Partly

Competing Interests: No competing interests were disclosed.

Reviewer Expertise: Currently working on acute and long-term neurologic manifestations of COVID-19 and neurologic adverse events following immunization against SARS-CoV-2.

I confirm that I have read this submission and believe that I have an appropriate level of expertise to confirm that it is of an acceptable scientific standard, however I have significant reservations, as outlined above.

Author Response 30 Mar 2022

Takafumi Hasegawa, Tohoku University Graduate School of Medicine, Sendai, Japan

Comment #1: It would be interesting if the author could discuss the positivity of anti-GQ1b antibody in the general population patients (without clinical suspicion of GBS), including sensitivity and specificity of this antibody for diagnosing MFS.

Reply: Thank you very much for your valuable comment. From two previous studies, all ten patients with MFS were positive for anti-GQ1b antibody, whereas all 81 control people without GBS were negative. Thus, the sensitivity and specificity of anti-GQ1b antibody in the patients with MFS should be very close to 100% (Chiba A et al. Ann Neurol (1992) 31:677–679. Willison HJ et al. J Neurol Neurosurg Psychiatry (1993) 56:204–206). We added this point in the first paragraph of introduction as follows: “Compared to control subjects without neurological complications, the sensitivity and specificity of anti-GQ1b antibody in the patients with MFS are very close to 100% (2,4). Since there are incomplete or atypical forms of Miller Fisher syndrome (MFS), an umbrella term, “anti-GQ1b antibody syndrome” has emerged to encompass these clinical conditions (5).”

Comment #2: In the discussion section, the author describes the possibility of diabetic cranial neuropathy. It would be interesting to know if the patient was tested for oligoclonal bands in the cerebrospinal fluid and serum anti-AQP-4 antibodies as part of unilateral optic neuritis differential diagnosis as his contrast-enhanced MRI demonstrates swelling and enhancement in the right oculomotor nerve.

Reply: We appreciate this reviewer’s constructive comment. Oligoclonal bands were negative in this case, but we did not measure anti-AQP-4 antibodies. It is true that anti-AQP-4 antibodies can cause oculomotor nerve palsy in a very rare case (Yasuda K et al. J Clin Neurosci. 2019 Aug;66:271-272.); however, our case did not have any other symptoms and

signs of NMOSD. Hence, we think it unlikely that anti-AQP-4 antibodies contribute to the manifestation of oculomotor nerve palsy in our case. Taking the above into consideration, we added the data of oligoclonal bands and myelin basic protein in the diagnostic assessment section as follows: "Oligoclonal bands were negative and myelin basic protein was less than 31.3 pg/mL (normal range: < 102 pg/mL).".

Comment #3: Lastly, it would be interesting if the author could discuss or speculate on some of the pathophysiological mechanisms on how mRNA-based vaccines may be related to GBS or MFS.

Reply: Thank you very much for your comment. We add the possible mechanism by which mRNA-based vaccine produce anti-GQ1b antibody and subsequent neurological deficits in the second paragraph of the discussion as follows: "BNT162b2 vaccine of messenger RNA enter the body and export spike proteins on the cell, which provoke the production of antibodies and T cell reactions (19). These immunological alterations may produce neutralizing antibodies as well as anti-GQ1b antibody, thereby leading to unfavorable neurological complications."

Competing Interests: None declared

Reviewer Report 30 November 2021

<https://doi.org/10.5256/f1000research.78037.r99811>

© 2021 Suzuki C. This is an open access peer review report distributed under the terms of the [Creative Commons Attribution License](#), which permits unrestricted use, distribution, and reproduction in any medium, provided the original work is properly cited.



Chieko Suzuki

Department of Neurology, Graduate School of Medicine, Hirosaki University, Hirosaki, Japan

This report shows unilateral oculomotor nerve palsy associated with anti- GQ1b antibody following COVID-19 vaccination. It is important because there is a growing concern about the adverse effects of COVID-19 vaccines worldwide.

Anti GQ1b antibody-associated isolated oculomotor nerve palsy is rare. On the other hand, diabetic oculomotor nerve palsy is a common disease. It is necessary to examine whether diabetes has any effect on this condition. In this case, treatment was started more than one month after the onset of the disease.

If the condition is related to GQ1b, recovery phase may begin. Were there any signs of recovery before starting treatment?

1. Elevated CSF protein is often observed in diabetes mellitus. Do you have follow-up data of CSF? If this condition is associated with GQ1b, there may be changes in CSF protein.

2. Contrast-enhanced findings of the oculomotor nerve on MRI have been reported in diabetic oculomotor palsy and idiopathic oculomotor palsy (Zhao *et al.* 2021¹; Yang *et al.* 2020²). This finding is not specific to MFS.

References

1. Zhao J, Li Y, Chang Q, Wang J, et al.: Diabetic Oculomotor Nerve Palsy Displaying Enhancement of the Oculomotor Nerve in the Orbit and Cavernous Sinus on MRI. *Eur Neurol.* 2021; **84** (4): 246-253
[PubMed Abstract](#) | [Publisher Full Text](#)
2. Yang Y, Lai C, Yan F, Wang J: Clinical Significance of MRI Contrast Enhancement of the Oculomotor Nerve in Ischemic Isolated Oculomotor Nerve Palsy. *J Clin Neurol.* 2020; **16** (4): 653-658
[PubMed Abstract](#) | [Publisher Full Text](#)

Is the background of the case's history and progression described in sufficient detail?

Yes

Are enough details provided of any physical examination and diagnostic tests, treatment given and outcomes?

Yes

Is sufficient discussion included of the importance of the findings and their relevance to future understanding of disease processes, diagnosis or treatment?

Yes

Is the case presented with sufficient detail to be useful for other practitioners?

Yes

Competing Interests: No competing interests were disclosed.

Reviewer Expertise: Neuropathy

I confirm that I have read this submission and believe that I have an appropriate level of expertise to confirm that it is of an acceptable scientific standard.

Author Response 30 Mar 2022

Takafumi Hasegawa, Tohoku University Graduate School of Medicine, Sendai, Japan

Comment #1: If the condition is related to GQ1b, recovery phase may begin. Were there any signs of recovery before starting treatment?

Reply: Thank you very much for your comment. There were no obvious signs of recovery before IVIG treatment. He had gradually improved after the therapy. To further clarify the process of recovery, we added the last follow-up when he completely recovered on day 77 in the second paragraph of the diagnostic assessment section as follows: "He completely recovered on day 71 (**Figure 1 C**)."

Comment #2: Elevated CSF protein is often observed in diabetes mellitus. Do you have follow-up data of CSF? If this condition is associated with GQ1b, there may be changes in CSF protein.

Reply: Thank you very much for your comment. We are sorry but we did not perform follow-up CSF analysis. As you mentioned, albuminocytologic dissociation in CSF might have improved after the therapy.

Comment #3: Contrast-enhanced findings of the oculomotor nerve on MRI have been reported in diabetic oculomotor palsy and idiopathic oculomotor palsy (Zhao et al. 20211; Yang et al. 20202). This finding is not specific to MFS.

Reply: We humbly accept this reviewer's comment. We deleted the following sentence in the 1st paragraph of the discussion: "In agreement with our case, cranial MRI demonstrated abnormal swelling, T2 hyperintensity, and gadolinium enhancement of the affected oculomotor nerve in classic forms of MFS, providing a useful tool for early diagnosis."

Competing Interests: None declared

The benefits of publishing with F1000Research:

- Your article is published within days, with no editorial bias
- You can publish traditional articles, null/negative results, case reports, data notes and more
- The peer review process is transparent and collaborative
- Your article is indexed in PubMed after passing peer review
- Dedicated customer support at every stage

For pre-submission enquiries, contact research@f1000.com

F1000Research