

Pediatric spinal high-grade glioma in the pediatric precision oncology registry INFORM: Identification of potential therapeutic targets

Elke Pfaff^o, Kathrin Schramm, Mirjam Blattner-Johnson, Barbara C. Jones, Sebastian Stark, Gnana Prakash Balasubramanian, Christopher Previti, Robert J. Autry, Petra Fiesel, Felix Sahn^o, David Reuss, Andreas von Deimling^o, Cornelis M. van Tilburg, Kristian W. Pajtler^o, Till Milde^o, Uta Dirksen, Christof M. Kramm, André O. von Bueren, Monica C. Munthe-Kaas, Ingrid Øra^o, Stefan M. Pfister^o, Olaf Witt, and David T.W. Jones^o

All author affiliations are listed at the end of the article

Corresponding Author: David T.W. Jones, PhD, Division of Pediatric Glioma Research, Hopp Children's Cancer Center, Heidelberg (KITZ) and German Cancer Research Center (DKFZ), Im Neuenheimer Feld 280, 69120 Heidelberg, Germany (david.jones@kitz-heidelberg.de).

Abstract

Background. High-grade glioma (HGG) of the spinal cord constitutes rare tumors in the pediatric population. Knowledge of the molecular profile of this pediatric HGG (pedHGG) subgroup is limited and the clinical outcome is poor. Therefore, the aim of this study is to provide more profound investigations of molecular characteristics and clinical features of these tumors.

Methods. Between January 2015 and October 2023, 17 spinal tumors with HGG histology were analyzed by the Individualized Therapy For Relapsed Malignancies in Childhood (INFORM) precision oncology registry. Comprehensive molecular profiling (including next-generation sequencing approaches and DNA methylation analysis) was performed. Clinical data provided by the treating centers were evaluated regarding treatment approaches and outcomes.

Results. Subgroup classification based on DNA methylation analysis revealed molecular HGG subgroups in 12/17 cases, while 2/17 were classified as molecular low-grade glioma (LGG) and 3/17 were not unequivocally classifiable. Typical genetic alterations described in pedHGG usually presenting at other localizations were also present in the counterparts located in the spinal cohort. Alterations that might serve as a promising target for personalized therapy approaches were identified in a subset of tumors.

Conclusion. With this cohort of 12 molecularly confirmed spinal pedHGG cases, we provide a compilation of genomic as well as clinical features of this rare subgroup, contributing to a better understanding and eventually to future treatment approaches.

Key Points

- Pediatric spinal high-grade glioma are rare tumors with poor clinical outcome.
- Molecular characterization of these tumors provides an urgently needed basis for the identification of potential therapeutic targets.

Importance of the Study

Pediatric spinal high-grade glioma (HGG) are insufficiently studied and clinical outcomes of the affected patients are poor. Assignment of the tumor to a specific brain tumor entity and molecular subgroup classification based on molecular diagnostics is essential for treatment and prognosis prediction. As compared to counterparts of pediatric high-grade glioma (pedHGG) in other localizations within the central nervous system,

biological and molecular data of spinal pedHGG are scarce. Comprehensive molecular profiling of the tumor provides valuable information on tumor characteristics and on alterations that might serve as targets for tailored therapeutic approaches. The study presented here contributes to a better understanding of spinal pedHGG and thus to improving treatment strategies and potential prognosis for the affected patients.

Primary tumors of the spinal cord are rare neoplasms, especially in childhood, accounting for approximately 5% of all pediatric tumors of the central nervous system (CNS).^{1,2} In pediatric patients, the most frequent histological tumor types are low-grade glioma (LGG, 31.5%), ependymal tumors (18.5–29.6%), high-grade glioma (HGG, 7.5–20.4%), nerve sheath tumors (9.3–17.6%), and embryonal tumors (3.7–7.6%).^{1–3}

As for pediatric HGG (pedHGG) in other localizations of the CNS, prognosis for spinal pedHGG patients is poor, with a median overall survival (OS) of 7–30.1 months^{1,3–5} and a median event-free survival (EFS) of 7–11.5 months.^{1,4}

Most of the patients with spinal HGG undergo surgery to reduce tumor burden and relieve symptoms.^{3,6} Previous reports described partial resection as the most frequent surgical result (in 45.4–51.7% of cases), although gross-total resection (GTR) was achieved in 3.1–28.7% of cases.^{3,6} As for pedHGG in other localizations, treatment ordinarily consists of radio- and chemotherapy.

Several studies describe younger age at diagnosis (below 5–7 years) as a positive prognostic factor in spinal pedHGG.^{4,7} The prognostic value of the extent of surgery and treatment with radiotherapy seems to be controversial with the positive influence of GTR or application of radiotherapy on survival in some series and studies, which was not confirmed by others.^{4,5,7} Overall, data on the value of different local therapy modalities for this subgroup of pedHGG are still limited, and evidence-based treatment recommendations cannot be provided.

With regard to the occurrence of diffuse glioma in different age groups, a distinction between “adult-type” and “pediatric-type” of HGG was first implemented in the fifth edition of the World Health Organization (WHO) Classification of Tumors of the CNS 2021,⁸ taking clinical and molecular differences of these two groups into account. In the last decades, a robust molecular characterization of supratentorial pedHGG, diffuse midline glioma (DMG), and diffuse intrinsic pontine glioma (DIPG) was implemented.^{9–11} However, data on spinal pedHGG are lacking, which would help to further understand the underlying tumor biology in this entity.

Therefore, in this study, we aimed to summarize data of spinal pedHGG cases from the INFORM registry (Individualized Therapy For Relapsed Malignancies in Childhood)^{12–14} to gain knowledge on molecular features and clinical aspects of these tumors. Here, we present clinical data as well as results of the comprehensive molecular profiling of 17 cases with histological HGG located in the spinal cord.

Material and Methods

The INFORM registry is an ongoing, international, multi-center, prospective, noninterventional molecular diagnostic registry for pediatric patients with relapsed, progressive, or high-risk malignancies and is registered in the German Clinical Trials Register (Study ID: DRKS00007623).

The INFORM registry protocol was reviewed and approved by the Ethics Committee of the Heidelberg University Hospital. Informed consent for participation in the INFORM registry including molecular analysis of tumor and constitutional DNA as well as use of molecular and clinical results for scientific purposes was obtained in written form. The study was conducted in accordance with Good Clinical Practice guidelines and the Declaration of Helsinki. All data evaluated in this study were produced and kindly provided by the INFORM program.^{12–14} Processing and molecular profiling of the tumor and constitutional (germline) material using next-generation sequencing methods was performed via the INFORM diagnostic pipeline as previously described.^{12,13,15} This includes whole-exome sequencing, low-coverage whole-genome sequencing, RNA sequencing, and DNA methylation analysis. Protocols for bioinformatic processing have been described previously.^{12,13,15}

To determine the respective molecular brain tumor (sub-) groups by DNA methylation-based classification, the previously described methylation classifier was applied¹⁶ using the latest version v12.8 of the Heidelberg methylation classifier (<https://www.moleculareuropathology.org/mnp/>). The threshold score for clear subgroup classification was set at >0.9.

Furthermore, based on low-coverage whole-genome profiling (lcWGS), the genomic signature for alternative lengthening of telomeres (ALT) was evaluated using the previously outlined software tool TelomereHunter.^{17,18}

Clinical data regarding medical history, current disease episodes as well as treatment and follow-up were entered in an electronic Case Report Form (eCRF) by the treating pediatric oncology centers.

Results

The evaluation of all pedHGG cases analyzed through the INFORM pipeline between January 2015 and October 2015

(data cutoff) revealed 17 cases as primarily located in the spinal cord (Figure 1A). Spinal metastases from primary tumors located elsewhere in the CNS were not included in this study presented here. The patients were enrolled in 10 German pediatric oncology centers, as well as one case each from a center in Norway and Sweden, respectively.

Clinical Features of Patients and Tumors

All 17 cases were registered in INFORM as HGG/glioblastoma, diffuse midline glioma (DMG), or other high-grade glial/astrocytic tumor. The epidemiological details on the cohort are displayed in Table 1.

Notably, two patients had suffered from another malignancy previous to the current diagnosis (namely Burkitt's lymphoma, case #1, and medulloblastoma, case #2), the pedHGG analyzed here thus being the subsequent (or secondary) tumor. One further patient (case #17) was initially histologically diagnosed with spinal ependymoma as the primary disease, however, at the time of subsequent surgery only 4 months later, the histological diagnosis was changed to HGG. Another patient (case #14) was primarily histologically diagnosed with spinal oligoastrocytoma WHO °II with several episodes of progressive disease. At the time of further tumor progression 10.5 years after primary diagnosis, histological assessment of newly extracted tumor material stated malignant progression to HGG. The latter 2 cases were both included in the INFORM analysis at subsequent relapse/progression episodes.

For one patient (case #16), constitutional mismatch repair deficiency (cMMRD) had been previously diagnosed as an underlying cancer predisposition syndrome (CPS).

Molecular Characteristics

Based on genome-wide DNA methylation profiling,¹⁶ 47.1% of tumors (8/17) were clearly assigned to the subgroup of diffuse midline glioma with Histone 3 K27M mutation (DMG_K27, score > 0.99) and showed the pathognomonic K27M single nucleotide variant (SNV) in the *H3F3A* gene (Figure 1B). Three of the 17 tumors had the highest classifier score for one of the pedHGG, RTK subgroups (pedHGG_RTK) and the tumor of one adolescent patient scored highest for the adult methylation class glioblastoma, IDH wildtype, subclass RTK I (GBM_RTK1). Even though the threshold score of >0.9 for clear subgroup assignment was not reached in 2 of these latter 4 cases, allocation to the respective subgroup was supported based on DNA methylation profile due to clustering with reference samples¹⁶ based on *t*-distributed stochastic neighbor embedding. Methylation analysis of the tumor pointed toward the classification as LGG in 2 patients who had been initially diagnosed as infants, with the highest classifier score for pilocytic astrocytoma (PA_INF) (score > 0.9 in 1 case and <0.9 but with unequivocal result in the other case). One of the characteristic alterations for LGG/pilocytic astrocytoma, a *KIAA1549::BRAF* fusion, was identified in one of these cases, whereas analysis revealed an *FGFR1* tandem duplication in the other case. The remaining three tumors with inconclusive classifier scores harbored

an *EWSR1::PATZ1* fusion, an *FGFR1::TACC1* fusion, and a *KIF5B::RET* fusion, respectively, and could not distinctly be assigned based on the DNA methylation analysis (Figure 1A). Further details on the methylation-based classification scores according to Heidelberg classifier version v12.8 as well as the MGMT promoter methylation status are provided in Supplementary Table 1.

As expected, typical alterations of HGG like *TP53* SNVs, *ATRX* deletion/SNV, and *ACVR1* SNV were detected in 8, 4, and 1 tumors, respectively, of the methylation subgroups DMG_K27, pedHGG_RTK, and GMB_RTK (Figure 1B). Beyond these, the most frequent single affected genes were *FGFR1* with SNVs in a total of 3/12 molecular HGG cases (25.0%) and *PIK3CA* being altered in 4/12 HGG cases (33.3%; 4 missense SNV). Other alterations in the MAPK pathway were identified in 4/12 molecular HGG cases, affecting *KRAS* ($n = 1$) and *NF1* ($n = 3$). Further receptor tyrosine kinases (besides *FGFR1*), namely *PDGFRA* (SNV; $n = 1$, amplification; $n = 1$), *KIT* (amplification; $n = 1$), *NTRK* (fusion; $n = 1$), and *IGF1R* (amplification; $n = 1$) displayed alterations in 4/12 molecular HGG cases. Cell cycle control and PI3K/AKT/mTOR pathway genes were affected in 3/12 and 5/12 molecular HGG cases, respectively (Figure 1B). Variant allele frequency for SNVs and small insertions/deletion (InDels) was 0.40 or higher in two-third of alterations. The occurrence of a specific alteration in a large proportion of tumor cells supports a potential value as a therapeutic target. In each of the 12 molecular HGG cases, at least one alteration was identified that could serve as a direct target or provide rationale for targeted therapy approaches.

For one patient having received previous treatment for medulloblastoma including radiotherapy (most likely craniospinal irradiation) more than 8 years ago, the current diagnosis of spinal HGG might be considered as a secondary malignancy or radiation-induced glioma. The tumor (case #2) showed no *H3F3A* K27M mutation, but further HGG-typical alterations like *CDK4* amplification, *NF1* structural variant, *TP53* mutation, and *ATRX* deletion. However, typical alterations for radiation-induced glioma such as *PDGFRA* amplification and *CDKN2A/B* deletion¹⁹ were not present in this case.

Two cases displayed a hypermutator phenotype with a very high somatic mutation count. The tumor mutational burden (TMB) was 94.65 somatic mutations per Megabase (Mb) (case #1) and 284.19 (case #16), respectively, with the cutoff for hypermutation being set at TMB > 10.²⁰ One of the two patients (case #1) had suffered from Burkitt's lymphoma in the past medical history and clinical information on the other patient (case #16) includes a known constitutional mismatch repair deficiency syndrome (cMMRD). In-depth analysis of constitutional DNA revealed bi-allelic alterations (compound-heterozygous in case #1 or homozygous in case #16) of the mismatch repair gene *PMS2* in both cases explaining the phenotype. Moreover, somatic mutations in genes playing an important role in DNA repair were detected in both tumors (namely *MSH2*, *MSH6*, *POLE*, and *POLD1* in case #1 and *PMS2* and *MSH2* in case #16) which might have further contributed to the high mutational load. The first of these two patients (case #1) succumbed to the disease only three months after diagnosis of the HGG. Since a constitutional alteration had not been known before, no specific treatment was applied.

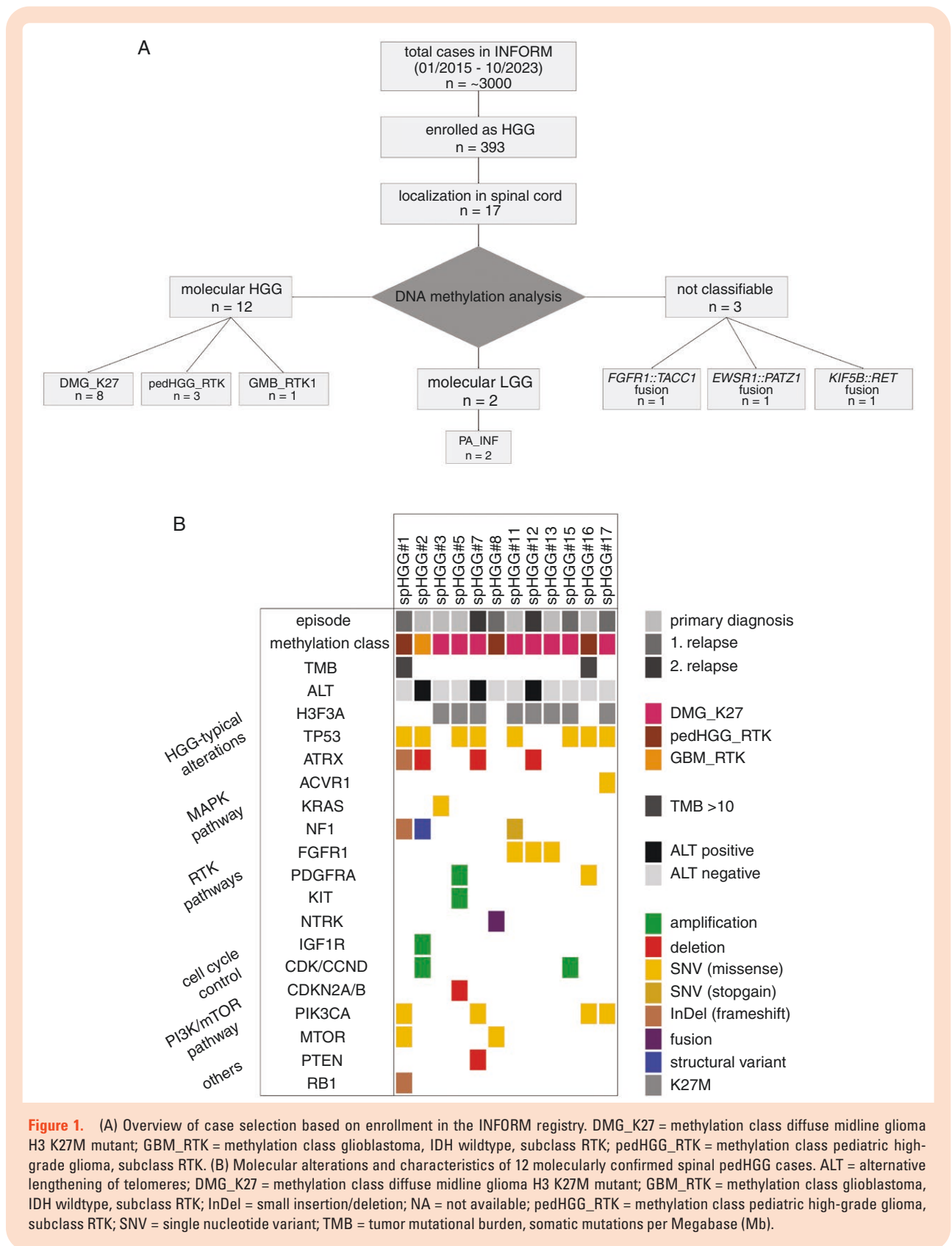


Table 1. Clinical Characteristics of the Study Cohort

Clinical characteristics	Spinal histological HGG (total <i>n</i> = 17)	Spinal molecular HGG (<i>n</i> = 12)
Sex, no. (%)		
Female	9 (52.9)	6 (50.0)
Male	8 (47.1)	6 (50.0)
Age, no. (%)		
≤4 y	4 (23.5)	2 (16.7)
> 4 y	13 (76.5)	10 (83.3)
Age, median years (range)	12 (2–17)	13 (2–17)
Number of relapse, no. (%)		
Primary diagnosis (including secondary malignancy)	6 (35.3)	6 (50.0)
Relapse 1	8 (47.1)	4 (33.3)
Relapse 2	2 (11.8)	2 (16.7)
Relapse 3	1 (5.9)	0
Median latency after previous episode for relapses (range, months)	18.3 (6.7 – 90.7)	13.9 (6.7 – 84.5)
Metastatic status, no (%)		
M0 ^a	11 (64.7)	7 (58.3)
M+ (including meningeosis cerebri) ^b	3 (17.6)	2 (16.7)
Missing data	3 (17.6)	3 (25.0)
Level of resection, no. (%)		
Biopsy (R4)	1 (5.9)	0
Partial resection (R3)	5 (29.4)	4 (33.3)
Rim near total resection (R2)	5 (29.4)	4 (33.3)
Gross-total resection (R1)	3 (17.6)	2 (16.7)
Missing data	3 (17.6)	2 (16.7)

^aM0 = no metastases as radiologically detected.

^bM+ = metastases detected radiologically.

With regard to the diagnosis of cMMRD for the other patient (case #16) a treatment with the immune checkpoint inhibitor nivolumab was initiated and ongoing at the last follow-up, complemented by ipilimumab for 4 doses. For all other cases, sequencing of constitutional DNA did not reveal underlying germline alterations potentially relevant to the current tumor disease.

Furthermore, positive genomic signatures for alternative lengthening of telomeres (ALT) were detected in 3/12 molecular HGG cases, which are also the cases harboring an *ATRX* deletion.

Treatment and Outcome Data

Due to the fact that patients were included in the INFORM registry and therefore also in this study at different episodes during the clinical course of the oncological disease, previously applied treatment regimens as well as subsequent therapeutic strategies for the patients with molecular pedHGG varied widely (Table 2). In line with the current treatment recommendation for pedHGG, the most frequently used therapeutic agent was temozolomide commonly combined with radiotherapy. However, various

chemotherapeutic agents and targeted therapies were given. Details on previous and subsequent treatment are summarized in Table 2. (Remark: in cases with multiple relapses information on treatment details is not available for all previous episodes.) As dictated by the INFORM inclusion criteria, routine surgery of the current episode was conducted for all patients as part of standard of care treatment.

A total of four pedHGG patients in this cohort received targeted therapy after the molecular tumor analysis within the INFORM registry. One patient (case #7) was treated with the mTOR-inhibitor everolimus based on a detected *PTEN* deletion and the PI3K-inhibitor copanlisib due to *PIK3CA* SNV. The tumors of two patients harbored *FGFR1* SNV, serving as a basis for the treatment with the FGFR-inhibitors ponatinib (case #12) and erdafitinib (case #13). The mTOR-inhibitor everolimus was also applied in another patient (case #17) due to a *PIK3CA* SNV detected in the tumor, with mTOR being located downstream within the PI3K/AKT/mTOR signaling pathway. Two of these 4 patients additionally received another targeted therapy without a corresponding targeted identified, namely sirolimus (case #13) and bevacizumab (case #17). Concomitant chemotherapy was administered in two of these 4 patients and radiotherapy in 1 patient.

Table 2. Details on Previous Oncological Therapy and Treatment of Current Episode

Pa-tient	Previous treatment ^a				Comment	Treatment of current episode			
	Chemotherapy	Radio-therapy	Tar-geted therapy	Extent of sur-gery		Chemotherapy	Radio-therapy	Targeted therapy	Further sur-gery
1	TMZ according to HIT-HGG 2007 ^b	Ac-cording to HIT-HGG 2007 ^b	No	R3	Burkitt's lymphoma in medical history, no details on pre-vious treatment available	No	Yes	No	Laminotomy
2	Yes	Yes	NA	R2	Previous treat-ment according to HIT 2000 Interim Register ^d (MET-HIT 2000-AB4-M1) due to diagnosis of medulloblastoma	TMZ	Yes	NA	No
3	No	No	No	R3		TMZ	Yes	No	NA
5	No	No	No	R3		TMZ + VPA	Yes	NA	NA
7	According to HIT-HGG 2013 ^c at primary diagnosis; TROF/ETO at re-lapse	Yes	No	NA		TROF/ETO (stopped be-fore start of TT)	NA	Everolimus, Copanlisib	NA
8	CARBO/ETO	No	No	R3		No	No	No	NA
11	No	No	No	R1		TMZ + VPA	Yes	NA	NA
12	TMZ according to HIT-HGG 2007 ^b	Yes	No	R2		TMZ + VPA	No	Ponatinib	NA
13	No	No	No	R2		TMZ + VPA + Irinotecan	Yes	Erdafitinib, Sirolimus	NA
15	TMZ according to HIT-HGG 2013 ^c	Yes	No	R2		NA	NA	No	NA
16	No	No	No	R1		CCNU	yes	NA	NA
17	TMZ + CCNU at re-lapse/progression	Yes at relapse/progres-sion	No	NA		No	NA	Everolimus, Bevacizumab	Yes

Abbreviations: CARBO, carboplatin; CCNU, lomustine; ETO, etoposide; HIT, German brain tumor cooperation network; NA, not available; TMZ, temozolomide; TROF, trofosfamide; TT, targeted therapy; VPA, valproic acid.

^aIn cases with multiple relapses, not all data are available.

^bHIT-HGG-2007 trial (EudraCT Number: 2007-000128-42).

^cHIT-HGG-2013 trial (ClinicalTrials.gov Identifier: NCT03243461).

^dHIT 2000 Interim Register (ClinicalTrials.gov Identifier: NCT02238899).

Regarding patients with molecularly confirmed HGG, 9 patients succumbed to the disease after a median time of 20.5 months (range 7.8–98.5 months) after diagnosis of spinal HGG, whereas two patients were alive at the last follow-up 30.4 and 11.8 months after diagnosis of spinal HGG. For one patient (case #11), no follow-up data were available. Details on the full clinical course of the 12 molecular spinal pedHGG cases are depicted in [Figure 2](#).

Discussion

Data on pediatric spinal HGG is very limited due to the rarity of the disease, and with the study presented here,

we provide a clinical and molecular data compilation of 12 molecular pedHGG cases from the INFORM registry.

The fact that for five cases enrolled as histological HGG the molecular characterization, especially DNA methylation analysis, could not confirm molecular pedHGG but rather pointed toward diagnosis of LGG or even nonlingual tumor, underlines the importance of molecular diagnostics. For example, case #14 which could not be clearly assigned to a specific subgroup based on the DNA methylation profile, showed an *EWSR1::PATZ1* fusion as the only relevant alteration. *PATZ1* fusions are described in a small series of pediatric brain tumors²¹ and as the typical alteration in a recently outlined molecular subgroup of neuroepithelial tumors.^{22,23} These latter tumors exhibit a wide spectrum of histological diagnosis and might occur in the spinal cord.

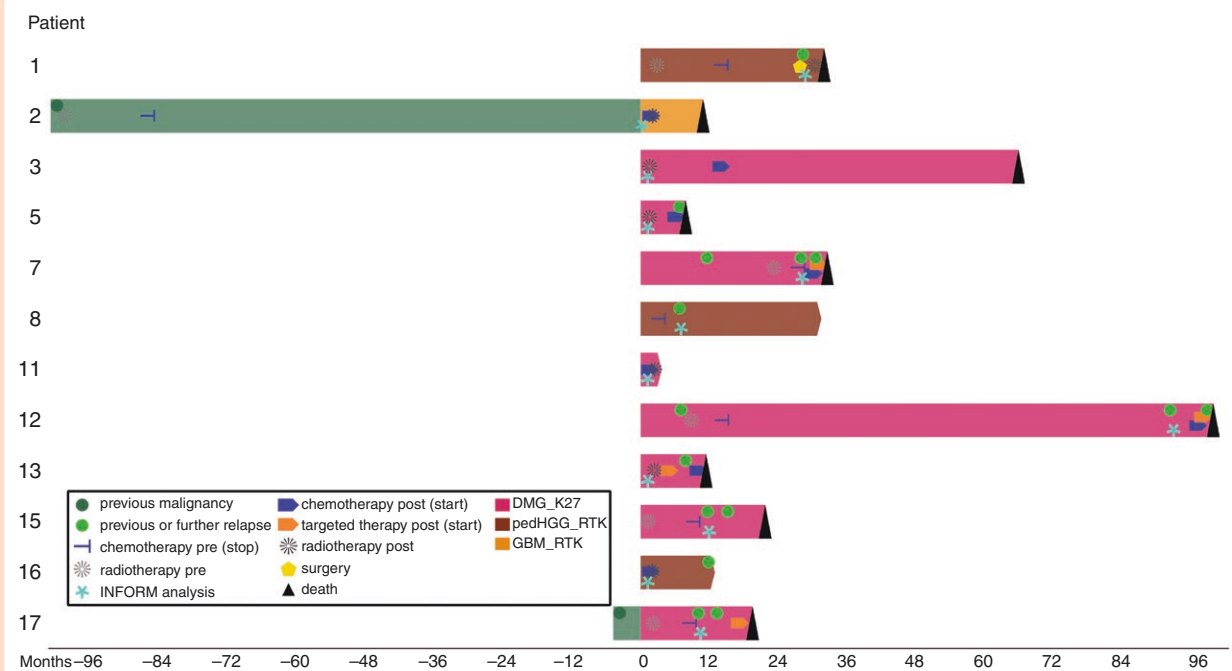


Figure 2: Visualization of the individual clinical courses of 12 molecular pedHGG patients: chemotherapy pre (stop) = stop date of previous chemotherapy before enrollment in INFORM; radiotherapy pre = radiotherapy applied before enrollment in INFORM analysis; chemotherapy post (start) = start of chemotherapy applied after INFORM analysis; targeted therapy post (start) = start of targeted therapy applied after INFORM analysis; radiotherapy post = start of radiotherapy applied after INFORM analysis; DMG_K27 = methylation class diffuse midline glioma H3 K27M mutant; pedHGG_RTK = methylation class pediatric high-grade glioma, subclass RTK; GBM_RTK = methylation class glioblastoma, IDH wildtype, subclass RTK. Timeline in months before/after diagnosis of spinal pedHGG (= time point 0).

Therefore, the mentioned tumor in our cohort possibly belongs to this recently described group of *PATZ1*-fused brain tumors. Besides, *EWSR1::PATZ1* fusion constitutes a typical translocation in a specific group of sarcoma/sarcomatous tumors²⁴⁻²⁶ which are currently classified by the World Health Organization Classification of Soft Tissue and Bone Tumors as “undifferentiated round cell sarcomas with *EWSR1*-non-ETS fusions.”²⁷

Regarding the 12 molecular pedHGG cases, as opposed to other reports focusing mostly on tumors at primary diagnosis,⁹ almost two-thirds of cases in our analysis were enrolled at relapsed/progressive disease. However, the detected spectrum and incidence of molecular alterations did not differ considerably compared to primary pedHGG cohorts irrespective of the tumor localization. The histone H3 (*H3F3A*) K27M mutation which is a diagnostic criteria according to the 2021 WHO classification of Tumors of the CNS⁸ pathognomonic for diffuse midline glioma H3 K27M-altered, was identified in two-thirds of molecularly-defined spinal pedHGG in our cohort. This finding is in line with the frequency of 53% in another report investigating *H3F3A* mutations in spinal HGG.²⁸ Further typical alterations for pedHGG such as *TP53* mutations and cell cycle disruption occurred at similar frequencies compared to a large meta-analysis of >1000 pedHGG and DIPG by Mackay et al.⁹ Notably, alterations affecting the RTK-PI3K-MAPK pathway were present in 11/12 molecular pedHGG cases in our cohort (91.7%), which is higher than the frequency of 61.7% reported in the mentioned meta-analysis by Mackay et al.⁹

Alterations in *FGFR1* have been described mainly in thalamic HGG with concomitant *H3F3A* K27M mutation,²⁹ but were one of the most frequent alterations in the cohort of spinal pedHGG presented in this study.

With regard to the extremely poor outcome, identification of targets for potential targeted therapy options would be desirable. In the current cohort, findings in several cases could be considered as promising therapeutic targets. The tumor of an infant patient (case #8) carried a *TPM3::NTRK1* fusion. NTRK inhibitors have shown activity in pediatric and adult patients with TRK fusion-positive primary CNS tumors.^{30,31} Moreover, two cases in the cohort exhibiting a hypermutator phenotype were identified. Treatment of pediatric patients suffering from tumors with hypermutator phenotype (TMB > 10), including pedHGG, with immune checkpoint inhibitors has shown responses and prolonged survival.^{32,33} Regarding the most frequently altered targetable gene in this cohort, *FGFR1*, there are case reports demonstrating promising anti-tumor activity of FGFR-inhibitors in FGFR-altered pediatric glioma (both LGG and HGG).^{34,35} The RET-fusion detected in one (non-HGG) tumor might also serve as a therapeutic target for the treatment with a RET inhibitor.³⁶ For the four patients in our cohort who received matching targeted therapy based on the molecular analysis results, the available data does not allow for an evaluation regarding clinical benefit for the patients. Two of these four patients were treated with concomitant antineoplastic therapy (chemotherapy/radiotherapy or both) and due to the fatal course of the disease

all 4 patients died within 7 months after initiation of targeted therapy.

There are several limitations of the current study. The small cohort size impairs profound interpretation, especially of outcome data. Due to the rarity of spinal pedHGG, prospective collections of cases within large (international) consortia are needed. Furthermore, the current cohort includes patients enrolled at primary diagnosis as well as patients suffering from relapse/progressive disease. The heterogeneity in previously applied treatment regimen and the varying duration of the preceding clinical course further hinders to draw detailed conclusions. This limitation could also be overcome by prospectively enrolling cases at primary diagnosis only.

Taken together, with the report on 17 pediatric spinal histological pedHGG cases presented here, we show that the assignment of these tumors to one of the molecular HGG subgroups is possible in most cases. Genetic alterations do not differ remarkably between molecular spinal pedHGG and pedHGG in other midline localizations of the CNS. In a subset of patients, alterations that might serve as promising targets for targeted therapies could be identified. Considering the fatal outcome of this disease, novel treatment approaches are needed and therefore investigations of larger cohorts of spinal pedHGG patients are required.

Supplementary Material

Supplementary material is available online at *Neuro-Oncology Advances* (<https://academic.oup.com/noa>).

Keywords

molecular characterization | pediatric spinal high-grade glioma | therapeutic targets.

Lay Summary

Gliomas are tumors found mostly in the brain, and a lot of research has been done on their genetic changes. Gliomas can rarely also be found in the spine, and their genetics have not been heavily studied. The authors of this study wanted to better understand the genetic changes in spinal high-grade gliomas in children and compare them to those found in the brain. To do this, they identified 17 patients with a diagnosis of spinal high-grade gliomas in a registry and genetically tested the tumors. They found that the genetic changes that are seen in brain gliomas also are seen in spinal gliomas.

Funding

This work was supported by Medical Faculty of Heidelberg University (Olympia-Morata program to E.P.); German Cancer

Research Center (DKFZ, for the INFORM registry); several German health insurance companies (for the INFORM registry); German Cancer Consortium (DKTK, for the INFORM registry); German Federal Ministry of Education and Research (BMBF, for the INFORM registry); German Federal Ministry of Health (BMG, for the INFORM registry); Ministry of Science, Research and the Arts of the State of Baden-Württemberg (MWK BW, for the INFORM registry); German Cancer Aid (DKH, for the INFORM registry), the German Childhood Cancer Foundation (DKS, for the INFORM registry; C.M.K.); RTL television, the aid organization BILD hilft e.V. (Ein Herz für Kinder, for the INFORM registry), private donation of the Scheu family (for the INFORM registry), German Research Foundation (A.v.D.).

Acknowledgments

We would like to express our sincere thanks to Carsten Maus, Erjia Wang (Genomics and Proteomics Core Facility, DKFZ) and Lena Weiser, Gregor Warsow (Omics IT and Data Management Core Facility, DKFZ) for their highly dedicated support in data management and processing as well as Rolf Kabbe (Division of Pediatric Neurooncology, DKFZ) for his sincere and dedicated contribution to the bioinformatics analyses.

Conflict of interest statement

A.v.D.: shareholder in Heidelberg Epignostix. C.M.v.T.: advisory board in Alexion, Bayer, Novartis, and Roche. T.M.: research grants from The Brain Tumor Charity, Biomed Valley Discoveries, and Day One Biopharmaceuticals. C.M.K.: advisory board in Boehringer Ingelheim; contracts for clinical trials: Blueprint Rover and Novartis. A.O.v.B.: advisory board in Alexion and Novartis. S.M.P.: advisory board in BioSkryb; cofounder & shareholder in Heidelberg Epignostix. O.W.: advisory board in Novartis; contracts for clinical trials: Novartis, Bayer, AstraZeneca, Loxo Janssen, Roche, Day One Biopharmaceuticals, and GSK; consulting fees: Roche, BMS, Day One Biopharmaceuticals, Ipsen, and Novartis; receipt of drugs for preclinical testing: BMS, JS Innopharm, Kronos Bio, and ProLynx. D.T.W.J.: advisory board in Day One Biopharmaceuticals; co-founder & shareholder in Heidelberg Epignostix.

Authorship Statement

E.P., K.S., M.B.-J., B.C.J., S.S., G.P.B., C.P., R.J.A., P.F., F.S., D.R., A.v.D., C.M.K., A.O.v.B., M.C.M.-K., I.Ø., and D.T.W.J. were involved in experimental design and provision of data. E.P., K.S., M.B.-J., B.C.J., S.S., G.P.B., C.P., R.J.A., C.M.v.T., K.W.P., T.M., U.D., C.M.K., A.O.v.B., S.M.P., O.W., and D.T.W.J. were involved in analysis and interpretation of data. E.P., K.S., M.B.-J., B.C.J., S.S., G.P.B., C.P., R.J.A., P.F., F.S., D.R., A.v.D., C.M.v.T., K.W.P., T.M., U.D., C.M.K., A.O.v.B., M.C.M.-K., I.Ø., S.M.P., O.W., D.T.W.J. were involved in the writing of the manuscript, approval of the final manuscript version.

Data Availability

The dataset generated and/or analyzed during the current study is available from the corresponding author upon reasonable request.

Affiliations

Division of Pediatric Glioma Research, Hopp Children's Cancer Center Heidelberg (KiTZ), Heidelberg, Germany (E.P., K.S., M.B.-J., B.C.J., S.S., D.T.W.J.); National Center for Tumor Diseases (NCT), NCT Heidelberg, DKFZ and Heidelberg University Hospital, Heidelberg, Germany (E.P., K.S., M.B.-J., B.C.J., S.S., G.P.B., C.P., R.J.A., C.M.v.T., K.W.P., T.M., S.M.P., O.W., D.T.W.J.); German Cancer Research Center (DKFZ), Heidelberg, Germany (E.P., K.S., M.B.-J., B.C.J., S.S., G.P.B., C.P., R.J.A., C.M.v.T., K.W.P., T.M., S.M.P., O.W., D.T.W.J.); Department of Pediatric Oncology, Hematology, Immunology and Pulmonology, Heidelberg University Hospital, Heidelberg, Germany (E.P., B.C.J., S.S., C.M.v.T., K.W.P., T.M., S.M.P., O.W.); Division of Pediatric Neurooncology, Hopp Children's Cancer Center Heidelberg (KiTZ), Heidelberg, Germany (G.P.B., C.P., R.J.A., K.W.P., S.M.P.); Department of Neuropathology, Institute of Pathology, Heidelberg University Hospital, Heidelberg, Germany (P.F., F.S., D.R., A.v.D.); Clinical Cooperation Unit Neuropathology, German Cancer Research Center (DKFZ) and German Cancer Consortium (DKTK), Heidelberg, Germany (P.F., F.S., D.R., A.v.D.); Clinical Cooperation Unit Pediatric Oncology, German Cancer Research Center (DKFZ) and German Cancer Consortium (DKTK), Heidelberg, Germany (C.M.v.T., T.M., O.W.); Department of Pediatrics and Adolescent Medicine, University Hospital Jena, Friedrich Schiller University Jena, Jena, Germany (T.M.); Pediatrics III, West German Cancer Centre Essen, University Hospital Essen, University of Duisburg-Essen, Essen, Germany (U.D.); German Cancer Consortium (DKTK) partner site Essen, University Hospital Essen, Essen, Germany (U.D.); National Center for Tumor diseases (NCT) partner site Essen, University Hospital Essen, Essen, Germany (U.D.); Division of Pediatric Hematology and Oncology, Department of Child and Adolescent Health, University Medical Center Göttingen, Göttingen, Germany (C.M.K.); Department of Pediatrics, Gynecology and Obstetrics, Division of Pediatric Hematology and Oncology, University Hospital of Geneva, Geneva, Switzerland (A.O.v.B.); Cansearch Research Platform for Pediatric Oncology and Hematology, Faculty of Medicine, Department of Pediatrics, Gynecology and Obstetrics, University of Geneva, Geneva, Switzerland (A.O.v.B.); Department of Pediatric Oncology and Hematology, Oslo University Hospital, Oslo, Norway (M.C.M.-K.); Division of Pediatric Hematology-Oncology, Skåne University Hospital, Clinical Sciences IKVL, Lund University, Lund, Sweden (I.Ø.)

References

1. Sturm D, Capper D, Andreiuolo F, et al. Multiomic neuropathology improves diagnostic accuracy in pediatric neuro-oncology. *Nat Med.* 2023;29(4):917–926.
2. Ostrom QT, Price M, Neff C, et al. CBTRUS statistical report: primary brain and other central nervous system tumors diagnosed in the United States in 2016–2020. *Neuro-Oncol.* 2023;25(Supplement_4):iv1–iv99.
3. Nunna RS, Khalid S, Behbahani M, Mehta AI. Pediatric primary high-grade spinal glioma: a National Cancer Database analysis of current patterns in treatment and outcomes. *Child's Nerv Syst.* 2021;37(1):185–193.
4. Wolff B, Ng A, Roth D, et al. Pediatric high grade glioma of the spinal cord: results of the HIT-GBM database. *J Neurooncol.* 2012;107(1):139–146.
5. Lam S, Lin Y, Melkonian S. Analysis of risk factors and survival in pediatric high-grade spinal cord astrocytoma: a population-based study. *Pediatr Neurosurg.* 2012;48(5):299–305.
6. Luksik AS, Garzon-Muvdi T, Yang W, Huang J, Jallo GI. Pediatric spinal cord astrocytomas: a retrospective study of 348 patients from the SEER database. *J Neurosurg Pediatr.* 2017;19(6):711–719.
7. Konar SK, Bir SC, Maiti TK, Nanda A. A systematic review of overall survival in pediatric primary glioblastoma multiforme of the spinal cord. *J Neurosurg Pediatr.* 2017;19(2):239–248.
8. Louis DN, Perry A, Wesseling P, et al. The 2021 WHO classification of tumors of the central nervous system: a summary. *Neuro-Oncol.* 2021;23(8):1231–1251.
9. Mackay A, Burford A, Carvalho D, et al. Integrated molecular meta-analysis of 1,000 pediatric high-grade and diffuse intrinsic pontine glioma. *Cancer cell.* 2017;32(4):520–537.e5.
10. Castel D, Philippe C, Kergrohen T, et al. Transcriptomic and epigenetic profiling of 'diffuse midline gliomas, H3 K27M-mutant' discriminate two subgroups based on the type of histone H3 mutated and not supratentorial or infratentorial location. *Acta Neuropathol Commun.* 2018;6(1):117.
11. Cohen KJ, Jabado N, Grill J. Diffuse intrinsic pontine gliomas-current management and new biologic insights. Is there a glimmer of hope? *Neuro-Oncol.* 2017;19(8):1025–1034.
12. Worst BC, van Tilburg CM, Balasubramanian GP, et al. Next-generation personalised medicine for high-risk paediatric cancer patients—The INFORM pilot study. *Eur J cancer (Oxford, England: 1990).* 2016;65:91–101.
13. van Tilburg CM, Pfaff E, Pajtler KW, et al. The pediatric precision oncology INFORM Registry: clinical outcome and benefit for patients with very high-evidence targets. *Cancer Discov.* 2021;11(11):2764–2779.
14. Heipertz AE, Pajtler KW, Pfaff E, et al. Outcome of children and adolescents with relapsed/refractory/progressive malignancies treated with molecularly informed targeted drugs in the pediatric precision oncology registry INFORM. *JCO Precision Oncology.* 2023;7:e2300015.
15. Pfaff E, El Damaty A, Balasubramanian GP, et al. Brainstem biopsy in pediatric diffuse intrinsic pontine glioma in the era of precision medicine: the INFORM study experience. *Eur J cancer (Oxford, England: 1990).* 2019;114:27–35.
16. Capper D, Jones DTW, Sill M, et al. DNA methylation-based classification of central nervous system tumours. *Nature.* 2018;555(7697):469–474.
17. Feuerbach L, Sieverling L, Deeg KI, et al. TelomereHunter—in silico estimation of telomere content and composition from cancer genomes. *BMC Bioinf.* 2019;20(1):272.
18. Sieverling L, Hong C, Koser SD, et al; PCAWG-Structural Variation Working Group. Genomic footprints of activated telomere maintenance mechanisms in cancer. *Nat Commun.* 2020;11(1):733.
19. Deng MY, Sturm D, Pfaff E, et al. Radiation-induced gliomas represent H3-/IDH-wild type pediatric gliomas with recurrent PDGFRA amplification and loss of CDKN2A/B. *Nat Commun.* 2021;12(1):5530.
20. Campbell BB, Light N, Fabrizio D, et al. Comprehensive analysis of hypermutation in human cancer. *Cell.* 2017;171(5):1042–1056.e10.
21. Rossi S, Barresi S, Colafati GS, et al. PATZ1-rearranged tumors of the central nervous system: characterization of a pediatric series of seven cases. *Mod Pathol.* 2024;37(2):100387.

22. Alhalabi KT, Stichel D, Sievers P, et al. PATZ1 fusions define a novel molecularly distinct neuroepithelial tumor entity with a broad histological spectrum. *Acta Neuropathol.* 2021;142(5):841–857.
23. Siegfried A, Rousseau A, Maurage CA, et al. EWSR1-PATZ1 gene fusion may define a new glioneuronal tumor entity. *Brain Pathol (Zurich, Switzerland).* 2019;29(1):53–62.
24. Bridge JA, Sumegi J, Druta M, et al. Clinical, pathological, and genomic features of EWSR1-PATZ1 fusion sarcoma. *Mod Pathol.* 2019;32(11):1593–1604.
25. Dehner CA, Torres-Mora J, Gupta S, et al. Sarcomas harboring EWSR1::PATZ1 fusions: a clinicopathologic study of 17 cases. *Mod Pathol.* 2024;37(2):100400.
26. Chougule A, Taylor MS, Nardi V, et al. Spindle and round cell sarcoma with EWSR1-PATZ1 gene fusion: a sarcoma with polyphenotypic differentiation. *Am J Surg Pathol.* 2019;43(2):220–228.
27. Dehner CA, Lazar AJ, Chrisinger JSA. Updates on WHO classification for small round cell tumors: Ewing sarcoma vs. everything else. *Hum Pathol.* 2024;147:101–113.
28. Gessi M, Gielen GH, Dreschmann V, Waha A, Pietsch T. High frequency of H3F3A (K27M) mutations characterizes pediatric and adult high-grade gliomas of the spinal cord. *Acta Neuropathol.* 2015;130(3):435–437.
29. Fontebasso AM, Papillon-Cavanagh S, Schwartzenuber J, et al. Recurrent somatic mutations in ACVR1 in pediatric midline high-grade astrocytoma. *Nat Genet.* 2014;46(5):462–466.
30. Doz F, van Tilburg CM, Georger B, et al. Efficacy and safety of larotrectinib in TRK fusion-positive primary central nervous system tumors. *Neuro-Oncol.* 2022;24(6):997–1007.
31. Desai AV, Robinson GW, Gauvain K, et al. Entrectinib in children and young adults with solid or primary CNS tumors harboring NTRK, ROS1, or ALK aberrations (STARTRK-NG). *Neuro-Oncol.* 2022;24(10):1776–1789.
32. Bouffet E, Larouche V, Campbell BB, et al. Immune checkpoint inhibition for hypermutant glioblastoma multiforme resulting from germline biallelic mismatch repair deficiency. *J Clin Oncol.* 2016;34(19):2206–2211.
33. Das A, Tabori U, Sambira Nahum LC, et al. Efficacy of nivolumab in pediatric cancers with high mutation burden and mismatch-repair deficiency. *Clin Cancer Res.* 2023;29(23):4770–4783.
34. Stepien N, Mayr L, Schmook MT, et al. Feasibility and antitumour activity of the FGFR inhibitor erdafitinib in three paediatric CNS tumour patients. *Pediatr Blood & Cancer.* 2024;71(3):e30836.
35. Farouk Sait S, Gilheeney SW, Bale TA, et al. Debio1347, an oral FGFR inhibitor: results from a single-center study in pediatric patients with recurrent or refractory FGFR-altered gliomas. *JCO Preci Oncol.* 2021;5:876–883.
36. Czech C, Chen A, Morgan KP, et al. Response to selpercatinib in a patient with recurrent glioblastoma and RET amplification. *J Natl Compr Cancer Netw.* 2022;20(9):966–971.