

Access this article online

Quick Response Code:



Website:  
www.ajts.org

DOI:  
10.4103/ajts.AJTS\_25\_17

# Effect of autologous PRP on wound healing in dental regenerative surgeries and its correlation with PDGF levels

Rahul Verma, Gita Negi, Abhishek Kandwal<sup>1</sup>, Harish Chandra<sup>2</sup>,  
Dushyant Singh Gaur, Meena Harsh

## Abstract:

**INTRODUCTION:** Autologous platelet-rich plasma (PRP) is the fraction of blood plasma, with increased concentration of platelets, from baseline serum level. Growth factors (GFs) in PRP expedite the soft tissue and bony healing. However, estimation of their levels and role in healing had not been studied extensively. This study gives an insight to the quantification of platelet-derived GF-BB (PDGF-BB) present in PRP and its correlation with the clinical wound healing and bone regeneration.

**AIMS:** This study aims to quantify PDGF-BB levels in PRP with its subsequent correlation with healing in dental regenerative surgeries.

**SETTINGS AND DESIGN:** This was an experimental study including patients undergoing various dental regenerative surgeries.

**SUBJECTS AND METHODS:** Autologous thrombin-activated PRP in the form of PRP gel was used in study group ( $n = 39$ ) whereas no such intervention was given in control group ( $n = 30$ ). PDGF-BB quantification was done in PRP samples using enzyme-linked immunosorbent assay. Clinicoradiological evaluation of healing was done in both the groups.

**STATISTICAL ANALYSIS USED:** Descriptive analysis, independent Z-test, Correlation regression analysis, and ANOVA.

**RESULTS:** Mean platelet concentration achieved in PRP was 5.79 times the baseline count. Mean PDGF-BB concentration in PRP was  $31.92 \pm 10.47$  ng/ml which significantly correlated ( $P < 0.05$ ) with the PRP platelet count. Study group showed significant healing clinically ( $P < 0.05$ ). Significant bone fill observed in study group at 3 and 6 months when compared to the baseline as well as control group. Furthermore, bone fill at 6 months showed linear correlation with PDGF-BB levels ( $r = 0.80$ ).

**CONCLUSIONS:** PRP led to enhanced bone regeneration and soft-tissue healing with former being directly related to higher concentration of PDGF-BB.

## Keywords:

Platelet-derived growth factor-BB, platelet-rich plasma, regeneration

## Introduction

Platelet-rich plasma (PRP) has recently gained popularity in fields such as wound healing and regenerative medicine.<sup>[1]</sup> It is fraction of blood plasma, which has an

increased concentration of platelets, from a baseline serum level.<sup>[2]</sup> Autologous PRP contains patient's own platelets and plasma and is a simple, low-cost, and minimally invasive method which provides a natural concentrate of autologous blood growth factors (GFs) that can be used to enhance tissue regeneration.<sup>[3]</sup> Recently, PRP has

This is an open access journal, and articles are distributed under the terms of the Creative Commons Attribution-NonCommercial-ShareAlike 4.0 License, which allows others to remix, tweak, and build upon the work non-commercially, as long as appropriate credit is given and the new creations are licensed under the identical terms.

For reprints contact: reprints@medknow.com

**How to cite this article:** Verma R, Negi G, Kandwal A, Chandra H, Gaur DS, Harsh M. Effect of autologous PRP on wound healing in dental regenerative surgeries and its correlation with PDGF levels. Asian J Transfus Sci 2019;13:47-53.

Departments of  
Pathology and <sup>1</sup>Dentistry,  
Swami Rama Himalayan  
Institute, Dehradun,  
Uttarakhand, <sup>2</sup>Department  
of Pathology, All India  
Institute of Medical  
Sciences, Rishikesh,  
Uttarakhand, India

## Address for correspondence:

Dr. Rahul Verma,  
Department of  
Pathology, Swami Rama  
Himalayan University,  
Dehradun - 248 140,  
Uttarakhand, India.  
E-mail: rahulsrhu@gmail.  
com

Submission: 23-02-2017  
Accepted: 06-02-2018

become a valuable adjunct to promote healing in many procedures in dental and oral surgeries such as tooth extraction surgeries, periapical surgeries, ablative surgical procedures, mandibular reconstruction, alveolar cleft repair, infrabony periodontal defects as well as procedures relating to the placement of osseointegrated implants.<sup>[4]</sup> Commonly, PRP is used in a gel formulation in dental surgeries, which is formed by mixing PRP with thrombin and calcium chloride. Autologous thrombin can be used for PRP gel formation to bypass the life-threatening coagulopathies which can occur due to bovine thrombin use.<sup>[5]</sup> Platelets release GFs, which upon activation, are essential for physiological healing as they stimulate revascularization and supply necessary nutrients needed for cells to regenerate the damaged tissue. Platelet-derived GF (PDGF) is a major constituent of PRP, responsible for chemotaxis, cell differentiation, angiogenesis, and possibly mitogenic effects of PRP on osteoblasts. It has various isoforms such as PDGF-AA, AB, and BB, out of which PDGF-BB is present in the highest concentration.<sup>[6]</sup> Hence, it seems very logical that increasing the concentration of platelets and therefore increasing the concentration of GFs may lead to a more rapid regeneration.<sup>[7]</sup> Variables such as preparation method, platelet concentration, platelet activation, and physical may lead to inconsistency in clinical and experimental methodology thus making it difficult to standardize PRP as a product.<sup>[8]</sup> Over the last decade, PRP had been studied extensively for its role in accelerating tissue regeneration; moreover, it has been established that PRP formulations have increased concentration of various GFs, but whether such high concentration of latter is responsible for the desired clinical effect is still debatable. Simultaneous evaluation of healing effect of PRP as well as correlation of healing with the GF levels in PRP will lead to better understanding of the efficacy of the PRP therapy. To the best of our knowledge, although PDGF-BB quantification had been done in PRP formulations, their role in healing, especially in periodontal defect regenerative surgeries had not been studied extensively. Since Himalayan Hospital is a tertiary care center, a large number of patients undergo tooth extraction, periodontal surgeries, and periapical surgeries. As per many previous studies, PRP is effective in tissue and bone regeneration in many dental surgeries and helps in shortening the wound healing period. Therefore, the study was being undertaken to evaluate the healing effect of autologous PRP in patients undergoing dental regenerative surgeries and to correlate the healing effect with PDGF-BB levels in of PRP-gel.

## Subjects and Methods

The study was carried out in the Department of Pathology in collaboration with Dentistry Department at Himalayan Institute of Medical Sciences, Swami Ram Nagar, Dehradun over a period of 12 months from

January 2015 to December 2015 after getting approval from the ethical committee. We did an experimental study including 69 cases of tooth extraction, periapical, and periodontal surgeries after obtaining written informed consent from the patients. All the cases were segregated using simple randomization. Cases which received the PRP therapy were allocated as study group ( $n = 39$ ) and those which did not as control group ( $n = 30$ ). PRP was prepared from the study group patient's blood using two spin technique. Under aseptic conditions, patient's blood was collected in four 10 ml ACD-A vacutainers and one ethylenediaminetetraacetic acid (EDTA) vial. Complete hemogram was performed on EDTA vial sample. ACD-A vacutainers were kept at room temperature for 40–45 min and then centrifuged at 1600 rpm for 15 min. Supernatant-containing platelets as well as plasma was aspirated from the ACD-A vacutainers using a 20-G spinal needle, without disturbing the buffy coat and transferred to a conical tube. This conical vial containing only platelets and plasma was again centrifuged at 2800 rpm for 7 min. Upper 2/3<sup>rd</sup> platelet poor plasma (PPP) was transferred in a plain vial and 5 ml plasma with platelet pellet (PRP) at its base was left for 1 h at room temperature without disturbing the sediments. Sediments were resuspended and kept it an agitator for another 2 h. One milliliter sample from the PRP prepared was taken for platelet count. Two milliliters of PRP were kept for gel formation and rest 2 ml was kept for GF quantification. Meanwhile, autologous thrombin was prepared by adding 0.2cc calcium gluconate to 5 cc PPP and agitating vigorously by shaking and inverting the vial five times. After 6 min, a gel was formed from PPP which was squeezed a bit with the spinal needle and the extracted solution was slowly aspirated to obtain calcium-stimulated autologous thrombin. PRP gel was then prepared intraoperatively by mixing PRP with autologous thrombin and calcium gluconate in the ratio of 5:2:1 vol at 24°C. The vial was agitated for 6–10 s to initiate clotting. After approximately 2 min, a gel was formed which within 30 min was placed in the bony cavity or the wound created during the dental surgery. Same volume of PRP was used to prepare PRP gel for all patients in the study group. Remaining 2 ml PRP sample kept for the GF estimation was also activated similarly using autologous thrombin and calcium gluconate and was kept overnight at 4°C for maximum clot retraction. Next day, the contents were centrifuged at 1000 g for 30 min and supernatant containing the GFs released from the alpha granules of activated platelets was aspirated and stored in aliquots at -70°C for PDGF-BB quantification later on. PDGF-BB quantification by ELISA (QAYEE BIO LTD) was done as per the kit manufacturer protocol. Clinical and radiological evaluation of healing was done in both study and control group. Clinical assessment of healing in both study and control groups was done 1 week

postoperatively on the day of suture removal according to healing index (HI) by Landry and Turnbull.<sup>[9]</sup> For radiographic evaluation, a baseline, 3<sup>rd</sup>, and 6<sup>th</sup> month intraoral periapical radio-visual graph (IOPA RVG) were taken after the surgical procedure in both the control and study group. Imaging software (ImageJ v1.50a,NIH,USA) was used to compare the images at baseline, 3, and 6 months for relative radiographic density (RRD) at specific reference points. For RRD, the average gray value of the boney cavity was calculated from the IOPA RVGs.

**Data management and statistical analysis**

Quantitative data were expressed in terms of mean and standard deviation. Independent Z-test was used to compare the mean relative density between two groups and paired Z-test was used to compare the mean relative density within the groups at different time interval. Correlation regression analysis was done between PDGF-BB and various parameters such as PRP platelet count, radiographic density, and healing scores. ANOVA was used to find significance in healing at 3- and 6-month follow-up.  $P < 0.05$  was considered as statistical significant with 95% confidence level. All statistical analyses were entered and analyzed using IBM SPSS Statistics software v. 22 (IBM,USA) and Microsoft excel 2007( Microsoft windows, USA).

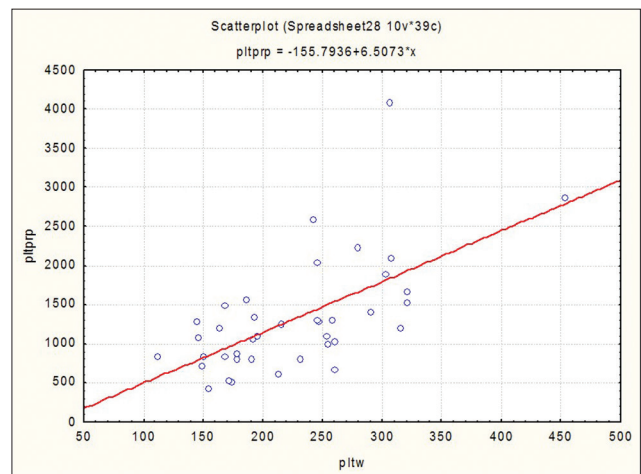
**Results**

In the study group, mean age was  $32 \pm 9.01$  with female predominance ( $n = 24/39$ ; 62%). In the study group, maximum numbers of cases were of periapical pathology ( $n = 15/39$ ; 38.4%) followed by impacted 3<sup>rd</sup> molar ( $n = 8/39$ ; 20.5%), periapical lesion ( $n = 7/39$ ; 17%), intra bony periodontal defects ( $n = 6/39$ ; 15%), and palatal impacted canine ( $n = 3/39$ ; 0.07%). Whereas, in control group, impacted molar was the most common diagnosis ( $n = 17/30$ ; 56.6%) followed by periapical pathology ( $n = 8/30$ ; 26.6%) and fracture tooth ( $n = 5/30$ ; 16.6%). Mean platelet concentration achieved in PRP in study group ( $n = 39$ ) was 13, 17, 025/mm<sup>3</sup> which was 5.79 times the baseline platelet count. There was a significant linear correlation between the platelets from whole blood and PRP as shown in Figure 1. PDGF-BB concentration in PRP varied from 22.66 ng/ml to 72 ng/ml with mean concentration of  $31.92 \pm 10.47$  ng/ml. The correlation between PGDF-BB and platelets from PRP was also highly significant ( $r = 0.90, P < 0.00$ ) as shown in Figure 2. Clinically, healing was significantly ( $P < 0.05$ ) better in study group at seventh postoperative day when compared to control group as shown in Table 1. However, within the study group, PDGF-BB values had no significant effect ( $P = 0.24$ ) on the healing score at seventh postoperative day. In study group, when compared to baseline X-ray [Figure 3], radiographic

analysis showed significant bone fill at 3 [Figure 4] and 6 months [Figure 5] after PRP gel placement in apicoectomy region. Bone healing was comparatively delayed in control group where PRP intervention was not given [Figures 6-8]. ImageJ analysis of the radiographic bone fill density was done by calculating the mean gray value of the region of interest as shown in Figure 9. Radiographic density was significantly higher in study group at 3 and 6 months ( $P < 0.05$ ) when compared to control group as shown in Table 2. RRD at 6 months was statistically significantly linearly correlated with PGDF-BB ( $r = 0.80$ ) at  $P < 0.05$ .

**Discussion**

In the present study, we have studied the role of PRP gel along with the quantification of PDGF-BB levels in the PRP products used in various dental regenerative surgeries. Surgical sites enhanced with PRP have been shown to heal at 2–3 times that of normal surgical sites.<sup>[10]</sup> Although PRP is used in a variety of clinical fields such as the management of chronic wounds,<sup>[11]</sup> dental regenerative surgeries, bone healing,<sup>[12]</sup> and skin rejuvenation,<sup>[13]</sup> the efficacy thereof is debated. Mean platelet concentration achieved in the PRP was 5.79 times

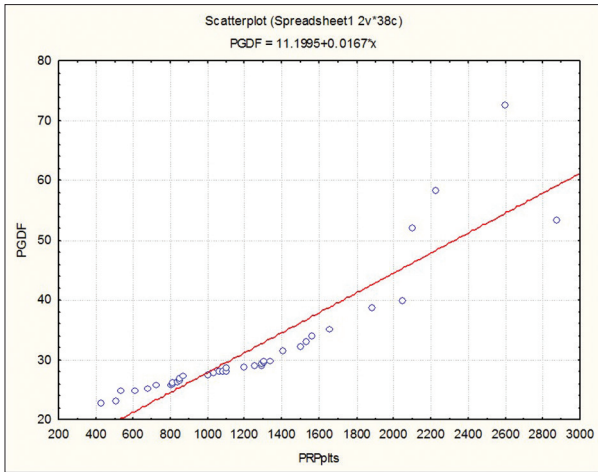


**Figure 1:** Correlation between whole blood platelet count and platelet-rich plasma platelet count. (plprp = Platelet count platelet-rich plasma, pltw = Platelet count whole blood). The linear correlation between the platelets from whole blood and platelet rich plasma was 0.62 (significant at 0.05 level) signifying that there exists a significant linear relationship, therefore suggesting that the platelet count in platelet-rich plasma increased with the increasing platelet count in whole blood

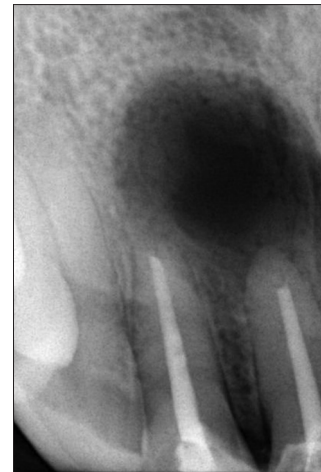**Table 1: Analysis of Landry, Turnbull, and Howley healing score (comparison between cases and controls)**

Variables	Rank sum study group (n=39)	Rank sum control group (n=30)	U	Z	Z-adjusted	P-level	Two-tailed exact (P)
Healing score	1413	240	69	4.8	5.29	0.00	0.00

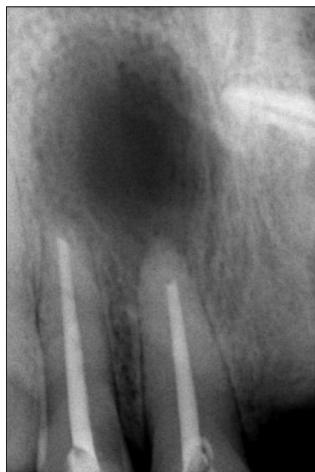



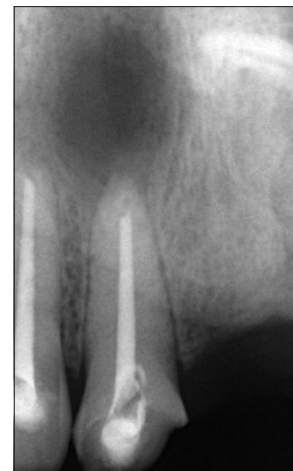**Figure 2:** Correlation between platelet-derived growth factor-BB and platelet-rich plasma platelet count. The strong linear relationship between platelet-derived growth factor-BB and platelet-rich plasma platelets is indicated by the scatter plot above. Prediction Model: platelet-derived growth factor-BB = 11.20 + 0.02 (platelet-rich plasma platelet count). For our study, the prediction model was able to predict the platelet-derived growth factor-BB values from the platelet-rich plasma platelets with strong linear relationship (very high adjusted R2 value of 0.80)



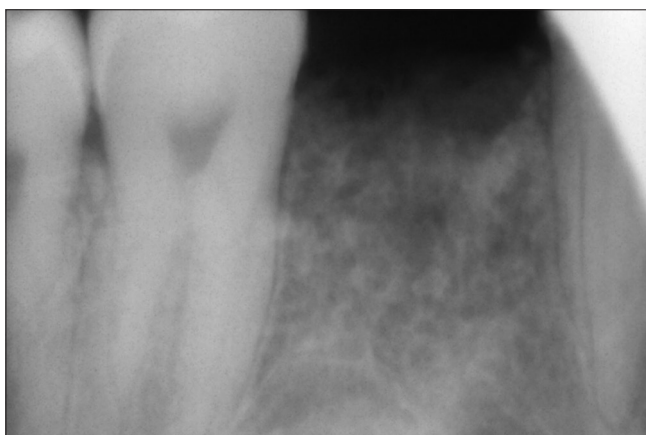**Figure 3:** Study group baseline intraoral periapical radio-visual graph



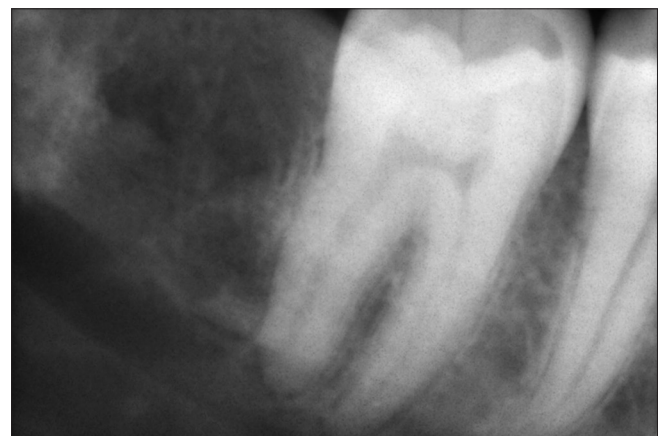**Figure 4:** Study group intraoral periapical radio-visual graph at 3 months



**Figure 5:** Study group intraoral periapical radio-visual graph at 6 months. Radiographic analysis shows clinically significant improvement at 3 and 6 months postplatelet-rich plasma gel placement in apicoectomy region



**Figure 6:** Control group baseline intraoral periapical radio-visual graph



**Figure 7:** Control group intraoral periapical at 3 months

the baseline platelet count. Platelet concentrations achieved in the present study was in concordance with

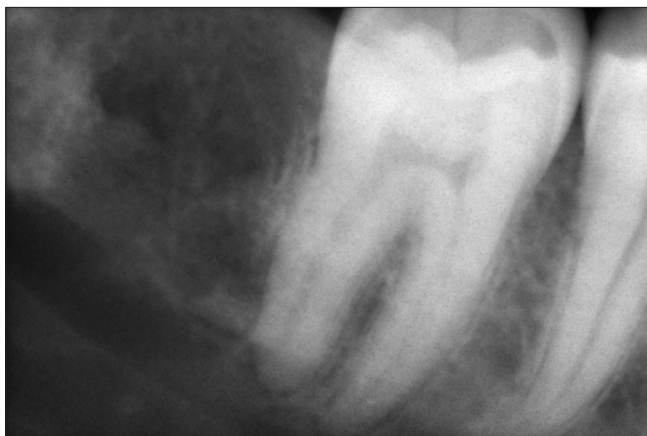Filardo *et al.*<sup>[14]</sup> and Kon *et al.*<sup>[15]</sup> Clinical assessment done on seventh postoperative day using Laundry and Turnbull HI showed that healing was significantly higher in study group where PRP was used ( $P < 0.05$ ). Findings

were in conformity with the studies of Kumar and Shubhashini,<sup>[16]</sup> Jankovic *et al.*,<sup>[9]</sup> Sammartino *et al.*,<sup>[17]</sup> and Simonpieri *et al.*<sup>[18]</sup> PRP lead to faster and enhanced bone healing in view of the increased radiographic density at various intervals. The control group required 6 months to reach the same degree of radiographic density as the PRP treatment achieved in 3 to 4 months. Mean gray value in study group where PRP gel was used was 65.21, 105.30, and 145.25 at baseline, 3, and 6 months, respectively. The values at 3 and 6 months were higher in the study group than the corresponding values at 3 and 6 months in control group where PRP was not used. Our results

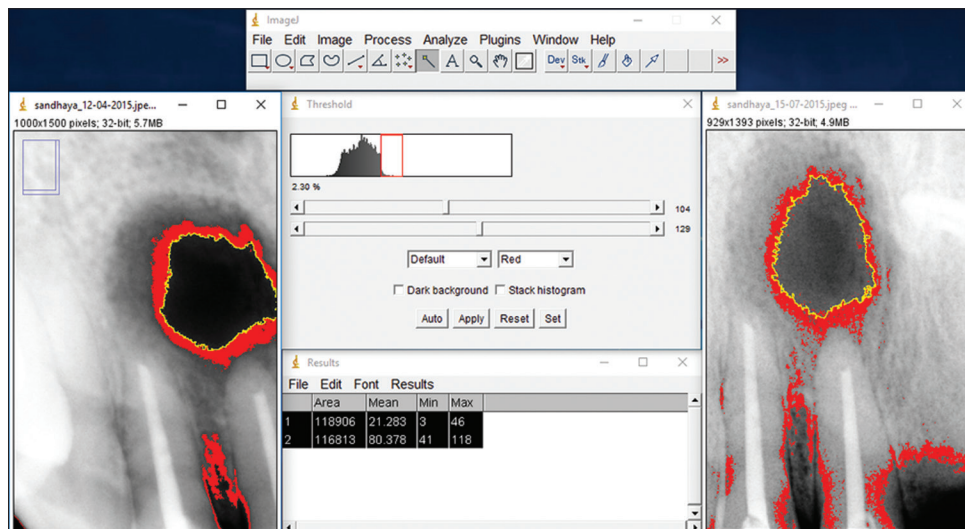
were in concordance with study conducted by Nathani *et al.* where they found that average gray level value at 16 weeks in PRP site was 144.29.<sup>[19]</sup> PRP stimulate both wound healing and bone regeneration owing to increased bone fill visualized as increased radiographic bone density. PRP also acts as bone space maintainer to prevent epithelium migration into the bony cavity. Later, this autologous PRP gel clot reorganizes to form bone under the effect of various GFs such as PDGF, transforming growth factor beta, and vascular endothelial growth factor, which take part in the regulation of bone repair and regeneration. Mean concentration of PDGF-BB in PRP samples was  $31.92 \pm 10.47$ . Our results were in line with previous findings by Lee *et al.* where PDGF-BB level was found to be  $37.15 \pm 1.62$  ng/ml; however, they did not correlate these levels with healing.<sup>[20]</sup> The correlation between PGDF-BB and RRD at 3 months was not significant ( $r = 0.24$ ). This is due to the fact that bone mineralization is not evident on X-ray in the initial 2–3 months as bone matrix is still maturing and also due to the limitation of the X-rays to capture early mineralization on image. Although there was significant difference between baseline defect and 3 months, ensuing rapid healing, the same was not related to the PDGF-BB levels. However, RRD at 6 months was significantly linearly correlated with PGDF-BB ( $r = 0.80$ ) at  $P < 0.05$  indicating that patients treated with PRP having increased concentration of PDGF-BB had increased radiographic density at 6 months as compared to PRP with lower PDGF-BB values. Similar results were obtained by Nevins *et al.*,<sup>[21]</sup> Howell *et al.*,<sup>[22]</sup> Mitlak *et al.*,<sup>[23]</sup> and Sarment *et al.*<sup>[24]</sup> who investigated the role of purified recombinant human PDGF prepared as a potential drug therapy in bone healing. However, in all these studies, synthetically prepared recombinant PDGF-BB does not Provide the advantages of the autologous PRP-derived PDGF-BB; moreover, the latter is cost effective. Our

**Table 2: Relative radiographic density comparison between study and control group**

	Mean control group (n=30)	Mean study group (n=39)	t	P
Baseline	62±16.29	65.21±25.96	0.50	0.61
3 months	88±16.56	105.30±32.21	-2.98	0.00
6 months	125±31.98	145.30±20.96	-2.71	0.00



**Figure 8:** Control group intraoral periapical radio-visual graph at 6 months. Control group had comparatively less and delayed bone healing



**Figure 9:** ImageJ analysis of the baseline and 3-month follow-up intraoral periapical showing significant bone fill measured in terms of increased mean gray value

study gives an insight into the regenerative effect of PDGF-BB present in PRP; however, whether their levels lead to enhanced regeneration in early phases of healing is still questionable and need to be further evaluated. Furthermore, simultaneous quantification of other GFs and their role in healing need to be evaluated to prove the fact that PRP has potential effect on wound healing and bone regeneration. Nevertheless, PRP gel can be considered as an effective agent for wound healing and regeneration in periodontal intrabony defects (four wall, three wall defects) and maxillary sinus augmentation procedures. It is also worth mentioning that PRP use in dental regenerative surgeries is 10–20 times cheaper than commercially available bone substituting graft materials. Moreover, autologous PRP clot do not cause any antigenic reaction as well as no chance of graft infection. The limiting factors of our study are the oral hygiene maintenance, host diet, host modulation factors, and lifestyle of each patient which are expected to be different thus affecting the outcomes of the study. Further split-mouth design can be undertaken to exclude inpatient variability. Larger sample size with similar surgical procedures should be taken to minimize the variability due to the surgical interventions. Bone height and width had not been measured.

## Conclusions

To summarize, definite improvement in the soft-tissue healing and faster regeneration of bone after surgery was observed in cases treated with PRP as compared to the control group postoperatively. This improvement in the wound healing and increase in the bone density signify and highlight the use of PRP, certainly as a valid method in inducing and accelerating tissue regeneration. Quantification of PDGF-BB released by the PRP led to the evaluation of role of PDGF in healing. Levels of PDGF-BB were not only proportional to the platelet counts in PRP but also positively correlated with the radiographic healing at 6 months. Therefore, considering the wide applications of PRP nowadays, it becomes necessary to evaluate its role in tissue healing and regeneration which can be validated by quantification and correlation of various GFs and cytokines, present in it, with the healing and regeneration. However, care should be exercised when drawing conclusions from these results concerning the effect of PRP gel on soft-tissue healing because larger sample size and more prolonged clinical evaluation may be required for reproducibility, accuracy, and validity of this index.

## Financial support and sponsorship

This study was financially supported by Research Committee of Swami Rama Himalayan University, Dehradun, Uttarakhand, India.

## Conflicts of interest

There are no conflicts of interest.

## References

1. Boswell SG, Cole BJ, Sundman EA, Karas V, Fortier LA. Platelet-rich plasma: A milieu of bioactive factors. *Arthroscopy* 2012;28:429-39.
2. Weibrich G, Kleis WK, Hafner G, Hitzler WE. Growth factor levels in platelet-rich plasma and correlations with donor age, sex, and platelet count. *J Craniomaxillofac Surg* 2002;30:97-102.
3. Civinini R, Macera A, Nistri L, Redl B, Innocenti M. The use of autologous blood-derived growth factors in bone regeneration. *Clin Cases Miner Bone Metab* 2011;8:25-31.
4. Albanese A, Licata ME, Polizzi B, Campisi G. Platelet-rich plasma (PRP) in dental and oral surgery: From the wound healing to bone regeneration. *Immun Ageing* 2013;10:23.
5. So SG LJ, Park JB, Kim HC, Park IH, Lee SC. Using Autologous Thrombin in Making PRP Gel-case Reports [Internet]. *Kaidimplant* 2009. Available from: <http://www.kaidimplant.or.kr/k1/journal/pdf/kaid26-1-09.pdf>. [cited 15 June 2016].
6. Colciago A, Celotti F, Casati L, Giancola R, Castano SM, Antonini G, et al. *In vitro* effects of PDGF isoforms (AA, BB, AB and CC) on migration and proliferation of saOS-2 osteoblasts and on migration of human osteoblasts. *Int J Biomed Sci* 2009;5:380-9.
7. Dugrillon A, Eichler H, Kern S, Klüter H. Autologous concentrated platelet-rich plasma (cPRP) for local application in bone regeneration. *Int J Oral Maxillofac Surg* 2002;31:615-9.
8. Textor J. Platelet-rich plasma (PRP) as a therapeutic agent: Platelet biology, growth factors and a review of the literature. In: Lana JF, Andrade Santana MH, Dias Belangero W, Malheiros Luzo AC, editors. *Platelet-Rich Plasma: Lecture Notes in Bioengineering*. Berlin, Heidelberg: Springer; 2014. p. 61-94.
9. Jankovic SM, Zoran AM, Vojislav LM, Bozidar DS, Kenny BE. The use of platelet-rich plasma in combination with connective tissue grafts following treatment of gingival recessions. *PERIO-Periodontal Pract Today* 2007;4: 63-71.
10. Rick G, Smith CJ, Mark S. Campbell. Platelet-rich plasma: Properties and clinical applications. *J Lanc Gen Hosp* 2007; 2: 73-78.
11. Bae JH, Kim YK, Myung SK. Effects of platelet-rich plasma on sinus bone graft: Meta-analysis. *J Periodontol* 2011;82:660-7.
12. Plachokova AS, Nikolidakis D, Mulder J, Jansen JA, Creugers NH. Effect of platelet-rich plasma on bone regeneration in dentistry: A systematic review. *Clin Oral Implants Res* 2008;19:539-45.
13. Sheth U, Simunovic N, Klein G, Fu F, Einhorn TA, Schemitsch E, et al. Efficacy of autologous platelet-rich plasma use for orthopaedic indications: A meta-analysis. *J Bone Joint Surg Am* 2012;94:298-307.
14. Filardo G, Kon E, Buda R, Timoncini A, Di Martino A, Cenacchi A, et al. Platelet-rich plasma intra-articular knee injections for the treatment of degenerative cartilage lesions and osteoarthritis. *Knee Surg Sports Traumatol Arthrosc* 2011;19:528-35.
15. Kon E, Filardo G, Di Matteo B, Di Martino A, Marcacci M. Platelet-rich plasma in sports medicine: New treatment for tendon and cartilage lesions. *Oper Tech Orthop* 2012;22:78-85.
16. Kumar RV, Shubhashini N. Platelet rich fibrin: A new paradigm in periodontal regeneration. *Cell Tissue Bank* 2013;14:453-63.
17. Sammartino G, Tia M, Marenzi G, di Lauro AE, D'Agostino E, Claudio PP, et al. Use of autologous platelet-rich plasma (PRP) in periodontal defect treatment after extraction of impacted mandibular third molars. *J Oral Maxillofac Surg* 2005;63:766-70.
18. Simonpieri A, Del Corso M, Sammartino G, Dohan Ehrenfest DM. The relevance of choukroun's platelet-rich fibrin and metronidazole during complex maxillary rehabilitations using bone allograft.

- Part II: Implant surgery, prosthodontics, and survival. *Implant Dent* 2009;18:220-9.
19. Nathani DB, Sequeira J, Rao BH. Comparison of platelet rich plasma and synthetic graft material for bone regeneration after third molar extraction. *Ann Maxillofac Surg* 2015;5:213-8.
  20. Lee JW, Kwon OH, Kim TK, Cho YK, Choi KY, Chung HY, *et al.* Platelet-rich plasma: Quantitative assessment of growth factor levels and comparative analysis of activated and inactivated groups. *Arch Plast Surg* 2013;40:530-5.
  21. Nevins M, Giannobile WV, McGuire MK, Kao RT, Mellonig JT, Hinrichs JE, *et al.* Platelet-derived growth factor stimulates bone fill and rate of attachment level gain: Results of a large multicenter randomized controlled trial. *J Periodontol* 2005;76:2205-15.
  22. Howell TH, Fiorellini JP, Paquette DW, Offenbacher S, Giannobile WV, Lynch SE, *et al.* A phase I/II clinical trial to evaluate a combination of recombinant human platelet-derived growth factor-BB and recombinant human insulin-like growth factor-I in patients with periodontal disease. *J Periodontol* 1997;68:1186-93.
  23. Mitlak BH, Finkelman RD, Hill EL, Li J, Martin B, Smith T, *et al.* The effect of systemically administered PDGF-BB on the rodent skeleton. *J Bone Miner Res* 1996;11:238-47.
  24. Sarment DP, Cooke JW, Miller SE, Jin Q, McGuire MK, Kao RT, *et al.* Effect of rhPDGF-BB on bone turnover during periodontal repair. *J Clin Periodontol* 2006;33:135-40.