



Original Article

Corresponding Author

Seok-Won Chung

 <https://orcid.org/0000-0002-7577-0603>

Department of Neurosurgery, Daegu Spine Health Wooridul Hospital, 648 Gukchaebosng-ro, Jung-gu, Daegu 41939, Korea

Tel: +82-53-212-3096

Fax: +82-53-212-3068

E-mail: neurochung79@gmail.com

Received: January 4, 2017

Revised: February 14, 2018

Accepted: February 15, 2018

Cerebral Thromboembolic Events During Anterior Cervical Spine Surgery: Retrospective Case Series Study With Diffusion-Weighted Magnetic Resonance Imaging Follow-up in the Immediate Postoperative Period

Seok-Won Chung¹, Min-Soo Kang¹, Sang-Ho Lee², Shin-Young Lee¹, Yong-Hwan Shin¹, Chan-Hong Park³

¹Department of Neurosurgery, Daegu Spine Health Wooridul Hospital, Daegu, Korea

²Department of Neurosurgery, Spine Health Wooridul Hospital, Seoul, Korea

³Department of Anesthesiology and Pain Medicine, Daegu Spine Health Wooridul Hospital, Daegu, Korea

Objective: We evaluated the efficacy of diffusion-weighted magnetic resonance imaging (DW-MRI) in detecting perioperative cerebral thromboembolic events after anterior cervical discectomy and fusion (ACDF).

Methods: This retrospective case series included 51 consecutive patients that underwent ACDF. To assess baseline presence of plaque or stenosis, all patients were assessed for risk factors of cerebrovascular events and underwent carotid ultrasound preoperatively and cerebral DW-MRI was performed in all patients postoperatively, with areas of high signal intensity interpreted as a cerebral thromboembolic event.

Results: One male patient who underwent a C4/5 ACDF had a focal diffusion abnormality on DW-MRI concerning for cerebral thromboembolic events in the right posterior cerebral artery territory. He remained asymptomatic and did not display related neurological symptoms, such as visual deficits.

Conclusion: Asymptomatic cerebral thromboembolic events can be detected by DW-MRI after ACDF. The incidence of such events remains very rare despite the direct manipulation and associated alteration of common carotid artery flow dynamics.

Keywords: Anterior cervical spine surgery, Cerebral thromboembolic event, Diffusion-weighted magnetic resonance imaging



This is an Open Access article distributed under the terms of the Creative Commons Attribution Non-Commercial License (<http://creativecommons.org/licenses/by-nc/4.0/>) which permits unrestricted non-commercial use, distribution, and reproduction in any medium, provided the original work is properly cited.

Copyright © 2018 by the Korean Spinal Neurosurgery Society

INTRODUCTION

Since the description of the anterior cervical discectomy and fusion (ACDF) by Robinson and Smith in 1955,¹ it has become one of the most common procedures performed by spinal neurosurgeons. Although ACDF is generally regarded as safe, pro-

longed retraction of the common carotid artery which is for adequate surgical exposure may decrease the blood flow of the common carotid artery during the surgery.² The reported incidence of postoperative cerebrovascular events associated with ACDF is only 0.13%, representing 1.51% of all complications.³ Of the few reports in the literature of cerebrovascular ischemic

complications associated with ACDF, most of them were symptomatic events.^{4,5} Recently, diffusion-weighted magnetic resonance imaging (DW-MRI) has been used to detect clinically silent thromboembolic events in cerebral endovascular procedures, with sensitivity as high as 60% to 80%.⁶⁻⁹ The ability of DW-MRI to give unique information regarding the viability of brain tissue suggests that this technique could permit improved detection of cerebral events associated with ACDF. We therefore obtained DW-MRI postoperatively in patients who underwent ACDF to assess the incidence of cerebral thromboembolic events, both symptomatic and asymptomatic.

MATERIALS AND METHODS

From April 2013 to April 2014, 51 patients with a mean age of 49.9 ± 12.1 years old were enrolled in the present study. All patients were sequentially scheduled for instrumental anterior cervical discectomy and fusion (ACDF) surgery at either 1 or 2 levels. Exclusion criteria were history of anterior neck surgery, including anterior cervical spine surgery and thyroid gland surgery. A total of 4 patients were excluded. Demographics of patients and surgical levels are summarized in Table 1.

Duplex ultrasound measurements of right common carotid artery dimensions and flow velocities were obtained preoperatively using a 128XP-10 ultrasound machine (Accuson, Denver, CO, USA). Atherosclerotic carotid disease was classified into 4 categories: mild (<39% stenosis), moderate (<59% stenosis),

severe (<79% stenosis), and critical (>80% stenosis). All patients underwent the surgery using the Smith-Robinson approach via the right side. During the surgery, a Caspar cervical self-retaining retractor (Aesculap, Tuttingen, Germany) was continuously applied to provide adequate surgical exposure of the anterior right aspect of the cervical spine. The retractor was positioned to move the right sternocleidomastoid muscle, right jugular vein, right common carotid artery, and right vagus nerve laterally, while moving the esophagus and the trachea medially. The retraction duration was recorded as part of the anesthesia record.

Within 48 hours after surgery, cerebral DW-MRI was routinely performed to assess for thromboembolic events, regardless of any changes in the patients' neurological status. A high-signal intensity lesion on the DW-MRI was interpreted as an acute thromboembolic event, and the number and locations of these lesions were recorded.

RESULTS

Preoperative duplex ultrasound measurements of the common carotid artery showed mild (<39% stenosis) atherosclerotic disease with mural plaques in three patients (5.8%); the remaining 48 patients had no evidence of preexisting carotid artery disease. None of the patients with preexisting carotid artery received prophylactic anticoagulant treatment. The mean retraction time was 159 ± 24.3 minutes ($n = 39$) for single-level ACDF and 220 ± 33.4 minutes ($n = 12$) for 2-level ACDF. There were no episodes of adverse events such as intraoperative hypo-

Table 1. Patient demographic data ($n = 51$)

Variable	Value
Age (yr)	49.9 ± 12.1
Sex	
Male	33
Female	18
Surgical Level	
Single level ($n = 39$)	
C3-4	4
C4-5	9
C5-6	22
C6-7	4
Two level ($n = 12$)	
C3-4 & C4-5	2
C4-5 & C5-6	4
C5-6 & C6-7	6

Values are presented as mean \pm standard deviation or number.

Table 2. Radiological results and mean retraction time

Parameter	Value
Atherosclerotic carotid disease	
Yes, mild ^a	3 (5.8)
No	48 (94.2)
Mean retraction time (min)	
Single level ($n = 39$)	159 ± 24.3
Two level ($n = 12$)	220 ± 33.4
Cerebral thromboembolic event on DW-MRI	
Positive	1 (1.96)
Negative	50 (98.4)

Values are presented as number (%) or mean \pm standard deviation. DW-MRI, diffusion-weighted magnetic resonance imaging.

^aBy convention mild atherosclerotic carotid disease represents <39% stenosis, moderate <59% stenosis, severe <79% stenosis, and critical >80% stenosis.

tension or hypertension, intraoperative hypoxia, or severe anemia. Radiological results and mean retraction time are summarized in Table 2.

Postoperative cerebral MRI, obtained within 48 hours after

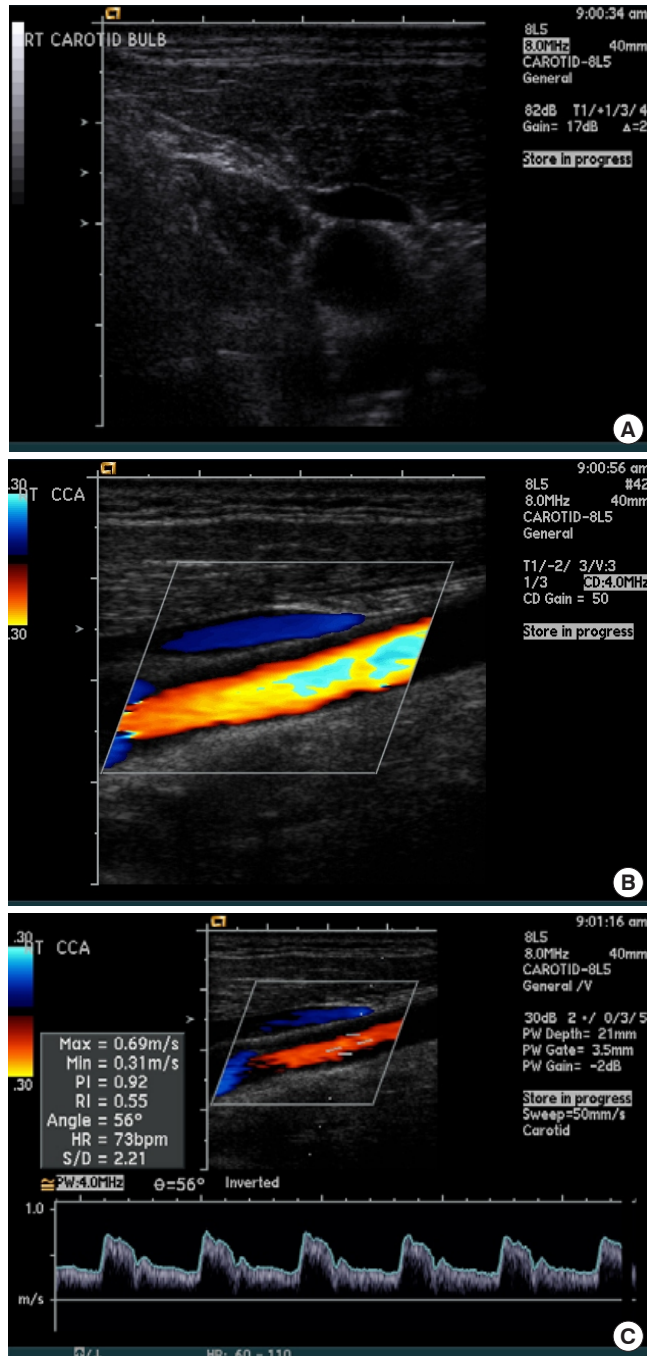


Fig. 1. Preoperative duplex ultrasound measurements of the right carotid artery in a patient who developed an asymptomatic cerebral thromboembolic event after surgery. No atherosclerotic carotid artery disease, including mural plaque was present. (A) Axial. (B) Longitudinal. (C) Velocity.

operation, was positive for a highsignal intensity lesion on DW-MRI, in 1 patient, and this was interpreted as an acute cerebral thromboembolic event. This 64-year-old man had a preoperative diagnosis of a degenerative herniated intervertebral disc at C4–5. He underwent ACDF using a zero-profile anchored spacer with allograft bone chips. His past medical history was not significant for any underlying disease and his only medications were narcotics for management of his cervical disc disease. As is shown in Fig. 1, no atherosclerotic carotid artery disease, including mural plaque, was detected on preoperative duplex ultrasound. His operative course was uneventful, without episodes of adverse events such as intraoperative hypotension or hypertension, and his total retraction duration was 140 minutes. Postoperatively he was stable, and taken to the recovery area without any noted neurological deficits. On postoperative day 2, cerebral MRI was obtained. On DW-MRI, a high signal-intensity lesion, considered to be an acute thromboembolic event, was noted in the right posterior cerebral artery territory (Fig. 2). A full neurological examination including assessment of visual field was performed and found to be within normal limits. As the patient did not display any neurological deficits, he was discharged home in the general course. At 2 years outpatient follow-up after ACDF, the preoperative severe radiating pain and right upper extremity was relieved and the patient was without

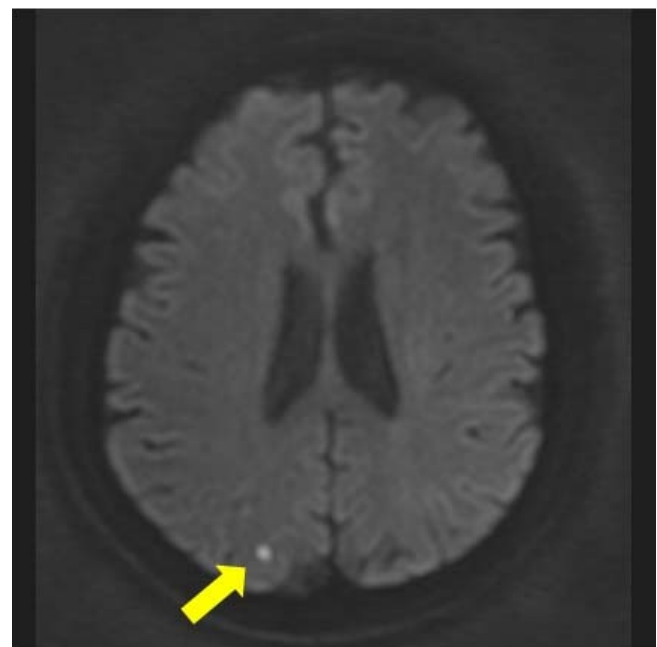


Fig. 2. Diffusion-weighted magnetic resonance imaging revealing a high-signal-intensity lesion in the right posterior cerebral artery territory (arrow).

any neurological deficits related to the identified cerebral thromboembolic event.

DISCUSSION

Both spinal neurosurgeons and orthopedic surgeons commonly perform ACDF with a high rate of clinical success. Adverse events are overall infrequent and manageable. The most common and potentially serious acute adverse events include dysphagia, dysphonia, bone graft failure, and airway compromise.¹⁰ Historically, thromboembolic events in the literature are typically reported for venous thromboembolism (pulmonary thromboembolism and deep vein thrombosis), especially in lumbar surgery.¹¹⁻¹⁴ Recently, Oglesby et al.¹⁵ analyzed data from the Nationwide Inpatient Sample database, demonstrating a 0.37% incidence of venous thromboembolic events in ACDF. Romano et al.³ studied postoperative in-hospital complication rates for elective ACDF, using discharge abstract data for all patients who underwent this procedure in California. They found that 6.7% of patients (n = 10,416) were reported to have one or more postoperative complications and cerebrovascular events occurred in 14 patients (0.13%). It is well accepted that intraoperative retraction during ACDF alters common carotid artery flow dynamics by causing a significant reduction in vessel cross-sectional area. Through duplex ultrasound measurements of the common carotid artery flow velocity, Pollard and Little² reported that vessel cross-sectional area decreased by an average of 14% with the initial placement of self-retaining retractors, and decreased further to 70% of baseline by the end of an ACDF case. However, only a few papers have reported cerebral thromboembolic events related to anterior cervical surgery and most of them are case reports describing to symptomatic events. Chozick et al.⁴ reported postoperative right hemispheric infarct in patients who underwent anterior corpectomies of the C4 and C5 vertebrae for cervical myelopathy resulting from ossification of the posterior longitudinal ligament. They suggested that the thrombosis may have been due to prolonged retraction on an atherosclerotic common carotid artery, and that an atherosclerotic common carotid artery might be more prone to thrombosis than a normal common carotid artery. Interestingly, Yeh et al.⁵ reported a postoperative left hemispheric lethal infarct after a lengthy 5-hour anterior cervical spine surgery in a patient without atherosclerotic disease of the common carotid artery.

In the present study, the mean retraction time was 159 ± 24.3 minutes (n = 39) for single-level ACDF and 220 ± 33.4 minutes (n = 12) for 2-level ACDF. A total of three patients underwent

retraction greater than 4 hours, and one patient was retracted for 5 hours. One patient experienced a silent cerebral thromboembolic event as determined by DW-MRI, and he had a relatively short retraction time (140 minutes). Further, there was no evidence of preoperative atherosclerotic carotid artery disease, including mural plaque as assessed with duplex ultrasound measurements.

Cerebral endovascular procedures, which also manipulate the common carotid artery like ACDF, have an incidence of clinically silent thromboembolic events as demonstrated by DW-MRI as high as 60 to 80%.⁶⁻⁹ This discrepancy between the high incidence with cerebral endovascular procedures and the low incidence of 1.96% of silent thromboembolic events in the present study may be due to the direct manipulation of endothelial wall in cerebrovascular endovascular procedure as opposed to indirect manipulation of the endothelial wall in ACDF.

Major limitations of this study are first, sample size is small and a larger scaled study is needed. Second, the incidence of silent cerebral infarction on DW-MRI in the general elderly population increases with age. Thromboembolic event located on the PCA territory in our study, despite the anterior circulation disturbance, can be an incidental finding or due to other origins including cardiovascular system.

CONCLUSION

This retrospective case series study revealed that cerebral thromboembolic event during ACDF is very rare, despite direct manipulation and compression of the common carotid artery during the surgery which causes alteration of common carotid artery flow dynamics.

CONFLICT OF INTEREST

The authors have nothing to disclose.

ACKNOWLEDGMENTS

This study was supported by a grant from the Wooridul Spine Foundation.

REFERENCES

1. Robinson RA, Smith G. Anterior cervical disk removal and interbody fusion for cervical disk syndrome. *Bull Johns Hopkins Hos* 1955;96:223-4.

2. Pollard ME, Little PW. Changes in carotid artery blood flow during anterior cervical spine surgery. *Spine (Phila Pa 1976)* 2002;27:152-5.
3. Romano PS, Campa DR, Rainwater JA. Elective cervical discectomy in California: postoperative in-hospital complications and their risk factors. *Spine (Phila Pa 1976)* 1997;22:2677-92.
4. Chozick BS, Watson P, Greenblatt SH. Internal carotid artery thrombosis after cervical corpectomy. *Spine (Phila Pa 1976)* 1994;19:2230-2.
5. Yeh YC, Sun WZ, Lin CP, et al. Prolonged retraction on the normal common carotid artery induced lethal stroke after cervical spine surgery. *Spine (Phila Pa 1976)* 2004;29:E431-4.
6. Kim JS, Byun HS, Kim KJ, et al. Coil embolization of intracranial aneurysms: the effectiveness and limitation. *J Korean Neurosurg Soc* 1998;27:749-56.
7. Murayama Y, Nien YL, Duckwiler G, et al. Guglielmi detachable coil embolization of cerebral aneurysms: 11 years' experience. *J Neurosurg* 2003;98:959-66.
8. Raymond J, Roy D. Safety and efficacy of endovascular treatment of acutely ruptured aneurysms. *Neurosurgery* 1997;41:1235-45.
9. Viñuela F, Duckwiler G, Mawad M. Guglielmi detachable coil embolization of acute intracranial aneurysm: perioperative anatomical and clinical outcome in 403 patients. *J Neurosurg* 1997;86:475-82.
10. Daniels AH, Riew KD, Yoo JU, et al. Adverse events associated with anterior cervical spine surgery. *J Am Acad Orthop Surg* 2008;16:729-38.
11. Cunningham JE, Swamy G, Thomas KC. Does preoperative DVT chemoprophylaxis in spinal surgery affect the incidence of thromboembolic complications and spinal epidural hematomas? *J Spinal Disord Tech* 2011;24:E31-4.
12. Gephart MG, Zygourakis CC, Arrigo RT, et al. Venous thromboembolism after thoracic/thoracolumbar spinal fusion. *World Neurosurg* 2012;78:545-52.
13. Oda T, Fuji T, Kato Y, et al. Deep venous thrombosis after posterior spinal surgery. *Spine (Phila Pa 1976)* 2000;25:2962-7.
14. Papadimitriou K, Amin AG, Kretzer RM, et al. Thromboembolic events and spinal surgery. *J Clin Neurosci* 2012;19:1617-21.
15. Oglesby M, Fineberg SJ, Patel AA, et al. The incidence and mortality of thromboembolic events in cervical spine surgery. *Spine (Phila Pa 1976)* 2013;38:E521-7.