

Case Report

Intravenous Thrombolysis of Occlusion in the Middle Cerebral and Retinal Arteries from Presumed Ventricular Myxoma

Cheung-Ter Ong^{1,2} and Rei-Yeuh Chang³

¹Department of Neurology, Chia-Yi Christian Hospital, 539 Chung-Shao Road, Chia-Yi 60002, Taiwan

²Department of Physical Therapy, Shu Zen College of Medicine and Management, Kaohsiung, Taiwan

³Department of Cardiology, Chia-Yi Christian Hospital, 539 Chung-Shao Road, Chia-Yi 60002, Taiwan

Correspondence should be addressed to Cheung-Ter Ong, ctong98@yahoo.com.tw

Received 30 July 2010; Accepted 8 November 2010

Academic Editor: Halvor Naess

Copyright © 2011 C.-T. Ong and R.-Y. Chang. This is an open access article distributed under the Creative Commons Attribution License, which permits unrestricted use, distribution, and reproduction in any medium, provided the original work is properly cited.

Background. Although thrombolytic therapy has been shown to be beneficial to stroke patients, the effectiveness of intravenous thrombolysis in ischemic stroke patients with ventricle myxoma is unknown. *Case Description.* A 22-year-old woman with left hemiplegia was sent to the emergency department at a teaching hospital. The magnetic resonance angiography showed occlusion of the right middle cerebral artery, and the echocardiography showed a mass in the left ventricle. Intravenous recombinant tissue plasminogen activator (rt-PA) was administered, and the postthrombolysis transcranial Doppler exam showed that her right middle cerebral artery was circulative. The patient's condition improved gradually, and no complication was observed up to 16 months of follow-up. *Conclusion.* Intravenous rt-PA is a reasonable treatment for stroke patients with ventricle myxoma.

1. Introduction

Myxoma represents 50% of primary cardiac tumors. Embolic stroke is the most common neurological manifestation of cardiac myxoma [1, 2], but the role of thrombolytic therapy in the treatment of stroke patients with cardiac myxoma is unknown. Considering that thrombolytic therapy has a 3-hour time-window only, physicians seldom performed a complete cardiac evaluation when applying the thrombolytic therapy to stroke patients. We hereby report a patient with left ventricle myxoma who received an intravenous recombinant tissue plasminogen activator (rt-PA) treatment and showed gradual symptom improvement without complications up to 16 months of followup.

2. Case Report

The patient was a 22-year-old, 53 Kg, right-handed woman with a history of exertional dyspnea who had suffered from three episodes of syncope. There was no family history of stroke. She had no history of headache, smoking, or drinking

and no history of taking birth control pills. She suddenly developed left-side limbs weakness and was brought to the emergency department at a teaching hospital within one hour of stroke onset. At the emergency department, her blood pressure was 104/68 mmHg, and she had a regular heart rate of 72 with normal heart sounds. She was conscious and well oriented. Her eyes were deviated to the right side, and her right eye vision was lost. She had a severe left-side hemiparesis and a left central type facial palsy. Her National Institutes of Health-Stroke-Scale (NIHSS) score was 12, and her modified rankin score (mRS) was 4. Results of her hematologic and biochemistry tests were normal, and her chest roentgenogram revealed a normal heart size. The brain computerized tomography (CT) showed no abnormal density, and the electrocardiogram (ECG) revealed sinus rhythm. There was no carotid bruit. Intravenous administration of rt-PA (0.9 mg/Kg) was given between 125 to 185 min after the stroke onset.

On the next day, her blood sugar, cholesterol, triglyceride, protein C, protein S, antithrombin, antinuclear antibody, anticardiolipin, and homocystein values were normal.

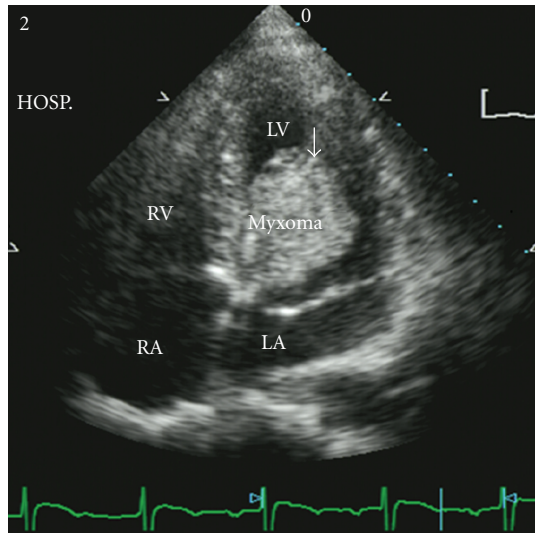


FIGURE 1: Transthoracic echocardiogram from apical 4-chamber view showed one myxoma (arrow) in the left ventricle with diameter 3×4 cm and stalk on middle interventricular septum.

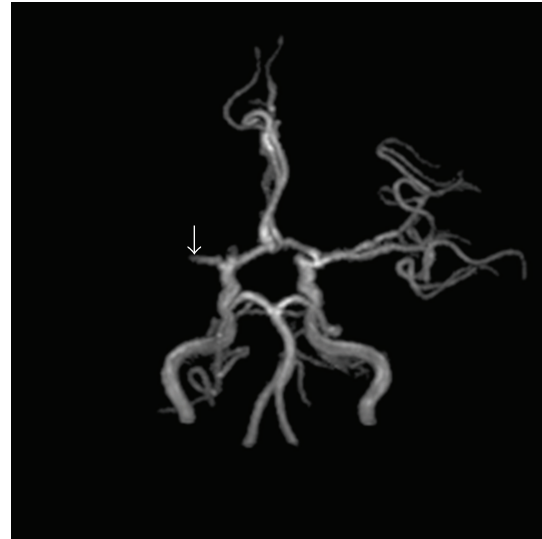

FIGURE 3: MRA shows right proximal middle cerebral artery (MCA) occlusion (arrow).

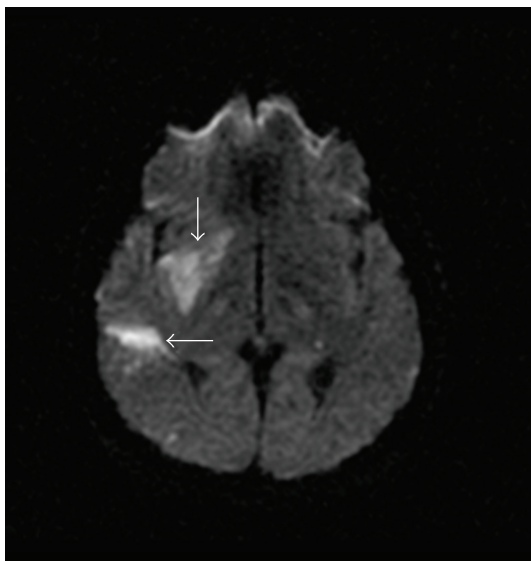


FIGURE 2: MRI of brain shows infarct in right putamen and temporal lobe (arrows).

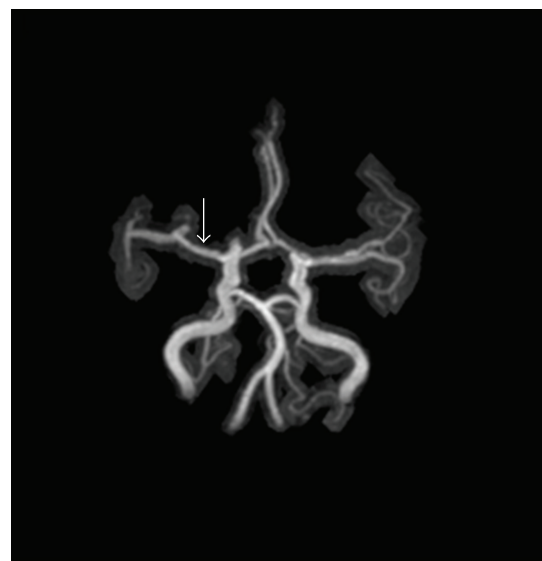

FIGURE 4: Sixteen months after thrombolytic therapy, MRA shows right middle cerebral artery recanalization (arrow).

A neurological examination showed a mild improvement, with NIHSS of 11 and mRS of 4, but no change in muscle power or facial palsy. Her transthoracic echocardiogram revealed a large (3×4 cm) homogenous mass with a stalk attached to the left interventricular septum (Figure 1), but her carotid duplex ultrasonography was normal. A transcranial Doppler (TCD) exam showed a decrease in blood flow in the right middle cerebral artery. From T2 and diffusion-weighted magnetic resonance image (MRI), infarcts in right basal ganglion and temporal lobe were observed (Figure 2).

Magnetic resonance angiography (MRA) showed occlusion of the right middle cerebral artery in the proximal section (Figure 3). No adverse effects following the thrombolytic therapy were observed.

The patient received a tumor resection, and the pathological examination confirmed the diagnosis of left ventricle myxoma. The postoperation clinical course was uneventful without further syncope episodes. Her neurological symptoms improved gradually, but her visual acuity had no improvement. Ten months after the thrombolytic therapy,

her NIHSS was 5 and mRS was 2. Sixteen months after the therapy, the MRA showed right middle cerebral artery recanalization (Figure 4).

3. Discussion

Approximately 75% of cardiac myxomas are located in the left atrium, and only 2.5% of them occur in the left ventricle [3, 4]. Clinical manifestations of cardiac myxoma include constitutional, obstructive, and embolic symptoms. Constitutional symptoms (recurrent fever, malagia, and weight loss) occur in 34 to 90% of patients, and obstructive symptoms (fatigue, weakness, dyspnea, and syncope) occur in 54 to 95% of patients. Embolic symptoms were reported in 10 to 45% of cases [2]. Neurological symptoms present in 12 to 45% of patients, and embolic cerebral infarct is the most common event [1, 5].

Thrombolysis with intravenous rt-PA treatment within three hours of ischemic stroke is now widely applied because it has been found to be beneficial to patient's outcome. In this patient, acute occlusions of the right middle cerebral artery and retinal artery were likely to be caused by embolism from the left ventricle myxoma. This patient had received a complete dose of rt-PA before her myxoma was diagnosed by transthoracic echocardiography. After the thrombolytic therapy, the patient's neurological symptoms improved. Although MRA did not show recanalization of the right middle cerebral artery, TCD showed that the right middle cerebral artery was circulative. Approximately 41% of cardiac myxomas have surface emboli, and systemic embolization related to myxoma surface thrombus is most likely [5]. Because cases of embolic stroke following thrombolytic therapy of myocardial infarction were reported [6], cardiac myxoma was once considered as a contraindication for thrombolytic therapy, but such an argument has not been well established [7].

Successful thrombolytic therapy with rt-PA in acute ischemic stroke patients with cardiac thrombus has been reported [8, 9], and intra-arterial thrombolysis of cerebral artery occlusion with urokinase has been demonstrated to be capable of causing partial recanalization [10]. However, a previous report showed that thrombolytic therapy in patients with ventricular thrombus may cause embolic stroke [6]. The response to intravenous thrombolysis by myxomatous embolic stroke patients is unpredictable.

Using "ventricular myxoma," "thrombolytic therapy," "stroke," and "cerebrovascular disease" as key words, we did not find any reports on similar cases in the PubMed databases. Intravenous thrombolytic therapy in acute ischemic stroke patients, caused by left atrial myxoma, had been reported to be an effective treatment [11]. However, thrombolytic therapy in patients caused by ventricular myxoma has not been reported. Therefore, the case described in this paper is probably the first reported evidence of a successful thrombolytic therapy in a stroke patient with presumed left ventricular myxomatous embolism. Based on this case, thrombolytic therapy with IV rt-PA is reasonable for ischemic stroke patients with ventricular myxoma.

References

- [1] L. E. Knepper, J. Biller, H. P. Adams Jr., and A. Bruno, "Neurologic manifestations of atrial myxoma. A 12-year experience and review," *Stroke*, vol. 19, no. 11, pp. 1435–1440, 1988.
- [2] F. O'Rourke, N. Dean, M. S. Mouradian, N. Akhtar, and A. Shuaib, "Atrial myxoma as a cause of stroke: case report and discussion," *Canadian Medical Association Journal*, vol. 169, no. 10, pp. 1049–1051, 2003.
- [3] M. F. Bauer, H. Aebert, H. Zurbrugg, J. Ruschoff, and D. E. Birnbaum, "Torsades de pointes arrhythmia in a patient with left ventricular myxoma," *Chest*, vol. 105, no. 6, pp. 1876–1878, 1994.
- [4] W. K. Nasser, "Atrial myxoma," *Chest*, vol. 60, no. 3, pp. 207–209, 1971.
- [5] V. H. Lee, H. M. Connolly, and R. D. Brown Jr., "Central nervous system manifestations of cardiac myxoma," *Archives of Neurology*, vol. 64, no. 8, pp. 1115–1120, 2007.
- [6] R. E. D. Bautista, "Embolic stroke following thrombolytic therapy for myocardial infarction in a patient with preexisting ventricular thrombi," *Stroke*, vol. 26, no. 2, pp. 324–325, 1995.
- [7] V. M. Abascal, J. Kasznica, G. Aldea, and R. Davidoff, "Left atrial myxoma and acute myocardial infarction: a dangerous duo in the thrombolytic agent era," *Chest*, vol. 109, no. 4, pp. 1106–1108, 1996.
- [8] L. Derex, N. Nighoghossian, M. Perinetti, J. Honnorat, and P. Trouillas, "Thrombolytic therapy in acute ischemic stroke patients with cardiac thrombus," *Neurology*, vol. 57, no. 11, pp. 2122–2125, 2001.
- [9] C. C. Trabuco, P. A. Pereira de Jesus, A. S. Bacellar, and J. Oliveira-Filho, "Successful thrombolysis in cardioembolic stroke from Chagas disease," *Neurology*, vol. 64, no. 1, pp. 170–171, 2005.
- [10] I. Bekavac, J. P. Hanna, R. C. Wallace, J. Powers, N. B. Ratliff, and A. J. Furlan, "Intra-arterial thrombolysis of embolic proximal middle cerebral artery occlusion from presumed atrial myxoma," *Neurology*, vol. 49, no. 2, pp. 618–620, 1997.
- [11] C. D. Nagy, M. Levy, T. J. Mulhearn 4th et al., "Safe and effective intravenous thrombolysis for acute ischemic stroke caused by left atrial myxoma," *Journal of Stroke and Cerebrovascular Diseases*, vol. 18, no. 5, pp. 398–402, 2009.