

Teaching Case

Radiation Myelopathy of the Cervical Spine in the Setting of Neuromyelitis Optica Spectrum Disorder After Low-Dose Radiation Therapy for Non-Hodgkin Lymphoma of the Cervical Lymph Nodes



Antony Koroulakis, MD,^a Michael Sullivan, BS,^b and James W. Snider, MD^{a,*}

^aDepartment of Radiation Oncology, University of Maryland Medical Center, Baltimore, Maryland; and ^bUniversity of Maryland School of Medicine, Baltimore, Maryland

Received 5 November 2019; revised 11 December 2019; accepted 6 January 2020

Introduction

The spinal cord, as a late-responding tissue, is a relatively radiosensitive structure. Radiation myelopathy (RM) is a very rare but potentially catastrophic complication. RM is defined as damage of the white matter of the spinal cord after exposure to ionizing radiation. Glial and vascular damage from radiation likely both contribute to this pathophysiology.^{1,2} It is often a diagnosis of exclusion based on a history of prior radiation of sufficient dose to cause cord injury, the region of irradiated cord being superior to the region of symptoms, presence of a latency period from completion of treatment, and a lack of explanatory disease progression.³ Its irreversible form often presents around 6 months posttreatment.⁴ Characteristic magnetic resonance imaging (MRI) findings include T2 hyperintensity, contrast enhancement, and sometimes cord edema.⁵ There is no well-established

treatment for RM, although trial of steroids is reasonable. Supportive care is indicated.

As a deterministic radiation effect, the risk and severity of RM is affected by radiation dose, with probability of RM estimated at <1%, 5%, and 50% at doses of 50, 60, and 70 Gy, respectively.⁶ Owing to low α/β of approximately 0.87, larger fraction sizes also increase risk of RM.⁷ Given the serial arrangement of the functional subunits of the spinal cord, high point doses are sufficient to cause RM. Furthermore, the lethality of RM increases with more proximal lesions, up to 70% mortality from cervical lesions and 30% with thoracic lesions.⁸ Prior existing conditions or prior therapies can contribute to the risk of RM. History of prior central nervous system (CNS) disease or injury, in addition to comorbidities such as hypertension, hypotension, diabetes, or vascular disease, can increase susceptibility to RM.⁹ In cases of prior radiation, the prior total dose, cumulative dose of all courses, and the time interval between courses all have critical implications as well.^{10,11} Rare reports have also indicated that the dose threshold for RM in patients receiving prior chemotherapy or immunotherapy may be lowered.¹²⁻¹⁵

Multiple reports have indicated increased risk of neurotoxicity in patients with a history of multiple sclerosis (MS) receiving CNS-directed radiation therapy

Sources of support: none.

Research data are stored in an institutional repository and will be shared upon request to the corresponding author.

Disclosures: J.W. Snider reports personal fees from Varian Medical Systems, personal fees from Siemens Healthineers, both outside the submitted work, and a patent-pending Proton GRID technique.

* Corresponding author: James W. Snider MD; E-mail: jsnider@umm.edu.

<https://doi.org/10.1016/j.adro.2020.01.001>

2452-1094/© 2020 The Authors. Published by Elsevier Inc. on behalf of American Society for Radiation Oncology. This is an open access article under the CC BY-NC-ND license (<http://creativecommons.org/licenses/by-nc-nd/4.0/>).

(RT), with autoimmune demyelination thought to reduce the threshold for said toxicity.^{16–18} Neuromyelitis Optica Spectrum Disorder (NMOSD), similarly to MS, is also an inflammatory condition affecting the CNS, but in contrast to MS, this disease preferentially affects the spinal cord, optic tracts, brainstem, and area postrema.¹⁹ It is also antibody mediated, rather than cell mediated in the case of MS.²⁰ To date, there are no reports, to our knowledge, relating risk of neurotoxicity in patients with NMOSD receiving radiation therapy to the spinal cord. We present an unusual case of RM in a patient with NMOSD receiving low-dose RT to the head and neck region.

Case Report

A 72-year-old black woman with history of hypertension received a diagnosis of stage II marginal zone non-Hodgkin lymphoma, with staging positron emission tomography (PET)/computed tomography (CT) imaging demonstrating increased uptake in the right posterior nasopharynx, bilateral superior posterior triangle nodes, and bilateral level II nodes. She received intensity modulated radiation therapy to the head and neck region, totaling 30.6 Gy in 1.8 Gy fractions. Of note, the maximum point dose to the spinal cord was 29.05 Gy. Representative images of the RT plan are shown in Figure 1. This treatment course was tolerated well without interruption. No systemic therapy was administered.

She continued to do well with no evidence of disease recurrence. Approximately 7 years after treatment, she developed neck pain and bilateral upper and lower extremity numbness and weakness, most pronounced in the right upper extremity. The onset was gradual, throughout 3 to 4 weeks, and symptoms progressively worsened to the point of difficulty with walking. She was admitted to the hospital. MRI of the brain and spinal cord demonstrated T2 hyperintensities in the caudal medulla, extending through the cervical spine to the level of C7 (Fig. 2A and 2B). Patchy areas of abnormal contrast enhancement were also noted in the same region. PET revealed no hypermetabolic lesions, including in the spinal canal. Lumbar puncture with cytology and flow cytometry was unrevealing, and CNS recurrence of marginal zone non-Hodgkin lymphoma was sufficiently ruled out. Of note, NMO antibodies were not checked. Radiation oncology was consulted regarding the possibility of radiation myelopathy. The clinical details of the case were thoroughly reviewed by the radiation oncologists, and the details of RT delivery and planning were also confirmed by medical physics to exclude a technical event. It was deemed unlikely given the low prior dose to the spinal cord, despite the lesions lying within the 50% to 95% isodose lines of the prior RT plan. High-dose intravenous steroids were initiated (dexamethasone IV 32 mg loading dose, 8 mg every 6 hours thereafter), which were then tapered. Both strength and sensation improved in all extremities, with strength noted to be 4 or 5 in all extremities at time of discharge from the hospital to

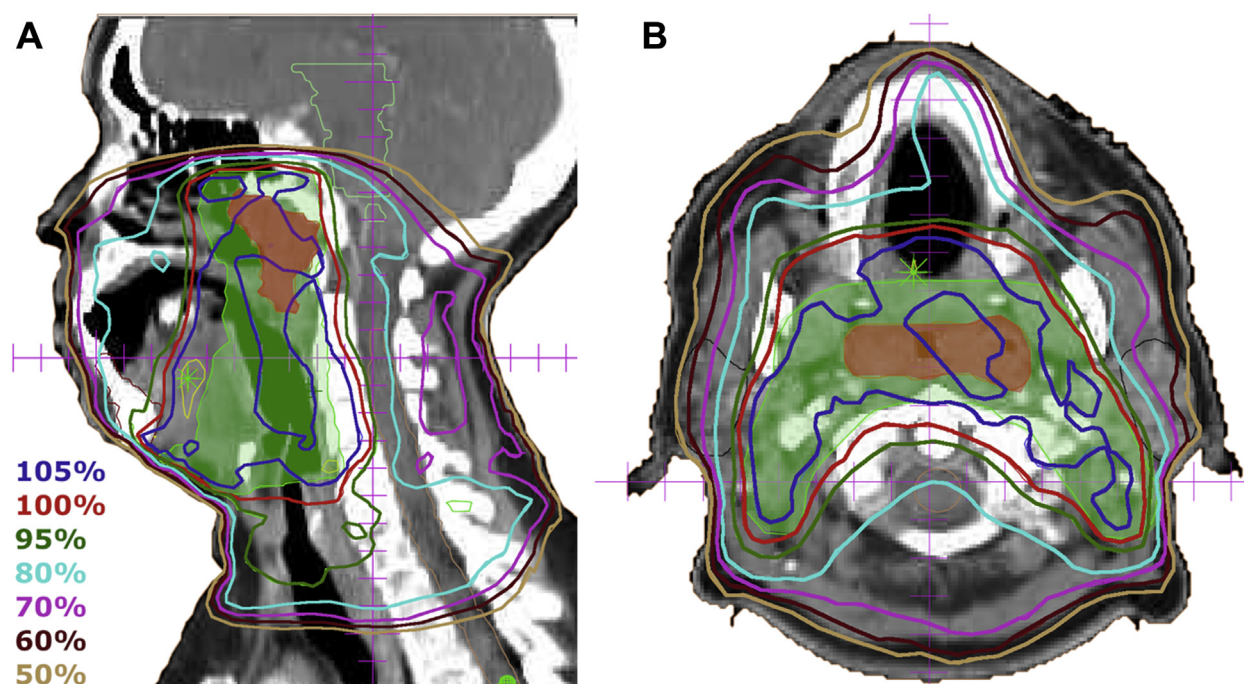


Figure 1 (A) Radiation therapy plan isodose lines; prescription dose of 30.6 Gy in 1.8 Gy fractions, with maximum point dose to the spinal cord of 29.05 Gy in sagittal (A) and axial (B) views. The gross tumor volume and planning target volume are shaded in red and green, respectively.

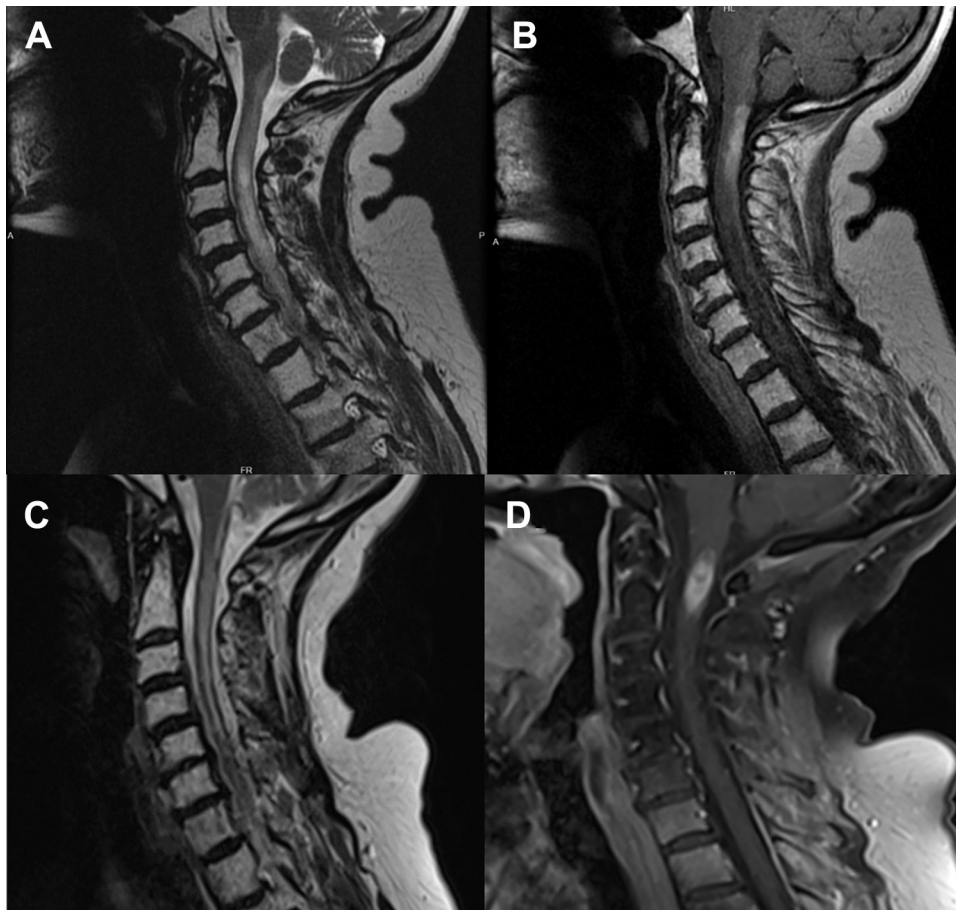


Figure 2 Magnetic resonance imaging upon initial presentation (T2 [A] and T1 postcontrast [B] images) and at relapse of neurologic symptoms (T2 [C] and T1 postcontrast [D] images), demonstrating abnormal signal and enhancement in the cervical spinal cord.

rehabilitation. Steroids had been tapered off by 10 days from initial presentation.

She spent 1 month in rehabilitation, regaining ability to walk without difficulty and with a full symptomatic recovery noted at clinical follow-up around 4 months from initial presentation. A follow-up MRI of the brain and spine at that time demonstrated significant improvement of T2 hyperintensities in the cervical cord, with residual increased signal extending from the cervical medullary junction to the level of C7. Additionally, there was noted to be less swelling and edema of the spinal cord, and no enhancement was noted.

Approximately 8 months from initial neurologic presentation, the patient had recurrence of symptoms. She was again admitted for evaluation, and MRI of the brain and spine again demonstrated abnormal signal and enhancement in the cervical spine (Fig. 2C and 2D). Repeat PET demonstrated no evidence of hypermetabolic lesions. However, at this time, NMO immunoglobulin G (IgG) antibodies were checked and detected in the serum, thus establishing diagnosis of NMOSD. The case was again reviewed by radiation oncology and during interdisciplinary tumor board.

Despite diagnosis of NMOSD, a component of RM could not be excluded.

Intravenous steroids were started and tapered. She subsequently received plasmapheresis treatments and rituximab maintenance therapy for NMOSD resulting in stabilization of symptoms. As of the present time, approximately 28 months from initial presentation, she continues to have stable symptoms with bilateral upper extremity weakness (4 out of 5).

Discussion

As previously mentioned, RM is a diagnosis of exclusion. In this case, the clinical neurologic symptoms, their delayed onset, strong imaging correlation to the region of prior RT, and the exclusion of disease recurrence all point to RM as the proximate cause. Especially, the MRI abnormality's presence entirely within the prior RT field is hard to ignore. The maximum dose to the spinal cord is the clear detractor from a typical presentation of RM. One would extrapolate from radiobiologic and data from the quantitative analyses of normal tissue effects in

the clinic that the risk of myelopathy in this case would otherwise be near zero. Also, the diagnosis of NMOSD does not preclude external beam radiotherapy (EBRT) as a contributing factor, especially considering the remaining data which strongly implicate EBRT. Rather, NMOSD may have provided an explanation for a lowered threshold dose for RM in this case.

NMOSD: Pathophysiology, diagnosis, and treatment

NMOSD is a demyelinating disorder mediated by AQP4-IgG, an autoantibody targeting aquaporin 4 (AQP4). This results in an immune astrocytopathy that also affects blood vessels.¹⁹ Specifically, aquaporin peptides circulate and present as antigens to T cells. This results in B cell activation, differentiation into plasmablasts, and secretion of AQP4-IgG. AQP4-IgG then circulates in the blood, penetrates the blood-brain barrier, attacks AQP4 proteins, and finally initiates a complement-mediated inflammatory reaction. These proteins are expressed on astrocyte endfeet that abut both vasculature and the pia mater. It is this effect both on the glial support and vasculature of the CNS that results in both lytic and nonlytic lesions causing symptoms, particularly in the spinal cord and optic pathways.

This disease much more commonly affects females and nonwhite populations in developed countries. Diagnosis of NMOSD entails a positive test for this antibody, at least one core clinical characteristic, and exclusion of other processes. Nearly 90% of patients have a relapsing disease course. Therapy focuses both on prevention and treatment of flares. First-line agents include azathioprine, mycophenolate mofetil, prednisone, and rituximab.²¹

Existing evidence on the interaction between EBRT and multiple sclerosis

Although there is no literature describing interaction with NMOSD and EBRT, there are perhaps certain important concepts that may be extrapolated from existing literature on the interaction between MS and EBRT. Indeed, MS is another neurologic inflammatory disorder. Fundamental distinctions include the different mechanism of action (antibody vs cell-mediated) and the location of lesions from MS in the white matter of the brain.

The deleterious effect of EBRT on the CNS in the presence of MS had been first postulated in 1959, and multiple reports have since corroborated the hypothesis that EBRT can exacerbate demyelination in MS.¹⁸ An important experience from the Mayo Clinic, largely preceding the advent of 3-dimensional planning, reported grade 4 or greater neurotoxicity in 6 of 15 consecutive patients with MS treated with EBRT to the brain, with all instances consistent with demyelinating injury within the

irradiated volume rather than necrosis. These occurred from 0.2 to 17.6 years after EBRT. Of note, MS was diagnosed after EBRT in 3 of these patients.

Proposed mechanism of RM in the setting of NMOSD

The precise mechanism responsible for the clinical presentation herein discussed is a matter of speculation. One possible mechanism for this may be release of AQP4 peptide antigens due to radiation damage, which then induced the previously described antibody-mediated inflammatory pathway affecting supporting astrocytes and vasculature of the spinal cord. Because both glial and vascular damage are implicated in the pathogenesis of RM and NMOSD, it is possible that AQP4-IgG antibodies effectively lowered the threshold for RM.⁸ In this way, one may consider both radiation effect and autoimmune pathology to have acted synergistically, such that the threshold for RM was significantly lowered, resulting in this presentation.

Conclusions

RM is a rare complication, and almost never seen at doses as low as 30.6 Gy in standard fractionation. Auto-immune pathologies can greatly lower the threshold for serious neurotoxicity, as previously demonstrated in the context of MS and as we postulate in this first reporting in a patient with NMOSD.

References

1. Okada S, Okeda R. Pathology of radiation myelopathy. *Neuropathology*. 2001;21:247-265.
2. Coderre JA, Morris GM, Micca PL, et al. Late effects of radiation on the central nervous system: Role of vascular endothelial damage and glial stem cell survival. *Radiat Res*. 2006;166:495-503.
3. Gunderson L, Tepper J, eds. *Clinical Radiation Oncology*. 4th ed. Philadelphia, PA: Elsevier; 2016.
4. Schultheiss TE, Higgins EM, El-Mahdi AM. The latent period in clinical radiation myelopathy. *Int J Radiat Oncol Biol Phys*. 1984;10:1109-1115.
5. Wang PY, Shen WC, Jan JS, Schultheiss TE, Stephens LC. MR imaging in radiation myelopathy. *Am J Neuroradiol*. 1992;13:1056-1058.
6. Schultheiss TE. The radiation dose-response of the human spinal cord. *Int J Radiat Oncol Biol Phys*. 2008;71:1455-1459.
7. Kirkpatrick JP, van der Kogel AJ, Schultheiss TE. Radiation dose-volume effects in the spinal cord. *Int J Radiat Oncol Biol Phys*. 2010;76(3 Suppl):S42-S49.
8. Schultheiss TE, Stephens LC, Peters LJ. Survival in radiation myelopathy. *Int J Radiat Oncol Biol Phys*. 1986;12:1765-1769.
9. Schultheiss TE, Stephens LC. Invited review: Permanent radiation myelopathy. *Br J Radiol*. 1992;65:737-753.
10. Nieder C, Grosu AL, Andratschke NH, Molls M. Update of human spinal cord reirradiation tolerance based on additional data from 38 patients. *Int J Radiat Oncol Biol Phys*. 2006;66:1446-1449.

11. Nieder C, Grosu AL, Andratschke NH, Molls M. Spinal cord reirradiation tolerance. *Int J Radiat Oncol Biol Phys.* 2006;66:1446-1449.
12. Ruckdeschel JC, Baxter DH, Mckneally MF, et al. Sequential radiotherapy and adriamycin in the management of bronchogenic carcinoma: The question of additive toxicity. *Int J Radiat Oncol Biol Phys.* 1979;5:1323-1328.
13. Bloss JD, DiSaia PJ, Mannel RS, et al. Radiation myelitis: A complication of concurrent cisplatin and 5-fluorouracil chemotherapy with extended field radiotherapy for carcinoma of the uterine cervix. *Gynecol Oncol.* 1991;43:305-308.
14. Chao MWT, Wirth A, Ryan G, MacManus M, Liew KH. Radiation myelopathy following transplantation and radiotherapy for non-Hodgkin's lymphoma. *Int J Radiat Oncol Biol Phys.* 1998;41:1057-1061.
15. Seddon BM, Cassoni AM, Galloway MJ, Rees JH, Whelan JS. Fatal radiation myelopathy after high-dose Busulfan and Melphalan chemotherapy and radiotherapy for Ewing's sarcoma: A review of the literature and implications for practice. *Clin Oncol.* 2005;17:385-390.
16. Peterson K, Rosenblum MK, Powers JM, et al. Effect of brain irradiation on demyelinating lesions. *Neurology.* 1993;43:2105-2112.
17. Murphy CB, Hashimoto SA, Graeb D, Thiessen BA. Clinical exacerbation of multiple sclerosis following radiotherapy. *Arch Neurol.* 2003;60:273-275.
18. Miller RC, Lachance DH, Lucchinetti CF, et al. Multiple sclerosis, brain radiotherapy, and risk of neurotoxicity: The Mayo Clinic experience. *Int J Radiat Oncol Biol Phys.* 2006;66:1178-1186.
19. Weinshenker BG, Wingerchuk DM. Neuromyelitis spectrum disorders. *Mayo Clin Proc.* 2017;92:663-679.
20. Milo R. Therapeutic strategies targeting B-cells in multiple sclerosis. *Autoimmun Rev.* 2016;15:714-718.
21. Wingerchuk DM, Lennon VA, Lucchinetti CF, Pittock SJ, Weinshenker BG. The spectrum of neuromyelitis optica. *Lancet Neurol.* 2007;6:805-815.