

## Distinct Localization of Peripheral and Central Types of Choline Acetyltransferase in the Rat Cochlea

Tsuyoshi Kitanishi<sup>1,2</sup>, Yoshinari Aimi<sup>3</sup>, Hiroya Kitano<sup>4</sup>, Mikio Suzuki<sup>5</sup>, Hiroshi Kimura<sup>1</sup>, Atsushi Saito<sup>6</sup>, Takeshi Shimizu<sup>2</sup> and Ikuo Tooyama<sup>1</sup>

<sup>1</sup>Molecular Neuroscience Research Center, Shiga University of Medical Science, <sup>2</sup>Department of Otorhinolaryngology, Shiga University of Medical Science, <sup>3</sup>Department of Anatomy, Shiga University of Medical Science, Seta Tsukinowa-cho, Otsu 520–2192, Japan, <sup>4</sup>Department of Otorhinolaryngology, Head and Neck Surgery, Faculty of Medicine, Tottori University, Yonago, Tottori 683–8503, Japan, <sup>5</sup>Department of Otorhinolaryngology, Head and Neck Surgery, Graduate School of Medicine, University of the Ryukyus, Uehara, Nishihara-cho, Okinawa 903–0215, Japan and <sup>6</sup>Department of Otolaryngology-Head and Neck Surgery, Kyoto Prefectural University of Medicine, Kawaramachi-Hirokoji, Kyoto 602–8566, Japan

Received July 9, 2013; accepted September 10, 2013; published online October 23, 2013

We previously discovered a splice variant of choline acetyltransferase (ChAT) mRNA, and designated the variant protein pChAT because of its preferential expression in peripheral neuronal structures. In this study, we examined the immunohistochemical localization of pChAT in rat cochlea and compared the distribution pattern to those of common ChAT (cChAT) and acetylcholinesterase. Some neuronal cell bodies and fibers in the spiral ganglia showed immunoreactivity for pChAT, predominantly the small spiral ganglion cells, indicating outer hair cell type II neurons. In contrast, cChAT- and acetylcholinesterase-positive structures were localized to fibers and not apparent in ganglion cells. After ablation of the cochlear nuclei, many pChAT-positive cochlear nerve fibers became clearly visible, whereas fibers immunopositive for cChAT and acetylcholine esterase disappeared. These results suggested that pChAT and cChAT are localized in different systems of the rat cochlea; pChAT in the afferent and cChAT in the efferent structures.

**Key words:** acetylcholine, cholinergic neurons, choline acetyltransferase, cochlear nervous system, spiral ganglion

### I. Introduction

Acetylcholine (ACh) is traditionally thought of as the neurotransmitter of the cochlea efferent system, since the report of Schuknecht and colleagues in 1959 [2, 12, 25, 35, 38], and indeed, ACh localizes exclusively to the basal and middle regions of the cochlea [1, 15, 16]. On the other hand, little is known about the transmitter substances of the afferent system.

Choline acetyltransferase (ChAT) [17, 20, 31, 46] and acetylcholine esterase (AChE) [18, 26, 39, 40] have long

been used as markers of cholinergic innervation of the cochlea. In particular, immunohistochemistry for ChAT is considered the most reliable histochemical technique for visualizing cholinergic structures [4, 11, 13, 23, 24, 29]. However, while powerful in revealing central cholinergic structures, most of the available antibodies against ChAT often fail to show peripheral cholinergic nerves, indicating a possible difference between the molecular forms of ChAT expressed in the central and peripheral nervous systems.

We previously demonstrated a splice variant of ChAT mRNA, of which the product is expressed preferentially in the peripheral nervous system [45]. We named this variant product ChAT of a peripheral type (pChAT), while we proposed the term ChAT of a common type (cChAT) for conventional ChAT. Using a rabbit antiserum raised against pChAT, we provided immunohistochemical evidence of

Correspondence to: Ikuo Tooyama, Professor, Molecular Neuroscience Research Center, Shiga University of Medical Science, Seta Tsukinowa-cho, Otsu 520–2192, Japan.  
E-mail: kinchan@belle.shiga-med.ac.jp

the variant protein expression in most neurons of the rat pterygopalatine ganglion, which is composed mainly of cholinergic cells, while no pChAT-immunopositive neurons were apparent in the rat forebrain. These findings suggested that the variant ChAT protein is expressed exclusively in peripheral cholinergic cells.

Immunohistochemistry using pChAT antiserum has subsequently confirmed the presence of cholinergic systems in the peripheral nervous system [3, 6, 9, 10, 19, 27, 32–34, 37, 47–51]. Interestingly, the possible existence of pChAT-positive neurons was also reported in various sensory ganglia such as the trigeminal ganglia [27, 48, 49, 51], nodosa ganglia [33, 34], and dorsal root ganglia [3].

To evaluate the immunohistochemical distribution of pChAT-positive structures in the rat cochlea, we employed immunohistochemical methods using pChAT antiserum. We also compared the distribution patterns of cChAT and AChE with that of pChAT, as well as the relative immunolocalization of pChAT after surgical removal of the cochlear nucleus, in order to understand the trajectory of pChAT-positive fibers and neuronal cell bodies in the cochlea.

## II. Materials and Methods

### Animals

Adult male Wistar rats (Clea Japan Inc., Japan) weighing approximately 200 g were used in this study. Animals were kept in laboratory conditions under a 12-hr dark/light cycle. All procedures were carried out in accordance with the Public Health Service Policy on the Humane Care and Use of Laboratory Animals, the NIH Guide for the Care and Use of Laboratory Animals, and the Animal Welfare Act (7 U.S.C. 2131 *et seq.*). The Institutional Animal Care and Use Committee of the Shiga University of Medical Science approved all experimental protocols.

### Tissue preparations

Under pentobarbital anesthesia (80 mg/kg), the animals (n=10) were perfused via the ascending aorta with 10 mM ice-cold phosphate-buffered saline (pH 7.4) followed by a fixative containing 4% paraformaldehyde in 0.1 M phosphate buffer (pH 7.4). The rats were kept in crushed ice during the perfusion, after which the temporal bones including the inner ear and brains were excised and post-fixed in 4% paraformaldehyde for 48 hr at 4°C. The tissues were then incubated overnight in 10% sucrose in phosphate buffer, and then cut into 20- $\mu$ m sections on a cryostat. The temporal bone specimens were stored for approximately 3 weeks in 10% sodium ethylenediamine-tetraacetic acid solution for decalcification, and then immersed for 30 min in 0.1 M phosphate buffer (pH 7.4) containing 10% gelatin at 37°C and then at 4°C for 1 hr. After cryoprotection for 2 days by immersion in 0.1 M phosphate buffer (pH 7.4) containing 15% sucrose, the tissues were cut into 20- $\mu$ m sections on a cryostat, and collected into 0.1 M phosphate-

buffered saline (pH 7.4) containing 0.3% Triton X-100 (PBST).

### Characterization of antibodies

For immunohistochemical staining of cChAT, we used a goat polyclonal anti-cChAT antibody that reacts by immunoblotting to protein bands with an apparent molecular weight of 69 kDa [3, 47]. For pChAT staining, we used a pChAT rabbit antiserum that detects a single band of 55 kDa in rat tissues by immunoblotting [3, 45].

### pChAT immunohistochemistry in the inner ear

The tissue sections were incubated as free-floating sections for 3 days at 4°C with either rabbit antiserum raised against pChAT (diluted 1 : 20,000–40,000) or goat antiserum against ChAT (diluted 1 : 10,000; AB144p, Chemicon, Temecula, CA), diluted in PBST, which was also used for washing of the section between steps. The sections were then incubated for 2 hr with biotinylated anti-rabbit IgG (diluted 1 : 1,000; Vector Laboratories, Burlingame, CA), and then for 1 hr with avidin-biotinylated peroxidase complex (diluted 1 : 2,000–4,000; Vector Laboratories) at room temperature. Peroxidase activity in the sections was visualized by reaction with 0.02% 3,3'-diaminobenzidine tetrahydrochloride, 0.0045% hydrogen peroxide, and 0.3% nickel ammonium sulfate in 50 mM Tris-HCl buffer (pH 7.6). The stained sections were mounted on gelatin-coated glass slides and air-dried. The sections were finally washed in tap water, dehydrated in a graded series of ethanol, cleared in xylene, and coverslipped with Entellan (Merck, Darmstadt, Germany) for examination under a light microscope.

For immunohistochemical controls, the pChAT antiserum was replaced with the pre-immune serum or by pChAT antiserum that had been preincubated overnight with the antigenic peptide of pChAT [45] or rat recombinant pChAT [36]. No positive staining was observed in these control experiments (data not shown).

### Image analysis for pChAT in the spiral ganglion cells

We performed a semiquantitative morphometric analysis using the NIH image system to correlate the intensity of pChAT immunostaining with the size of pChAT-positive cells.

### AChE histochemistry

We carried out AChE histochemistry as described by Tago and colleagues [44]. After washing with 0.1 M malate buffer (pH 6.0), cochlear cryostat sections were incubated for 2 hr in 0.1 M malate buffer (pH 6.0) containing 18  $\mu$ M acetylthiocholine iodide, 5  $\mu$ M  $K_3Fe(CN)_6$ , 30  $\mu$ M  $CuSO_4$ , and 50  $\mu$ M sodium citrate at room temperature. After washing with 50 mM Tris-HCl buffer (pH 7.6), the sections were then reacted for 20 min with 50 mM Tris-HCl buffer (pH 7.6) containing 0.02% 3,3'-diaminobenzidine and 0.0045% hydrogen peroxide with 0.3% nickel ammonium sulfate.

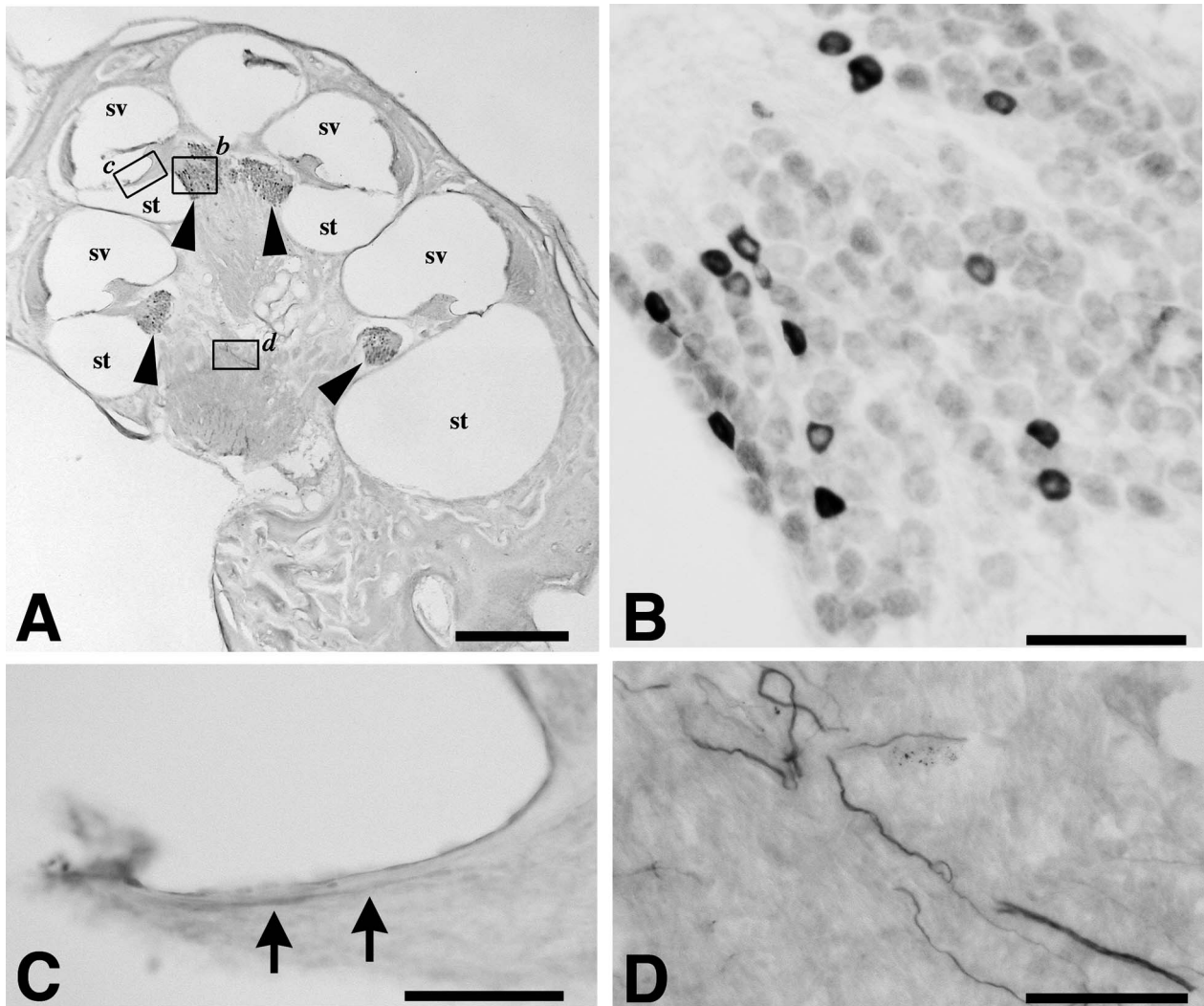
### Surgical removal of the cochlear nucleus

To investigate changes in the distribution of efferent and afferent nerve fibers after removal of the rat cochlear nucleus unilaterally, the rat skulls were opened with a drill to expose the cerebellum under deep anesthesia with pentobarbitone sodium (50 mg/kg). The paraflocculus was then exposed and removed by aspiration. The cochlear nucleus was also removed unilaterally by aspiration under direct vision. Immunohistochemical staining with anti-pChAT antibody was performed in the rat temporal bone, 3 days after the treatment. Ablation of the cochlear nucleus was confirmed by examination of cresyl violet-stained sections of the brainstem.

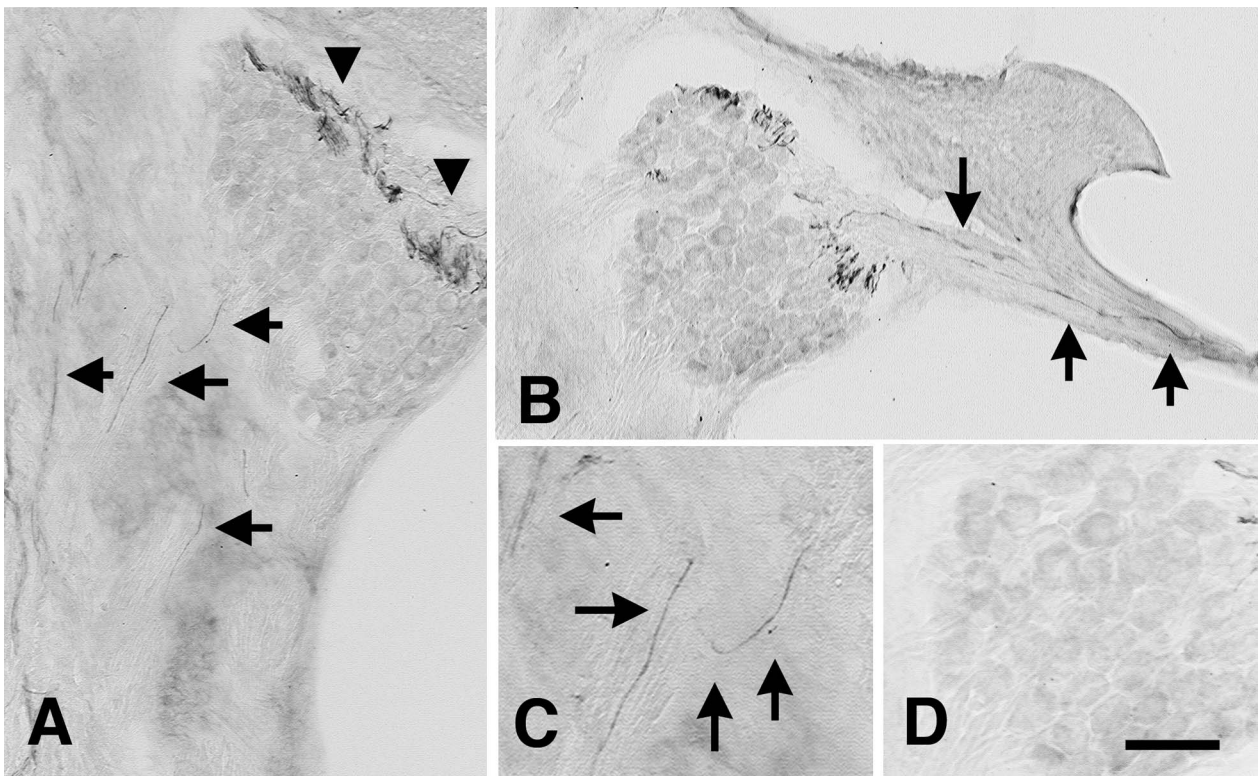
### III. Results

#### Immunohistochemical localization of pChAT and cChAT in the cochlea

Immunoreactivity for pChAT was localized to neuronal structures in specific areas of the rat cochlea (Fig. 1). In particular, some cells in the spiral ganglia were intensely stained for pChAT (arrows in Fig. 1A). Higher magnification views (Fig. 1B) revealed immunostaining for pChAT in densely packed cytoplasmic structures of mostly small spiral ganglion cells. The organ of Corti contained some nerve fibers weakly stained for pChAT (arrows in Fig. 1C), but hair cells were pChAT-immunonegative (Fig. 1C). Nerve fibers positive for pChAT, probably cochlear nerves, were also observed in the modiolus of the cochlea (Fig. 1D).



**Fig. 1.** Immunohistochemical localization of choline acetyltransferase of a peripheral type (pChAT)-positive structures in the rat cochlea. (A) Low power magnification of the rat cochlea. Arrowheads indicate spiral ganglia. sv, scala vestibule; st, scala tympani. (B) High power magnification of a spiral ganglion, showing intense staining of some smaller cells. (C) High power magnification of the organ of Corti. A nerve fiber weakly stained for pChAT extends to the outer cell layer (arrows). No pChAT-positive cells are seen. (D) High power magnification of pChAT-positive nerve fibers in the modiolus of the cochlea. Bars=500  $\mu$ m (A), 50  $\mu$ m (B-D).



**Fig. 2.** Immunohistochemical localization of choline acetyltransferase of a common type (cChAT)-positive structures in the rat cochlea. (A) In the modiolus, cChAT-positive fibers (arrows) are gathered near the spiral ganglion (arrowheads). (B) In the organ of Corti, cChAT-positive fibers are observed extending to the hair cells (arrows). (C) High power magnification of cChAT-positive fibers in the modiolus (arrows). (D) High power magnification of the spiral ganglion, showing no cChAT-positive cells. Bar=50  $\mu\text{m}$  (A, B), 25  $\mu\text{m}$  (C, D).

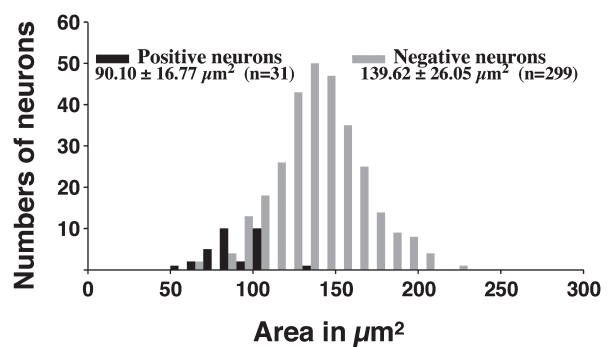
Figure 2 demonstrates cChAT-positive structures in the rat cochlea, wherein immunoreactivity for cChAT was detected only in some nerve fibers, such as in the modiolus (arrows in Fig. 2A, C). Interestingly, many cChAT-positive fibers were gathered near the spiral ganglion (arrowheads in Fig. 2A) and extended to hair cells in the organ of Corti (arrows in Fig. 2B). Cells in the spiral ganglion were negative for cChAT (Fig. 2D), and no positive staining was observed in the stria vascularis, inner spiral bundles, or tunnel spiral bundles.

#### **Morphometric analysis of pChAT-positive neurons in the spiral ganglion**

As mentioned above, pChAT immunoreactivity appeared to localize preferentially in small spiral ganglion cells. Morphometric analysis to confirm this visual impression showed pChAT immunoreactivity in 9.4% of the total number of spiral ganglion cells. As shown in Figure 3, pChAT-positive cells also corresponded to smaller neurons.

#### **Comparison with AChE histochemistry**

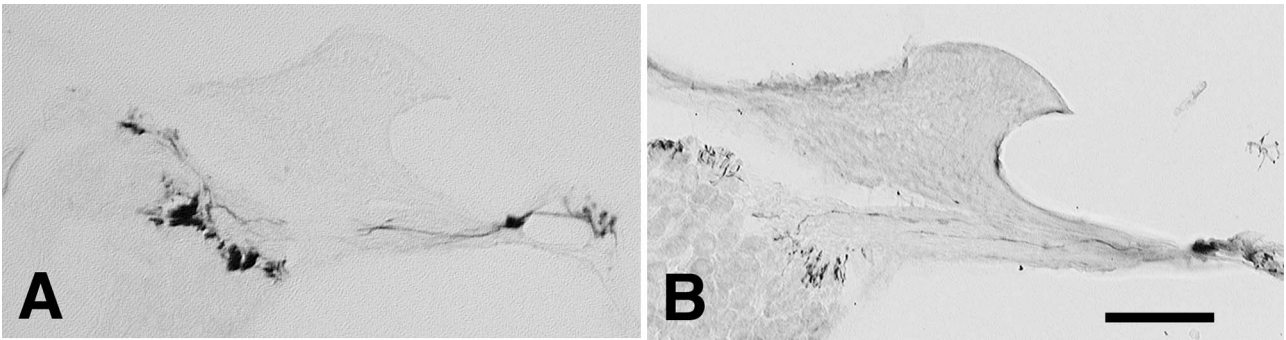
Figures 4A and 4B show the results of AChE histochemistry and cChAT immunohistochemistry, respectively. The pattern of distribution of AChE-positive fibers was



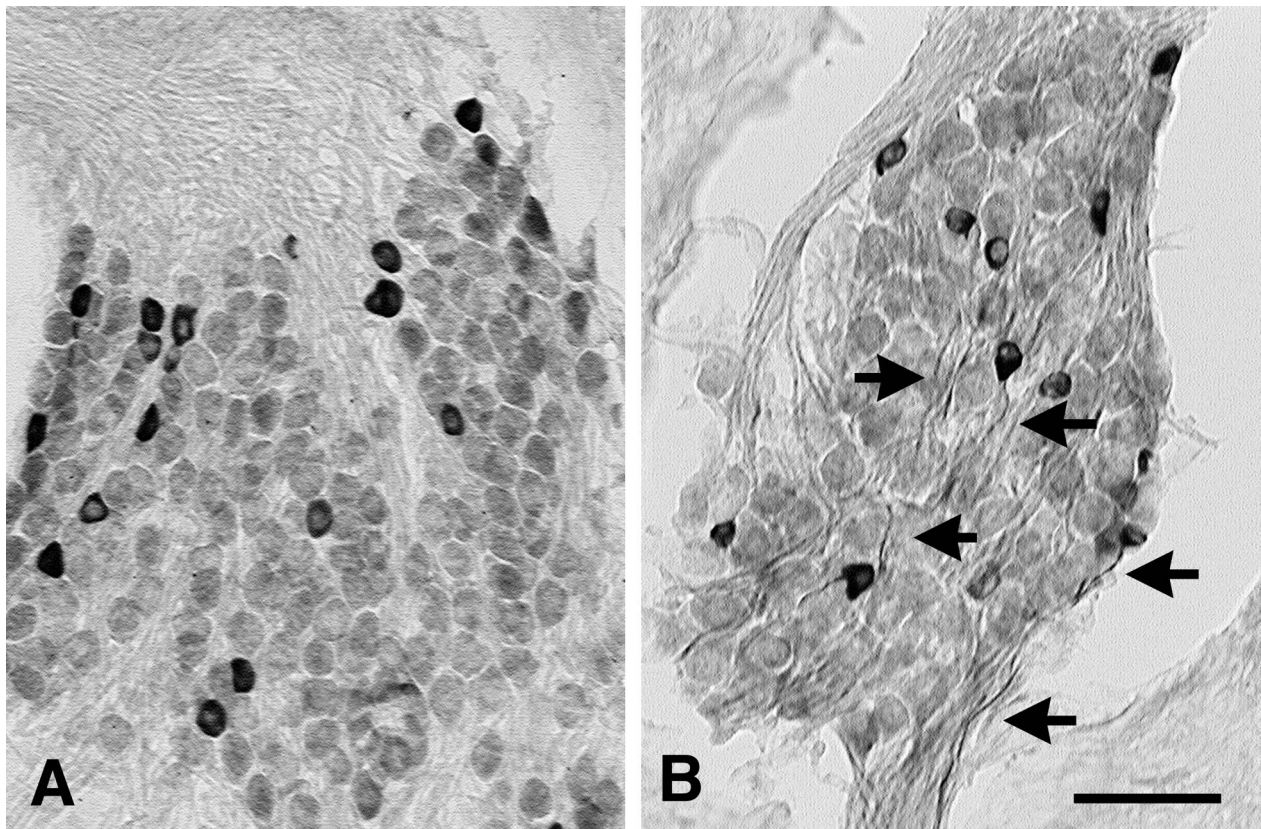
**Fig. 3.** Scattergram showing the correlation between the concentration of choline acetyltransferase of a peripheral type (pChAT) staining and cell area, indicating that pChAT-positive staining in the spiral ganglion seems more specific for the smaller cells.

similar to that of cChAT-positive fibers, but was fundamentally different from that of pChAT-positive fibers (Fig. 4A, B). In agreement with previous studies, we found no AChE-positive cells in the spiral ganglion (Fig. 4A) and no overlap between AChE-positive nerve fibers and those exhibiting pChAT immunoreactivity (data not shown).





**Fig. 4.** Acetylcholinesterase (AChE)-positive (A) and choline acetyltransferase of a common type (cChAT)-positive structures (B) in the rat cochlea. The distribution pattern of AChE-positive nerve fibers is similar to that of cChAT-positive nerve fibers. Neither AChE nor cChAT-positive cells are shown. Bar=50  $\mu$ m.

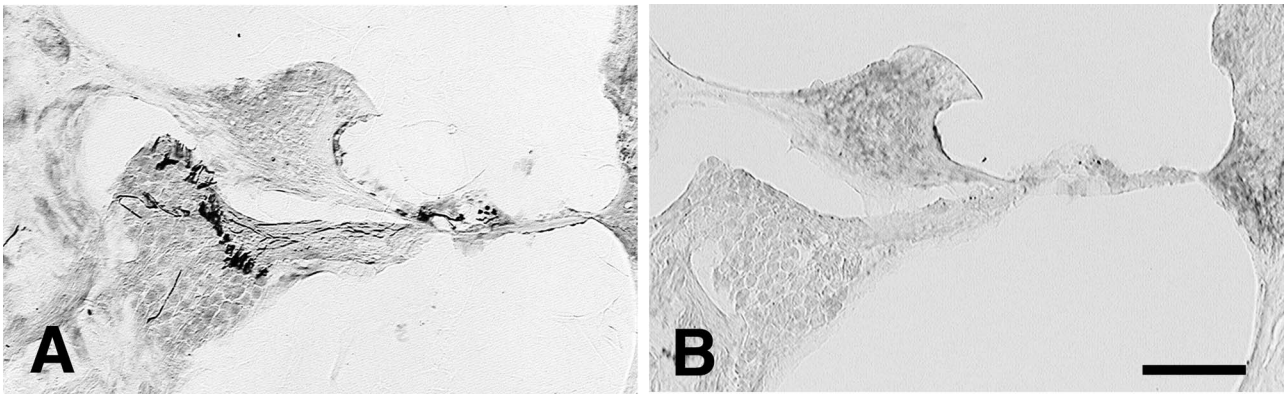


**Fig. 5.** Immunohistochemical staining of choline acetyltransferase of a peripheral type (pChAT) in the spiral ganglion with no treatment (A) or after removal of the cochlear nucleus (B). After removal of the cochlear nucleus, many pChAT-positive fibers are visible (arrows). Bar=50  $\mu$ m.

#### ***Surgical removal of the cochlear nucleus***

To eliminate efferent supplies to the cochlea unilaterally, the cochlear nucleus on one side of the brainstem was ablated surgically. Figures 5A and 5B show pChAT immunoreactivity in the spiral ganglion cells of the untreated and treated side after removal of the cochlear nucleus, respectively. In untreated control sections, pChAT immunoreactivity was localized to the cell bodies of some

ganglionic cells. After removal of the cochlear nucleus, many pChAT-positive nerve fibers became clearly visible (arrows in Fig. 5B). Figures 6A and 6B show cChAT immunoreactivity in the spiral ganglion of the untreated and treated side after removal of the cochlear nucleus, respectively. In contrast to pChAT, cChAT-positive structures in the treated side disappeared after removal of the cochlear nucleus (Fig. 6B).



**Fig. 6.** Immunohistochemical staining of choline acetyltransferase of a common type (cChAT) in the organ of Corti with no treatment (A) or after removal of the cochlear nucleus (B). After removal of the cochlear nucleus, cChAT-positive nerve fibers disappeared. Bar=100  $\mu$ m.

#### IV. Discussion

The present study demonstrated the localization of pChAT-positive neurons and fibers in the spiral ganglion and modiolus of rats. The distribution patterns of pChAT-positive neurons and fibers were different to those of cChAT- and AChE-positive structures. In agreement with previous AChE histochemical studies [14, 21, 22, 30, 42], cChAT- and AChE-positive reactions were detected only in fibers, with none seen in spiral neurons. The cChAT-positive nerve fibers were abolished by ablation of the cochlear nucleus, which is indicative of efferent fibers. This result is supported by many previous reports showing that ChAT activity is strongly decreased as a consequence of such lesions [2, 12, 25, 35]. The present study also demonstrated that cChAT-positive efferent fibers are associated with AChE activity, which agrees with a previous study showing reduced AChE activity after lesioning of the olivocochlear bundle in the brainstem [18].

Although available antibodies against cChAT failed to stain any spiral ganglion cells, the pChAT antibody stained some of these cells, suggesting that some spiral ganglion cells, in particular small cells, express pChAT. After surgical removal of the cochlear nucleus, many pChAT-positive nerve fibers became clearly visible. These results suggested that pChAT protein is transported from the spiral ganglion to the cochlear nucleus. Most pChAT-positive cells were small in size and intensely stained. These small cells in the spiral ganglion were reported to be type II neurons sending sensory information from the outer hair cells (OHCs) to the brainstem [5, 7, 8, 43]. We observed that 9.4% of total ganglionic cells were immunopositive for pChAT, which agrees well with previous studies showing that the OHC type II neurons make up 5%–10% of the spiral ganglion neurons [5, 7, 8, 43]. Taken together with our results, pChAT should be a good marker for OHC type II neurons.

The OHC type II afferent fiber synapse lacks a reliable indicator of activity. The afferent innervation of this hair cell type is very minor compared with that of the inner hair cells. As a consequence, OHC type II afferent fiber activity

is almost certainly masked by innervation of the predominant inner hair cells. Previous studies have suggested that this OHC afferent innervation could act to monitor the motile state (tension) of the OHCs, somewhat paralleling in function the intra-fusal fiber system in striated muscles [28]. This would imply that the innervation actually conveys “sensations of auditory pain” [8] or messages of OHC damage [41] to the cochlear nucleus in response to high-intensity noises that significantly depolarize the OHC, and probably greatly alter its motile state. Neurotransmitter release could occur at that moment, in turn exciting the spiral dendrites of the type II neurons.

It remains unknown whether pChAT synthesizes ACh in the OHC afferent system. However, a recent study showed that pChAT synthesizes ACh in the dorsal root ganglia [3], thus it is highly likely that pChAT participates in the production of ACh. Further studies are required to clarify this issue.

#### V. Conclusion

The localization of pChAT-positive structures was examined in the rat cochlea and compared to cChAT- and AChE-positive structures. While cChAT- and AChE-positive structures were localized to fibers, pChAT-immunoreactivity was detected only in selected neurons in the spiral ganglia. These neurons are small in size and account for 9.4% of total ganglionic cells, suggesting that pChAT-positive cells are OHC type II neurons. After ablation of the cochlear nucleus, cChAT-positive fibers disappeared and pChAT-positive fibers were visible, suggesting that cChAT is localized in the efferent system and pChAT in the afferent system of the rat cochlea.

#### VI. Acknowledgments

This study is supported by Grants-in-Aid for Scientific Research (Kakenhi) from the Ministry of Education, Culture, Sports, Science and Technology (MEXT).

## VII. References

- Altschuler, R. A., Kachar, B., Rubio, J. A., Parakkal, M. H. and Fex, J. (1985) Immunocytochemical localization of choline acetyltransferase-like immunoreactivity in the guinea pig cochlea. *Brain Res.* 338; 1–11.
- Altschuler, R. A. and Fex, J. (1986) Efferent neurotransmitters. In "Neurobiology of hearing: the cochlea" ed. by R. A. Altschuler, R. P. Bobbin and D. W. Hoffman, Raven Press, New York, pp. 161–171.
- Bellier, J. P. and Kimura, H. (2007) Acetylcholine synthesis by choline acetyltransferase of a peripheral type as demonstrated in adult rat dorsal root ganglion. *J. Neurochem.* 101; 1607–1618.
- Benecke, S., Ostermann-Latif, C., Mader, M., Schmidt, B., Unger, J. W., Westarp, M. E. and Felgenhauer, K. (1993) Antibodies raised against synthetic peptides react with choline acetyltransferase in various immunoassays and in immunohistochemistry. *J. Neurochem.* 61; 804–811.
- Berglund, A. M. and Ryugo, D. K. (1987) Hair cell innervation by spiral ganglion neurons in the mouse. *J. Comp. Neurol.* 260; 591–604.
- Brehmer, A., Schrod, F., Neuhuber, W., Tooyama, I. and Kimura, H. (2004) Co-expression pattern of neuronal nitric oxide synthase and two variants of choline acetyltransferase in myenteric neurons of porcine ileum. *J. Chem. Neuroanat.* 27; 33–41.
- Brown, M. C. (1987) Morphology of labeled afferent fibers in the guinea pig cochlea. *J. Comp. Neurol.* 260; 591–604.
- Brown, M. C., Berglund, A. M., Kiang, N. Y.-S. and Ryugo, D. K. (1988) Central trajectories of type II spiral ganglion neurons. *J. Comp. Neurol.* 278; 581–590.
- Chiocchetti, R., Poole, D. P., Kimura, H., Aimi, Y., Robbins, H. L., Castelucci, P. and Furness, J. B. (2003) Evidence that two forms of choline acetyltransferase are differentially expressed in subclasses of enteric neurons. *Cell Tissue Res.* 311; 11–22.
- Chiocchetti, R., Grandis, A., Bombardi, C., Clavanzani, P., Costerbosa, G. L., Lucchi, M. L. and Furness, J. B. (2004) Characterisation of neurons expressing calbindin immunoreactivity in the ileum of the unweaned and mature sheep. *Cell Tissue Res.* 318; 289–303.
- Crawford, G. D., Correa, L. and Salvaterra, P. M. (1982) Interaction of monoclonal antibodies with mammalian choline acetyltransferase. *Proc. Natl. Acad. Sci. USA* 79; 7031–7035.
- Davies, E. D. and Owen, C. (1985) The nature of neurotransmitters in the mammalian lower auditory system. In "Auditory biochemistry" ed. by D. G. Drescher and C. C. Thomas, III, Springfield, pp. 244–257.
- Eckenstein, F. and Thoenen, H. (1982) Production of specific antisera and monoclonal antibodies to choline acetyltransferase: characterization and use for identification of cholinergic neurons. *EMBO J.* 1; 363–368.
- Eybalin, M. (1993) Neurotransmitters and neuromodulators of the mammalian cochlea. *Physiol. Rev.* 73; 309–373.
- Eybalin, M. and Pujol, R. (1987) Choline acetyltransferase (ChAT) immunoelectron microscopy distinguishes at least three types of efferent synapses in the guinea pig organ of Corti. *Brain Res.* 65; 261–270.
- Eybalin, M. and Alschuler, R. A. (1990) Immunoelectron microscopic localization of neurotransmitters in the cochlea. *J. Electron Microsc. Teach.* 15; 209–224.
- Fonnum, F., Frizell, M. and Sjostrand, J. (1973) Transport, turnover and distribution of choline acetyltransferase in the vagus and hypoglossal nerves of the rabbit. *J. Neurochem.* 21; 1109–1120.
- Godfrey, D. A., Williams, A. D. and Matschinsky, F. M. (1977) Quantitative histochemical mapping of enzymes of the cholinergic system in cat cochlear nucleus. *J. Histochem. Cytochem.* 25; 397–416.
- Hanada, K., Kishimoto, S., Bellier, J. P. and Kimura, H. (2013) Peripheral choline acetyltransferase in rat skin demonstrated by immunohistochemistry. *Cell Tissue Res.* 351; 497–510.
- Hebb, C. O. (1957) Biochemical evidence for the neural function of acetylcholine. *Physiol. Rev.* 37; 196–220.
- Iurato, S. (1974) Efferent innervation of the cochlea. In "Handbook of Sensory Physiology" ed. by W. D. Keidel and W. D. Neff, Springer-Verlag, Berlin, pp. 261–282.
- Iurato, S., Luciano, L., Pannese, E. and Reale, E. (1971) Histochemical localization of acetylcholinesterase (AChE) activity in the inner ear. *Acta Otolaryngol. Suppl.* 279; 1–50.
- Kimura, H., McGeer, P. L., Peng, F. and McGeer, E. G. (1980) Choline acetyltransferase-containing neurons in rodent brain demonstrated by immunohistochemistry. *Science* 208; 1057–1059.
- Kimura, H., McGeer, P. L., Peng, J. H. and McGeer, E. G. (1981) The central cholinergic system studied by choline acetyltransferase immunohistochemistry in the cat. *J. Comp. Neurol.* 200; 151–201.
- Klinke, R. (1986) Neurotransmission in the inner ear. *Hear Res.* 22; 235–243.
- Koelle, G. B. (1963) Cytological distributions and physiological functions of cholinesterases. In "Cholinesterases and anticholinesterase agents" ed. by G. B. Koelle, Springer-Verlag, Berlin, pp. 187–298.
- Koga, T., Bellier, J. P., Kimura, H. and Tooyama, I. (2013) Immunoreactivity for choline acetyltransferase of peripheral-type (pChAT) in the trigeminal ganglion neurons of the non-human primate *Macaca fascicularis*. *Acta Histochem. Cytochem.* 46; 59–64.
- Lepage, E. L. (1989) Functional role of the olivo-cochlear bundle: a motor unit control system in the mammalian cochlea. *Hear Res.* 38; 177–198.
- Levey, A. I., Armstrong, D. M., Atweh, S. F., Terry, R. D. and Wainer, B. H. (1983) Monoclonal antibodies to choline acetyltransferase: production, specificity, and immunohistochemistry. *J. Neurosci.* 3; 1–9.
- Lieberman, M. C. (1990) Effects of chronic cochlear deafferentation on auditory-nerve response. *Hear Res.* 49; 209–223.
- McCaman, R. E. and Dewhurst, S. A. (1970) Choline acetyltransferase in individual neurons of *Aplysia californica*. *J. Neurochem.* 17; 1421–1426.
- Nakajima, K., Tooyama, I., Yasuhara, O., Aimi, Y. and Kimura, H. (2000) Immunohistochemical demonstration of choline acetyltransferase of a peripheral type (pChAT) in the enteric nervous system of rats. *J. Chem. Neuroanat.* 18; 31–40.
- Nakanishi, Y., Tooyama, I., Yasuhara, O., Aimi, Y., Kitajima, K. and Kimura, H. (1999) Immunohistochemical localization of choline acetyltransferase of a peripheral type in the rat larynx. *J. Chem. Neuroanat.* 17; 21–32.
- Okano, H., Toyoda, K., Bamba, H., Hisa, Y., Oomura, Y., Imamura, T., Furukawa, S., Kimura, H. and Tooyama, I. (2006) Localization of fibroblast growth factor-1 in cholinergic neurons innervating the rat larynx. *J. Histochem. Cytochem.* 54; 1061–1071.
- Rossi, G., Rolando, M. and Olina, M. (1986) The neurotransmitters of the efferent cochlear system. *Scand. Audiol. Suppl.* 25; 49–52.
- Saito, A., Sato, T., Okano, H., Toyoda, K., Bamba, H., Kimura, S., Bellier, J. P., Matsuo, A., Kimura, H., Hisa, Y. and Tooyama, I. (2009) Axotomy alters alternative splicing of choline acetyltransferase in the rat dorsal motor nucleus of the vagus nerve. *J. Comp. Neurol.* 513; 237–248.
- Sakaue, Y., Bellier, J. P., Kimura, S., D'Este, L., Takeuchi, Y. and Kimura, H. (2013) Immunohistochemical localization of two types of choline acetyltransferase in neurons and sensory cells of the octopus arm. *Brain Struct. Funct.* (in press).

38. Schuknecht, H. F., Churchill, J. A. and Doran, R. (1959) The localization of acetylcholinesterase in the cochlea. *Arch. Otolaryngol.* 69; 549–559.
39. Shute, C. C. D. and Lewis, P. R. (1965) Cholinesterase-containing pathways of the hindbrain: afferent cerebellar and centrifugal cochlear fibers. *Nature* 205; 242–246.
40. Silver, A. (1967) Cholinesterases of the central nervous system with special reference to the cerebellum. *Int. Rev. Neurobiol.* 10; 57–109.
41. Simmons, D. D. and Liberman, M. C. (1988) Afferent innervation of outer hair cells in adult cats. I. Light microscopic analysis of fibers labeled with horseradish peroxidase. *J. Comp. Neurol.* 270; 132–144.
42. Sobkowicz, H. M. and Emmerling, M. (1989) Development of acetylcholinesterase-positive neuronal pathways in the cochlea of the mouse. *J. Neurocytol.* 18; 209–224.
43. Spoendlin, H. (1972) Innervation densities of the cochlea. *Acta Otolaryngol.* 73; 235–248.
44. Tago, H., Kimura, H. and Maeda, T. (1986) Visualization of detailed acetylcholinesterase fiber and neuron staining in rat brain by a sensitive histochemical procedure. *J. Histochem. Cytochem.* 34; 1431–1438.
45. Tooyama, I. and Kimura, H. (2000) A protein encoded by an alternative splice variant of choline acetyltransferase mRNA is localized preferentially in peripheral nerve cells and fibers. *J. Chem. Neuroanat.* 17; 217–226.
46. Wainer, B. H., Levey, A. I., Mufson, E. J. and Mesulam, M. M. (1984) Cholinergic systems in mammalian brain identified with antibodies against choline acetyltransferase. *Neurochem. Int.* 6; 163–182.
47. Yasuhara, O., Tooyama, I., Aimi, Y., Bellier, J. P., Hisano, T., Matsuo, A., Park, M. and Kimura, H. (2003) Demonstration of cholinergic ganglion cells in rat retina: expression of an alternative splice variant of choline acetyltransferase. *J. Neurosci.* 23; 2872–2881.
48. Yasuhara, O., Aimi, Y., Shibano, A., Matsuo, A., Bellier, J. P., Park, M., Tooyama, I. and Kimura, H. (2004) Innervation of rat iris by trigeminal and ciliary neurons expressing pChAT, a novel splice variant of choline acetyltransferase. *J. Comp. Neurol.* 472; 232–245.
49. Yasuhara, O., Aimi, Y., Shibano, A. and Kimura, H. (2007) Primary sensory neurons containing choline acetyltransferase of the peripheral type in the rat trigeminal ganglion and their relation to neuropeptides-, calbindin- and nitric oxide synthase-containing cells. *Brain Res.* 1141; 92–98.
50. Yasuhara, O., Matsuo, A., Bellier, J. P. and Aimi, Y. (2007) Demonstration of choline acetyltransferase of a peripheral type in the rat heart. *J. Histochem. Cytochem.* 55; 287–299.
51. Yasuhara, O., Aimi, Y., Matsuo, A. and Kimura, H. (2008) Distribution of a splice variant of choline acetyltransferase in the trigeminal ganglion and brainstem of the rat: comparison with calcitonin gene-related peptide and substance P. *J. Comp. Neurol.* 509; 436–448.

---

This is an open access article distributed under the Creative Commons Attribution License, which permits unrestricted use, distribution, and reproduction in any medium, provided the original work is properly cited.

---