



# Profound trigeminocardiac reflex from lingual nerve stimulation: a case report

Allen Champion, John Masi

Oral and Maxillofacial Surgery, Thomas Jefferson University, Philadelphia, USA

Trigeminocardiac reflex (TCR) is a well-known brainstem reflex that manifests as hypotension, bradycardia, dysrhythmia, and asystole when stimulation is applied to a branch of the trigeminal nerve. Most commonly associated with ophthalmic, orbital, and neurologic surgeries, mandibular division and oral cavity variants occur far less frequently. Here, we describe a case of asystolic TCR elicited by lingual nerve stimulation. This case highlights the role of specific anesthetic medications in modulating this phenomenon and reinforces the need for early recognition and clear communication in case of its occurrence. Anesthesia providers must consider discontinuing or avoiding certain medications when clinically appropriate, even during low TCR-risk procedures.

**Keywords:** Anesthesia, General; Asystole; Reflex, Trigeminocardiac.



This is an Open Access article distributed under the terms of the Creative Commons Attribution Non-Commercial License (<http://creativecommons.org/licenses/by-nc/4.0/>) which permits unrestricted non-commercial use, distribution, and reproduction in any medium, provided the original work is properly cited.



## INTRODUCTION

Intraoperative hypotension and asystole from traction on the extraocular muscles during orbital surgery were first characterized by Aschner and Dagnini in 1908 and labeled oculocardiac reflex (OCR). Since then, the oculocardiac reflex has been reclassified as a subtype of the trigeminocardiac reflex (TCR), a term coined by Shelly and Church [1]. TCR is a well-documented brainstem reflex during maxillofacial and neurological surgery. It is characterized by paroxysmal dysautonomia from manipulation of the sensory branches of the fifth cranial nerve, resulting in gastric hypermotility, hypotension, cardiac dysrhythmias, asystole, and bradycardia [2].

TCR has been described during numerous surgical procedures in the head and neck region. Ophthalmic,

strabismus, and orbital surgeries carry the greatest risk of eliciting TCR, followed by skull-base surgeries. Lefort I osteotomy, zygomatic arch reduction, and temporomandibular joint insufflation, are considered low-risk [3]. However, several physiological and pharmacological factors can influence patients' individual risk assessment. To the best of the authors' knowledge, this phenomenon has never been elicited by stimulating the lingual nerve via tongue traction. This case describes a profound manifestation of TCR during surgery for ranula excision as well as anesthetic risk factors that may potentiate this rare phenomenon. This study was exempt from institutional review board review (#21E.1013).

## CASE REPORT

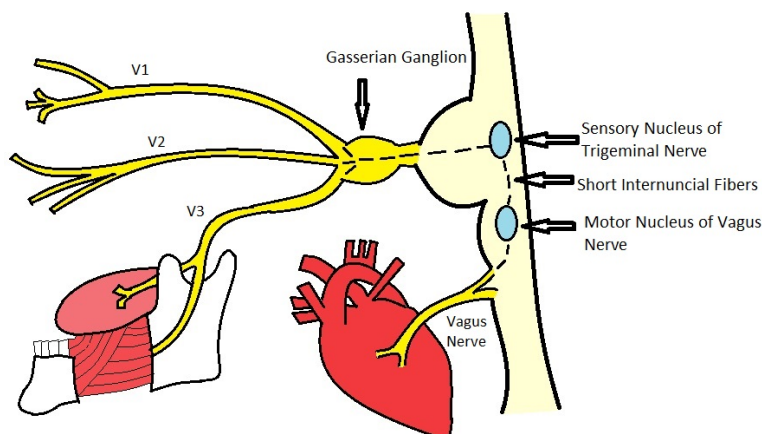
A 77-year-old man (height, 183 cm; weight, 75 kg;

Received: December 6, 2021 • Revised: December 26, 2021 • Accepted: January 4, 2022

Corresponding Author: Allen Champion, DDS, Assistant Professor, Oral and Maxillofacial Surgery, Thomas Jefferson University, Oral and Maxillofacial Surgery, 909 Walnut St suite 300, Philadelphia, PA 19107, USA

Phone: +1-(215)955-6215 Fax: +1-(215)923-9189 E-mail: [Allen.champion@jefferson.edu](mailto:Allen.champion@jefferson.edu)

Copyright© 2022 Journal of Dental Anesthesia and Pain Medicine



**Fig. 1.** Schematic diagram illustrating the mechanism of action of the trigeminocardiac reflex. In the present case, the reflex was believed to have been elicited by stimulation of the lingual nerve.

body mass index (BMI), 22.7) presented to the oral and maxillofacial surgery office for evaluation of a ranula in the right floor of the mouth. His pertinent medical history was significant for coronary artery disease status post mild myocardial infarction (MI) 11 years prior, hypertension, well-controlled type II diabetes mellitus, stage III chronic kidney disease, and cervical disc disease status post C3-T3 fusion surgery. Medications included aspirin 81 mg and metoprolol 50 mg. No food or medication allergies, nor alcohol, tobacco, or recreational drug use was reported. A review of the baseline electrocardiogram (ECG) showed sinus rhythm with a ventricular rate of 68 bpm and corrected Q-T interval (QTc) of 400.

Due to the patient's cervical immobility from previous spinal fusion and Mallampati III airway, awake nasal fiberoptic intubation was planned. Routine monitors were placed, revealing pre-anesthetic heart rates ranging from 60–68 bpm and a pre-induction blood pressure of 130/68. A 2% lidocaine gel-soaked “lollipop” was used to topicalize the posterior oropharynx, and phenylephrine nasal spray was administered into each nostril. Next, 2 mg midazolam and 20 mg ketamine were administered intravenously. Following uneventful nasal intubation, the subglottic cuff position was fiberoptically confirmed, and an 80 mg bolus of propofol was administered to induce general anesthesia. Afterwards, the patient was mechanically ventilated, and anesthesia was maintained

with infusions of remifentanyl 0.1 mcg/kg/min and propofol 80 mcg/kg/min. During the period from preoperative sedation through intubation, the heart rate ranged from 60–68 bpm and remained regular; the mean arterial pressure (MAP) ranged from 70–103 mm Hg, and oxyhemoglobin saturation remained at 99% or greater. A 3-0 silk suture was placed near the tip of the tongue to aid in retraction. To identify Wharton's duct, the anterior floor of the mouth was visualized by manually applying gentle digital pressure to the right ventral aspect of the tongue. The patient became bradycardic and asystolic. Manipulation of the soft tissue ceased, and the heart rate returned to 50–55 bpm within 1 min. The non-invasive blood pressure reading was 60/40, and 15 mg ephedrine and 50 µg phenylephrine was administered intravenously. Once hemodynamics stabilized, the procedure was continued. Superior tongue traction was applied in the aforementioned fashion, and the patient became bradycardic and asystolic. The procedure was stopped, and the patient was given 0.1 mg glycopyrrolate intravenously. Consistent with the pulseless state, the pulse oximeter did not register numerical values following asystolic periods. However, after the heart rate rebounded, the readings returned to the anesthetic baseline of 100%. A third attempt at tongue traction was performed by applying digital sublingual pressure. This time, the patient's heart rate dropped below 30 bpm but ultimately returned to within 20% of his anesthetic

**Table 1.** Prospective studies investigating the effect of remifentanyl and ketamine on trigemino-cardiac reflex

Author	Manuscript title	Study design	Number of patients in study	Age range (years)	Findings
Hahnenkamp, et al, 2000 [11]	Effect of Different Anesthetic Regimes on the Oculocardiac Reflex during Pediatric Strabismus Surgery	RCT	39	4-14	Ketamine anesthesia showed a statistically significant blunting of OCR during pediatric strabismus surgery compared with other anesthetic techniques.
Arnold, et al, 2004 [6]	The Profound Augmentation of the Oculocardiac Reflex by Fast Acting Opioids	Prospective study	1275	0.2-92	In the absence of anticholinergics, remifentanyl potentiated OCR the most during tension on extraocular muscles, followed by sufentanyl, then fentanyl. Morphine and meperidine showed no effect.
Choi, et al, 2007 [10]	Single Bolus of Intravenous Ketamine for Anesthetic Induction Decreases Oculocardiac Reflex in Children Undergoing Strabismus Surgery	RCT	120	3-9	A single pre-operative bolus of ketamine significantly reduced the incidence of OCR compared to propofol.
Chung, et al 2008 [9]	Effect of Remifentanyl on Oculocardiac Reflex in Pediatric Strabismus Surgery	RCT	120	1-9	Remifentanyl infusion enhanced the OCR in patients compared to sevoflurane.
Choi, et al, 2009 [8]	Effect of Different Anesthetic Agents on Oculocardiac Reflex in Pediatric Strabismus Surgery	RCT	280	1-9	Incidence of OCR with remifentanyl and propofol was greater than with sevoflurane or desflurane. Ketamine did not exhibit blunting of OCR in either anesthetic regimen.
Mizrak, et al, 2010 [13]	Ketamine Versus Propofol for Strabismus Surgery in Children	RCT	60	4-11	Heart rate and blood pressure were maintained in the ketamine group compared to the propofol group, suggesting that ketamine provided protection against parasympathetic activation by OCR.
Oh, et al, 2013 [14]	Effect of Ketamine and Midazolam on Oculocardiac Reflex in Pediatric Strabismus Surgery	RCT	61	2-9	No statistically relevant decrease in incidence of OCR with ketamine as compared to midazolam.
Espahbodi, et al, 2014 [12]	Ketamine or Atropine: Which One Better Prevents Oculocardiac Reflex during Eye Surgery? a Prospective Randomized Clinical Trial	RCT	90	4-10	Ketamine was associated with a lower incidence of the OCR and may be the better choice for induction compared to atropine.

OCR, oculocardiac reflex; RCT, randomized controlled trials.

baseline upon cessation of manipulation. The patient experienced a profound manifestation of the TCR, not inhibited by administration of sympathomimetic and anticholinergic medications. Because the surgery required continued retraction of the tongue and floor of the mouth mucosa throughout the procedure, the elective procedure was aborted. The propofol and remifentanyl infusions were discontinued, and uneventful emergence and extubation followed. Postoperative chest X-ray showed no electrolyte abnormalities, with negative serial troponin T.

## DISCUSSION

TCR is an autonomic reflex that manifests as

bradycardia or asystole and hypotension during maxillofacial and neurological surgery (Fig. 1). However, its incidence is particularly rare among the mandibular variants. A review of the literature revealed only five reported third-division TCR cases occurring under general anesthesia that resulted in asystole and none involving lingual nerve stimulation. In this case, TCR was most likely activated via the lingual nerve, a branch of the posterior division of the mandibular division of cranial nerve V.

Predisposing risk factors for the activation of the TCR include hypercapnia, hypoxemia, light anesthesia depth, young age, and certain medications [2,4]. Any medication that can augment vagal tone can potentiate the reflex, such as beta blockers, calcium channel blockers, and opioid analgesics, through sympathetic blockade [5,6]. In

this case, the patient was taking metoprolol, a beta-adrenergic blocker, which was continued on the day of the surgery. Consequently, the heart rate remained stable during induction and intubation. However, the resultant decrease in sympathetic tone may have made the patient more vulnerable to intraoperative bradycardia during manipulation. Although propofol is known to cause a reduction in heart rate and blood pressure, the period from induction to the start of surgical manipulation saw MAPs range from 82–90 mmHg and heart rate range from 58–64 bpm, not significantly different from the pre-anesthetic vital signs. However, propofol has been found to increase the relative risk of OCR during pediatric strabismus surgery compared with volatile anesthetic agents [7]; therefore, its effect on the anesthetic outcome in this case must be considered.

Fast-acting opioids have been shown to increase the risk of TCR. A systematic review of the literature revealed three prospective trials that enrolled a total of 1,675 patients and investigated the TCR-modulating effects of remifentanyl, all of which reported a drug-related increase in the incidence of TCR [6,8,9]. In a prospective trial of 1,274 patients, Arnold et al. reported that remifentanyl potentiated TCR most frequently, followed by sufentanyl and fentanyl; some narcotics displayed TCR augmentation similar to the blunting effect of IV anticholinergic medications [6]. However, ketamine's role in modulating TCR is less clearly defined. Several trials have demonstrated its TCR-attenuating effect [10–13], while others reporting no protection [8,14] (Table 1). Notably, all eight clinical trials used extraocular muscle tension to elicit TCR. The small dose (20 mg) administered prior to intubation did not significantly influence the outcome in this case.

Midazolam, ketamine, propofol, and remifentanyl combination was believed to provide appropriate anesthetic depth in this case, as evidenced by the patient's lack of consciousness, lack of reflex movement or swallowing, apnea, and need for mechanical ventilation, particularly in the absence of neuromuscular blockade. While no single medication administered can definitively

be attributed to potentiating TCR in this case, combination of propofol, remifentanyl, and beta blockade may have decreased sympathetic tone sufficiently to predispose the patient to the observed vital sign perturbations.

While several investigators have reported blunting of TCR with administration of local anesthesia, its efficacy remains controversial. Similarly, no consensus exists regarding the use of topical or intravenous lidocaine for blunting or preventing TCR. However, surgical factors, such as applying prolonged tension to nerves or their innervated structures, are associated with an increased TCR risk [3].

The patient in this case had multiple medical comorbidities but none was considered to have directly influenced his anesthetic outcome. His cardiac condition was stable, without functional impairment or arrhythmia, with no pathological cardiopulmonary clinical examination findings. His diabetes was well controlled and his chronic kidney disease did not result in electrolyte abnormalities. Local factors, such as taping of the eyelids and endotracheal tube, also did not appear to affect the outcome, as vital sign parameters remained stable during these efforts. Even the placement of the tongue suture did not appear to influence the clinical course. As ablative surgery never actually began, sutures were never used to aid in retraction. Instead, TCR was consistently elicited by application of gentle superior traction to the ventral aspect of the tongue on three separate occasions. No other mechanical or pharmacological interventions leading up to this traction event resulted in changes in the heart rate or blood pressure.

Anesthesia providers must remain vigilant during monitoring of vital sign perturbations consistent with TCR, not only during high-risk orbital and ophthalmic surgeries, but also with any procedure that involves applying traction to structures innervated by branches of the trigeminal nerve. Discontinuation or avoidance of known TCR-potentiating agents, when clinically appropriate, may facilitate safe anesthesia delivery in refractory cases. Clear communication between the

surgeon and anesthetist is crucial, particularly when treating patients with pharmacological and surgical risk factors that increase their susceptibility to TCR.

#### AUTHOR ORCID*s*

**Allen Champion:** <https://orcid.org/0000-0002-0696-3997>

**John Masi:** <https://orcid.org/0000-0001-5282-5926>

#### AUTHOR CONTRIBUTIONS

**Allen Champion:** Conceptualization, Data curation, Investigation, Writing - original draft, Writing - review & editing

**John Masi:** Data curation, Investigation, Writing - original draft

**CONFLICTS OF INTEREST:** The authors declare no conflict of interest.

#### REFERENCES

1. Shelly MP, Church JJ. Bradycardia and facial surgery (letter). *Anesthesia* 1988; 43: 422.
2. Schaller B, Probst R, Strebel S, Gratzl O. Trigemino-cardiac reflex during surgery in the cerebellopontine angle. *J Neurosurg* 1999; 90: 215-20.
3. Lübbers HT, Zweifel D, Grätz KW, Kruse A. Classification of potential risk factors for trigemino-cardiac reflex in craniomaxillofacial surgery. *J Oral Maxillofac Surg* 2010; 68: 1317-21.
4. Lang S, Lanigan DT, van der Wal M. Trigemino-cardiac reflexes: maxillary and mandibular variants of the oculocardiac reflex. *Can J Anaesth* 1991; 38: 757-60.
5. Arasho B, Sandu N, Spiriev T, Prabhakar H, Schaller B. Management of the trigemino-cardiac reflex: facts and own experience. *Neurol India* 2009; 57: 375-80.
6. Arnold RW, Jensen PA, Kovtoun TA, Maurer SA, Schultz JA. The profound augmentation of the oculocardiac reflex by fast acting opioids. *Binocul Vis Strabismus Q* 2004; 19: 215-22.
7. Scheiermann P, Herzog F, Siebenhofer A, Strametz R, Weberschock T. Intravenous versus inhalational anesthesia for pediatric inpatient surgery - a systematic review and meta-analysis. *J Clin Anesth* 2018; 49: 19-25.
8. Choi SR, Park SW, Lee JH, Lee SC, and Chung CJ. Effect of different anesthetic agents on oculocardiac reflex in pediatric strabismus surgery. *J Anesth* 2009; 23: 489-93.
9. Chung CJ, Lee JM, Choi SR, Lee SC, Lee JH. Effect of remifentanyl on oculocardiac reflex in paediatric strabismus surgery. *Acta Anaesthesiol Scand* 2008; 52: 1273-7.
10. Choi SH, Lee SJ, Kim SH, Kim JH, Kwon HH, Shin YS, et al. Single bolus of intravenous ketamine for anesthetic induction decreases oculocardiac reflex in children undergoing strabismus surgery. *Acta Anaesthesiol Scand* 2007; 51: 759-62.
11. Hahnenkamp K, Hönemann CW, Fischer LG, Durieux ME, Muehlendyck H, Braun U. Effect of different anaesthetic regimes on the oculocardiac reflex during paediatric strabismus surgery. *Paediatr Anaesth* 2000; 10: 601-8.
12. Espahbodi E, Sanatkar M, Sadrossadat H, Darabi Vafsi ME, Azarshahin M, Shoroughi M. Ketamine or atropine: which one better prevents oculocardiac reflex during eye surgery? A prospective randomized clinical trial. *Acta Med Iran* 2015; 53: 158-61.
13. Mizrak A, Erbagci I, Arici T, Ozcan I, Ganidagli S, Tatar G, et al. Ketamine versus propofol for strabismus surgery in children. *Clin Ophthalmol* 2010; 19: 673-9.
14. Oh JN, Lee SY, Lee JH, Choi SR, Chin YJ. Effect of ketamine and midazolam on oculocardiac reflex in pediatric strabismus surgery. *Korean J Anesthesiol* 2013; 64: 500-4.