

# Pathophysiology of Coagulopathy in Hematological Malignancies and in COVID-19

Marcel Levi<sup>1,2</sup>

**Correspondence:** Marcel Levi (marcel.levi@nhs.net).

## Abstract

Many severe illnesses with a systemic impact may cause activation of coagulation. While systemic activation of coagulation leads to a coagulopathy that follows many common activation pathways and failure of endogenous regulatory anticoagulant systems, underlying conditions may utilize distinctive pathogenetic routes and may vary in clinical manifestations of the coagulopathy. The coagulation derangement associated with hematological malignancies and the coagulopathy of coronavirus disease 2019 (COVID-19) clearly demonstrate such differences. Malignancies are associated with venous thromboembolism due to the biological effect of malignant cells, frequent medical interventions, or the presence of indwelling vascular catheters. The underlying pathogenesis of cancer-associated coagulopathy relies on tissue factor-mediated activation of coagulation, cytokine-controlled defective anticoagulant pathways, fibrinolytic changes, and dysfunctional endothelium. There is an additional risk caused by anti-cancer agents including chemotherapy and immunotherapy. The underlying pathogenetic factor that contributes to the thrombotic risk associated with chemotherapy is endothelial cell injury (or loss of protection of endothelial integrity, for example, by vascular endothelial growth factor inhibition). In addition, individual anti-cancer agents may have specific prothrombotic effects. One of the remarkable features of severe COVID-19 infections is a coagulopathy that mimics but is not identical to the disseminated intravascular coagulation and thrombotic microangiopathy and has been identified as a strong marker for an adverse outcome. Severe COVID-19 infections cause inflammation-induced changes in coagulation in combination with severe endothelial cell injury. This coagulopathy likely contributes to pulmonary microvascular thrombosis, bronchoalveolar fibrin deposition (which is a hallmark of acute respiratory distress syndrome) and venous thromboembolic complications.

## Introduction

A variety of disorders, including infectious conditions or malignant disease, can lead to activation of coagulation. In many cases, this activation of coagulation will not lead to clinical complications and will not even be detected by routine laboratory tests, but can only be measured with sensitive molecular markers for activation of coagulation factors and pathways.<sup>1,2</sup> However, in specific cases and if activation of coagulation is sufficiently strong, the platelet count may decrease and global clotting times may become prolonged. In its most extreme form, systemic activation of coagulation is known as disseminated intravascular coagulation (DIC). DIC is characterized by the simultaneous occurrence of widespread (micro)vascular thrombosis, thereby compromising blood supply to various organs, which may contribute to organ failure.<sup>3,4</sup> Ongoing activation of the coagulation system and

other factors, such as impaired synthesis and increased degradation of coagulation proteins and protease inhibitors, may cause consumption of clotting factors and platelets, resulting in bleeding from various sites.

Different underlying causes of systemic coagulation activation may lead to different clinical presentations.<sup>5,6</sup> In contrast to the acutely ill septic patient with acute and severe DIC, associated with multiple organ dysfunction, patients with cancer may have mild or protracted clinical manifestations of consumption or even subclinical disease manifest by only laboratory abnormalities.<sup>7-9</sup> The clinical picture of subacute to chronic DIC generally occurs in patients with more advanced solid or hematological malignancies.<sup>10</sup> The clinical manifestations may be dominated by bleeding or venous and arterial thromboembolism.<sup>11</sup> In contrast, the coagulopathy associated with coronavirus disease 2019 (COVID-19) presents with localized pulmonary fibrin deposition and thrombotic microangiopathy as well as an increased incidence of venous thromboembolism.<sup>12-14</sup> The coagulopathy accompanying each of these 2 clinical situations will be further highlighted in the following paragraphs.

## The coagulopathy of malignancies

Patients with hematological and solid tumors are vulnerable to risk factors and additional triggers of DIC that can aggravate thromboembolism and bleeding.<sup>10,15</sup> Risk factors include advanced age, stage of the disease, and use of chemotherapy or other anti-neoplastic treatment.<sup>16</sup> Frank DIC may be seen in patients with malignancies and is particularly severe in patients with acute lymphoblastic leukemia's, widespread intravascular metastases and mucin-secreting adenocarcinomas.<sup>10</sup>

<sup>1</sup>Department of Medicine and Cardiometabolic Programme-NIHR UCLH/UCL BRC, University College London Hospitals NHS Foundation Trust, London, United Kingdom

<sup>2</sup>Department of Vascular Medicine, Amsterdam University Medical Center (location Academic Medical Center), Amsterdam, The Netherlands  
Copyright © 2021 the Author(s). Published by Wolters Kluwer Health, Inc. on behalf of the European Hematology Association. This is an open-access article distributed under the terms of the Creative Commons Attribution-Non Commercial-No Derivatives License 4.0 (CCBY-NC-ND), where it is permissible to download and share the work provided it is properly cited. The work cannot be changed in any way or used commercially without permission from the journal. HemaSphere (2021) 5:6(e571). <http://dx.doi.org/10.1097/H59.0000000000000571>.

Received: 14 March 2021 / Accepted: 7 April 2021

Tumor cells can express different procoagulant molecules including tissue factor (TF), which forms a complex with factor VII(a) to activate factors IX and X, and a cancer procoagulant (CP)—a cysteine protease with factor X activating properties.<sup>17</sup> In several cancers, TF is expressed by vascular endothelial cells as well as the tumor cells. TF also appears to be involved in tumor metastasis and angiogenesis. CP is an endopeptidase that can be found in extracts of neoplastic cells but also in the plasma of patients with solid tumors. The exact role of CP in the pathogenesis of cancer-related DIC is unclear. Interactions of P- and L-selectins with cancer cells can induce formation of platelet microthrombi and probably constitute a third mechanism of cancer-related thrombosis. Depending on the rate and quantity of exposure or influx of shed vesicles from tumors containing TF, a nonovert or overt DIC develops.<sup>18</sup>

Numerous reports on DIC and fibrinolysis complicating the course of acute leukemias have been published. In 161 consecutive patients presenting with acute myeloid leukemia, DIC was diagnosed in 52 (32%) of them. In acute lymphoblastic leukemia, DIC was diagnosed in 15%–20%.<sup>19</sup> Some reports indicate that the incidence of DIC in acute leukemia patients might further increase during remission induction with chemotherapy. In patients with acute promyelocytic leukemia (APL), DIC is present in more than 90% of patients at the time of diagnosis or after initiation of remission induction. The pathogenesis of hemostatic disturbance in APL is related to properties of the malignant cells and their interaction with the host's endothelial cells. APL cells express TF and the CP that can initiate coagulation, and they release interleukin (IL)-1 $\beta$  and tumor necrosis factor (TNF)- $\alpha$ , which down-regulate endothelial thrombomodulin, thereby compromising the protein C anticoagulant pathway.<sup>20,21</sup> APL cells also express increased amounts of annexin II, which mediates augmented conversion of plasminogen to plasmin.<sup>22</sup> The overall results of these processes are DIC and hyperfibrinolysis, ensued by life-threatening major bleeding. All-trans-retinoic acid, used for induction and maintenance therapy of APL, inhibits *in vitro* and *in vivo* the deleterious effect of APL cells and has led to a reduced frequency of early hemorrhagic death.<sup>23,24</sup>

## Cancer-related thrombosis and thrombotic microangiopathy

The epidemiology of cancer in patients who present with thrombosis has been studied in 14 cohort studies with almost 5000 patients.<sup>25</sup> The mean prevalence was about 15% and it can be calculated that cancer increases the risk of thrombosis by a factor 4. If chemotherapy is administered, the relative risk further rises to 6.5. Studies in patients with breast cancer on chemotherapeutic agents (and often hormonal treatment) demonstrated a 5-year risk of thrombosis of up to 10%. Factors that increase the risk of thrombosis in patients with malignancies are the tumor type, the stage of the disease, the type of chemotherapy, and other issues, notably the presence of intravascular catheters. The Khorana score is increasingly used as a thrombotic risk prediction score in patients with cancer.<sup>26</sup> Patients with a high score in this algorithm should be considered for antithrombotic prophylaxis.<sup>27,28</sup>

Apart from venous thromboembolism, another serious complication of cancer and chemotherapy is thrombotic microangiopathy. The pathogenesis of thrombotic microangiopathy in cancer remains to be precisely elucidated. It is hypothesized that cancer-related changes in endothelial cells play a central role in the development of the syndrome. Endothelial damage and subsequent dysfunction have been implicated in various reports dealing with chemotherapy-related thrombotic microangiopathy, however, there is no definitive proof for this hypothesis nor is it clear how the endothelial dysfunction may result in the

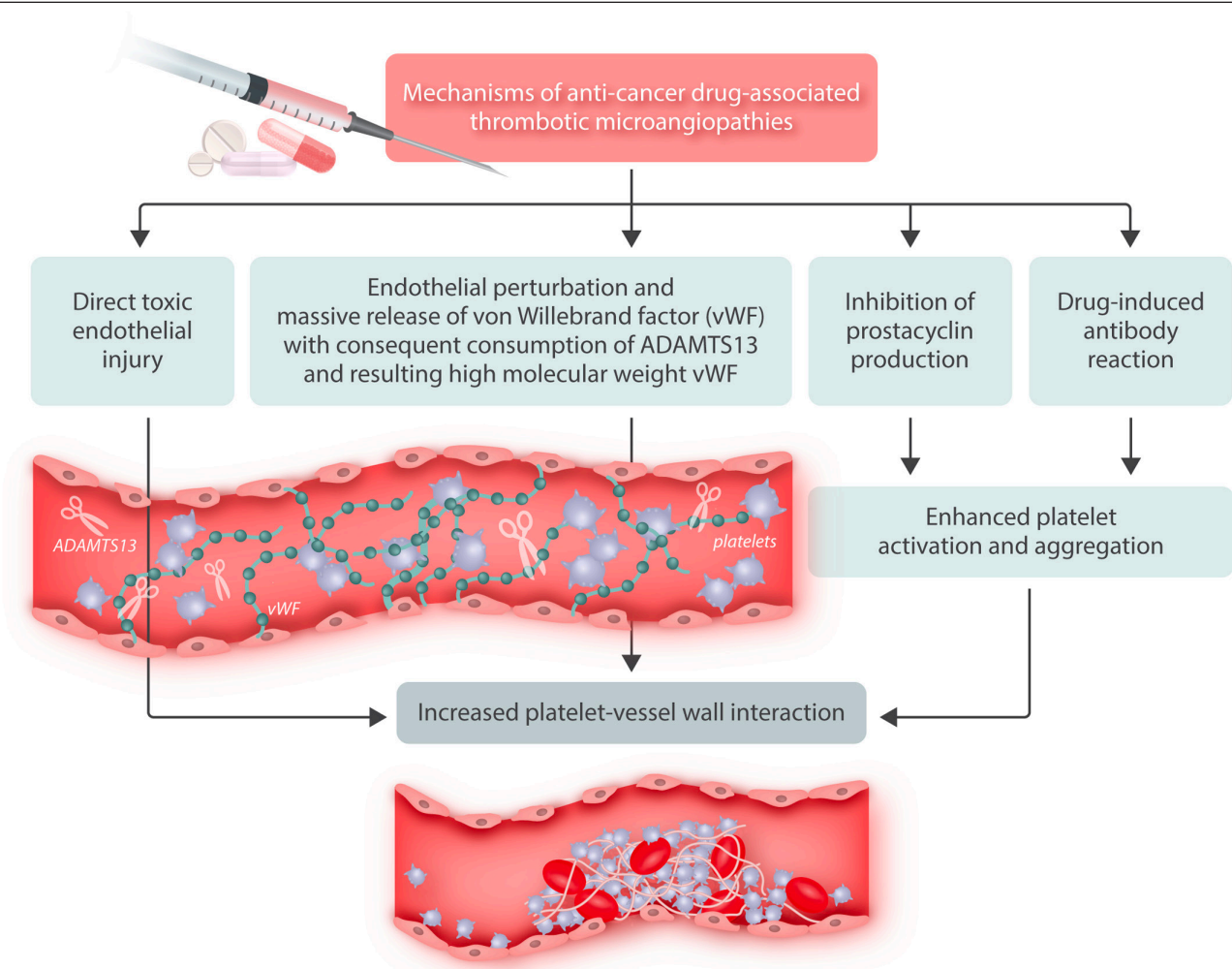
thrombotic microangiopathy.<sup>29</sup> More than 90% of patients with cancer-related thrombotic microangiopathy have metastasized malignancies, whereas in contrast, patients with chemotherapy-induced thrombotic microangiopathy have limited disease.<sup>30</sup> In particular, high-dose conventional chemotherapy that is used as conditioning regimen before autologous or allogeneic stem cell transplantation and newer biological anti-cancer agents may cause this complication.

## Chemotherapy, coagulopathy, and thrombosis

Chemotherapy increases the risk of thrombosis, mostly due to its damaging effect on endothelial cells.<sup>15</sup> Anti-angiogenic agents, in particular in combination with (high-dose) conventional chemotherapy, considerably increase this risk. The use of thalidomide (mostly in myeloma and renal cell carcinoma) in combination with chemotherapy causes thrombosis in 30%–40% of patients.<sup>31,32</sup> This incidence is not significantly different with newer variants, such as lenalidomide and pomalidomide.<sup>33</sup> Of note, the occurrence of venous thrombosis is associated with a 1.7-fold increased 6-month mortality in patients with myeloma.<sup>34</sup> New generation anti-angiogenic agents have been associated with a high risk of venous thromboembolism but also arterial thrombosis, presumably in the same way because of their effect on endothelial cells.<sup>35,36</sup>

Indwelling intravascular catheters may provide a surface on which thrombosis in patients with cancer can more easily occur, and this risk is further increased when catheter-related infection is present. Retrospective trials have demonstrated that the risk of catheter-associated thrombosis is between 5% and 15%.<sup>37,38</sup> A study in patients with a hematological malignancy showed that nonsymptomatic thrombosis had an even higher incidence.

Vascular endothelium plays a crucial role in coagulation and thrombus formation (Figure 1). Endothelium is the primary source of von Willebrand factor, the adhesive protein that governs the interaction between the glycoprotein Ib receptor on the platelet surface and the vessel wall. Many cancer patients display enhanced plasma levels of von Willebrand factor potentially contributing to increased platelet-vessel wall interaction.<sup>15,39,40</sup> *In vitro* studies have demonstrated that chemotherapy enhances endothelial cell reactivity to platelets.<sup>41</sup> In addition, endothelial cells can express TF and thrombomodulin (which modulates the activation of protein C, a pivotal physiological inhibitor of coagulation) on their surface.<sup>42,43</sup> *In vitro* studies have demonstrated that endothelial cells respond to certain stimuli, such as toxic agents, with a downregulation of thrombomodulin expression, thereby impairing the generation of activated protein C and blocking this inhibitory pathway of coagulation.<sup>43</sup> The use of high-dose chemotherapy has indeed been associated with reduced activity of the protein C system. Finally, a myriad of adhesion molecules, expressed by the endothelium can regulate binding and activation of leukocytes to the vessel wall, causing the release of various cytokines that can mediate activation of blood coagulation and clot formation.<sup>27,29,30,44,45</sup> More than 200 cases have been described in the literature in more than 25 publications and prospective studies, showing that the incidence of thrombotic microangiopathy in recipients of high-dose chemotherapy ranges from 2% to 8%.<sup>29,46–51</sup> Thrombotic microangiopathy includes syndromes such as thrombotic thrombocytopenic purpura and hemolytic uremic syndrome but also conditions such as veno-occlusive disease are reminiscent to those seen in thrombotic microangiopathy. Thrombotic microangiopathy is caused by enhanced platelet adhesion to the endothelium leading to abundant platelet aggregation and activation causing consumptive thrombocytopenia. The formed platelet thrombi in the vasculature result in impaired organ function such as renal insufficiency or neurological disease and in red cell fragmentation as a consequence of microangiopathic hemolysis.<sup>52</sup> The



**Figure 1. Schematic representation of mechanisms by which various anti-neoplastic agents can cause thrombotic microangiopathy as a result of enhanced platelet-vessel wall interaction and contributing to organ dysfunction and overt vascular complications.**

prognosis of chemotherapy-induced thrombotic microangiopathy is poor: mortality was shown to be approximately 30%, most of which was directly caused by the thrombotic microangiopathy.<sup>29,30</sup> In addition, surviving patients may have persistent renal failure.

### COVID-19 coagulopathy

The most remarkable abnormal coagulation test in severe COVID-19 patients is an excessively elevated D-dimer level.<sup>53-55</sup> A large COVID-19 case series study found abnormally elevated D-dimer levels in 46% of all cases (43% in nonsevere patients versus 60% in critically ill intensive care unit patients).<sup>56</sup> In another study, increased concentrations of D-dimer were related to an adverse outcome.<sup>53</sup> In an investigation of more than 300 COVID-19 patients it was demonstrated that D-dimer levels of more than 2.0 mg/L predicted death with a sensitivity of 92% and a specificity of 83%.<sup>57</sup>

In patients with more severe COVID-19 infection, the prothrombin time is only moderately prolonged (about 3 s).<sup>55</sup> Prolongation of the activated partial thromboplastin time (aPTT) is less often seen, although this could be obscured by high levels of factor VIII and fibrinogen that in most assays shortens the aPTT.

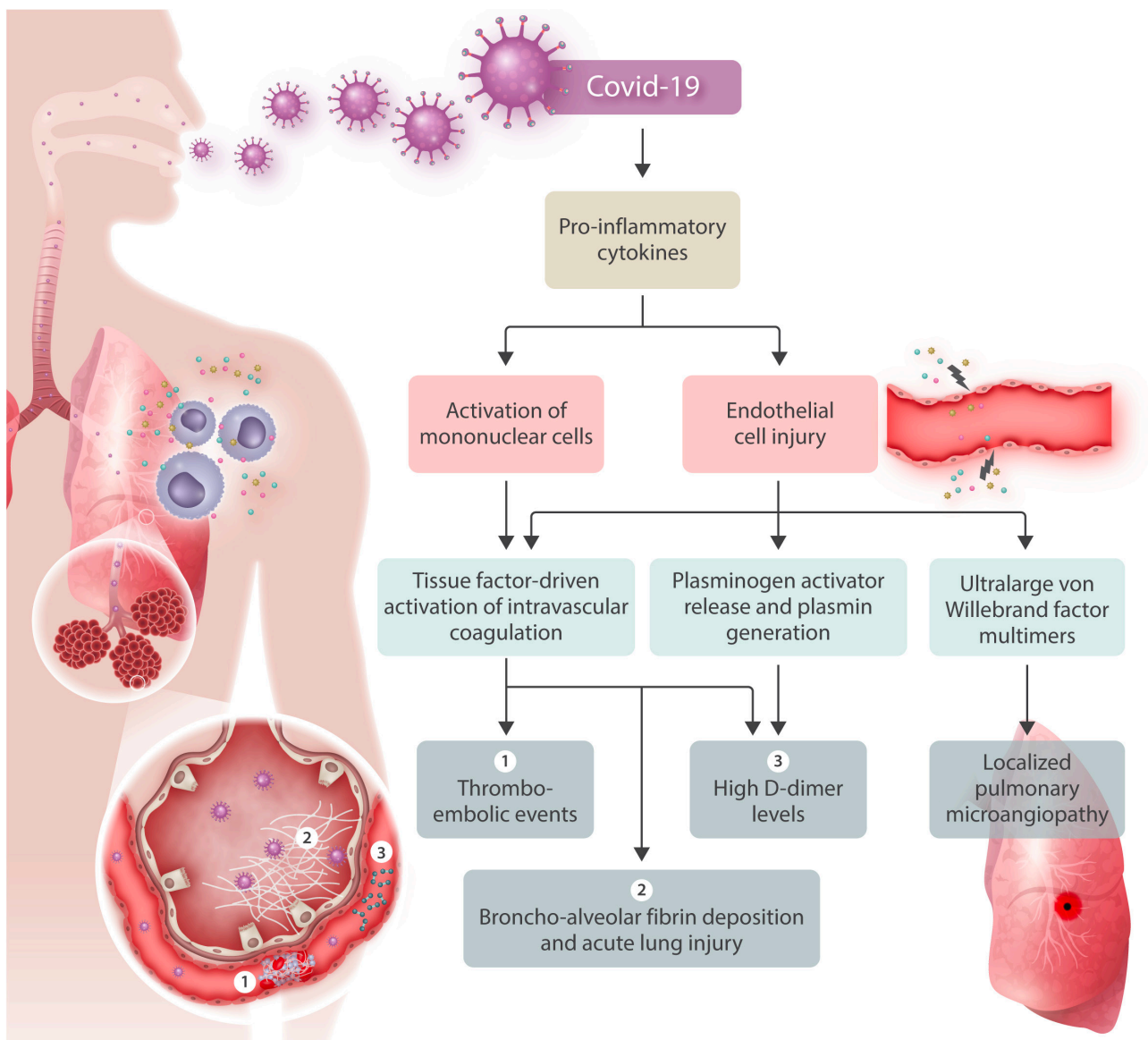
Another coagulation defect that is seen in the most severely affected patients is thrombocytopenia.<sup>58,59</sup> Most of these patients have a platelet count between 100 and 150 × 10<sup>9</sup>/L and more severe

thrombocytopenia is hardly (<5%) observed.<sup>54,56</sup> A meta-analysis demonstrated significantly lower platelet counts (about minus 30 × 10<sup>9</sup>/L [95% confidence interval (CI), -35 to -29 × 10<sup>9</sup>/L]) in critically ill COVID-19 patients and thrombocytopenia defined as below the lower limit of the reference range was associated with more than 5-fold higher risk of severe disease (odds ratio, 5.1; 95% CI, 1.8-14.6).<sup>60</sup> In contrast to low platelet counts seen in other severe infections, thrombocytopenia in COVID-19 has not been significantly associated with mortality.<sup>58,61</sup>

Coagulation factor levels in COVID-19 are usually within the normal range but mean fibrinogen plasma concentration (and to a lesser extent factor VIII:c) can be abnormally high, which is likely due to an acute phase response.<sup>55</sup> In very ill patients a rapid fall in plasma fibrinogen levels below <1.0 g/L was observed shortly before death. Plasma levels of physiological coagulation regulators such as protein C and antithrombin are slightly low, in particular in the nonsurviving patients, but these concentrations seldom drop below 80% of normal.<sup>55</sup> Several studies have reported abnormal overall clotting and increased viscoelastic parameters by thrombelastography.<sup>62</sup>

### Pathogenesis and relevance of COVID-19 coagulopathy

In severe COVID-19 circulating levels of proinflammatory cytokines, such as TNF- $\alpha$  and IL-1 and IL-6, are distinctly



**Figure 2. Pathogenetic pathways in the coagulopathy of COVID-19 leading to various prothrombotic clinical manifestations of the disease.** Cytokine activation leads to tissue factor expression and endothelial injury, subsequently resulting in coagulation activation, plasminogen activator release and occurrence of ultra-large von Willebrand factor multimers due to endothelial cell release and overwhelming of the cleaving protease ADAMTS-13 as well as inhibition of this cleavage due to high levels of interleukin-6.

increased (Figure 2).<sup>54</sup> IL-6 generates TF expression on mononuclear cells, which consequently results in thrombin generation. In a subset of the most severe COVID-19 patients, a cytokine ‘storm’ can be recognized with (very) high levels of proinflammatory cytokines and chemokines.<sup>63</sup> It has been hypothesized that this pattern mimics secondary hemophagocytic lymphohistiocytosis, an under-recognized, hyper-inflammatory syndrome characterized by fulminant hypercytokinemia, excessive coagulation activation and multiple organ failure.<sup>64</sup>

All coronavirus infections are associated with a remarkable fibrinolytic profile. Experiments in mice with a targeted deletion of the urokinase-type plasminogen gene demonstrated a urokinase-driven route as an important factor for survival.<sup>65</sup> In addition, in patients with human severe acute respiratory syndrome coronavirus 1 infection, levels of tissue-type plasminogen activator were 6-fold higher than normal.<sup>66</sup> It is probable that inflammation-mediated endothelial cell perturbation causes a substantial release of plasminogen activators which explains the high concentrations of D-dimer in the most severe COVID-19

patients. Also, plasmin effects on metalloproteinases can lead to extracellular matrix remodeling, thereby promoting capillary leakage and pulmonary edema. Interestingly, the effects of the virus on plasminogen activators do not translate into a hyperfibrinolytic state or an enhanced risk of systemic hemorrhage in patients with COVID-19.

There is a marked relationship between bronchoalveolar coagulation and fibrinolysis and the development of acute respiratory distress syndrome (ARDS), in which intrapulmonary fibrin deposition as a result of deranged bronchoalveolar fibrin turnover is a critical step.<sup>67</sup> The clinical and laboratory picture of serious ARDS in ventilated COVID-19 patients and important coagulation abnormalities may point to a potential role of bronchoalveolar fibrin turnover in the most severe COVID-19 patients.<sup>68</sup>

The coagulation changes associated with COVID-19 infection point in the direction of a hypercoagulable state that may at least cause an enhanced risk of thromboembolic complications. Immobilization and vascular damage are other factors that may

increase the risk of thrombosis. A large number of clinical observational studies in almost 2000 patients suggests an incidence of venous thromboembolism of up to 35% in patients with severe COVID-19.<sup>69,70</sup> Several retrospective studies point to a higher risk of venous thromboembolism in patients with more severe COVID-19 coagulopathy. It has been suggested that (low molecular weight) heparin prophylaxis can reduce the risk of venous thromboembolism. In addition, there is ample experimental and some clinical evidence that heparin has antithrombotic and anti-inflammatory properties that may be relevant for the treatment of “immunothrombosis.”<sup>71</sup>

The relevance of microvascular thrombosis for organ dysfunction has also been suggested based on post-mortem pathological reports. Several reports highlight vascular wall thickening, stenosis of the vascular lumen, and microthrombus formation associated with findings of ARDS. Comparable pathological observations have been made in the vasculature of other organs.<sup>72</sup>

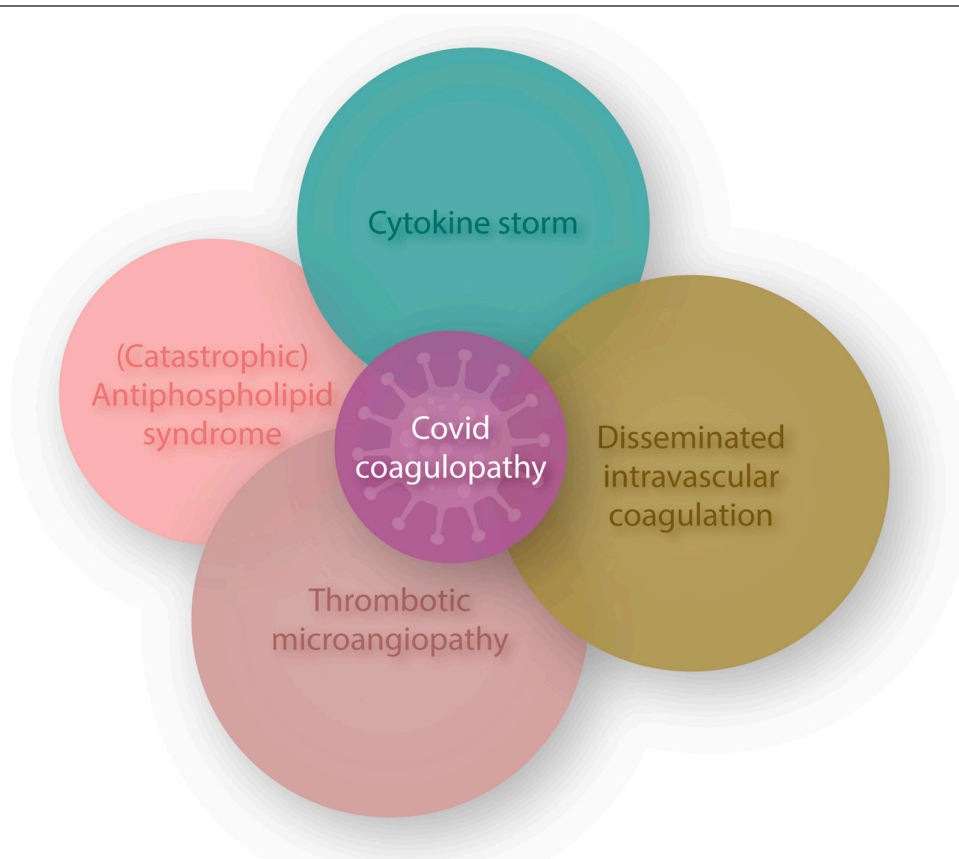
Taken together, it seems there are 2 parallel clinical manifestations of the COVID-19 coagulopathy: (1) “classic” venous thromboembolism (presumably provoked by cytokine-mediated activation of coagulation in combination with other risk factors for thrombosis) and (2) diffuse microthrombosis with endothelial damage (in the lungs) directly caused by the coronavirus.<sup>61</sup>

### Other pathways in the COVID-19 coagulopathy

COVID-19 overlaps with various other coagulopathies (Figure 3).<sup>73</sup> Some features mimic cytokine release syndromes and in a number of studies, positive antiphospholipid antibodies

have been reported (but never confirmed according to current guidelines for antiphospholipid syndrome classification).<sup>74</sup> Histopathology from post-mortem examinations in COVID-19 patients has shown typical microvascular platelet-rich thrombotic depositions in small vessels of the lungs along foci of local hemorrhage and accumulation and entrapment of inflammatory cells, such as neutrophils, in alveolar capillaries. This picture is compatible with pulmonary thrombotic microangiopathy.<sup>75</sup> Thrombotic microangiopathy is a result of increased platelet adhesion to the vascular endothelium in association with platelet aggregation and activation causing consumptive thrombocytopenia.<sup>76</sup> The resultant platelet thrombi in the microvasculature cause impaired organ function and classically contribute to complications such as renal insufficiency or neurological disease as well as microangiopathic hemolysis. The presence of (at least localized) thrombotic microangiopathy is supported by observations of abnormal von Willebrand factor/ADAMTS-13 ratio's. Interestingly, IL-6 is known to inhibit the cleavage of ultra-large von Willebrand factor multimers by ADAMTS-13.<sup>77</sup> A recent report also correlates low ADAMTS-13 plasma levels with mortality in seriously ill COVID-19 patients.<sup>78</sup> However, at present, there is insufficient evidence to support the presence of systemic thrombotic microangiopathy.

The striking increase in vascular complications and specific coagulation changes as discussed above seem to point to a specific endothelial cell involvement in COVID-19. COVID-19 (and other coronavirus infections) are clear examples of direct viral infection of endothelial cells.<sup>79</sup> Indeed, infection- and inflammation-induced endothelial cell perturbation and injury can provide an excellent scaffold for intravascular thrombus



**Figure 3. COVID-19-associated coagulopathy partially overlaps with infection-induced DIC, CRS, APS, and TMA, however, it does not meet the criteria for any of these coagulopathies.** APS = antiphospholipid syndrome; CRS = cytokine release syndrome; DIC = disseminated intravascular coagulation; TMA = thrombotic microangiopathy; vWF = von Willebrand factor.

formation. It may also cause increased platelet-vessel wall interaction, due to release of high molecular weight multimers of von Willebrand factor, insufficiently cleaved by deficient ADAMTS-13, and resulting in thrombotic microangiopathy in the microvasculature.<sup>80</sup>

## Conclusions

Systemic coagulopathies follow common pathogenetic pathways for initiation, propagation and impaired regulation of coagulation activation but distinctive underlying disorders, such as cancer or specific infections such as COVID-19, may follow differential pathways and present with characteristic clinical presentations. Unified pathways encompass cytokine-mediated expression of TF and downregulation of physiological anticoagulant routes as well as endothelial cell perturbation and injury. The extent of endothelial damage may determine specific additional hemostatic defects, such as thrombotic microangiopathy or localized organ-specific fibrin deposition.

## Disclosures

The author has no conflicts of interest to disclose.

## References

- Levi M, Scully M. How I treat disseminated intravascular coagulation. *Blood*. 2018;131:845–854.
- Levi M, Seligsohn U. Disseminated intravascular coagulation. In: Kaushansky K, Lichtman M, Beutler E, et al, eds. *Williams Hematology*. 10th ed. Philadelphia, PA: McGraw Hill; 2021.
- Levi M, Ten Cate H. Disseminated intravascular coagulation. *N Engl J Med*. 1999;341:586–592.
- Levi M. Disseminated intravascular coagulation. *Crit Care Med*. 2007;35:2191–2195.
- Squizzato A, Gallo A, Levi M, et al. Underlying disorders of disseminated intravascular coagulation: communication from the ISTH SSC Subcommittees on Disseminated Intravascular Coagulation and Perioperative and Critical Care Thrombosis and Hemostasis. *J Thromb Haemost*. 2020;18:2400–2407.
- Iba T, Levy JH, Thachil J, et al. The progression from coagulopathy to disseminated intravascular coagulation in representative underlying diseases. *Thromb Res*. 2019;179:11–14.
- Straub PW. Diffuse intravascular coagulation in liver disease? *Semin Thromb Hemost*. 1977;4:29–39.
- Levi M. Disseminated intravascular coagulation: a disease-specific approach. *Semin Thromb Hemost*. 2010;36:363–365.
- Seligsohn U. Disseminated intravascular coagulation. In: Handin RL, Lux SE, Stossel TP, eds. *Blood: Principles and Practice of Hematology*. Philadelphia, PA: J. B. Lippincott; 2000.
- Levi M. Disseminated intravascular coagulation in cancer: an update. *Semin Thromb Hemost*. 2019;45:342–347.
- Levi M. Cancer-related coagulopathies. *Thromb Res*. 2014;133(suppl 2):S70–S75.
- Levi M, Thachil J, Iba T, et al. Coagulation abnormalities and thrombosis in patients with COVID-19. *Lancet Haematol*. 2020;7:e438–e440.
- Iba T, Levy JH, Connors JM, et al. The unique characteristics of COVID-19 coagulopathy. *Crit Care*. 2020;24:360.
- Iba T, Levy JH, Levi M, et al. Coagulopathy of coronavirus disease 2019. *Crit Care Med*. 2020;48:1358–1364.
- Leiva O, Newcomb R, Connors JM, et al. Cancer and thrombosis: new insights to an old problem. *J Med Vasc*. 2020;45:6S8–6S16.
- Levi M, Sivapalaratnam S. An overview of thrombotic complications of old and new anticancer drugs. *Thromb Res*. 2020;191(suppl 1):S17–S21.
- Falanga A, Marchetti M, Vignoli A. Coagulation and cancer: biological and clinical aspects. *J Thromb Haemost*. 2013;11:223–233.
- Falanga A, Schieppati F, Russo D. Cancer tissue procoagulant mechanisms and the hypercoagulable state of patients with cancer. *Semin Thromb Hemost*. 2015;41:756–764.
- Barbui T, Falanga A. Disseminated intravascular coagulation in acute leukemia. *Semin Thromb Hemost*. 2001;27:593–604.
- Marti-Carvajal AJ, Anand V, Sola I. Treatment for disseminated intravascular coagulation in patients with acute and chronic leukemia. *Cochrane Database Syst Rev*. 2015;2015:CD008562.
- Franchini M, Di Minno MN, Coppola A. Disseminated intravascular coagulation in hematologic malignancies. *Semin Thromb Hemost*. 2010;36:388–403.
- Stein E, McMahon B, Kwaan H, et al. The coagulopathy of acute promyelocytic leukaemia revisited. *Best Pract Res Clin Haematol*. 2009;22:153–163.
- Burnett AK, Russell NH, Hills RK, et al. Arsenic trioxide and all-trans retinoic acid treatment for acute promyelocytic leukaemia in all risk groups (AML17): results of a randomised, controlled, phase 3 trial. *Lancet Oncol*. 2015;16:1295–1305.
- Visani G, Gugliotta L, Tosi P, et al. All-trans retinoic acid significantly reduces the incidence of early hemorrhagic death during induction therapy of acute promyelocytic leukemia. *Eur J Haematol*. 2000;64:139–144.
- Otten HM, Prins MH. Venous thromboembolism and occult malignancy. *Thromb Res*. 2001;102:V187–V194.
- van Es N, Di Nisio M, Cesarman G, et al. Comparison of risk prediction scores for venous thromboembolism in cancer patients: a prospective cohort study. *Haematologica*. 2017;102:1494–1501.
- Herrmann J. Vascular toxic effects of cancer therapies. *Nat Rev Cardiol*. 2020;17:503–522.
- Verso M, Agnelli G, Barni S, et al. A modified Khorana risk assessment score for venous thromboembolism in cancer patients receiving chemotherapy: the Protecht score. *Intern Emerg Med*. 2012;7:291–292.
- Pettitt AR, Clark RE. Thrombotic microangiopathy following bone marrow transplantation. *Bone Marrow Transplant*. 1994;14:495–504.
- Izzedine H, Perazella MA. Thrombotic microangiopathy, cancer, and cancer drugs. *Am J Kidney Dis*. 2015;66:857–868.
- Zangari M, Anaissie E, Barlogie B, et al. Increased risk of deep-vein thrombosis in patients with multiple myeloma receiving thalidomide and chemotherapy. *Blood*. 2001;98:1614–1615.
- Desai AA, Vogelzang NJ, Rini BI, et al. A high rate of venous thromboembolism in a multi-institutional phase II trial of weekly intravenous gemcitabine with continuous infusion fluorouracil and daily thalidomide in patients with metastatic renal cell carcinoma. *Cancer*. 2002;95:1629–1636.
- Li A, Wu Q, Warnick G, et al. The incidence of thromboembolism for lenalidomide versus thalidomide in older patients with newly diagnosed multiple myeloma. *Ann Hematol*. 2020;99:121–126.
- Schoen MW, Carson KR, Luo S, et al. Venous thromboembolism in multiple myeloma is associated with increased mortality. *Res Pract Thromb Haemost*. 2020;4:1203–1210.
- Kuenen BC, Rosen L, Smit EF, et al. Dose-finding and pharmacokinetic study of cisplatin, gemcitabine, and SU5416 in patients with solid tumors. *J Clin Oncol*. 2002;20:1657–1667.
- Dhami SPS, Patmore S, O'Sullivan JM. Advances in the management of cancer-associated thrombosis. *Semin Thromb Hemost*. 2021;47:139–149.
- Bona RD. Thrombotic complications of central venous catheters in cancer patients. *Semin Thromb Hemost*. 1999;25:147–155.
- Walshe LJ, Malak SF, Eagan J, et al. Complication rates among cancer patients with peripherally inserted central catheters. *J Clin Oncol*. 2002;20:3276–3281.
- Holler E, Kolb HJ, Hiller E, et al. Microangiopathy in patients on cyclosporine prophylaxis who developed acute graft-versus-host disease after HLA-identical bone marrow transplantation. *Blood*. 1989;73:2018–2024.
- Collins PW, Gutteridge GN, O'Driscoll A, et al. von Willebrand factor as a marker of endothelial cell activation following BMT. *Bone Marrow Transplant*. 1992;10:499–506.
- Bertomeu MC, Gallo S, Lauri D, et al. Chemotherapy enhances endothelial cell reactivity to platelets. *Clin Exp Metastasis*. 1990;8:511–518.
- Conway EM, Van de Wouwer M, Pollefeys S, et al. The lectin-like domain of thrombomodulin confers protection from neutrophil-mediated tissue damage by suppressing adhesion molecule expression via nuclear factor kappaB and mitogen-activated protein kinase pathways. *J Exp Med*. 2002;196:565–577.
- Conway EM, Rosenberg RD. Tumor necrosis factor suppresses transcription of the thrombomodulin gene in endothelial cells. *Mol Cell Biol*. 1988;8:5588–5592.
- Levi M, ten Cate H, van der Poll T. Endothelium: interface between coagulation and inflammation. *Crit Care Med*. 2002;30(5 suppl):S220–S224.
- Doll DC, Yarbro JW. Vascular toxicity associated with antineoplastic agents. *Semin Oncol*. 1992;19:580–596.

46. Snyder HW Jr, Mittelman A, Oral A, et al. Treatment of cancer chemotherapy-associated thrombotic thrombocytopenic purpura/hemolytic uremic syndrome by protein A immunoadsorption of plasma. *Cancer*. 1993;71:1882–1892.
47. Guinan EC, Tarbell NJ, Niemeyer CM, et al. Intravascular hemolysis and renal insufficiency after bone marrow transplantation. *Blood*. 1988;72:451–455.
48. Chappell ME, Keeling DM, Prentice HG, et al. Haemolytic uraemic syndrome after bone marrow transplantation: an adverse effect of total body irradiation? *Bone Marrow Transplant*. 1988;3:339–347.
49. Antignac C, Gubler MC, Leverger G, et al. Delayed renal failure with extensive mesangiolytic following bone marrow transplantation. *Kidney Int*. 1989;35:1336–1344.
50. Rabinowe SN, Soiffer RJ, Tarbell NJ, et al. Hemolytic-uremic syndrome following bone marrow transplantation in adults for hematologic malignancies. *Blood*. 1991;77:1837–1844.
51. Juckett M, Perry EH, Daniels BS, et al. Hemolytic uremic syndrome following bone marrow transplantation. *Bone Marrow Transplant*. 1991;7:405–409.
52. Neild GH. Haemolytic-uraemic syndrome in practice. *Lancet*. 1994;343:398–401.
53. Zhou F, Yu T, Du R, et al. Clinical course and risk factors for mortality of adult inpatients with COVID-19 in Wuhan, China: a retrospective cohort study. *Lancet*. 2020;395:1054–1062.
54. Huang C, Wang Y, Li X, et al. Clinical features of patients infected with 2019 novel coronavirus in Wuhan, China. *Lancet*. 2020;395:497–506.
55. Tang N, Li D, Wang X, et al. Abnormal coagulation parameters are associated with poor prognosis in patients with novel coronavirus pneumonia. *J Thromb Haemost*. 2020;18:844–847.
56. Guan WJ, Ni ZY, Hu Y, et al. Clinical characteristics of coronavirus disease 2019 in China. *N Engl J Med*. 2020;381:1708–1720.
57. Zhang L, Yan X, Fan Q, et al. D-dimer levels on admission to predict in-hospital mortality in patients with Covid-19. *J Thromb Haemost*. 2020;18:1324–1329.
58. Lippi G, Plebani M, Henry BM. Thrombocytopenia is associated with severe coronavirus disease 2019 (COVID-19) infections: a meta-analysis. *Clin Chim Acta*. 2020;506:145–148.
59. Brogaard Larsen J, Pasalic L, Hvas AM. Platelets in coronavirus disease. *Semin Thromb Hemost*. 2020;46:823–825.
60. Favaloro EJ, Lippi G. Maintaining hemostasis and preventing thrombosis in coronavirus disease 2019 (COVID-19)-part I. *Semin Thromb Hemost*. 2020;46:757–762.
61. Levi M, Iba T. COVID-19 coagulopathy: is it disseminated intravascular coagulation? *Intern Emerg Med*. 2021;16:309–312.
62. Ranucci M, Ballotta A, Di Dedda U, et al. The procoagulant pattern of patients with COVID-19 acute respiratory distress syndrome. *J Thromb Haemost*. 2020;18:1747–1751.
63. Levi M. Tocilizumab for severe COVID-19: a promising intervention affecting inflammation and coagulation. *Eur J Intern Med*. 2020;76:21–22.
64. Valade S, Mariotte E, Azoulay E. Coagulation disorders in hemophagocytic lymphohistiocytosis/macrophage activation syndrome. *Crit Care Clin*. 2020;36:415–426.
65. Gralinski LE, Bankhead A 3rd, Jeng S, et al. Mechanisms of severe acute respiratory syndrome coronavirus-induced acute lung injury. *mBio*. 2013;4:e00271–e00213.
66. Liu ZH, Wei R, Wu YP, et al. Elevated plasma tissue-type plasminogen activator (t-PA) and soluble thrombomodulin in patients suffering from severe acute respiratory syndrome (SARS) as a possible index for prognosis and treatment strategy. *Biomed Environ Sci*. 2005;18:260–264.
67. Glas GJ, Van Der Sluijs KF, Schultz MJ, et al. Bronchoalveolar hemostasis in lung injury and acute respiratory distress syndrome. *J Thromb Haemost*. 2013;11:17–25.
68. Levi M, Hunt BJ. Thrombosis and coagulopathy in COVID-19: an illustrated review. *Res Pract Thromb Haemost*. 2020;4:744–751.
69. Iba T, Levy JH, Connors JM, Warkentin TE, Thachil J, Levi M. Managing thrombosis and cardiovascular complications of COVID-19: answering the questions in COVID-19-associated coagulopathy. *Expert Rev Respir Med*. 2021 March 14. [Epub ahead of print].
70. Malas MB, Naazie IN, Elsayed N, et al. Thromboembolism risk of COVID-19 is high and associated with a higher risk of mortality: a systematic review and meta-analysis. *EClinicalMedicine*. 2020;29:100639.
71. Buijssers B, Yanginlar C, Maciej-Hulme ML, et al. Beneficial non-anticoagulant mechanisms underlying heparin treatment of COVID-19 patients. *EBioMedicine*. 2020;59:102969.
72. Iba T, Levy JH, Levi M, et al. Coagulopathy in COVID-19. *J Thromb Haemost*. 2020;18:2103–2109.
73. Levi M, Thachil J. Coronavirus disease 2019 coagulopathy: disseminated intravascular coagulation and thrombotic microangiopathy—either, neither, or both. *Semin Thromb Hemost*. 2020;46:781–784.
74. Miyakis S, Lockshin MD, Atsumi T, et al. International consensus statement on an update of the classification criteria for definite antiphospholipid syndrome (APS). *J Thromb Haemost*. 2006;4:295–306.
75. Fox SE, Atmakbekov A, Harbert JL, Li G, Brown JQ, Vander Heide RS. Pulmonary and cardiac pathology in Covid-19: the first autopsy series from New Orleans. *medRxiv*. Preprint posted online April 10, 2020. doi: 10.1101/2020.04.06.20050575.
76. George JN, Nester CM. Syndromes of thrombotic microangiopathy. *N Engl J Med*. 2014;371:654–666.
77. Bernardo A, Ball C, Nolasco L, et al. Effects of inflammatory cytokines on the release and cleavage of the endothelial cell-derived ultralarge von Willebrand factor multimers under flow. *Blood*. 2004;104:100–106.
78. Bazzan M, Montaruli B, Sciascia S, et al. Low ADAMTS 13 plasma levels are predictors of mortality in COVID-19 patients. *Intern Emerg Med*. 2020;15:861–863.
79. Varga Z, Flammer AJ, Steiger P, et al. Endothelial cell infection and endotheliitis in COVID-19. *Lancet*. 2020;395:1417–1418.
80. Levi M, Scully M, Singer M. The role of ADAMTS-13 in the coagulopathy of sepsis. *J Thromb Haemost*. 2018;16:646–651.