



Contents lists available at [ScienceDirect](https://www.sciencedirect.com)

JPRAS Open

journal homepage: www.elsevier.com/locate/jpra



Short Communication

'Hands up technique': An alternative surgical setup for Brachioplasty ☆

A. Appukkuttan^{a,b,*}, R. Chukwulobelu^{a,b}, R. Ragoowansi^{a,b}

^a Department of Plastic Surgery, Barts and the London NHS Trust, London E11BB, United Kingdom

^b 101 Harley Street, London W1G6AH, United Kingdom

ARTICLE INFO

Article history:

Received 24 November 2018

Accepted 29 April 2019

Available online 17 May 2019

Keywords:

Brachioplasty

Chinese finger trap

Hands up technique

Suspended arm brachioplasty

Suspended arm brachioplasty

Arm lift

ABSTRACT

For routine brachioplasty, conventional intra-operative positioning involves abducted arms resting on two tables with the patient supine. This technique does not facilitate intra-operative comparison for symmetry and engages one assistant to hold the arm at all times. We describe a novel positioning technique for brachioplasty using Chinese finger traps and drip stands which is safe, easy to reproduce, obviates the need for a positioning assistant and facilitates symmetrical resection.

© 2019 The Authors. Published by Elsevier Ltd on behalf of British Association of Plastic, Reconstructive and Aesthetic Surgeons. This is an open access article under the CC BY-NC-ND license.

(<http://creativecommons.org/licenses/by-nc-nd/4.0/>)

Introduction

Traditional positioning for brachioplasty involves the patient supine with arms abducted and resting on arm tables. The senior author finds that this technique renders it difficult to assess the contour and symmetry of the arms peri-operatively, especially if there is no assistant. We describe an alternative positioning technique for brachioplasty using Chinese finger traps which has been safe in our hands and easy to reproduce. Our technique allows the surgeon to accurately assess the excess, reduction and tightening. It also frees up one member of the surgical team from having to support the arm

☆ Part of this article has been presented at the following meeting: British Association of Plastic, Reconstructive and Aesthetic Surgeons (BAPRAS) Winter Scientific Meeting, London, UK, 29 November 2017.

* Corresponding author at: 7 Carnforth Gardens, Elm Park, Hornchurch RM12 5DJ, United Kingdom
E-mail address: a.appukkuttan@nhs.net (A. Appukkuttan).

<https://doi.org/10.1016/j.jpra.2019.04.006>

2352-5878/© 2019 The Authors. Published by Elsevier Ltd on behalf of British Association of Plastic, Reconstructive and Aesthetic Surgeons. This is an open access article under the CC BY-NC-ND license.
(<http://creativecommons.org/licenses/by-nc-nd/4.0/>)




Figure 1. Pre-operative markings.

for the primary surgeon. This technique is probably more suitable for medial scar technique (which is used in our centre).

Technique

Exclusion criteria for the technique included patients with previous wrist or finger ligament injuries, peripheral vascular disease and arthropathy of the hand/wrist. Informed consent is obtained. Pre-operative markings are carried out as per routine (Figure 1). With the patient supine and arms resting on arm tables, the Chinese finger traps of appropriate sizes are mounted onto three or four digits. Each arm is individually suspended using a drip stand on either side (Figure 2) and the field prepped and draped (Figure 3). We use soft nylon finger traps (ARTHREX finger trap, Arthrex, Naples, Florida, US) as they are atraumatic to digital skin as opposed to the metal wire finger traps (Figure 4). Feathering liposuction (if required) and resection are performed with the arms suspended, allowing intra-operative comparison (Figure 5). Once the procedure is completed and the dressings applied, the traps are carefully removed by applying gentle axial pressure to loosen the matrix.

Results

We have used the suspension technique in 84 patients over a period of 7 years from 2010 to current. All the procedures were performed by the senior author and a large majority were carried out without an operating assistant. The preoperative preparation and draping take slightly longer than the conventional arm table only technique. The impressions of the traps on the finger disappear spontaneously over a few minutes. The majority of patients experienced an uneventful post-operative recovery with a small incidence (<3%) of minor delayed wound healing of the axillary wounds, transient numbness in medial cutaneous nerve in the forearm territory and scar hypertrophy and median nerve neuropraxia in one patient from the axillary suspension suture, which needed removal.

Comments

Many potential complications have been mentioned in literature from the use of finger traps including finger oedema, transient digital nerve neuropraxia, finger pain, finger ligament sprain and

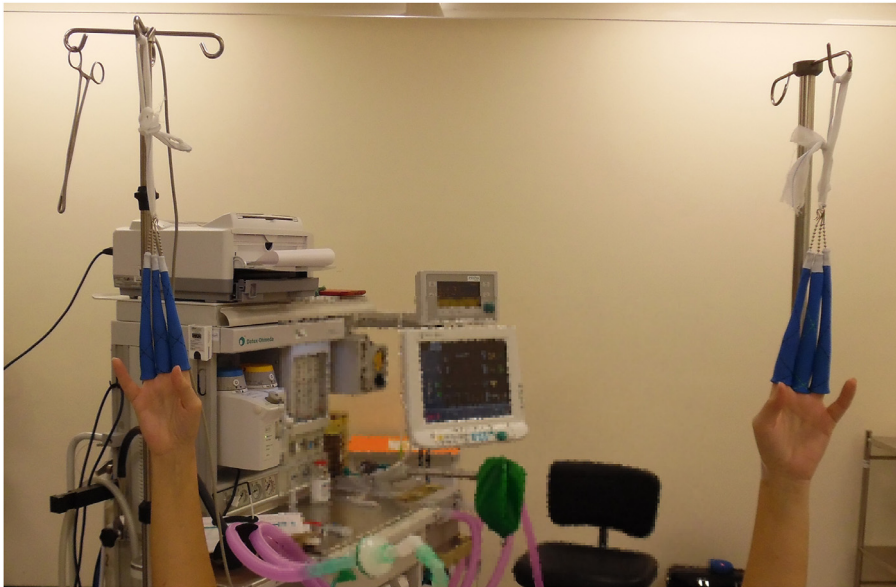

Figure 2. Arms suspended on drip stands using finger traps.

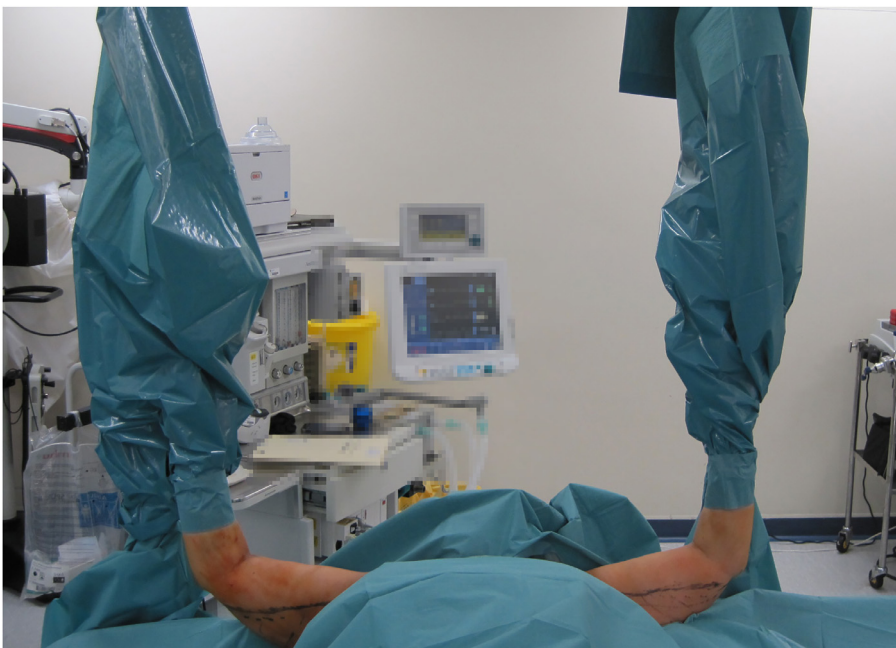

Figure 3. Draping of suspended arms and stands.

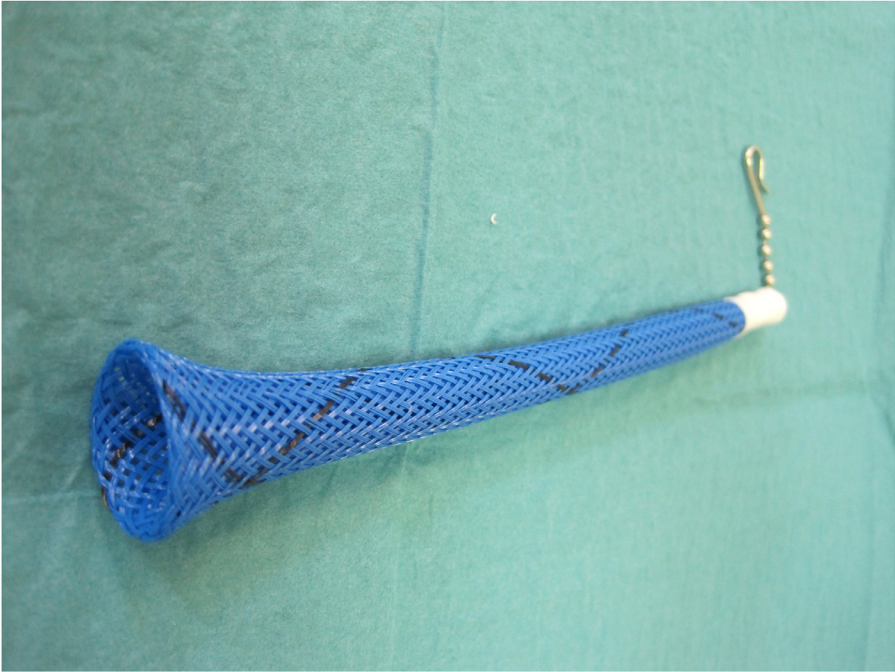


Figure 4. Nylon Chinese finger trap.

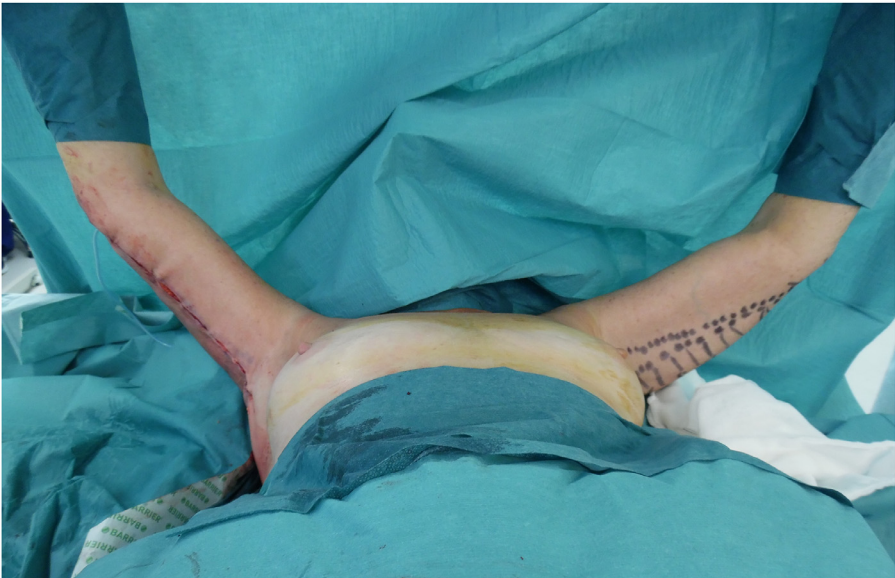


Figure 5. Intraoperative comparison of both sides.

blistering of the skin, but when combined with traction for wrist arthroscopy¹. Traction is not employed when performing brachioplasties unlike in arthroscopy and hence this risk is much lower. Use of three or four fingers instead of two has been found to be safer as it disperses the force^{2–4}. Hence we always use traps on three or four fingers and carefully select the patients. Soft flexible, nylon finger traps are preferred over metal as they provide a broad contact area and a gentle, even distribution of pressure on the skin^{2,4}. Excessive or prolonged traction has the potential to injure the ligaments of the metacarpophalangeal joints leading to stiff and swollen joints postoperatively⁵. The digital nerves of the fingers also have the potential to be injured by traction and the compression caused by tightening of the finger traps around the finger. As per literature, the traction force applied should not exceed 10 lbs to prevent these complications and some authors even recommend 7 lbs as the cut off⁵. Spurrier et al showed that even with traction, the pressure applied on the digital nerves is much lower than that thought to produce any nerve damage⁶. None of our patients have had any complications attributable to traction including digital nerve injury, skin damage or ligament injury. None of our patients had complained of post-operative pain in the fingers or hand or wrist joints from the traction.

Conclusion

The 'Hands-up technique' described by us has the advantages of allowing better intraoperative assessment of the skin redundancy and resections and to compare the two sides for symmetry of the brachioplasties without any change in position. It also obviates the need for extra assistants to position the arm during surgery and has been found to be safe in our experience.

Conflict of interest

None.

Funding

None.

References

1. Leclercq C, Mathoulin C. Complications of wrist arthroscopy: A multicenter study based on 10,107 arthroscopies. *J Wrist Surg.* 2016;5:320–326.
2. Warhold LG, Ruth RM. Complications of wrist arthroscopy and how to prevent them. *Hand Clin.* 1995;11:81–89.
3. Culp RW. Complications of wrist arthroscopy. *Hand Clin.* 1999;15:529–535.
4. De Smet L. Pitfalls in wrist arthroscopy. *Acta Orthop Belgica.* 2002;68(4):325–329.
5. Whipple TL. Precautions for arthroscopy of the wrist. *Arthroscopy.* 1990;6:3–4.
6. Spurrier E, Pathak G, Khanna A. Pressure exerted by finger traps. *J Perioper Pract.* 2011;21:140–141.