

Dexmedetomidine for an awake fiber-optic intubation of a parturient with Klippel-Feil syndrome, Type I Arnold Chiari malformation and status post released tethered spinal cord presenting for repeat cesarean section

Tanmay H. Shah, Manasi S. Badve, Kowe O. Olajide, Havyn M. Skorupan, Jonathan H. Waters, Manuel C. Vallejo

Department of Anesthesiology, Magee Womens Hospital, University of Pittsburgh Medical Center, Pittsburgh, PA, USA

Abstract

Patients with Klippel-Feil Syndrome (KFS) have congenital fusion of their cervical vertebrae due to a failure in the normal segmentation of the cervical vertebrae during the early weeks of gestation and also have myriad of other associated anomalies. Because of limited neck mobility, airway management in these patients can be a challenge for the anesthesiologist. We describe a unique case in which a dexmedetomidine infusion was used as sedation for an awake fiber-optic intubation in a parturient with Klippel-Feil Syndrome, who presented for elective cesarean delivery. A 36-year-old female, G₂P₁A₀ with KFS (fusion of cervical vertebrae) who had prior cesarean section for breech presentation with difficult airway management was scheduled for repeat cesarean delivery. After obtaining an informed consent, patient was taken in the operating room and non-invasive monitors were applied. Dexmedetomidine infusion was started and after adequate sedation, an awake fiberoptic intubation was performed. General anesthetic was administered after intubation and dexmedetomidine infusion was continued on maintenance dose until extubation. Klippel-Feil Syndrome (KFS) is a rare congenital disorder for which the true incidence is unknown, which makes it even rare to see a parturient with this disease. Patients with KFS usually have other congenital abnormalities as well, sometimes including the whole thoraco-lumbar spine (Type III) precluding the use of neuraxial anesthesia for these patients. Obstetric patients with KFS can present unique challenges in administering anesthesia and analgesia, primarily as it relates to the airway and dexmedetomidine infusion has shown promising result to manage the airway through awake fiberoptic intubation without any adverse effects on mother and fetus.

Case Report

A 36-year-old female, G₂P₁A₀ ASA physical status III, with KFS (fusion of cervical vertebrae, Figures 1 and 2) who had prior cesarean section for breech presentation, presented at 36 weeks and 6 days for repeat cesarean delivery. Her medical history included mild aortic stenosis, Arnold Chiari malformation (Figure 3), release of a tethered cord, scoliosis, right sided hearing loss, mild gastro-esophageal reflux disease, partial sacral agenesis (absence of S3-S5) and a single right sided kidney. Her surgical history was significant for correction of imperforate anus at birth, submucous cleft palate repair, release of tethered spinal cord and cesarean section for her first baby. Awake nasal fiber-optic intubation for her previous cesarean section had been difficult because of her webbed neck and decrease range of motion in the cervical spine. She was of short stature (141 cm) and weighed 71 kg. On inspection, her neck was immobile with a downward tilt of her head at a right angle and her trachea was not palpable between her chin and sternal notch. Overall, her neck was short with limited neck mobility and low hair line (Figure 1). Normal mouth opening was observed and her dentition was intact with a Mallampati class 2 airway. Lungs were clear to auscultation bilaterally and her heart had a regular rate and rhythm with mild systolic murmur noted at 2nd right intercostal space. Echocardiogram of heart showed focal calcification of the aortic valve with normal aortic valve opening and gradient with an ejection fraction greater than 65%. She was nil per os for at least 8 hours.

Informed consent was obtained for general endotracheal anesthesia and an 18 gauge peripheral intravenous catheter was placed in her left hand. Once in the operating room, she was placed supine on the operating table, her left nasal passage was topicalized with two sprays of 1% pseudoephedrine, and 10 mL of 2% lidocaine jelly was applied into the left nares. Cetacaine spray (Benzocaine 14.0 %, Butamben 2.0%, and Tetracaine Hydrochloride 2.0%) was applied to the patient's posterior pharynx. At this time, 4 liters per min of oxygen by nasal canula was applied. After the patient received a loading dose of dexmedetomidine 1 µg/kg over 10 minutes followed by a maintenance infusion of dexmedetomidine at 0.7 µg/kg/hr, the anesthesiology resident attempted nasal fiberoptic intubation but failed due to inadequate patient sedation secondary to an obstruction of the dexmedetomidine infusion. Once the obstruction was resolved, the dexmedetomidine was permitted to infuse for several minutes. A second attempt was made by the attending anesthesiologist who was also unsuccessful due to copious

Correspondence: Manuel C. Vallejo, Obstetric Anesthesia, Magee Womens Hospital, 300 Halket St., Suite 3510, Pittsburgh, PA 15213, USA. Tel. +1.412.641.4260 - Fax: +1.412.641.4766. E-mail: vallejomc@anes.upmc.edu

Key words: Klippel-Feil syndrome, dexmedetomidine, awake fiberoptic intubation, cesarean section.

Conflict of interest: the authors report no conflicts of interest.

Received for publication: 26 May 2011.
Accepted for publication: 26 July 2011.

This work is licensed under a Creative Commons Attribution NonCommercial 3.0 License (CC BY-NC 3.0).

©Copyright T.H. Shah et al., 2011
Licensee PAGEPress, Italy
Clinics and Practice 2011; 1:e57
doi:10.4081/cp.2011.e57

secretions. Glycopyrolate 0.2 mg was administered intravenous (IV). On the third attempt a 6.5 mm Parker flex™ endotracheal tube was successfully placed by an otolaryngologist who was requested to remain stand by for possible failed intubation. The airway and vocal cords were topicalized with a total of 8 mL 2% xylocaine for the intubation. After the placement of endotracheal tube, end tidal CO₂ was confirmed by capnography and bilateral breath sounds were auscultated. General anesthesia was then induced with 50 mg of propofol followed by 30 mg of rocuronium and was maintained with 4% desflurane in a 50/50 air/O₂ mixture with a dexmedetomidine infusion at 0.7 µg/kg/hr. During the loading dose and throughout the infusion of dexmedetomidine, the fetal heart rate was continuously monitored and the tracing was reassuring. Maternal heart rate, blood pressure and oxygen saturation also remained stable during the dexmedetomidine infusion. Over the course of the fiberoptic intubation the patient received a total of 2 mg midazolam in four divided doses. During intubation, the patient did not experience any coughing, desaturation, or excessive neck movements, except for mild discomfort when the intravenous dexmedetomidine infusion catheter was kinked, became obstructed and the pump alarm sounded. The patient did not have airway obstruction at this time and she went from a sleeping state (Ramsay sedation scale score of 3) to being more awake (Ramsay sedation scale of 1). Once the intravenous kink was resolved, the infusion was allowed to run for several minutes before continuation of the intubation procedure (Ramsay sedation scale score of 3). Total time from the initial intubation attempt until actual intuba-

tion was 37 min. Throughout the entire induction sequence, surgical procedure and after extubation the heart rate (range; 70-110 beats per min), respiratory rate (range; 8-10 breaths per min), systolic blood pressure (range; 118-150 mmHg), and pulse oximetry saturation (range; 99-100%) were within normal limits.

The cesarean section was uneventful. A healthy female infant with Apgar scores of 7 and 9 at 1 and 5 minutes respectively was delivered. Following placental delivery, 30 units of oxytocin was started IV as an infusion. The umbilical cord blood was sent for gas analysis. Umbilical arterial blood gas analysis revealed a pH 7.29, PCO₂ 59 mmHg and PO₂ 22 mmHg. Umbilical venous blood gas analysis revealed a pH 7.33, PCO₂ 49 mmHg and PO₂ 45 mmHg. After the baby was delivered, the patient was given 100 mcg of IV fentanyl and inhaled concentration of desflurane was decreased to 2% to prevent uterine atony. She also received 30 mg of IV ketorolac at the end of surgery for post-operative pain relief. During the procedure, the patient received 8 mg of IV dexamethasone, 10 mg of IV metoclopramide and one liter of IV fluid. At the conclusion of the case, desflurane was discontinued and when no desflurane was noted by end-tidal gas monitoring, the dexmedetomidine was reduced to 0.3 µg/kg/hr. The patient was given 5 mg of neostigmine and 0.8 mg of glycopyrrolate IV for neuromuscular reversal. Shortly after, the patient started to breathe spontaneously and started to follow commands at which point, dexmedetomidine infusion was stopped and the endotracheal tube was removed three minutes after application of the surgical dressing. The patient and newborn infant had no documented events or problems during the rest of their hospital stay and they were both discharged to home on the third post-operative day.

Discussion

We found dexmedetomidine infusion to be a highly effective approach for our patient with KFS who had a difficult airway and was not a candidate for neuraxial anesthesia due to the Arnold Chiari malformation, a history of a tethered spinal cord, and multiple back surgeries.

Klippel-Feil Syndrome is a rare disorder, first described in 1912 by Maurice Klippel and Andre Feil of which the true incidence is unknown.¹ The syndrome is characterized by congenital fusion of any 2 of the 7 cervical vertebrae and is associated with a range of other features including scoliosis, spina bifida, anomalies of the ribs and kidneys, cleft palate, respiratory problems and congenital heart defects. While the incidence of Klippel-Feil Syndrome is low, it is even less frequent to

have a parturient with the syndrome. The use of dexmedetomidine for awake fiberoptic intubation in a parturient with spinal muscular atrophy type III for cesarean delivery has been reported and they found maternal heart rate, blood pressure and oxygen saturation to remain stable without any adverse neonatal effects during the dexmedetomidine administration, which was also noted in our case.² Dresner and Maclean described the management of a Klippel-Feil patient for cesarean section using incremental dosing of a micro spinal catheter.³ In their patient, they were

worried about a total or high spinal anesthetic. If a total or high spinal had occurred, than emergent airway management would have to occur in a patient with a difficult airway due to KFS.³

In 1988, Burns *et al.* described an awake nasal fiberoptic intubation of a mother with Klippel-Feil Syndrome, increased intracranial pressure and severe pre-eclampsia who necessitated cesarean section at 33 weeks gestation.⁴ Nasal fiberoptic intubation was difficult for that patient as they were not able to pass the tracheal tube over the bronchoscope and

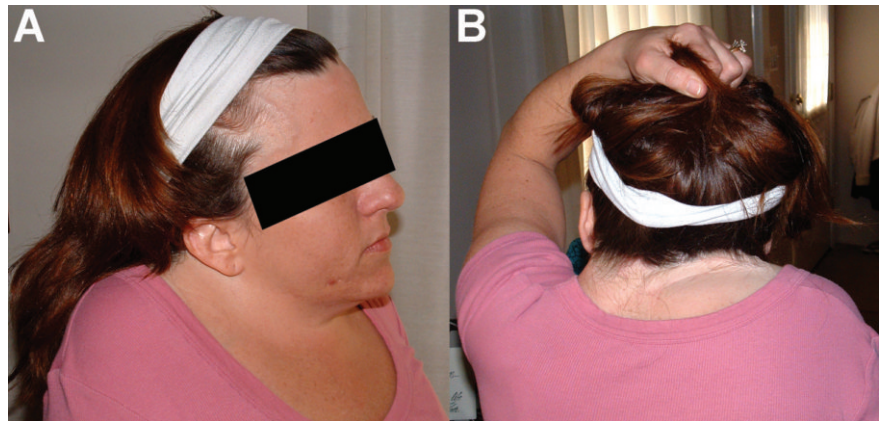

Figure 1. Photograph of patient with Klippel-Feil Syndrome. A-note webbed neck and decreased range of motion secondary to fusion of the cervical spine, B-note surgical scar further restricting range of motion.

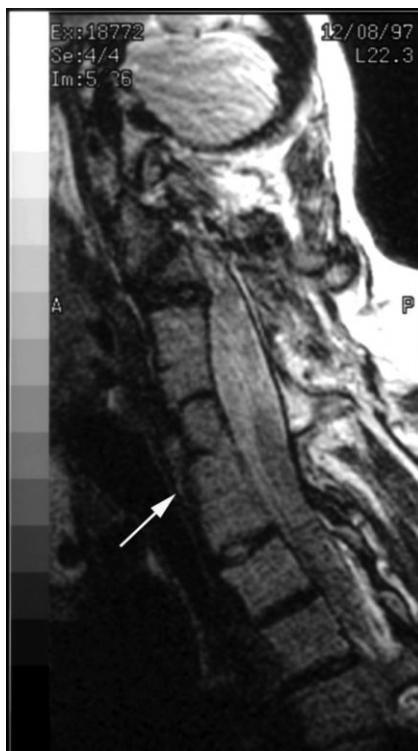


Figure 2. Magnetic resonance imaging showing fused cervical vertebrae (white arrow).

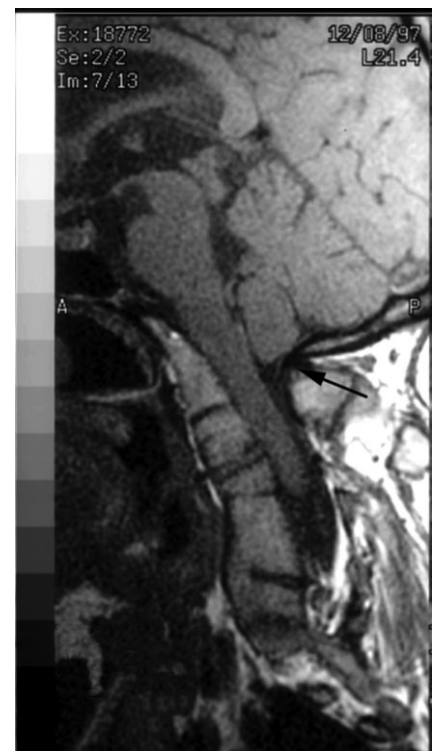

Figure 3. Magnetic resonance imaging showing tentorial herniation due to Arnold Chiari malformation (black arrow).

into the larynx even after sedation with incremental doses of midazolam. They considered it was wise to secure the airway in their patient with KFS before induction of general anesthesia in view of the predicted difficult intubation.⁴ In hindsight, a baseline neurological examination would have been helpful prior to induction of general anesthesia, however, any neurologic impairment would have been observed upon awakening after the cesarean section at which time it would have been addressed.

Dexmedetomidine is a second generation selective α_2 adrenergic receptor agonist which activates G-proteins to inhibit adenylyl cyclase eventually leading to decrease amount of cyclic adenosine monophosphate and inhibit the release of endogenous catecholamines at different adrenoceptor sites which attributes to antihypertensive, analgesic and sedative properties of dexmedetomidine. It was chosen for an awake fiber-optic intubation because of its known desirable pharmacologic properties of sedation, anxiolysis, hypnosis, analgesia and anti-sialagogue effects with a relative lack of respiratory depressant effect. With these properties, dexmedetomidine has become the drug of choice for sedation during awake intubation for critical airways and in some cases has shown to provide amnesia during awake fiberoptic intubation.⁵ The primary action is a natural sleep like sedation from which patient is easily arousable without respiratory depression, but it does not reliably produce amnesia. Smaller amounts of midazolam has been helpful during dexmedetomidine infusion to prevent patient recall and co-administration of other IV anesthetics has also shown to potentiate the effects of dexmedetomidine on cardiovascular and respiratory system.⁶ Dexmedetomidine has limited analgesic effects and may not be the ideal agent for painful procedures. If used, intravenous narcotics should be titrated for both operative and post-operative analgesia. Due to greater lipophilicity of dexmedetomidine, it has negligible placental transfer, making it the safe drug to use for parturients.⁷ If used during the normal labor, it can also reduce maternal shivering and does not reliably cause amnesia which may make the birthing experience memorable.⁷ Investigations on dexmedetomidine effects on uteroplacental physiology and fetus has shown that dexmedetomidine increases myometrial contractions in rats and isolated human myometrium, at simulated clinical concentration.^{8,9} It is a dose dependant uterotonic agent at therapeutic level, so it can also be used as adjuvant to oxytocin therapy to augment labor.^{7,10} In a comparison study between epidurally placed clonidine and dexmedetomidine, less dexmedetomidine was found in the maternal circulation and even less was found to be transferred to the fetal circulation likely due to

higher lipophilicity of the drug.¹⁰

The use of dexmedetomidine in pediatric anesthesia and critical care has been relatively commonplace for a number of years.¹¹ Dexmedetomidine is most often used in pediatrics as sedation for various procedures and diagnostic tests as well as for treatment and prophylaxis against emergence delirium.¹¹ Similar to finding in adults, many studies have found dexmedetomidine to be equal to and often superior to many other sedatives in various categories.¹¹ A population analysis of the pharmacokinetics of dexmedetomidine in patients (0-15 years) found that the clearance in neonates is approximately one third that of adults, which was consistent with immature elimination pathways (described by two-compartment disposition model) and this rate increases to near 90% that of adults by the age of one.¹² They recommend decreasing the target dose in infants and neonates.^{11,12} The appropriate dosing for sedation in a pregnant mother is much higher than the dosing for a neonate. More research is necessary to determine the exact amount of maternally administered IV dexmedetomidine that crosses the placenta and how the percentage of dexmedetomidine that crosses the placenta truly affects the fetus. Adverse effects of dexmedetomidine in neonates range from bradycardia, hypotension and decreased cardiac output which are secondary to the attenuation of plasma catecholamine release.¹¹ It has been shown to decrease the cardiac output resulting from the changes in heart rate or increased afterload and rarely it can cause sinus pause or cardiac arrest. Sometimes, it causes an initial increase in blood pressure due to stimulation of peripheral α_2B -adrenergic receptors causing vasoconstriction.¹¹ As described in our case a mild decrease in the fetal heart rate was observed but no other adverse effects were noted during or after the procedure. The lack of adverse events may have been due to a small amount of dexmedetomidine that could have crossed the placenta.

In our patient with Klippel-Feil Syndrome and a known difficult airway it was felt to be unwise to create an opportunity for the possible need for emergency airway management, especially since the trachea was not easily accessible. In this case, the properties of dexmedetomidine have provided adequate sedation without respiratory depression, which may become a problem by using higher doses of fentanyl and midazolam. In addition, dexmedetomidine also facilitated the extubation of the patient when she had no measurable inhalational agent on-board and no opioids, which could have potentially compromised her airway. The use of Dexmedetomidine provided an extra level of safety for this case and it did so without any adverse effects on the patient, delivery or infant.

References

1. Klippel M, Feil A. The classic: A case of Absence of Cervical Vertebrae with the Thoracic Cage Rising to the Base of the Cranium (Cervical Thoracic Cage). *Clin Orthop Relat Res* 1975;(109):3-8.
2. Neumann MM, Davio MB, Macknet MR, Applegate RL 2nd. Dexmedetomidine for awake fiberoptic intubation in a parturient with spinal muscular atrophy type III for cesarean delivery. *Int J Obstet Anesth* 2009;18:403-7.
3. Dresner MR, Maclean AR. Anaesthesia for caesarean section in a patient with Klippel-Feil syndrome. The use of a microspinal catheter. *Anaesthesia* 1995;50:807-9.
4. Burns AM, Dorje P, Lawes EG, Nielsen MS. Anaesthetic management of caesarean section for a mother with pre-eclampsia, the Klippel-Feil syndrome and congenital hydrocephalus. *Br J Anaesth* 1988;61:350-4.
5. Abdelmalak B, Makary L, Hoban J, Doyle DJ. Dexmedetomidine as sole sedative for awake intubation in management of the critical airway. *J Clin Anesth* 2007;19:370-3.
6. David MD, De Marchi L. Dexmedetomidine sedation for awake tracheotomy: case report and literature review. *J Clin Anesth* 2010;22:360-2.
7. Palanisamy A, Klickovich RJ, Ramsay M, et al. Intravenous dexmedetomidine as an adjunct for labor analgesia and cesarean delivery anesthesia in a parturient with a tethered spinal cord. *Int J Obstet Anesth* 2009;18:204-6.
8. Ala-Kokko TI, Pienimäki P, Lampela E, et al. Transfer of clonidine and dexmedetomidine across the isolated perfused human placenta. *Acta Anaesthesiol Scand* 1997;41:313-9.
9. Karaman S, Evren V, Firat V, Cankayali I. The effects of dexmedetomidine on spontaneous contractions of isolated gravid rat myometrium. *Adv Ther* 2006;23:238-43.
10. Sia AT, Kwek K, Yeo GS. The in vitro effects of clonidine and dexmedetomidine on human myometrium. *Int J Obstet Anesth* 2005;14:104-7.
11. Tobias JD. Dexmedetomidine: applications in pediatric critical care and pediatric anesthesiology. *Pediatr Crit Care Med* 2007;8:115-31.
12. Potts AL, Warman GR, Anderson BJ. Dexmedetomidine disposition in children: a population analysis. *Paediatr Anaesth* 2008;18:722-30.