

The Feasibility of Natural Orifice Transluminal Endoscopic Surgery in Gynecology Practice: Single-Surgeon Experience

Cihan Kaya, Ismail Alay*, Sukru Yildiz, Huseyin Cengiz, Xalide Afandi, Levent Yasar

Department of Obstetrics and Gynecology, Bakirkoy Dr. Sadi Konuk Training and Research Hospital, University of Health Sciences, Istanbul, Turkey

Abstract

Objectives: Natural orifice transluminal endoscopic surgery (NOTES) has been performed in gynecology practice for the surgical treatment of ovarian cysts, uterine fibroids, ectopic pregnancies, adnexal masses, and pelvic organ prolapse. The aim of this study is to evaluate the intraoperative and postoperative outcomes of patients who underwent NOTES for gynecological diseases.

Materials and Methods: This study was a retrospective clinical study. The data of 50 patients who had been treated via NOTES procedure for benign gynecological indications such as ectopic pregnancy, adnexal mass, uterine fibroid, and treatment-resistant heavy menstrual bleeding during the time period between January 2016 and 2019 were included. All procedures were performed by a single surgeon (C.K.) using a self-constructed glove port, and a sealing device in addition to conventional laparoscopic (CL) equipment. Descriptive analysis of the patients' data was performed.

Results: The initial two of the adnexectomy procedures were performed via hybrid NOTES technic and four of them were performed via total vaginal NOTES technic. The remaining procedures, namely hysterectomies, adnexectomies, salpingectomies, and myomectomy were performed via vaginally assisted NOTES (VaNOTES) technic. The mean operation time for the hysterectomy ± bilateral salpingo-oophorectomy (BSO) and salpingo-oophorectomy patients was 85.25 min and 53.15 min, respectively. For those patients who underwent VaNOTES procedure, the median postoperative visual analog scale pain score at the 6th h was six and at the 24th h was two. The mean length of the hospital stay was 2.07 days in the hysterectomy ± BSO patients and 1.63 days in the salpingo-oophorectomy patients.

Conclusion: The NOTES procedure is a feasible technic in regards to the duration of surgery, postoperative pain scores, and cosmetic outcomes.

Keywords: Gynecology, hysterectomy, laparoscopy, natural orifice transluminal endoscopic surgery, salpingectomy

INTRODUCTION

Advances in laparoscopic skills have enabled minimally invasive surgical procedures to be performed in daily gynecology practice. Compared to conventional multiple-port laparoscopic procedures, single-incision surgeries have advantages in favor of cosmetic appearance, decreased port site pain, and lesser duration of surgeries.^[1] Up to now, as a less invasive procedure, natural orifice transluminal endoscopic surgery (NOTES) has been performed in gynecology practice for the surgical treatment of ovarian

cysts, intramural uterine fibroids, ectopic pregnancies, adnexal masses, and pelvic organ prolapse.^[2,3]

Having the advantage of endoscopic procedures such as magnifying the surgical area by optical systems, enabling the surgeon a sitting position during the surgery, improved cosmetic outcomes, and decreased umbilical or port site hernia rates, NOTES procedures have better outcomes compared to conventional laparoscopic (CL) and open surgeries.^[1,4]

Article History:

Submitted: 5 August 2019

Revised: 10 September 2019

Accepted: 1 October 2019

Published: 28 April 2020

Access this article online

Quick Response Code:



Website:
www.e-gmit.com

DOI:
10.4103/GMIT.GMIT_84_19

Address for correspondence:

Dr. Ismail Alay,
Tevfik Saglam, Str No 11, Zuhuratbaba, Bakirkoy, Istanbul, Turkey.
E-mail: dr_ismailalay@hotmail.com

This is an open access journal, and articles are distributed under the terms of the Creative Commons Attribution-NonCommercial-ShareAlike 4.0 License, which allows others to remix, tweak, and build upon the work non-commercially, as long as appropriate credit is given and the new creations are licensed under the identical terms.

For reprints contact: reprints@medknow.com

How to cite this article: Kaya C, Alay I, Yildiz S, Cengiz H, Afandi X, Yasar L. The feasibility of natural orifice transluminal endoscopic surgery in gynecology practice: Single-surgeon experience. *Gynecol Minim Invasive Ther* 2020;9:69-73.

A recently published randomized controlled study comparing total laparoscopic hysterectomy (TLH) and NOTES hysterectomies to treat uterine pathologies has concluded that NOTES technic may be comparable to TLH.^[5]

However, there is still a lack of evidence and less cumulative data on the feasibility, intraoperative complication rates, postoperative pain scores, dyspareunia rates, and duration of surgery of NOTES procedures in gynecologic practice.

Therefore, in this report, we aimed to declare our initial experience of 50 NOTES procedures for the treatment of benign gynecological diseases.

MATERIALS AND METHODS

The study was comprised of 50 patients who were surgically treated via NOTES technic for various gynecological indications such as ectopic pregnancy, adnexal mass, uterine fibroid, and treatment-resistant heavy menstrual bleeding in our department during the time period between January 2016 and 2019. The ethical approval was obtained from the local institutional ethics committee (Approval number: 2019-04-27). The written informed consent was obtained from participants. All of the procedures were performed by the same surgeon (C.K.) who is experienced in laparoscopic surgery. The surgical procedures were performed for the women who had no contraindication for pneumoperitoneum or the Trendelenburg position. The patients with the presence of sacrouterine nodularity on bimanual pelvic examination, tubo-ovarian abscess, endometriosis, intrauterine pregnancy, history of colorectal surgery or pelvic inflammatory disease, and suspicion of any pelvic organ malignancy were excluded from the study. The medical and surgical data of the study population such as: age, weight, height, body mass index (BMI), gravidity, parity, number, type, and indication of previous abdominal or pelvic surgeries, mean dimension of the mass on pelvic ultrasound, duration of anterior and/or posterior colpotomy, duration of total surgery, uterine weight, preoperative and postoperative hemoglobin (Hb), hematocrit (Hct), decrease of Hb/Hct levels, presence of peri-/post-operative complications, duration of hospital stay, Visual Analog Scale (VAS) scores at postoperative 6th and 24th h, and final pathology results were retrospectively analyzed. The duration of anterior/posterior colpotomy was recorded as from the initiation of a cervical incision to the point of accessing the abdominal cavity. The total duration of surgery was defined as the time from the grasping of the cervical tenaculum to the end of closure of the colpotomy defect. Perioperative complications were defined as major bowel, bladder, ureteral, or major vascular injuries and total blood loss over 300 mL. Postoperative complications were considered as the presence of bowel obstruction, bleeding or infection from the vaginal cuff, and pelvic abscess or hematoma.

Postoperative pain scores were evaluated with a Likert type VAS (scoring from 0 = no pain to 10 = worst pain ever) after 6th and 24th h postoperatively. Prophylactic antibiotic therapy with a 2 g of I.V. cefazolin was induced 30 min before the surgeries. Each patient was booked for a postoperative control after the 1st and 4th weeks of the surgery.

Surgical procedures

Anterior and/or posterior colpotomy was performed in the dorsal lithotomy position under general anesthesia. After identification of the cervix with vaginal retractors, the anterior lip was grasped and moved upward/downward with a tenaculum forceps to achieve anterior/posterior colpotomy. A 2–3 cm cervical incision was performed with an 11-mm scalpel and/or cautery. For the anterior/posterior colpotomy, the vaginal mucosa was pushed with blunt and sharp dissections along with the cervical fascia. Once the peritoneum was identified, it was opened and enlarged with a scissor. Both anterior and posterior colpotomies were performed for hysterectomy cases and only a posterior colpotomy was performed for the treatment of adnexal pathologies and ectopic pregnancies. A self-constructed glove port was inserted through the colpotomy openings into the abdominal cavity as described in our previous report.^[6] A small-sized Alexis Wound Protector/Retractor (Applied Medical, Rancho Santa Margarita, CA, USA) was used for vaginally assisted NOTES (VaNOTES) hysterectomy cases and a X small-sized wound retractor was used for adnexectomy procedures. After achieving pneumoperitoneum/pneumovagina with 12 mmHg CO₂ insufflation, a 10-mm rigid 0° telescope was then inserted for optical imaging (Karl Storz visualization system; Karl Storz Tuttlingen, Germany) for hysterectomy cases and a 10-mm telescope 30° telescope was used for the treatment of adnexal pathologies. Disposable CL grasping forceps and tissue sealing device were used as standard equipment. A suction-irrigation device was used where needed. Hybrid NOTES technic which is a modified natural orifice surgery technic combining with transabdominal assistance with an umbilical optic port or accessory trocar was performed in cases with advanced adhesions or restricted visualization.^[7] After exploration of the abdominal and pelvic organs, in hysterectomy cases, both of the sacrouterine ligaments, uterine arteries, and adnexal roots were sealed and cut. For the treatment of adnexal pathologies infundibulopelvic ligaments were sealed and cut. The uterus and adnexa were extracted through the vaginal opening. An Endobag was used for removal/in bag aspiration of adnexal masses. To perform NOTES-assisted myomectomy, the uterine serosa was incised with a reusable monopolar hook and grasped and dissected by conventional equipment. After morcellation and extraction of the uterine fibroid, the uterine defect was sutured

vaginally after NOTES port removal. The vaginal opening was closed with a vicryl 1-0 suture (Ethicon, Piscataway, NJ, USA) after all of the procedures [Figure 1a-d].

Statistical analysis

Data analysis was performed with SPSS (IBM SPSS Statistics for Windows, Version 20.0. Armonk, NY: IBM Corp., USA). The frequency and percentage values of the categorical variables and the mean, standard deviation, and range values of the continuous variables were presented.

RESULTS

Fifty cases had been surgically treated via NOTES technic during the time period reviewed. The initial two operations were performed via hybrid NOTES technic and four of the hysterectomies were performed via total vaginal NOTES (TVNOTES) technic and the remaining procedures were performed via VaNOTES technic. The following are the mean values for each variable of the patients who had undergone hysterectomy ± bilateral salpingo-oophorectomy (BSO); age: 51.75 ± 8.06 years (range, 41–72 years), BMI: 31.71 ± 8.35 kg/m² (range, 22–54 kg/m²), uterine weight: 298.07 ± 208.42 g (range, 102–786 g), size of uterus: 10.14 ± 2.11 weeks (range, 8–16 weeks), duration of surgery: 85.25 ± 34.31 min (range, 40–170 min.), decrease of Hb: 1.28 ± 1.11 (range, 1–4 g/dL) g/dL, blood loss: 90.45 ± 106.03 cc (range, 25–500 cc), hospital stay: 2.07 ± 0.89 (range, 1–4 days) days, postoperative 6th h VAS score: 6 ± 0.5 (range, 4–8), and postoperative 24th h VAS score: 2 ± 1.28 (range, 2–4). Fifteen patients had BSO in addition to hysterectomy, and the remaining 13 patients had only hysterectomy.

The following are the mean values for each variable of the patients who were treated for adnexal pathologies such as ovarian mass or ectopic pregnancies; age:

43.76 ± 11.01 years (range, 19–66 years), BMI: 32.74 ± 9.91 kg/m² (range, 20–54 kg/m²), size of mass: 70.29 ± 19.07 mm (range, 40–120 mm) duration of surgery: 53.15 ± 34.60 (range, 25–120) min for adnexal masses and 31.25 ± 5.51 (range, 25–39) min for ectopic pregnancy, decrease of Hb: 1.66 ± 0.79 (range, 1–4) g/dL, blood loss: 60.88 ± 34.11 cc (range, 20–150 cc), hospital stay: 1.63 ± 0.68 (1–3) days, postoperative 6th h VAS score: 5 ± 1.45 (range, 3–8), and postoperative 24th h VAS score: 2 ± 0.51 (range, 0–3). Four patients had salpingectomies due to ruptured ectopic pregnancy, and the remaining 17 patients had uni/BSO procedures. Tables 1 and 2 present an overview of the patient and perioperative and postoperative data with hysterectomy ± BSO and adnexectomy procedures. Only one conversion to a standard multi-incision laparoscopy was required due to intraoperative diagnosis of endometrioma

Table 1: Patients' basic characteristics and surgical outcomes of hysterectomy±bilateral salpingo-oophorectomy and adnexectomy cases

	Mean±SD (range)	
	Hysterectomy +/- BSO (n=28)	Adnexectomy (n=21)
Age (years)	51.75±8.06 (41-72)	43.76±11.01 (19-66)
Gravidity	3.07±1.76 (1-9)	3.64±2.08 (2-9)
Parity	2.78±1.34 (1-7)	2.61±1.62 (0-7)
BMI (kg/m ²)	31.71±8.35 (22-54)	32.74±9.91 (20-54)
Dimension of the mass (mm)		
Uterine fibroid	65.31±14.54 (41-93)	N/A
Adnexal mass	N/A	70.29±19.07 (40-120)
Ectopic pregnancy	N/A	31.25±5.96 (27-40)
Number of previous abdominal surgery	0±0.83 (0-3)	0±1.05 (0-3)
Preoperative Hb (g/dL)	11.28±1.99 (8-15)	12±1.76 (9-15)
Preoperative Hct (%)	33.5±4.05 (27-42)	35.11±3.35 (30-41)
Decrease of Hb	1.28±1.11 (1-4)	1.66±0.79 (1-4)
Decrease of Hct	2.42±2.64 (3-6)	3.19±2.31 (2-8)
Colpotomy time (min)	13.61±9.11 (4-45)	5.84±2.77 (2-15)
Duration of surgery (min)	85.25±34.31 (40-170)	53.15±34.61 (25-120)
Uterine weight (g)	298.07±208.42 (102-786)	N/A
Uterine size (week)	10.14±2.11 (8-16)	N/A
Postoperative Hb (g/dL)	10±1.74 (7-13)	10.47±1.58 (8-13)
Postoperative Hct (%)	31.01±2.77 (27-36)	32.23±3.36 (26-38)
Duration of hospital stay (days)	2.07±0.89 (1-4)	1.63±0.68 (1-3)
Blood loss (cc)	90.45±106.03 (25-500)	60.88±34.11 (20-150)
Postoperative 6 th hour VAS score	6±0.5 (4-8)	5±1.45 (3-8)
Postoperative 24 th hour VAS score	2±1.28 (2-4)	2±0.51 (0-3)

BSO: Bilateral salpingo-oophorectomy, BMI: Body mass index, Hb: Hemoglobin, Hct: Hematocrit, VAS: Visual analog scale, N/A: Not available

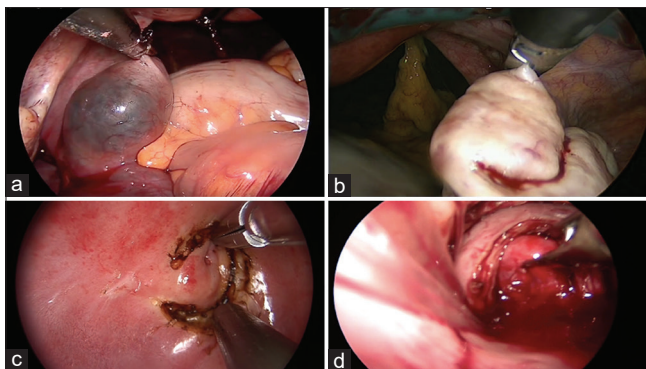


Figure 1: The figure demonstrates gynecological procedures performed via natural orifice transluminal endoscopic surgery technic. (a) A right tubal ectopic pregnancy. (b) A left adnexectomy procedure. (c) Total vaginal natural orifice transluminal endoscopic surgery hysterectomy procedure. (d) Natural orifice transluminal endoscopic surgery-assisted myomectomy procedure

Table 2: Type and indications of previous and present abdominal surgeries and final pathology results of hysterectomy ± bilateral salpingo-oophorectomy and adnexectomy cases

	Hysterectomy +/- BSO, n (%)	Adnexectomy, n (%)
Type of previous incision		
Pfannenstiel	6 (66.4)	4 (58)
McBurney	1 (11.1)	0
Umbilical	1 (11.1)	1 (14)
Midline	0	1 (14)
Subcostal	1 (11.1)	1 (14)
Indication of previous surgery		
Cesarean section	6 (66.4)	4 (58)
Appendectomy	1 (11.1)	0
Cholecystectomy	1 (11.1)	1 (14)
Umbilical hernia	1 (11.1)	1 (14)
Pelvic mass	0	1 (14)
Indication of present surgery		
HMB	23 (82.1)	0
Pelvic mass	2 (7.2)	17 (81)
Ectopic pregnancy	0	4 (19)
Pelvic pain	3 (10.7)	0
Final pathology		
Dermoid cyst	1 (3.6)	8 (38)
Simple serous cyst	0	6 (30)
Ectopic pregnancy	0	4 (19)
Endometrioma	0	1 (4)
Fibrothecoma	0	2 (9)
Uterine fibroid	14 (50)	0
Adenomyosis	8 (28.6)	0
Endometrial hyperplasia	5 (17.9)	0

BSO: Bilateral salpingo-oophorectomy, HMB: Heavy menstrual bleeding

and dense pelvic adhesions. Two patients had more than 300 cc blood loss and required postoperative I.V. blood transfusion.

In addition to the cases mentioned above, 1 patient had NOTES-assisted vaginal myomectomy to treat a 9-cm intramural uterine fibroid located in the posterior uterine wall. The procedure was last for 87 min. There were no vaginal wound infections or dehiscence in total, and no patients reported any pelvic pain or dyspareunia during their postoperative visits.

DISCUSSION

Up to now, NOTES surgery has been neglected by most of the gynecologic surgeons despite their familiarity with the pelvic anatomy. This could be attributed to less experience in vaginal surgeries in the era of abdominal laparoscopic surgeries and lack of accumulated evidence about the NOTES procedure, since it is only performed by a few institutions for the treatment of gynecologic diseases.^[8,9]

To clarify the feasibility of NOTES hysterectomy procedures, recently, Baekelandt *et al.* had published the first randomized controlled study comparing 35 patients treated conventional TLH to 35 NOTES hysterectomy.^[5] In this study, the uterine weight was similar between the study groups (177 vs. 206 g), and they found that NOTES procedure was with shorter hospital stay (0.8 vs. 1.3 days), lesser duration of surgery (41 vs. 75 min), and decreased total use of analgesics (8 vs. 14 units) compared to TLH.^[5] In another study by Su *et al.* reported the data of 16 hysterectomies that were completed via transvaginal NOTES and no conversion to conventional laparoscopy was observed.^[10] In this study, the mean uterine weight, operative time, blood loss, and postoperative hospital stay was 538.8 ± 102.9 g, 122.7 ± 17.6 min, 379.4 ± 95.4 mL, and 2.8 ± 0.2 days, respectively.^[10] Although they reported no intraoperative or postoperative complications, four patients required blood transfusion.^[10] In another study, Lee *et al.* reported the largest hysterectomy series with 137 patients treated with transvaginal NOTES technique.^[4] In their series, 94.9% ($n = 130$) of the patients were successfully treated via planned surgical route, with the mean operative time and hospital stay as 88.2 ± 4.1 min and 2.8 days, respectively.^[4] In this study, the mean uterine weight was 450.0 ± 24.1 g. Two patients had complications including intraoperative hemorrhage and cystotomy, five had transvaginal colpotomy failure and ten patients required a blood transfusion.^[4] In our study, we performed 28 hysterectomy ± BSO procedures and the mean duration of surgeries was around 85 min which was quite similar to the study by Lee *et al.* However, Baekelandt *et al.* reported shorter duration of surgeries and that might be explained with being familiar with the procedure.^[4,5] The mean uterine weight was also higher in our study group (298.07 ± 208.42 g). In our series, only two patients had more than 300 cc blood loss and required postoperative blood transfusion, and these cases were with huge uterus (>700 g).

In regards to NOTES procedures for adnexal masses, Lee *et al.* reported ten consecutive patients who underwent transvaginal NOTES for adnexal pathologies.^[11] In this report, three patients had tubal sterilization, three patients had salpingectomy due to ectopic pregnancy, and four patients were treated for the presence of ovarian mass. Nine out of the ten procedures were completed via planned NOTES technic. The overall duration of the surgical procedures varied between 18 and 162 min.^[11] In another study, by Ahn *et al.* performed ten transvaginal NOTES procedures for treatment of benign uterine adnexal diseases.^[12] They reported that the mean operation time was decreased with experience from 67.5 to 55 min for simple cystectomies and 62.5 min for complicated cases.^[12] Yang *et al.* also reported their experience on transvaginal NOTES procedures for the treatment of seven patients with adnexal masses.^[13] They observed neither

intraoperative complication nor conversion to conventional laparoscopy. In their study, the median mass size was 6 cm and the mean operative time was 45 min. The decrease in Hb was about 1.6 g/dL.^[13] In our study, we performed 21 NOTES procedures to treat a variety of adnexal pathologies and the mean duration of the surgery was around 53 min which was comparable with the previous reports.^[12,13] We might clearly speculate that considering the size and the complexity of the adnexal mass, the duration of the surgeries may vary. In our series, the initial two operations were performed via hybrid NOTES technic due to less experience and one conversion to standard multi-incision laparoscopy was required due to the presence of endometrioma and dense pelvic adhesions.

Another utilization area of the NOTES procedure is to treat extrauterine pregnancies.^[14] For that purpose, Baekelandt *et al.* had defined an IMELDA approach for the treatment of pregnancies with an unknown location in 15 patients beginning with transvaginal hydrolaparoscopy and successfully performed salpingectomies in 12 patients via TVNOTES technic.^[14] In another series by Lee *et al.*, they reported three salpingectomies because of ectopic pregnancy with the mean operative time varying between 62 and 116 min.^[11] In our study, four patients had salpingectomy due to ruptured ectopic pregnancy and the mean operative time was 31 min and no conversion was required.

Finally, Baekelandt *et al.* had reported the feasibility of NOTES procedure to treat uterine fibroids in eight cases, and all cases were successfully treated via VaNOTES technic and no complications or conversions to standard laparoscopy was observed.^[15] They had concluded that treatment of type 3–7 uterine fibroids via NOTES technic could be a new minimally invasive approach to other conventional endoscopic procedures.^[15] In our study, we performed a NOTES assisted vaginal myomectomy to treat a 9-cm intramural uterine fibroid located in the posterior uterine wall. The duration of the procedure was 87 min, and the uterine defect was closed through the vaginal opening in a conventional manner due to excessive bleeding that restraining visualization.

The limitation of VNOTES procedure is having the lack of triangulation and the clashing of the instruments which is called “chopsticks effect” during the surgical procedure due to less movement capability compared to conventional laparoscopy.^[16] To overcome this problem, the access platforms and instruments which are used in VNOTES procedures need to be improved. The caudal-cranial exploration of the pelvic cavity and adapting CL skills to NOTES procedures require an educational and learning curve period.

CONCLUSION

To sum up, NOTES procedures could be used for the treatment of a variety of gynecological diseases. Although

these findings are from our initial experience, by advancing the clinical experience and equipment of the procedure, we might speculate that NOTES surgeries might be taking place CL with better surgical outcomes in the near future.

Financial support and sponsorship

Nil.

Conflicts of interest

There are no conflicts of interest.

REFERENCES

1. Baekelandt J, De Mulder PA, Le Roy I, Mathieu C, Laenen A, Enzlin P, *et al.* Postoperative outcomes and quality of life following hysterectomy by natural orifice transluminal endoscopic surgery (NOTES) compared to laparoscopy in women with a non-prolapsed uterus and benign gynaecological disease: A systematic review and meta-analysis. *Eur J Obstet Gynecol Reprod Biol* 2017;208:6-15.
2. Yoshiki N, Okawa T, Kubota T. Hybrid transvaginal and transumbilical laparoendoscopic adnexal surgery. *J Laparoendosc Adv Surg Tech A* 2012;22:992-5.
3. Liu J, Kohn J, Sun B, Guan Z, Liang B, Guan X. Transvaginal natural orifice transluminal endoscopic surgery sacrocolpopexy: Tips and tricks. *J Minim Invasive Gynecol* 2019;26:38-9.
4. Lee CL, Wu KY, Su H, Wu PJ, Han CM, Yen CF. Hysterectomy by transvaginal natural orifice transluminal endoscopic surgery (NOTES): A series of 137 patients. *J Minim Invasive Gynecol* 2014;21:818-24.
5. Baekelandt JF, De Mulder PA, Le Roy I, Mathieu C, Laenen A, Enzlin P, *et al.* Hysterectomy by transvaginal natural orifice transluminal endoscopic surgery versus laparoscopy as a day-care procedure: A randomised controlled trial. *BJOG* 2019;126:105-13.
6. Kaya C, Alay İ, Ekin M, Yaşar L. Hysterectomy by vaginal-assisted natural orifice transluminal endoscopic surgery: Initial experience with twelve cases. *J Turk Ger Gynecol Assoc* 2018;19:34-8.
7. Terzi H, Turkay U, Uzun ND, Sahıcı M. Hysterectomy and salpingo-oophorectomy by transvaginal natural orifice transluminal endoscopic surgery (V-NOTES) assisted by an umbilical camera: Case report and new hybrid technique in gynecology. *Int J Surg Case Rep* 2018;51:349-51.
8. Baekelandt J. Total vaginal NOTES hysterectomy: A New approach to hysterectomy. *J Minim Invasive Gynecol* 2015;22:1088-94.
9. Yang YS, Kim SY, Hur MH, Oh KY. Natural orifice transluminal endoscopic surgery-assisted versus single-port laparoscopic-assisted vaginal hysterectomy: A case-matched study. *J Minim Invasive Gynecol* 2014;21:624-31.
10. Su H, Yen CF, Wu KY, Han CM, Lee CL. Hysterectomy via transvaginal natural orifice transluminal endoscopic surgery (NOTES): Feasibility of an innovative approach. *Taiwan J Obstet Gynecol* 2012;51:217-21.
11. Lee CL, Wu KY, Su H, Ueng SH, Yen CF. Transvaginal natural-orifice transluminal endoscopic surgery (NOTES) in adnexal procedures. *J Minim Invasive Gynecol* 2012;19:509-13.
12. Ahn KH, Song JY, Kim SH, Lee KW, Kim T. Transvaginal single-port natural orifice transluminal endoscopic surgery for benign uterine adnexal pathologies. *J Minim Invasive Gynecol* 2012;19:631-5.
13. Yang YS, Hur MH, Oh KY, Kim SY. Transvaginal natural orifice transluminal endoscopic surgery for adnexal masses. *J Obstet Gynaecol Res* 2013;39:1604-9.
14. Baekelandt J, Vercammen J. IMELDA transvaginal approach to ectopic pregnancy: Diagnosis by transvaginal hydrolaparoscopy and treatment by transvaginal natural orifice transluminal endoscopic surgery. *Fertil Steril* 2017;107:e1-2.
15. Baekelandt J. Transvaginal natural-orifice transluminal endoscopic surgery: A new approach to myomectomy. *Fertil Steril* 2018;109:179.
16. Franssen SA, van den Bos J, Stassen LP, Bouvy ND. Is single-port laparoscopy more precise and faster with the robot? *J Laparoendosc Adv Surg Tech A* 2016;26:898-904.