

Case Report

Adenine phosphoribosyltransferase (APRT) deficiency: a new genetic mutation with early recurrent renal stone disease in kidney transplantation

Vanna Micheli¹, Fabio Massarino², Gabriella Jacomelli¹, Matteo Bertelli⁵, Maria Rita Corradi¹, Andrea Guerrini¹, Antonino Cucchiara³, Jean Louis Ravetti⁴, Laura Negretti³ and Giuseppe Cannella²

¹Dipartimento di Biologia Molecolare, Università di Siena, Via Fiorentina 1, Siena, Italy, ²Divisione di Nefrologia, Dialisi e Trapianto, Azienda Ospedaliera Universitaria S. Martino, L.go R. Benzi 10, Genova, Italy, ³Dip. Te. Ris., Università di Genova, V.le Benedetto XV 5, Genova, Italy, ⁴Div. di Anatomia Patologica, Azienda Ospedaliera Universitaria S. Martino, L.go R. Benzi 10, Genova, Italy and ⁵International Association of Medical Genetics (MAGI-onlus), Via delle Grazie 3, Rovereto (TN), Italy

Correspondence and offprint requests to: Vanna Micheli; E-mail: micheli@unisi.it

Abstract

Adenine phosphoribosyltransferase (APRT) deficiency, a rare inborn error inherited as an autosomic recessive trait, presents with 2,8-dihydroxyadenine (2,8-DHA) crystal nephropathy. We describe clinical, biochemical and molecular findings in a renal transplant recipient with renal failure, 2,8-DHA stones and no measurable erythrocyte APRT activity. Homozygous C>G substitution at -3 in the splicing site of exon 2 (IVS2 -3 c>g) was found in the APRT gene. The patient's asymptomatic brother was heterozygous for such mutation, and his APRT activity was 23% of controls. A splicing alteration leading to incorrect gene transcription and virtually absent APRT activity is seemingly associated with the newly identified mutation.

Keywords: APRT deficiency; gene mutation; nephrolithiasis; renal transplantation

Background

Adenine phosphoribosyltransferase (APRT, E.C. 2.4.2.7) catalyses adenine conversion to AMP accomplishing the elimination of free adenine derived from the diet or released as a waste product of the polyamine pathway [1]. APRT deficiency is a rare inborn error causing the accumulation of adenine which is excreted as such or after conversion into its poorly soluble metabolites, 8-OH-adenine and 2,8-OH adenine (2,8-DHA), catalysed by xanthine oxidase.

The APRT gene is located on chromosome 16 (16q24), and the deficiency is inherited as an autosomic recessive trait. The deficiency may remain completely asymptomatic (heterozygosity) or may present with severe renal failure due to 2,8-DHA deposition with stone formation and chronic obstruction (homozygosity). Two types of homozygotes with various different mutations have been described, with either virtually undetectable (type 1) or detectable

(type 2) erythrocyte activity [1]. Provided APRT deficiency is recognized early, renal failure can be prevented, arrested or reversed by treatment with allopurinol which inhibits xanthine oxidase, thus reducing 2,8-DHA formation [2]. The diagnosis can be performed by analysis of renal stones and assay of APRT activity in erythrocytes.

Case report

The patient described in this report is a 48-year-old Caucasian man with renal failure and a history of recurrent renal staghorn lithiasis on both sides, revealed by ultrasonography, since the age of 17. No familial cases of lithiasis were reported. Recurrences occurred every 2–3 years, always on the right side; crystal analysis was not performed. The patient did not receive any pharmacological therapy and underwent extracorporeal shock wave lithotripsy treatment on the right kidney at the age of 20. His serum creatinine worsened with time (2.0 mg/dL at 30 years up to 4.5 mg/dL at 41 years), and haemodialysis was started at the age of 42. After 1 year, he became anuric and received a renal transplant from a deceased donor. Triple immunosuppressive therapy (tacrolimus, mycophenolate mofetil and steroid) was administered; neither dehydration nor acute rejection ever occurred. Soon after, he regained good renal function, and at discharge, his serum creatinine was 1.8 mg/dL. Two weeks after transplantation, he suffered from a renal colic, and during the following month, his serum creatinine rose to 3.0 mg/dL. A kidney biopsy, never executed before, was performed and disclosed interstitial crystal deposition with diffuse intratubular crystal cast formations (Figures 1 and 2). Two weeks later, the patient passed small stones in the urine two more times. Analysis of renal stones by analytical X-ray diffraction software showed that they were composed of 6-amino-2,8(3,9)-purenidione (C₅H₅N₅O₂ or 2,8-DHA), suggesting




Fig. 1. Scanning of the renal 2,8-DHA calculus by electron microscope (magnification $\times 216$). High-definition view of crystals inside the calculus on the right upper panel.

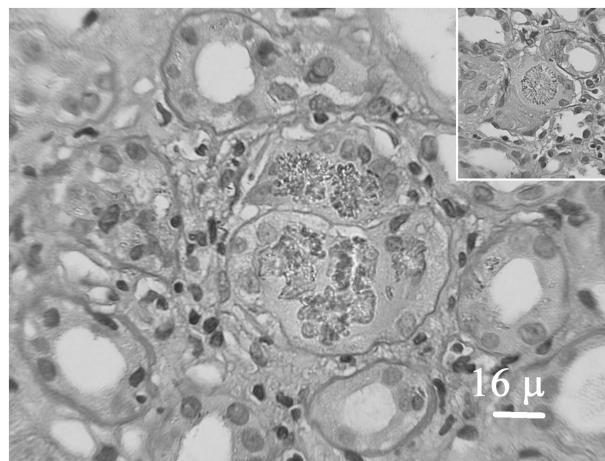


Fig. 2. High-power view of renal biopsy showing crystals of 2,8-DHA in tubular lumen (PAS, magnification $\times 600$) and inside an interstitial multinuclear giant cell (right upper panel).

APRT deficiency. Hence, allopurinol therapy was started, with high fluid intake and low-protein diet. Two further renal colics occurred in the following months. Serum creatinine gradually fell to the present value of 2.0 mg/dL, and ultrasonography disclosed only a few small calcification plaques at the medullopapillary junction in the transplanted kidney, with no evidence of nephrocalcinosis.

Diagnostic protocol for APRT deficiency was performed in the patient and in his asymptomatic 44-year-old brother, including biochemical and molecular investigations in the blood and detection of adenine and its metabolites in urine samples. Blood and urine samples from the proband and his brother were obtained as part of the treatment programme, and thus, ethical committee approval was not required.

Previously described HPLC-linked methods were used for all the biochemical assays: plasma and urine metabolites were detected and quantified; APRT activity was measured in lysates and in intact erythrocytes, the latter following the conversion of ^{14}C -adenine into nucleotides [3]. Control range for all the parameters measured in the patient was provided by analysis of blood and urine samples from 50 healthy adult voluntary donors.

Genomic DNA was obtained from whole blood by conventional methods (QIAamp DNA Mini kit, QIAGEN GmbH, Germany), and amplification of the APRT gene was carried out by PCR. Purified PCR products were directly sequenced with an automated 3730xl DNA Analyser. Total RNA was also extracted from whole blood by conventional methods (QIAamp RNA blood Mini kit, QIAGEN GmbH, Germany) and reverse-transcribed by the random hexamer method; cDNA was amplified by PCR, and purified products were sequenced.

APRT activity was undetectable in both lysates and intact erythrocytes from the patient, thus suggesting type I APRT deficiency [2]; the activity was low in the brother's lysate (5 nmol/h/mg Hb, $\sim 23\%$ of normal mean values ranging 22 ± 4 nmol/h/mg Hb) but within control range in his intact erythrocytes (89 nmol/h/mL packed cells, control range 101 ± 18). Twice the normal amount of adenine and a

considerable amounts of 2,8-DHA, undetectable in controls and in the patient's brother, were measured in both plasma and urine from the patient (2,8-DHA concentration was 14 and 310 $\mu\text{mol/L}$, respectively).

A homozygous C>G substitution at -3 in the splicing site of exon 2 (IVS2 -3 c>g), never described before and not present in a control population, was found in the patient's genomic DNA by amplification of the APRT gene. The patient's brother was heterozygous for such a mutation, which did not affect the coding region directly and suggested RNA splicing alteration. In order to ascertain whether the identified mutation might be responsible for the APRT activity deficiency, RNA studies were conducted by reverse transcription. cDNA from the brother allowed amplification of a normal sequence transcript, while no amplification at all was obtained from the patient's cDNA. This finding confirmed that the mutation was seemingly responsible for a splicing alteration leading to incorrect transcription of the gene, possibly resulting in truncated protein or no protein at all. Only one splicing variant (IVS4 +1 G>T) was reported as cause of APRT deficiency [4].

Discussion

We describe a case of APRT deficiency presenting with nephrolithiasis and progressive renal failure recurring after renal transplant. The diagnosis of APRT deficiency was made only after renal transplantation.

Few cases of APRT deficiency with recurrent 2,8-DHA lithiasis have been reported in renal transplant recipients up to now. All of them were diagnosed only after transplantation, as in our patient [5-9]. In our opinion, 2,8-DHA crystal nephropathy should be considered in the differential diagnosis of any familiar juvenile form of recurrent nephrolithiasis, and a high index of suspicion is needed because this condition may be underdiagnosed. Early diagnosis supported by crystalluria study is very important for this rare genetically determined metabolic abnormality.

mality since renal failure can be prevented, reversed or arrested at a low cost with specific treatment.

The case reported in this paper is remarkable for the very early recurrent 2,8-DHA lithiasis following renal transplant in a patient with virtually absent APRT activity. Moreover, the enzyme deficiency is due to a newly identified gene mutation.

References

1. Simmonds HA. Adenine phosphoribosyltransferase deficiency. *Orphanet Encyclopedia*, July 2001, updated July 2003. <http://www.orphanet/data/patho/GB/uk-APRT.html>
2. Sahota A, Tischfield J, Kamatani N *et al.* Adenine phosphoribosyltransferase deficiency: 2, 8-dihydroxyadenine lithiasis. In: Scriver CR, Beaudet AL, Sly WS, Valle D (eds). *The Metabolic and Molecular Basis of Inherited Disease*. McGraw-Hill, Inc., 2001; 2571–2584
3. Micheli V, Gathof BS, Rocchigiani M *et al.* Biochemical and molecular study of mentally retarded patients with partial deficiency of hypoxanthine-guanine phosphoribosyltransferase. *Biochim Biophys Acta-Mol Basis Dis* 2002; 1587: 45–52
4. Sahota A, Chen J, Stambrook PJ *et al.* Mutational basis of adenine phosphoribosyltransferase deficiency. *Adv Exp Med Biol* 1991; 309B: 73–76
5. Cassidy MJD, McCulloch T, Fairbanks LD *et al.* Diagnosis of adenine phosphoribosyltransferase deficiency as the underlying cause of renal failure in a renal transplant recipient. *Nephrol Dial Transplant* 2004; 19: 736–738
6. Gagne ER, Deland E, Daudon M *et al.* Chronic renal failure secondary to 2,8-dihydroxyadenine deposition: the first case of recurrence in a renal transplant. *Am J Kidney Dis* 1994; 24: 104–107
7. Benedetto B, Madden R, Kurbanov A *et al.* Adenine phosphoribosyltransferase deficiency and renal allograft dysfunction. *Am J Kidney Dis* 2001; 37: E37
8. Eller P, Rosenkranz AR, Mark W *et al.* Four consecutive renal transplantations in a patient with adenine phosphoribosyltransferase deficiency. *Clin Nephrol* 2004; 61: 217–221
9. de Jong DJ, Assmann KJ, De Abreu RA *et al.* 2, 8-Dihydroxyadenine stone formation in a renal transplant recipient due to adenine phosphoribosyltransferase deficiency. *J Urol* 1996; 156: 1754–1755

Received for publication: 8.2.10; Accepted in revised form: 7.5.10