

Concurrent multiple intracranial and intramedullary conus tuberculoma: A rare case report

Manish Jaiswal, Ashok Gandhi, Devendra Purohit, Radhey Shyam Mittal

Department of Neurosurgery, SMS Medical College and Hospital, Jaipur, Rajasthan, India

ABSTRACT

Central nervous system (CNS) tuberculosis commonly manifests as tubercular meningitis. CNS tuberculomas are more common intracranially and less frequently involve the spinal cord. Combination of intramedullary with intracranial tuberculomas is extremely rare. We report a case of concurrent occurrence of intramedullary tuberculoma with multiple intracranial tuberculomas in a young 16-year-old boy, who presented with two weeks history of paresthesias and weakness of the lower limbs and diminution of vision in left eye, who had been treated for pulmonary tuberculosis. Magnetic resonance imaging (MRI) spine showed a well-circumscribed lesion opposite L1, which was diagnosed as intramedullary tuberculoma. As for vision complaint, on cranial imaging, he was found to have multiple round contrast enhancing lesions, which were diagnosed as intracranial tuberculomas based on their typical MRI findings. He had complete recovery with conventional treatment of anti-tubercular therapy and steroids, without any surgical intervention. We suggest that MRI of the brain should be performed in all case of intramedullary spinal tuberculoma because of the possible presence of early asymptomatic/mild symptomatic intra-cranial tuberculomas.

Key words: Conus tuberculoma, intra-cranial tuberculoma, intramedullary spinal tuberculoma

Introduction

The most frequent manifestations of central nervous system (CNS) tuberculosis are tuberculous meningitis and intra-cranial tuberculomas. Intra-dural spinal tuberculosis commonly manifests as spinal meningitis. Intra-medullary tuberculomas are rare and constitute only 0.2-5% of all CNS tuberculomas.^[1,2] The combination of intra-medullary and intra-cranial tuberculomas is extremely rare and only few cases have been reported in the literature so far.^[3-7] We report a case of concurrent intracranial (supratentorial as well as infratentorial) and intra-spinal (conus) tuberculoma which is extremely rare.

Case Report

A 16-year-boy presented with high-grade fever, generalized weakness, back pain and motor weakness of both lower

extremities for 2 weeks and diminution of vision in left eye since 10 days. Examination revealed spastic paraparesis with muscle strength of 2/5 in both lower extremities, impaired sensations below the L1 level, and exaggerated deep tendon reflexes. The magnetic resonance imaging (MRI) of dorso-lumbar spine showed an iso-intense fusiform dilatation of the spinal cord, at the level of conus in T1 and T2-weighted images showed heterogenous hyperintensity at the conus level with one granulatous lesion at L1 level [Figure 1]. On administration of Gadolinium (Gd)- diethylene triamine pentaacetic acid (DTPA) contrast, the two lesions demonstrated at D12 and L1 level with ring enhancement at the periphery (target sign) [Figure 2]. There was no abnormality in the vertebral bodies or the paraspinal soft-tissues. This lesion, due to its characteristic location, size and classical enhancement was thought to be typical of a tuberculoma. The patient showed negative for HIV, but his chest X-ray revealed randomly distributed miliary nodules in both lung fields, which was highly suggestive of miliary pulmonary tuberculosis. The

Access this article online	
Quick Response Code:	Website: www.asianjns.org
	DOI: 10.4103/1793-5482.143461

Address for correspondence:

Dr. Manish Jaiswal, A 33/48 A 2, Omkareshwar, Varanasi - 221 001, Uttar Pradesh, India.
E-mail: manishmlnmc@gmail.com

This is an open access article distributed under the terms of the Creative Commons Attribution-NonCommercial-ShareAlike 3.0 License, which allows others to remix, tweak, and build upon the work non-commercially, as long as the author is credited and the new creations are licensed under the identical terms.

For reprints contact: reprints@medknow.com

How to cite this article: Jaiswal M, Gandhi A, Purohit D, Mittal RS. Concurrent multiple intracranial and intramedullary conus tuberculoma: A rare case report. Asian J Neurosurg 2017;12:331-3.

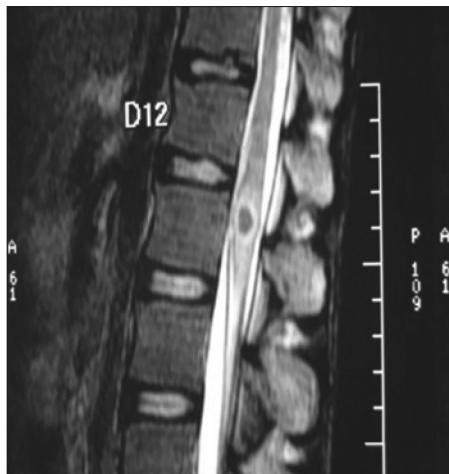


Figure 1: T2 weighted magnetic resonance imaging image of dorso-lumbar spine showing L1 level ring enhancing lesion with peri-lesional edema

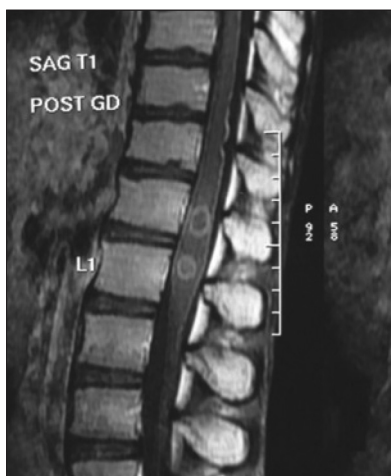

Figure 2: Post-Gadolinium magnetic resonance imaging image of dorso-lumbar spine revealing two ring enhancing lesion (target sign) at D12 and L1 level suggestive of tuberculoma

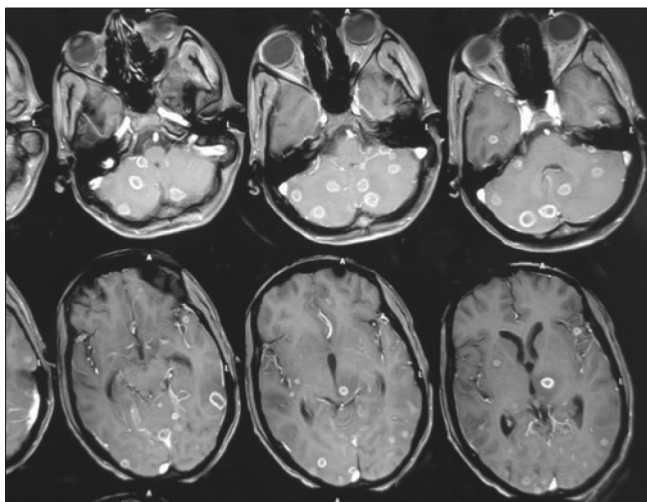


Figure 3: Magnetic resonance imaging brain contrast revealing multiple ring enhancing lesions in both cerebral hemisphere and cerebellum S/O tuberculoma

tuberculin immunoglobulin M protein (TB IgM) was positive and the MRI of the brain revealed multiple enhancing nodules in deep white matter and subcortical area both supratentorial and infratentorial compartment [Figure 3]. He was treated with rifampicin 600 mg, isoniazid 300 mg, pyrazinamide 1500 mg, ethambutol 1200 mg and pyridoxine 25 mg. On hematological examination, the leucocyte count was 7,500/mm³ and the erythrocyte sedimentation rate (ESR) at the end of 1 h was 90 mm. Patient improved in follow-up and now walk with assistant.

Discussion

CNS involvement is a less frequent manifestation of extra-pulmonary tuberculosis as compared to the involvement of other systems. Neuro-tuberculosis is seen in up to 10% of patients with systemic tuberculosis and occurs as a result of hematogenous spread from a primary focus, usually the lung.^[6,7] There may not be any evidence of extra-neural tuberculosis in up to a third cases of neuro-tuberculosis.^[6] The MRI is a sensitive and non-invasive tool for diagnosing and localizing intra-medullary as well as brain tuberculomas. The lesion appears as an iso-intense or hyper-intense ring on the T1-weighted images and as an iso-intense or hypo-intense lesion on the T2-weighted images. MRI will also delineate the extent of surrounding edema. MRI also helps in determining the stage of tuberculoma formation. Presence of a bright central spot in the granuloma (target sign) is indicative of central caseation (rich foci).^[4,6,8] Gd-DTPA enhancement MRI is more sensitive than MRI without enhancement in demonstrating the lesions of tuberculoma and arachnoiditis. In early stages of brain tuberculoma contrast MRI will show homogeneous enhancement representing the early tuberculoma stage, which may later evolve to ring enhancement with hypointense center.^[4,6,8] In present case, MRI after contrast administration showed characteristic peripheral irregular ring enhancement of conus lesion suggestive of tuberculoma. However, MRI of brain showed solid ring like enhancement of lesion suggestive of early stage of disease without caseating necrosis. The differential diagnosis of intramedullary tuberculomas includes other granulomas such as cysticercosis, and neoplastic lesions such as astrocytoma, metastasis or lymphoma.^[6] In present case, the clinical and imaging features combined with the classical hematological findings were suggestive of tuberculous etiology. Recently, polymerase chain reaction (for *Mycobacterial* protein) combined with contrast MRI has been used with a reasonable degree of certainty. There is no unanimity regarding the management protocol. Anti-tuberculosis therapy with anti-edema measures is the mainstay of treatment for these patients.^[4] Conservative treatment with anti-tuberculosis medications and a short course of injectable steroids offers an effective, inexpensive, safe, and feasible option for treating intra-medullary tuberculoma, especially in developing countries.^[6] Role of

steroid is largely unproven. However, in patients with perilesional edema short-term steroids may be helpful.^[3] Usually, the conservative treatment is successful in achieving complete clinical neurological recovery over a period of 1 year, which is also accompanied by resolution of the tuberculomas.^[6] With skilled microsurgical techniques it is possible to safely excise the spinal tuberculomas as these lesions are well circumscribed. Surgery is reserved for the patients with large lesions causing significant compression, patients who do not respond to or deteriorates during conservative treatment.^[1,2,5,7-12] As with any surgical procedure there are attendant risks of anesthesia and probability of developing post-surgical tuberculosis meningitis, sinus formation, and residual deficit^[9,12] but patients who present with profound neurological deficits should undergo early surgical decompression even if the treating physician is reasonably sure about the diagnosis of intramedullary tuberculoma. Undue delay entailed by prolonged medical therapy might lead to irreversible cord damage, and the patient might not improve neurologically even if the lesion disappears radiologically. Patient is doing well, however, long-term follow-up is awaited.

Conclusion

In conclusion, this case emphasizes intra-cranial and intra-medullary tuberculomas can co-exist in a patient. In acute stage, clinical features of intramedullary spinal tuberculoma may predominate. We suggest that MRI of the brain should be performed in the case of intramedullary spinal tuberculoma because of the possible presence of early asymptomatic/mild symptomatic intracranial tuberculomas, which changes the management in terms of anti-epileptic

and anti-edema drugs to prevent seizure and intra-cranial hypertension.

Financial support and sponsorship

Nil.

Conflicts of interest

There are no conflicts of interest.

References

1. Citow JS, Ammirati M. Intramedullary tuberculoma of the spinal cord: Case report. *Neurosurgery* 1994;35:327-30.
2. Süzer T, Coşkun E, Tahta K, Bayramoğlu H, Düzcan E. Intramedullary spinal tuberculoma presenting as a conus tumor: A case report and review of the literature. *Eur Spine J* 1998;7:168-71.
3. Huang CR, Lui CC, Chang WN, Wu HS, Chen HJ. Neuroimages of disseminated neurotuberculosis: Report of one case. *Clin Imaging* 1999;23:218-22.
4. Lin SK, Wu T, Wai YY. Intramedullary spinal tuberculomas during treatment of tuberculous meningitis. *Clin Neurol Neurosurg* 1994;96:71-8.
5. Shen WC, Cheng TY, Lee SK, Ho YJ, Lee KR. Disseminated tuberculomas in spinal cord and brain demonstrated by MRI with gadolinium-DTPA. *Neuroradiology* 1993;35:213-5.
6. Thacker MM, Puri AI. Concurrent intra-medullary and intra-cranial tuberculomas. *J Postgrad Med* 2004;50:107-9.
7. Yen HL, Lee RJ, Lin JW, Chen HJ. Multiple tuberculomas in the brain and spinal cord: A case report. *Spine (Phila Pa 1976)* 2003;28:E499-502.
8. Shaharao VB, Pawar M, Agarwal R, Bavdekar SB. Intra-medullary tuberculoma occurring during treatment of tuberculous meningitis. *Indian J Pediatr* 2004;71:107-8.
9. Gupta VK, Sharma BS, Khosla VK. Intramedullary tuberculoma: Report of two cases with MRI findings. *Surg Neurol* 1995;44:241-3.
10. Kayaoglu CR, Tuzun Y, Boga Z, Erdogan F, Gorguner M, Aydin IH. Intramedullary spinal tuberculoma: A case report. *Spine (Phila Pa 1976)* 2000;25:2265-8.
11. Kumar R, Jain R, Kaur A, Chhabra DK. Brain stem tuberculosis in children. *Br J Neurosurg* 2000;14:356-61.
12. Rhoton EL, Ballinger WE Jr, Quisling R, Sybert GW. Intramedullary spinal tuberculoma. *Neurosurgery* 1988;22:733-6.