

Ascending aortic estrogen receptor positivity and aortic valve stenosis

 Ari Mennander,  Nitta-Nea Valtonen¹,  Eetu Niinimäki¹,  Ivana Kholová¹,  Timo Paavonen¹

Division of Cardiothoracic Surgery, Tampere University Heart Hospital and Tampere University; Tampere-Finland

¹Department of Pathology, Fimlab Laboratories and Tampere University; Tampere-Finland

Introduction

There is increasing awareness that the aortic valve may be involved in the pathophysiology of the ascending aorta (1). Age, sex, and osteoporosis may impact the physiopathology of atherosclerosis and aortic valve stenosis (2-5), along with renin-angiotensin activation, nitric oxide, and noradrenaline (4). Structurally, the aortic valve is directly connected to the media layer of the ascending aorta, highlighting the important functional and anatomical connection of the aortic valve, the aortic root, and the ascending aorta (e.g., a severely stenotic aortic valve is often found inside a stiff atherosclerotic aortic root) (1).

As steroid hormones, estrogens have gained abundant interest in terms of vascular pathology (2). There are 2 different estrogen receptors (ER), ER1 and ER2. In particular, ER2 modulates the vasculature through inflammation, regulates smooth muscle cells proliferation, the vascular tone, and neovascularization (6, 7), all of which play a role in inducing anti-atherosclerosis (6).

Study protocol and surgery

We investigated whether ERs are expressed in the ascending aortic wall and sought the presence of aortic valve stenosis. After approval by the Institutional Clinical Ethics Committee, we obtained the ascending aortic wall resection of 29 consecutive patients undergoing surgery for ascending aorta and processed them for histology.

Histology and immunohistochemistry

A minimum of 6 pieces of representative resected ascending aorta were embedded in paraffin; cut to 4 μ m-thick segments; and stained with hematoxylin and eosin, Verhoeff–van Gieson, Elastase–van Gieson, and periodic acid-Schiff. Immunohistochemistry was performed using the Ventana Lifesciences

(Tucson, AZ, USA) Benchmark XT Staining module. ER1 was detected by mouse monoclonal antibody (clone 6F11; NovoCastra, Newcastle upon Tyne, United Kingdom; 1:50). ER2 was studied with polyclonal rabbit antibody (sc-8974; Santa Cruz Biotechnology, Heidelberg, Germany; 1:50). Inflammatory cells, intensity of inflammation, medial degeneration, intima cellularity and thickness, as well as ER positivity (ER+) were defined within the 3 different aortic wall layers as described previously (8).

Statistical analysis

Quantitative variables are listed as mean and standard error of the mean. The Mann–Whitney U–test was used for continuous variables. The predictive value of ER+ to identify patients without aortic valve stenosis was assessed by receiver operating characteristic curve analysis. Correlation of medial ER+ to severity of aortic valve stenosis was performed by Spearman rank rho. P values <0.05 were considered statistically relevant.

Main results

The patient characteristics included hypertension in 11 patients, diabetes in 3 patients, hypercholesterolemia in 5 patients, obesity in 1 patient, and 1 patient with a family history for aortic aneurysm. Twenty-three patients had ascending aortic dilatation, whereas 6 patients also had aortic dissection. ER+ staining was predominantly found in the media, but also in the intima and the adventitia (Fig. 1). The patients were categorized according to whether they had ER+ or not (nonER). The mean age for the patients was 66 \pm 2 years (66 \pm 3 vs. 66 \pm 2 years; $p=0.965$ in the ER+ vs. nonER patients, respectively). The ER+ group was 50% male, whereas the nonER group was 77% male ($p=0.249$). The ER+ group consisted of only ER2 and was present in 16 patients. ER1 was not found in the aortic tissue. The mean aortic diameter was 57 \pm 2 mm for all patients. Aortic dissection was present in 4 out of 16 aortas with ER+ (25%) and 2 out of 13 aortas with nonER (16%). Aortic

Address for correspondence: Ari Mennander, MD, Division of Cardiothoracic Surgery, Tampere University Heart Hospital and Tampere University; Tampere-Finland
Phone: +358442944055 E-mail: ari.mennander@hotmail.com - ari.mennander@sydansaara.fi

Accepted Date: 16.07.2020 **Available Online Date:** 17.09.2020

©Copyright 2020 by Turkish Society of Cardiology - Available online at www.anatoljcardiol.com
DOI:10.14744/AnatolJCardiol.2020.37665



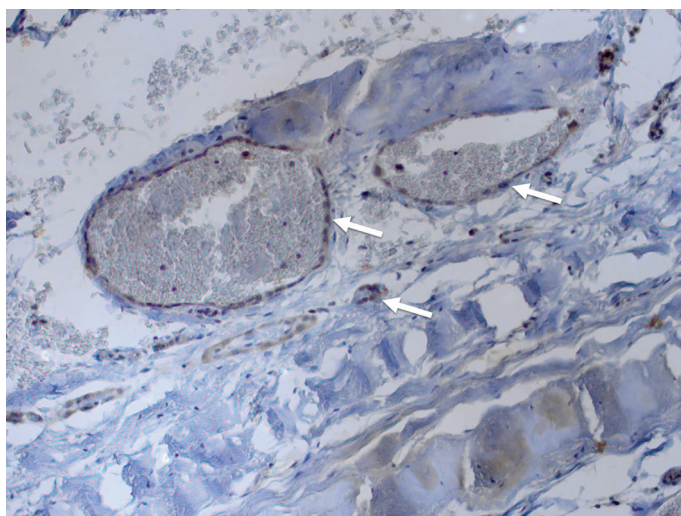


Figure 1. Representative immunohistochemistry (x40) for estrogen receptor beta (ER2) of the ascending aorta without aortic valve stenosis. Note ER2 (arrows) in the media layer of the ascending aorta

root surgery was necessary in 10 patients with ER+ (63%) as opposed to only 5 patients with nonER (38%). Eight patients with ER+ and 7 with nonER had aortic valve insufficiency, but 1 patient with ER+ and 4 patients with nonER had a mixed aortic valve disease considered as stenotic and insufficient. Two patients with ER+ had aortic valve stenosis compared with 8 patients with nonER. Macrophages of the media were increased in patients with ER+ compared with those with nonER (1.75 ± 0.28 vs. 1.08 ± 0.17 ; $p=0.044$, respectively) (Table 1). Receiver operating characteristic curve analysis showed that dilated ascending aorta with medial ER+ was seldom associated with aortic valve stenosis (area under the curve, 0.805; standard error, 0.081; $p=0.008$; 95% confidence interval, 0.646–0.964), and ER+ correlated inversely with the severity of aortic valve stenosis ($r=-0.5$; $p=0.009$).

Comments

This pilot study suggests that the presence of aortic valve stenosis is seldom associated with ascending aortic ER+. In contrast

Table 1. Histology and quantitative immunohistochemistry

Mean grade of staining Point score units/mm ²	All patients n=29	ER+ n=16	NonER n=13	P value
Adventitia				
T cells	1.67±0.13	1.64±0.16	1.70±0.21	0.845
B cells	1.04±0.20	1.23±0.32	0.83±0.24	0.440
Macrophages	1.88±0.12	1.93±0.18	1.82±0.18	0.464
Plasma cells	1.15±0.20	1.00±0.27	1.36±0.31	0.344
Inflammation	2.04±0.12	2.00±0.19	2.08±0.14	0.761
Proliferation	1.00±0.18	0.93±0.22	1.09±0.31	0.778
IgG4	0.19±0.07	0.21±0.11	0.15±0.10	0.692
Ca9	1.23±0.23	1.80±0.48	0.87±0.12	0.692
Media				
T cells	0.50±0.13	0.69±0.17	0.25±0.17	0.057
B cells	0.07±0.04	0.06±0.06	0.08±0.07	0.881
Macrophages	1.45±0.18	1.75±0.28	1.08±0.17	0.044*
Plasma cells	0.10±0.07	0.13±0.12	0.08±0.07	0.921
Inflammation	1.21±0.16	1.31±0.19	1.08±0.28	0.457
Proliferation	1.14±0.19	1.31±0.27	0.92±0.28	0.314
Degeneration	1.72±0.20	2.00±0.22	1.38±0.35	0.166
Elastase	1.48±0.19	1.63±0.28	1.31±0.23	0.450
Intima				
T cells	1.29±0.16	1.56±0.18	0.92±0.28	0.091
B cells	0.21±0.11	0.37±0.20	0	0.105
Macrophages	1.69±0.18	2.00±0.22	1.31±0.26	0.056
Plasma cells	0.45±0.12	0.56±0.18	0.31±0.17	0.273
Inflammation	1.52±0.14	1.50±0.18	1.54±0.24	0.983
Proliferation	0.79±0.16	0.94±0.23	0.62±0.21	0.346
Thickness	2.00±0.17	2.12±0.22	1.85±0.27	0.420
Cellularity	1.72±0.12	1.62±0.15	1.85±0.19	0.380

*P<0.05

to increased myocardial ER+ after cardiac hypertrophy (9), aortic ER+ reflects a non-stenotic circulatory milieu. ER2 may even protect the arterial vasculature from atherosclerotic features (6). The expression of ER2 was predominantly present in the media-adventitia layer of the ascending aorta, in which an abundant capillary-like network is located (7, 10). The loose connective tissue around these neovascular structures, along with increased macrophages may even signify that the aortic wall is susceptible to tear leading to dissection (7). It is tempting to describe the necessity of aortic root surgery encompassing the ascending aorta as clinically reflecting severe ascending aortic frailty, because the final decision of the extension of aortic resection is decided at surgery by inspecting the aortic wall. Patients with ER+ aortas may require long-term follow-up to anticipate possible ongoing dilatation and aortic events of the remaining aorta after surgery.

Conclusion

The small number of the patients in this study limits comparison of the patient groups. Aortic ER+ suggests for non-atherosclerotic aortic wall prone for aortic events such as dissection, whereas the ascending aorta with nonER may be associated with a stiff aortic wall and aortic valve stenosis. ER histopathology may reveal an exciting means to stratify the risk of aortic events after surgery.

Conflict of interest: None declared.

Peer-review: Externally peer-reviewed.

Authorship contributions: Concept – A.M., E.N., I.K., T.P.; Design – A.M., T.P.; Supervision – A.M., T.P.; Fundings – A.M.; Materials – A.M., T.P.; Data collection &/or processing – A.M., N.N.V., E.N., I.K.; Analysis &/or interpretation – A.M., N.N.V., E.N., I.K., T.P.; Literature search – A.M., N.N.V.; Writing – A.M., I.K., T.P.; Critical review – A.M., N.N.V., E.N., I.K., T.P.

References

1. Wysokiński A, Zapolski T. Relationship between aortic valve calcification and aortic atherosclerosis: a transoesophageal echocardiography study. *Kardiol Pol* 2006; 64: 694-701.
2. Nordström P, Glader CA, Dahlén G, Birgander LS, Lorentzon R, Waldenström A, et al. Oestrogen receptor alpha gene polymorphism is related to aortic valve sclerosis in postmenopausal women. *J Intern Med* 2003; 254: 140-6.
3. Masjedi S, Ferdous Z. Understanding the Role of Sex in Heart Valve and Major Vascular Diseases. *Cardiovasc Eng Technol* 2015; 6: 209-19.
4. Dobson LE, Fairbairn TA, Plein S, Greenwood JP. Sex Differences in Aortic Stenosis and Outcome Following Surgical and Transcatheter Aortic Valve Replacement. *J Womens Health (Larchmt)* 2015; 24: 986-95.
5. Skolnick AH, Osranek M, Formica P, Kronzon I. Osteoporosis treatment and progression of aortic stenosis. *Am J Cardiol* 2009; 104: 122-4.
6. Chakrabarti S, Lekontseva O, Peters A, Davidge ST. 17beta-Estradiol induces protein S-nitrosylation in the endothelium. *Cardiovasc Res* 2010; 85: 796-805.
7. Albrecht ED, Babischkin JS, Lidor Y, Anderson LD, Udoff LC, Pepe GJ. Effect of estrogen on angiogenesis in co-cultures of human endometrial cells and microvascular endothelial cells. *Hum Reprod* 2003; 18: 2039-47.
8. Levula M, Paavonen T, Valo T, Pelto-Huikko M, Laaksonen R, Kahonen M, et al. A disintegrin and metalloprotease -8 and -15 and susceptibility for ascending aortic dissection. *Scand J Clin Lab Invest* 2011; 71: 515-22.
9. Nordmeyer J, Eder S, Mahmoodzadeh S, Martus P, Fielitz J, Bass J, et al. Upregulation of myocardial estrogen receptors in human aortic stenosis. *Circulation* 2004; 110: 3270-5.
10. Osada H, Kyogoku M, Ishidou M, Morishima M, Nakajima H. Aortic dissection in the outer third of the media: what is the role of the vasa vasorum in the triggering process? *Eur J Cardiothorac Surg* 2013; 43: e82-8.