

Case Report

Chronic expanding pituitary hematoma without rebleeding after pituitary apoplexy

Masato Hojo, Masanori Goto, Susumu Miyamoto

Department of Neurosurgery, Kyoto University Graduate School of Medicine, Kyoto 606-8507, Japan

E-mail: *Masato Hojo - mhojo@kuhp.kyoto-u.ac.jp; Masanori Goto - mgoto@kuhp.kyoto-u.ac.jp; Susumu Miyamoto - miy@kuhp.kyoto-u.ac.jp

*Correspondence author

Received: 19 February 13 Accepted: 05 March 13 Published: 28 March 13

This article may be cited as:Hojo M, Goto M, Miyamoto S. Chronic expanding pituitary hematoma without rebleeding after pituitary apoplexy. *Surg Neurol Int* 2013;4:41.Available FREE in open access from: <http://www.surgicalneurologyint.com/text.asp?2013/4/1/41/109654>

Copyright: © 2013 Hojo M. This is an open-access article distributed under the terms of the Creative Commons Attribution License, which permits unrestricted use, distribution, and reproduction in any medium, provided the original author and source are credited.

Abstract

Background: Enlargement of intracerebral hematoma without rebleeding in chronic phase is a rare but well-known clinical condition, and is well-described as chronic expanding intracerebral hematoma. However, chronic enlargement of pituitary hematoma without rebleeding after pituitary apoplexy is extremely rare.

Case Description: We report a case of chronic expanding pituitary hematoma without rebleeding after pituitary apoplexy. A 29-year-old male presented with sudden onset of headache and vomiting. Magnetic resonance imaging (MRI) demonstrated a pituitary mass lesion with hematoma, consistent with pituitary apoplexy. Neuro-ophthalmological examination revealed no visual field defect, and endocrinological evaluations showed an elevated prolactin level. Pituitary apoplexy due to a prolactinoma was the most likely diagnosis. He was conservatively treated because he exhibited no visual disturbance. Three weeks after the onset, he gradually began to complain of blurred vision and neuro-ophthalmological examination revealed bitemporal upper quadrant hemianopsia. MRI showed enlargement of the pituitary hematoma without any finding suggestive of rebleeding. This enlarged mass lesion compressed the chiasm. The patient was operated on via transsphenoidal approach. After dural opening, xanthochromic fluid spouted out, but no fresh clot could be detected within the cyst. After the operation, the visual field disturbance resolved completely. The possible mechanism of hematoma enlargement is considered to be expansion due to the serum exudation from capillaries of the hematoma capsule. This pathogenetic mechanism is common in enlargement of chronic subdural hematoma.

Conclusions: This case is the first report of chronic expanding pituitary hematoma without rebleeding after pituitary apoplexy.

Key Words: Chronic expanding hematoma, pituitary apoplexy, pituitary adenoma, prolactinoma, transsphenoidal surgery

**Access this article
online****Website:**www.surgicalneurologyint.com**DOI:**

10.4103/2152-7806.109654

Quick Response Code:

INTRODUCTION

Pituitary apoplexy is a rare clinical syndrome caused by the rapid enlargement of a pituitary adenoma because

of hemorrhage or infarction.^[5,6,9-11] It usually presents with sudden onset of severe headache, vomiting, visual disturbance, ocular palsy, and consciousness disturbance. The patients with pituitary apoplexy, who exhibit no

neuro-ophthalmological signs, can be conservatively treated.^[6,9-11] Although rare, deterioration at the chronic stage is caused by rebleeding within the hematoma or hemorrhagic change within the infarct area.

Enlargement of intracerebral hematoma without rebleeding in chronic phase is a rare but well-known clinical condition, and is well-described as chronic expanding intracerebral hematoma.^[1,4,7,8,14] The possible mechanism of hematoma enlargement is expansion due to serum exudation or repeated minor bleeding from capillaries of the hematoma capsule.^[14] However, expansion of an intrasellar pituitary hematoma without rebleeding at the chronic stage of pituitary apoplexy is an extremely rare clinical condition. Here, we report the first case of chronic expanding intrasellar hematoma without rebleeding after pituitary apoplexy.

CASE REPORT

A 29-year-old male presented with a sudden onset of severe headache accompanied by vomiting, and visited a local hospital. A physician could not detect any abnormal finding by computed tomography (CT) scans. Two weeks after the onset, magnetic resonance imaging (MRI) revealed a pituitary mass with hematoma consistent with pituitary apoplexy [Figure 1a and b], and he was referred to our institute. Neuro-ophthalmological examination revealed no visual field disturbance. Endocrinological evaluation showed that the prolactin level was elevated at 583.2 ng/mL (normal value: 3.6-16.3 ng/mL). Pituitary apoplexy due to a prolactinoma was the most likely diagnosis. He also complained of general fatigue and appetite loss. The adrenocorticotropic hormone (ACTH) level was slightly decreased: 8 pg/mL (normal value: 7-56 pg/mL). The testosterone level was also decreased:

24.1 ng/dL (normal value: 161-904 ng/dL). Thus, hypopituitarism was proved and replacement therapy was started. Because he exhibited no neuro-ophthalmological deficit, we continued medical treatment.

Three weeks after the onset, he gradually began to complain of blurred vision. Neuro-ophthalmological examination revealed bitemporal upper quadrant hemianopsia. MRI showed the enlargement of the pituitary mass lesion resulting in the compression of the chiasm [Figure 1c]. The intensity of the hematoma within the adenoma was changed from hyperintensity to hypointensity on T1-weighted image [Figure 1c]. No sign of rebleeding was detected. Laboratory investigations revealed no abnormal values in hematological and coagulant parameters: Thrombocyte count, prothrombin time, and activated and partial thromboplastin times.

He was operated on via transsphenoidal approach. The dura of the sella was tense. After dural opening, xanthochromic fluid spouted out, but no fresh clot could be detected within the hematoma cavity [Figure 2]. The wall of the hematoma cavity was fibrous and thick, and had characteristics similar to the outer membrane of chronic subdural hematoma (CSDH). Grayish adenoma was detected and removed with curettage. Histological examination confirmed the diagnosis of pituitary adenoma. Postoperative course was uneventful. Visual field disturbance was completely resolved and hypopituitarism was gradually improved. Postoperative MRI showed that the cyst was evacuated and the chiasm was decompressed.

DISCUSSION

The clinical features of pituitary apoplexy are typically sudden in onset, including acute headache, nausea,

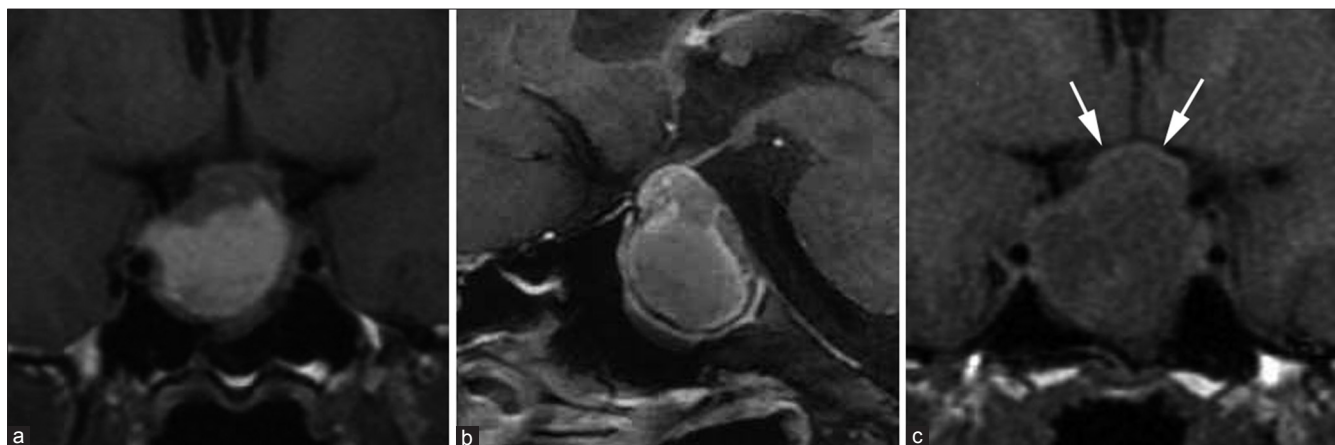


Figure 1: MR images obtained 2 weeks (a, b) and 3 weeks (c) after onset, (a) coronal T1-weighted image demonstrated intra- and suprasellar mass with a central area of high signal intensity consistent with hematoma of subacute phase. The hyperintense signal may correspond to hemoglobin degradation content as extracellular methemoglobin, (b) sagittal postgadolinium T1-weighted image showed rim enhancement of hematoma capsule, (c) coronal T1-weighted image demonstrated enlargement of pituitary hematoma resulting in compression of the chiasm (arrows). No sign of rebleeding was detected. Compared with MR images obtained 2 weeks after onset (a), the compression of chiasm was markedly worsened for this one week (c, arrows)

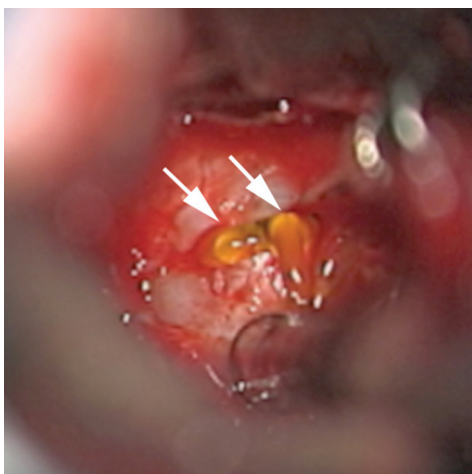


Figure 2: Intraoperative microphotograph showing the content of hematoma. Xanthochromic fluid was spouted after dural opening (arrows)

vomiting, visual field defect, and ocular paresis.^[5,6,9-11] After acute stage, these symptoms are gradually improved and deterioration is rare. Deterioration at chronic stage is usually caused by rebleeding within the hematoma or infarction. In the present case, visual field disturbance was developed at chronic state due to enlargement of the hematoma without rebleeding. This is the first case of chronic expanding intrasellar pituitary hematoma without rebleeding after pituitary adenoma. Previously, Veldhuis, *et al.* reported a case of chronic intrasellar hematoma.^[12] In this report, a chronic intrasellar hematoma mimicked recurrent tumor one year after operation for a prolactinoma. However, only plain X-ray film was presented in this report, because this case was treated in the pre-CT era. The feature of hematoma could not be examined in detail by imaging such as MRI. Hence, the present case is the first report of chronic expanding intrasellar hematoma, which is examined by MRI, without rebleeding after pituitary apoplexy.

The phenomenon of chronic expansion of hematoma is well-known in CSDH. In CSDH, various theories have been proposed to explain the enlargement of hematomas. Intermittent cycles of bleeding, coagulation, fibrinolysis, and rebleeding from the vascularized outer membrane are widely accepted to be the pathophysiology of hematoma expansion.^[3] Enlargement of CSDH without rebleeding is also well-known: Increased vascular permeability and subsequent serum exudation from the outer membrane may be involved in hematoma expansion without rebleeding.^[2,3,13] This mechanism can also explain the pathophysiology of pituitary hematoma expansion in the present case. The hematoma capsule of the present case was well-enhanced. Enhancement of the hematoma capsule may be the result of blood-brain barrier breakdown, resulting in plasma exudation. Intraoperative

findings revealed the hematoma capsule of the present case was thickened and like outer membrane of CSDH, suggesting that the same mechanism with CSDH may be involved in the hematoma expansion of the present case. It is likely that serum exudation from the hematoma capsule is the cause of hematoma expansion without rebleeding in the present case.

CONCLUSION

It was highly likely that the intrasellar pituitary hematoma expanded without rebleeding through the same mechanism as CSDH: Expansion due to serum exudation from capillaries of the hematoma capsule. To the authors' knowledge, this is the first documented case of chronic expanding intrasellar hematoma without rebleeding after pituitary apoplexy. Although it is unusual clinical condition, expansion of intrasellar pituitary hematoma without rebleeding at chronic stage should be taken into account in the treatment of pituitary apoplexy.

REFERENCES

1. Aoki N, Mizuguchi K. Chronic encapsulated intracerebellar hematoma in infancy: Case report. *Neurosurgery* 1984;14:594-7.
2. Frati A, Salvati M, Mainiero F, Ippoliti F, Rocchi G, Raco A, *et al.* Inflammation markers and risk factors for recurrence in 35 patients with a posttraumatic chronic subdural hematoma: A prospective study. *J Neurosurg* 2004;100:24-32.
3. Fujisawa H, Nomura S, Kajiwara K, Kato S, Fujii M, Suzuki M. Various magnetic resonance imaging patterns of chronic subdural hematomas: Indicators of the pathogenesis? *Neurol Med Chir* 2006;46:333-8.
4. Hirsh LF, Spector HB, Bogdanoff BM. Chronic encapsulated intracerebral hematoma. *Neurosurgery* 1981;9:169-72.
5. Liu ZH, Chang CN, Pai PC, Wei KC, Jung SM, Chen NY, *et al.* Clinical features and surgical outcome of clinical and subclinical pituitary apoplexy. *J Clin Neurosci* 2010;17:694-9.
6. Lubina A, Olchovsky D, Berezin M, Ram Z, Hadani M, Shimon I. Management of pituitary apoplexy: Clinical experience with 40 patients. *Acta Neurochir* 2005;147:151-7.
7. Pozzati E, Giuliani G, Gaist G, Piazza G, Vergoni G. Chronic expanding intracerebral hematoma. *J Neurosurg* 1986;65:611-4.
8. Roda JM, Carceller F, Perez-Higueras A, Morales C. Encapsulated intracerebral hematomas: A defined entity: Case report. *J Neurosurg* 1993;78:829-33.
9. Semple PL, Webb MK, de Villiers JC, Laws ER, Jr. Pituitary apoplexy. *Neurosurgery* 2005;56:65-72.
10. Sibal L, Ball SG, Connolly V, James RA, Kane P, Kelly WF, *et al.* Pituitary apoplexy: A review of clinical presentation, management and outcome in 45 cases. *Pituitary* 2004;7:157-63.
11. Turgut M, Ozsunar Y, Basak S, Guney E, Kir E, Meteoglu I. Pituitary apoplexy: An overview of 186 cases published during the last century. *Acta Neurochir* 2010;152:749-61.
12. Veldhuis JD, Santen RJ. Pituitary pseudotumor. Mimicry of recurrent prolactinoma by a chronic intrasellar hematoma. *Arch Intern Med* 1979;139:1309-11.
13. Watanabe T, Nakahara K, Miki Y, Shibui S, Takakura K, Nomura K. Chronic expanding epidural haematoma: Case report. *Acta Neurochir* 1995;132:150-3.
14. Yamamoto S, Momose T, Aoyagi M, Ohno K. Spontaneous intracerebral hematomas expanding during the early stages of hemorrhage without rebleeding. Report of three cases. *J Neurosurg* 2002;97:455-60.