



Intraoperative Halo-Femoral Traction in Surgical Treatment of Adolescent Idiopathic Scoliosis Curves between 70° and 90°: Is It Effective?

Mehmet Nuri Erdem¹, Ismail Oltulu², Sinan Karaca³, Seçkin Sari², Mehmet Aydoğan²

¹Department of Orthopaedics and Traumatology, Hisar Intercontinental Hospital, İstanbul, Turkey

²Fulya Orthopaedic and Spine Center, İstanbul, Turkey

³Department of Orthopaedics and Traumatology, Fatih Sultan Mehmet Training and Research Hospital, İstanbul, Turkey

Study Design: A retrospective clinical study.

Purpose: To analyze the surgical outcomes of intraoperative halo-femoral traction (HFT) in patients with adolescent idiopathic scoliosis (AIS) with Cobb angles between 70° and 90° and flexibility <35%.

Overview of Literature: Numerous methods have been described to achieve adequate correction and successful results in the surgical treatment of AIS patients with a Cobb angle >70°. However, few studies have evaluated the results of HFT in AIS patients with Cobb angles between 70° and 90° and flexibility <35%.

Methods: The study comprised 24 AIS patients (18 females, six males; mean age, 17.4 years; mean preoperative Cobb angle, 80.1°; range, 70°–90°) who underwent surgery using intraoperative HFT. Neurological status was constantly assessed during the surgery using intraoperative neurophysiological monitoring.

Results: The mean follow-up period was 33.5 months. Radiographic outcomes demonstrated 85.7% correction of the major Cobb angle. Coronal and sagittal balance was achieved in all the patients, and shoulder levels were equalized. The traction was discontinued when a decrease in spinal cord potentials was observed during the surgery.

Conclusions: Intraoperative HFT is an effective and reliable method for the management of scoliosis curves between 70° and 90°. The most significant advantages of the method are avoidance of the morbidities related to anterior surgery, osteotomy, or vertebral column resection; its contribution in helping achieve adequate reduction and optimum balance by the gradually increased corrective force, lack of any need for extreme correction force during instrumentation; and the high correction rates achieved.

Keywords: Scoliosis; Posterior instrumentation; Traction; Posterior spinal fusion; Surgical outcomes

Introduction

The choice of treatment in adolescent idiopathic scoliosis (AIS) depends on the degree and flexibility of the curve. High correction rates and successful outcomes have been

reported in AIS patients with curves between 40° and 70° and even in those with rigid curves [1]. Severe scoliosis is defined as presence of curves with Cobb angles >70° and those that cannot be reduced by >35% on bending radiographs [2]. Despite modern instrumentation systems and

Received Nov 6, 2017; Revised Nov 17, 2017; Accepted Nov 19, 2017

Corresponding author: Mehmet Nuri Erdem

Department of Orthopaedics and Traumatology, Hisar Intercontinental Hospital, Saray, Site Yolu Cad. No:7, Ümraniye/İstanbul, Turkey
Tel: +90-216-524-1300, GSM: +90-533-221-5938, Fax: +90-216-524-1323, E-mail: mnerdem@yandex.com

surgical techniques, spinal surgery for severe AIS remains challenging due to the magnitude of the deformity, reduced lung capacity, potential pseudoarthrosis, and neurologic complications. Curves $>90^\circ$ are often rigid, and, therefore, anterior release, posterior osteotomy, or column resection have been performed for their management with satisfactory outcomes [3-5]. Conversely, the selection of treatment method for curves between 70° and 90° may be considered as a gray zone. The degree and flexibility of the curve, patient age, and surgeon's experience have led to the use of different techniques for the treatment of AIS patients. Recently, intraoperative halo-femoral traction (HFT) has been successfully used to manage severe AIS without the need for anterior surgery, osteotomy, or column resection [6-8]. We aimed to analyze the surgical outcomes of intraoperative HFT in AIS patients with Cobb angles between 70° and 90° and flexibility $<35\%$.

Materials and Methods

1. Patients

After obtaining institutional review board approval, we evaluated a prospectively maintained surgical database for patients with scoliosis and identified 24 consecutive patients with severe AIS treated with intraoperative HFT between 2008 and 2011. Their clinical and radiological data were retrospectively analyzed by a spine surgeon uninvolved in the surgical treatment. The inclusion criteria included a diagnosis of AIS, age >15 years, major curve between 70° and 90° , flexibility of the curve $<35\%$, Risser sign ≥ 3 , follow-up period >2 years, and use of intraoperative HFT. Patients with systemic neurological or connective tissue diseases, intramedullary pathologies, and cervical instability were excluded. Patient age at the time of surgery, sex, length of hospital stay, preoperative weight, preoperative lung functions, surgical time, amount of bleeding, and complications were recorded. All the patients had completed the Scoliosis Research Society 22-item (SRS-22) questionnaire preoperatively and at 6 months and 1 and 2 years postoperatively.

Standing anteroposterior and lateral radiographs of the whole spinal column and supine right and left bending radiographs were preoperatively taken. To rule out any intramedullary disease, all the patients were evaluated using cervical, thoracic, and lumbar magnetic resonance imaging. The presence of cervical instability was assessed using

cervical dynamic radiographs. The atlantodens interval was measured in the C1–C2 vertebrae, and subaxial cervical instability (displacement >4 mm, angulation $>10^\circ$) was evaluated. The flexibility of the curves was calculated using supine bending radiographs. All the patients were examined for leg length discrepancy and pelvic obliquity using bilateral lower extremity orthoroentgenograms. The curves were classified according to the Lenke classification. Pulmonary function tests were performed to determine the respiratory function preoperatively and at 1 year postoperatively. Fusion levels were determined by the senior author (MA) based on the aforementioned studies. All the radiographs and related studies were performed preoperatively and at 6 weeks and 3, 6, 12, and 24 months postoperatively.

2. Surgical technique

With the patient under general anesthesia and in the supine position, the patient's head was placed on the operating table without a pillow. Pins were placed orthogonally, immediately below the equator and at the level of the tragus, for Gardner–Wells traction (J-Tongs; Ossur, Eindhoven, The Netherlands). The pins were sequentially and symmetrically tightened until 8 lbs (3.63 kg) of torque was attained, and halo fixation was completed (Fig. 1). Femoral supracondylar Steinmann pins were then bilaterally inserted; neuromonitoring probes were placed. The patient was turned prone, and weights were applied to both the femurs and the head, beginning with 20% of the body weight. The weight distribution was gradually increased until it reached 8 kg in the cervical part and up to a maximum of 40% of the total body weight during the correction phase. In patients with pelvic obliquity, the pelvis was made horizontal by applying more weight to the higher side. A posterior midline skin incision was made, and the laminae, facet joints, transverse processes, and costovertebral joints were exposed. Soft tissue and facet joint contractures on the concave side were completely released, and facet joint osteotomies were performed. In the rigid levels, the intertransverse and supraspinous ligaments were excised. Once adequate posterior relaxation was achieved, pedicle screws (Legacy; Medtronic, Minneapolis, MN, USA) were bilaterally placed into all the vertebrae to be fused. After the correction, autografts harvested from the patient were applied and posterior fusion was completed. Neurological status was constantly assessed

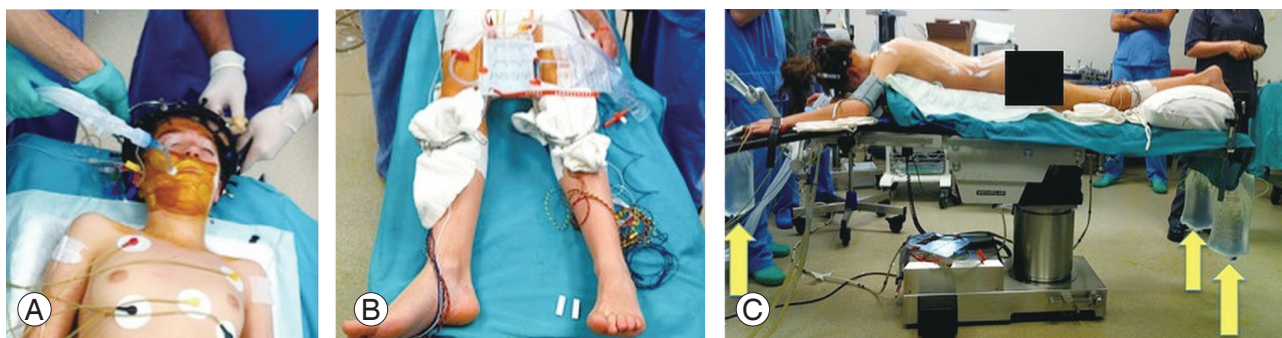


Fig. 1. (A–C) Placement of halo apparatus and bilateral distal femoral pins. The patient was then turned prone, and weights were applied to both the femurs and the head (arrows).

throughout the surgery using intraoperative neurophysiological monitoring (NIM, Medtronic). The traction was discontinued after the rods were placed and final correction was made. To achieve shoulder balance, compression was applied onto the convex aspect of the proximal thoracic curve until the T1 vertebra and the head of the first rib became level on intraoperative fluoroscopic views. All the patients were mobilized on postoperative day 1.

Results

The study group comprised six males and 18 females (mean age, 17.4 years; range, 15–25 years). The mean follow-up period was 33.5 months (range, 24–45 months), mean patient weight was 61.9 kg (range, 47–74 kg), and the mean total maximum traction force was 23 kg (range, 18–30 kg). According to the Lenke classification, scoliosis was type 1 in 11 patients, type 3 in 11 patients, type 4 in one patient, and type 6 in one patient. The mean number of segments involved in fusion was 14. To achieve an adequate shoulder balance, the upper instrumented vertebra was T2 in all the patients and the lower instrumented vertebra was L3 in 20, L4 in two, and L1 in two patients (Table 1). The pars defect in the L5 vertebra of one patient was treated during the same surgery (Fig. 2).

The degrees and flexibilities of the curves of the patients were as follows: the mean degree and flexibility of the major curve were 80.1° (range, 70°–90°) (Fig. 3) and 21.1% (range, 11.4%–33.1%), respectively, and those of the major compensatory curve were 36° (range, 23°–51°) and 21%, respectively. Two years postoperatively, the mean major thoracic curve was 11.6° (range, 3°–20°), mean correction rate in the major curve was 85.7% (range, 80.0%–95.7%), major compensatory curve was 6° (range, 0°–11°), mean

rate of correction in the major compensatory lumbar curve was 83.3%, mean sagittal curve was 51° (range, 44°–67°), and mean rate of reduction in the major sagittal curve was 37.9%. During the final follow-up examination, correction losses of 2.8° in the major thoracic curve and 2° in the major sagittal curve were noted (Table 2).

The mean operative blood loss was 2,550 mL (range, 1,800–5,000 mL), and the mean surgical time was 5.2 hours (range, 4.5–7 hours). The mean functional vital capacity was 2.96 L preoperatively and 4.12 L at the end of the first-year follow-up (39% improvement). Preoperative and postoperative SRS-22 measurements were 2.37 and 4.11 for function, 3.55 and 4.77 for pain, 1.48 and 4.51 for self-image, 2.23 and 4.71 for mental health, and 1.70 and 4.65 for satisfaction, respectively.

One patient experienced hip pain that started postoperatively and resolved within 2 weeks with analgesic treatment. One patient experienced neck pain for 1 week that resolved with analgesic treatment. Decreased motor potential was observed in one patient after the insertion of the rods and during correction with the in situ bender. In this patient, the traction was immediately discontinued and the correction was continued without traction. There were no postoperative neurological problems. One patient with bilateral pars defects underwent repair during the same surgery. None of the patients developed infection, pseudoarthrosis, neurological deficit, or HFT-related complications.

Discussion

The degree and flexibility of the curve are the major factors determining the indication for and type of surgery in AIS patients. These patients often undergo surgery earlier

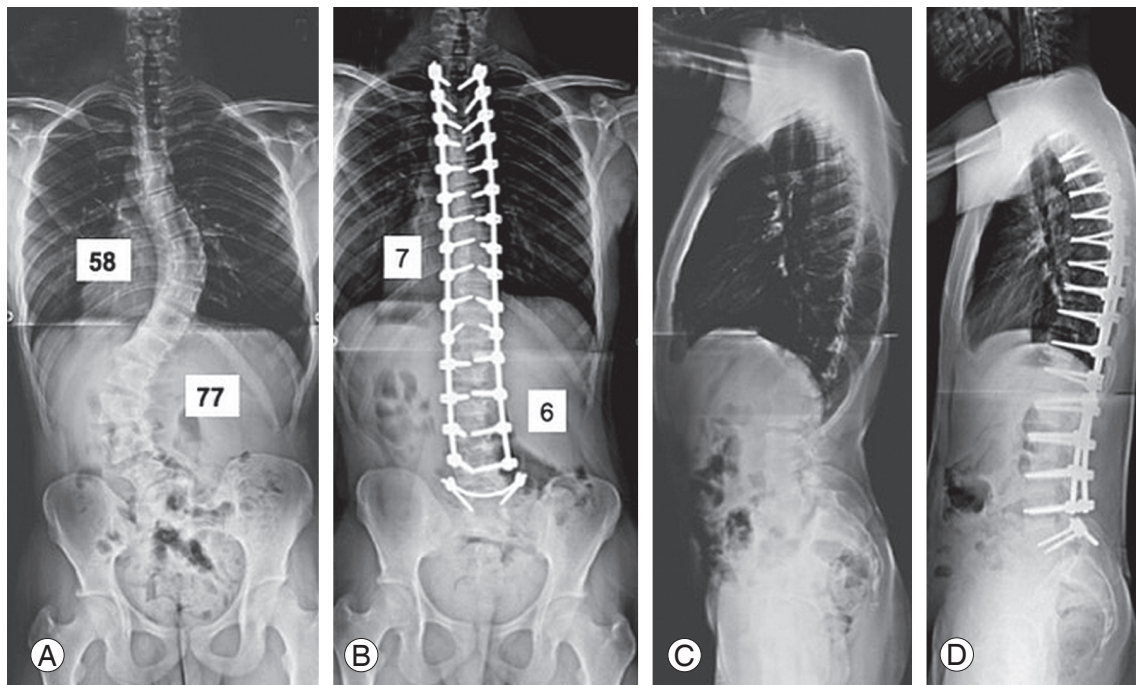


Fig. 2. A 19-year-old male patient who underwent posterior instrumentation and fusion with intraoperative halo-femoral traction. Anteroposterior (A, B) and lateral (C, D) radiographs preoperatively and at postoperative 2-year follow-up. The pars defect in the L5 vertebra was treated during the same surgery.

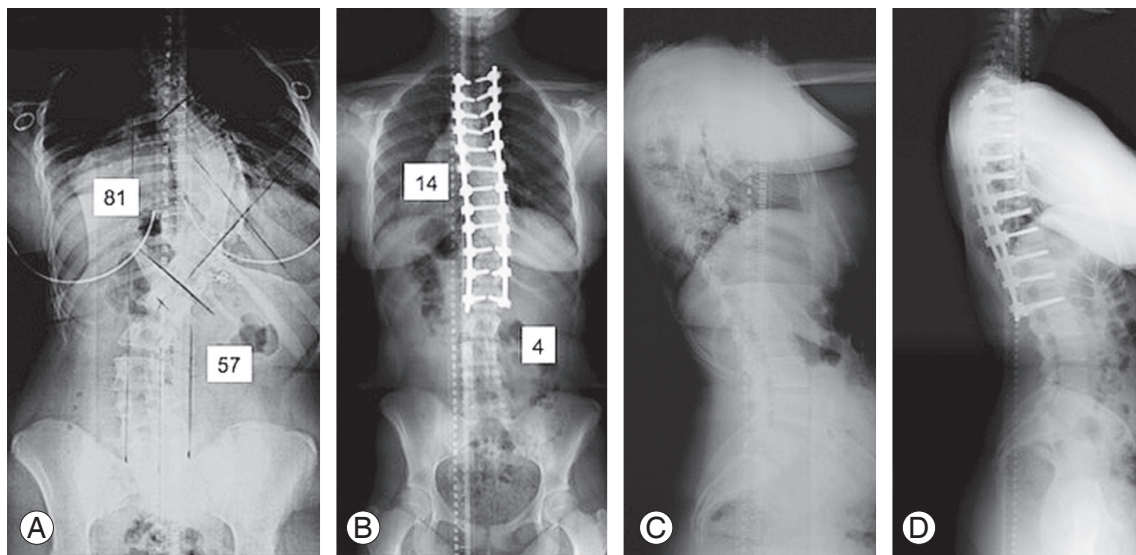


Fig. 3. A 19-year-old female patient who underwent posterior instrumentation and fusion with intraoperative halo-femoral traction. Anteroposterior (A, B) and lateral (C, D) radiographs preoperatively and at postoperative 2-year follow-up.

when the curves are flexible, and high correction rates can be achieved with only one surgery using the posterior approach. The use of pedicle screws together with instrumentation, as well as the three-dimensional correction of the curve have yielded successful results with primary

posterior instrumentation in the surgical management of scoliosis, especially in patients with curves between 40° and 70° [1]. Curves >70° are classified as severe, especially those >90°, and are treated using multiple techniques, including posterior instrumentation, anterior release, and

Table 1. Patients' demographic and operative data

Patient no.	Age (yr)	Sex	Follow-up (mo)	Max. traction weight (kg)	Lenke type	Fusion levels	Fused segments
1	25	F	44	24	4	T2-L3	14
2	15	F	43	22	3	T2-L3	14
3	17	F	37	20	3	T2-L4	15
4	19	M	37	30	6	T2-L4 ^{a)}	15
5	22	F	34	18	1	T2-L3	14
6	16	F	33	24	1	T2-L1	12
7	18	M	33	24	3	T2-L3	14
8	17	F	32	20	1	T2-L3	14
9	21	F	29	28	3	T2-L3 ^{b)}	14
10	19	F	27	24	1	T2-L3	14
11	16	F	25	20	1	T2-L3	14
12	18	F	24	20	1	T2-L3	14
13	15	F	28	24	3	T2-L3	14
14	17	M	32	22	1	T2-L1	12
15	16	F	39	24	3	T2-L3	14
16	18	M	30	28	3	T2-L3	14
17	16	F	24	20	1	T2-L3	14
18	15	F	26	22	3	T2-L3	14
19	17	M	38	24	3	T2-L3	14
20	19	F	40	24	1	T2-L3	14
21	16	F	45	22	3	T2-L3	14
22	14	F	29	20	3	T2-L3	14
23	15	F	39	23	1	T2-L3	14
24	17	M	36	24	1	T2-L3	14
Average	17.4		33.5	23			14

F, female; M, male.

^{a)}The patient had a pars interarticularis defect at the L5 level. ^{b)}The patient had hip pain for 2 weeks, which resolved with analgesic and rest.

osteotomy. In cases with curves between 70° and 90°, the flexibility of the curve is important when selecting the treatment for a successful correction. In such cases, the aim is to increase the flexibility of the curve by applying intraoperative HFT, thereby completing the correction with primary posterior instrumentation and achieving high correction rates. In the present study, we investigated the outcomes in patients who had curves with Cobb angles between 70° and 90° and flexibility <35% and who underwent single-stage surgery comprising only posterior instrumentation with intraoperative HFT and no osteotomy or anterior release.

Numerous methods have been described to achieve adequate correction and successful surgical outcomes in the treatment of AIS with a Cobb angle >70°. Zhou et al. [4]

reported satisfactory outcomes using anterior and posterior vertebral column resection in patients with curves >90° and flexibility <20%. In another study, anterior release was applied with internal distraction and posterior fusion to treat curves >90° with flexibility <30% [5]. Others have suggested posterior vertebral column resection for curves >80° and flexibility <25% [3]. For scoliosis curves between 70° and 100°, posterior fusion performed with thoracic pedicle screws showed results equivalent to those of anterior/posterior fusion [9]. Similarly, for curves >90°, Dobbs et al. [10] reported no difference in correction between posterior fusion only versus anterior/posterior fusion. However, they underlined the difficulty in inserting the pedicle screws at the curve apex and recommended that the procedure should be performed by an experienced

Table 2. Curve characteristics of the patients

Patient no.	Preoperative (°)	Flexibility (%)	Postoperative 3 wk (°)	Final follow-up (°)	Final curve correction (%)
1	90	11.4	10	15	83.3
2	70	17.8	8	12	82.8
3	71	32.7	0	3	95.7
4	77	14.0	9	11	85.8
5	75	27.8	7	10	86.6
6	81	19.5	8	14	82.7
7	86	33.1	12	12	86.0
8	77	28.7	3	8	89.6
9	73	13.6	10	11	84.9
10	90	15.8	12	18	80.0
11	80	22.4	10	14	82.5
12	76	20.6	6	10	86.8
13	86	18.7	18	20	76.8
14	83	27.7	14	16	80.7
15	78	13.4	10	10	87.2
16	90	22.2	13	15	83.3
17	76	18.4	2	4	94.7
18	78	18	4	6	92.1
19	84	26.2	8	10	88.1
20	79	24.1	6	9	88.6
21	88	15.9	14	16	81.8
22	82	14.6	10	12	85.4
23	74	25.7	5	6	91.9
24	84	23.8	12	16	81
Average	80.1	21.1	8.8	11.6	85.7

The flexibility of the curves was calculated using supine bending radiographs $\{100 \times (\text{preoperative major curve}^\circ - \text{bending major curve}^\circ) / \text{preoperative major curve}\}$.

surgeon. A significant finding of our study was that intraoperative HFT enabled primary posterior instrumentation to provide adequate stabilization of curves between 70° and 90°. For curves >90°, correction was applied with posterior Smith-Peterson osteotomies in accordance with the flexibility of the curve. Hamzaoglu et al. [6] also used HFT to treat curves >100°; they reported that the mean preoperative major thoracic curve magnitude of 122° decreased to 60° postoperatively (51% correction).

The aim of surgical treatment for rigid and major thoracic curves is to achieve an acceptable balance in the spine and fuse as few segments as possible, rather than performing maximum correction. HFT provides passive correction after the induction of general anesthesia and

prior to surgery, thereby decreasing the risk for any neurological deficit that may arise due to the sudden reduction [11]. In addition, coronal balance is more effectively achieved under the effect of traction. The weights are gradually increased during wide soft tissue releases and facet excisions, eliminating the need for reduction maneuvers. Before inserting the screws, the decrease in the rotation of the curve under the effect of traction especially facilitates the insertion of the screws at the curve apex. Bilateral application of the screws to all the segments included in the fusion, as performed in our series, increases the achieved correction force and decreases the screw pullout and postoperative correction loss.

Investigations related to preoperative intramedullary

pathologies and the presence of cervical instability are crucial in patients for whom HFT is planned. The reported HFT-related complications are neurological complications, pin loosening and pin tract infection, brain abscess, cranial nerve palsy, avascular necrosis of the odontoid process, and cervical spondylosis [12-17]. These complications generally develop due to a longer traction time and greater traction force. None of these complications was observed in our study patients as the traction was applied only during the surgical period, a traction force exceeding 40% of patient's body weight was avoided, and patient's neurological status was closely followed with constant neuromonitoring. Although HFT increases the total anesthesia time, it also decreases the surgical time because reduction is facilitated.

One of the most important clinical results of our study was the high correction rate achieved. Previous studies have reported various correction rates using various methods to manage curves $>70^\circ$. Sink et al. [13] used perioperative halo-gravity traction and achieved 35% correction in 19 patients with Cobb angles between 63° and 100° . Rinella et al. [2] used perioperative halo-gravity traction and obtained 46% correction in 33 patients with Cobb angles between 22° and 158° . In patients with Cobb angles between 70° and 100° , Luhmann et al. [9] performed anterior posterior fusion in 22 and posterior fusion in 62 patients and reported correction rates of 58.5% and 44.3%, respectively. Arlet et al. [18] reported a 54% correction rate and Burton et al. [19] reported a 64% correction rate with posterior fusion in 15 (Cobb angles between 70° and 90°) and 50 (Cobb angles between 70° and 88°) patients, respectively. In our study, the major curve correction rate was 85.7%. The most significant factor in reaching this rate was attaining curve correction by mostly passive means, without the need for serious reduction maneuvers. Thus, high correction rates can be achieved without procedures that entail higher morbidity rates, such as anterior fusion, posterior osteotomy, or column resection.

The major limitation of this study was failure to obtain an intraoperative radiograph due to the mechanism of the traction. A cassette could not be inserted under the operating table because of the pulley mechanism, thus, precluding radiographic imaging during various stages of the surgery and preventing estimation of the amount of correction provided by the traction. The second limitation of our study was the lack of a control group of patients treated without HFT in the same patient population.

The third limitation was the relatively small number of patients and short follow-up period. Randomized, prospective, controlled studies with larger series and longer follow-up periods are required in the future.

Conclusions

In severe AIS patients with Cobb angles between 70° and 90° , using intraoperative HFT together with posterior instrumentation is an effective and reliable method. The gradually increased correction force decreases the risk for any neurological deficit; facilitates surgical reduction, especially screw insertion at the curve apex; and provides high correction rates. As it is applied only intraoperatively, traction-related complications are minimized. Other advantages of the technique include avoiding the potential morbidity related to anterior surgery, osteotomy, or vertebral column resection and achieving coronal and sagittal correction similar to that with combined surgeries.

Conflict of Interest

No potential conflict of interest relevant to this article was reported.

Author Contributions

Erdem MN, Aydogan M: conception and design; all authors: data acquisition; Erdem MN, Oltulu I, Karaca S: analysis of data; Erdem MN, Oltulu I, Sarı S: drafting of the manuscript; Erdem MN, Aydogan M: critical revision; Erdem MN, Aydogan M: administrative support; and Aydogan M: supervision.

References

1. Suk SI, Kim JH, Kim SS, Lim DJ. Pedicle screw instrumentation in adolescent idiopathic scoliosis (AIS). *Eur Spine J* 2012;21:13-22.
2. Rinella A, Lenke L, Whitaker C, et al. Perioperative halo-gravity traction in the treatment of severe scoliosis and kyphosis. *Spine (Phila Pa 1976)* 2005;30:475-82.
3. Suk SI, Chung ER, Kim JH, Kim SS, Lee JS, Choi WK. Posterior vertebral column resection for severe rigid scoliosis. *Spine (Phila Pa 1976)* 2005;30:1682-7.
4. Zhou C, Liu L, Song Y, et al. Anterior and posterior

- vertebral column resection for severe and rigid idiopathic scoliosis. *Eur Spine J* 2011;20:1728-34.
5. Zhou C, Liu L, Song Y, et al. Anterior release internal distraction and posterior spinal fusion for severe and rigid scoliosis. *Spine (Phila Pa 1976)* 2013;38:E1411-7.
 6. Hamzaoglu A, Ozturk C, Aydogan M, Tezer M, Aksu N, Bruno MB. Posterior only **pedicle screw instrumentation** with intraoperative halo-femoral traction in the surgical treatment of severe scoliosis (>100 degrees). *Spine (Phila Pa 1976)* 2008;33:979-83.
 7. Zhang HQ, Wang YX, Guo CF, et al. Posterior-only surgery with strong halo-femoral traction for the treatment of adolescent idiopathic scoliotic curves more than 100°. *Int Orthop* 2011;35:1037-42.
 8. Zhang HQ, Gao QL, Ge L, et al. Strong halo-femoral traction with wide posterior spinal release and three dimensional spinal correction for the treatment of severe adolescent idiopathic scoliosis. *Chin Med J (Engl)* 2012;125:1297-302.
 9. Luhmann SJ, Lenke LG, Kim YJ, Bridwell KH, Schootman M. Thoracic adolescent **idiopathic scoliosis** curves between 70 degrees and 100 degrees: is anterior release necessary? *Spine (Phila Pa 1976)* 2005;30:2061-7.
 10. Dobbs MB, Lenke LG, Kim YJ, Luhmann SJ, Bridwell KH. Anterior/posterior **spinal instrumentation** versus posterior instrumentation alone for the treatment of adolescent idiopathic scoliotic curves more than 90 degrees. *Spine (Phila Pa 1976)* 2006;31:2386-91.
 11. O'Brien JP, Yau AC, Smith TK, Hodgson AR. Halo pelvic traction: a preliminary report on a method of external skeletal fixation for correcting deformities and maintaining fixation of the spine. *J Bone Joint Surg Br* 1971;53:217-29.
 12. MacEwen GD, Bunnell WP, Sriram K. Acute neurological complications in the treatment of scoliosis: a report of the Scoliosis Research Society. *J Bone Joint Surg Am* 1975;57:404-8.
 13. Sink EL, Karol LA, Sanders J, Birch JG, Johnston CE, Herring JA. Efficacy of perioperative halo-gravity traction in the treatment of severe scoliosis in **children**. *J Pediatr Orthop* 2001;21:519-24.
 14. Victor DI, Bresnan MJ, Keller RB. Brain abscess complicating the use of halo traction. *J Bone Joint Surg Am* 1973;55:635-9.
 15. Tredwell SJ, O'Brien JP. Avascular necrosis of the proximal end of the dens: a complication of halo-pelvic distraction. *J Bone Joint Surg Am* 1975;57:332-6.
 16. Dove J, Hsu LC, Yau AC. The cervical spine after halo-pelvic traction: an analysis of the complications of 83 patients. *J Bone Joint Surg Br* 1980;62-B:158-61.
 17. Tredwell SJ, O'Brien JP. Apophyseal joint degeneration in the cervical spine following halo-pelvic distraction. *Spine (Phila Pa 1976)* 1980;5:497-501.
 18. Arlet V, Jiang L, Ouellet J. Is there a need for anterior release for 70-90 degrees masculine thoracic curves in adolescent scoliosis? *Eur Spine J* 2004;13:740-5.
 19. Burton DC, Sama AA, Asher MA, et al. The treatment of large (>70 degrees) thoracic idiopathic scoliosis curves with posterior instrumentation and arthrodesis: when is anterior release indicated? *Spine (Phila Pa 1976)* 2005;30:1979-84.