

Combined endothelial keratoplasty and clear lens extraction for corneal decompensation in irido-corneal endothelial syndrome

Vikas Mittal¹, Ruchi Mittal², Rajat Maheshwari³

A 38-year-old woman presented with corneal decompensation in left eye secondary to irido-corneal endothelial (ICE) syndrome. She underwent simultaneous Descemet's stripping endothelial keratoplasty (DSEK) and clear lens extraction with posterior chamber intraocular lens implantation. The surgery was accomplished comfortably without rupture of peripheral anterior synechiae (PAS). 5 weeks postoperatively, the graft was attached, the cornea was clear and best-corrected visual acuity improved from 20/400 to 20/30. DSEK combined with clear lens

extraction appears to be an effective measure to treat corneal decompensation in patients with ICE syndrome. Associated lens extraction in such cases increases the working space in anterior chamber for DSEK, which minimizes the intra-operative graft manipulation. This also avoids a future difficult cataract surgery in the presence of PAS and an endothelial graft, which may increase the chances of graft survival.

Key words: Clear lens extraction, corneal decompensation, endothelial keratoplasty, irido-corneal endothelial syndrome

Case Report

A 38-years-old lady was referred for corneal transplantation in left eye for corneal decompensation secondary to ICE syndrome. Best corrected visual acuity (BCVA) in right eye was 20/20, N/6 and in left eye was 20/400, N/60. Slit lamp examination of left eye showed diffuse corneal edema. Peripheral anterior synechiae (PAS) were intermittently present all around 360°. Details of iris, lens, and fundus were hazily seen due to corneal edema. Right eye examination was within normal limits [Fig. 1]. Intraocular Pressure and not pressures. (IOP) readings by applanation tonometry were 15 mmHg in right eye and 11 mmHg in left eye. Ultrasound pachymetry readings were 489 μ in right eye and 641 μ in left eye. Ultrasonic central anterior chamber depth (ACD) was 3.68 mm in right eye and 3.75 mm in left eye. Fundus examination including optic disc assessment was within normal limits in right eye. Central endothelial cell density as measured by non-contact specular microscope (Topcon SP 2000P) in right eye was 2316 cells/mm². Specular image acquisition was not possible in left eye due to marked corneal edema. Patient was diagnosed ICE syndrome with endothelial decompensation in left eye, and simultaneous DSEK and CLE with PCIOL implantation under peribulbar anesthesia was planned for her left eye.

Donor dissection was performed before the patient was called in operation room. 49-years-old, phakic, clinically 'very good' donor corneal tissue was used for surgery.

Access this article online	
Quick Response Code:	Website: www.ijo.in
	DOI: 10.4103/0301-4738.118435

¹Department of Cornea and Anterior Segment Services, ²Vitreoretina Services, ³Glaucoma Services, Sanjivni Eye Care, Model Town, Ambala City, Haryana, India

Correspondence to: Dr. Vikas Mittal, MS, Consultant, Cornea Services, Sanjivni Eye Care, Model town, Ambala City, Haryana-134002, India. E-mail: vikas_mittal@hotmail.com

Manuscript received: 22.12.10; Revision accepted: 12.04.12

Donor tissue was manually dissected into anterior 2/3rd and posterior 1/3rd of stroma using artificial anterior chamber (Madhu Instruments, New Delhi, India) and blunt lamellar dissectors (Ankur Metal Works, Kolkotta, India). Edematous corneal epithelium was removed to improve the visibility. A 5.5 mm superotemporal scleral tunnel was used for the surgery. The internal wound of this tunnel was made ahead of PAS. Anterior chamber (AC) was continuously formed by anterior chamber maintainer, attached to balanced salt solution (BSS). While attaching irrigation in the form of AC maintainer to the eye, it was ensured to avoid touching PAS. After performing circular curvilinear capsulorhexis (CCC) and hydro dissection, nucleus was delivered from sclero-corneal tunnel with the hydrostatic pressure of BSS. A single piece acrylic PCIOL was implanted in the capsular bag after cortical wash. Intracameral pilocarpine was used to keep the intraocular lens in position during graft insertion. In view of simultaneous EK, the planned postoperative refraction was -1.5 diopters. Descemet's membrane (DM) was scored and separated in a circular pattern (descemetorhexis) in peripheral cornea central to PAS with the help of a reverse Sinsky hook and removed from anterior chamber. Trypan blue was not used, and descemetorhexis was done against red glow of clear crystalline lens. Pre-dissected donor tissue was trephined using 8.0 mm disposable corneal trephine (Madhu Instruments, New Delhi, India). The diameter of the trephine was selected after measuring the PAS free central cornea with calipers and subtracting 1 mm from it. The idea was to avoid graft-PAS touch. A sheet's glide was placed in the scleral wound such that the tip of the glide covers the pupil. The part of the glide outside the wound was covered with cohesive viscoelastic substance (Healon, Abbott Medical optics). Posterior stromal donor tissue with healthy endothelium was also covered with same viscoelastic substance on endothelial side and separated from anterior layer. The graft was placed on the sheet's glide with endothelium facing down and slipped into AC with the help of Sinsky hook. The graft was secured in position by filling anterior chamber (AC) with air and centered by stroking on the surface of host cornea. It was ensured that the edge of the graft doesn't touch PAS anywhere. The air was replaced with balanced salt solution 1 hour after the surgery. (Video; Supplementary File).

Postoperatively, the patient was prescribed topical gatifloxacin 0.3% 4 times per day for 2 weeks and topical prednisolone acetate 1% 6 times per day, which was tapered in 3 months. After 3 months, patient was advised topical fluorometholone 0.1% once per day indefinitely. There was no IOP spike postoperatively at any time till last follow-up (1 year).

Corneal edema cleared completely in 5 weeks with a best corrected visual acuity (BCVA) of 20/30 (-2.5DSph/ -3.0D cyl @ 120 degrees). This improved further to 20/20 at last follow-up visit of patient (1 year post-op). There was no interface haze. Central endothelial cell count at 6 months was 1315 cells/mm² with coefficient of variation in cell size of 47. It was stable (1290 cells/mm²) till last follow-up (1 year). Postoperative central ultrasonic pachymetry was 590 microns in left eye. Iris atrophic patches were visible through clear cornea [Fig. 2]. Gonioscopic examination of left eye showed patches of peripheral anterior synechiae in all quadrants,

which were documented with anterior segment OCT [Fig. 3]. IOP (18 mmHg), optic disc assessment (0.5: 1 Cup: Disc ratio with healthy neuroretinal rim) and visual field evaluation

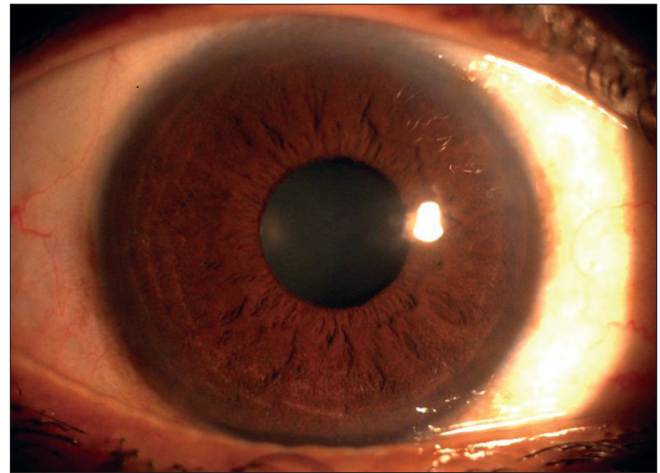


Figure 1: Right Eye showing normal iris pattern

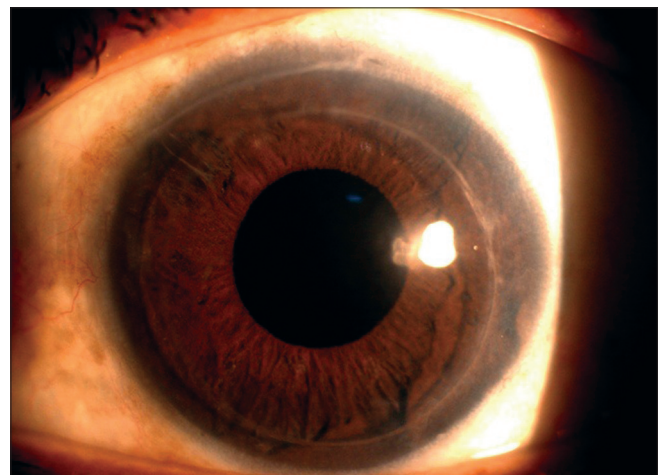


Figure 2: Left Eye- 2 month's postoperative clinical picture showing iris atrophy patches and peripheral anterior synechiae (PAS)

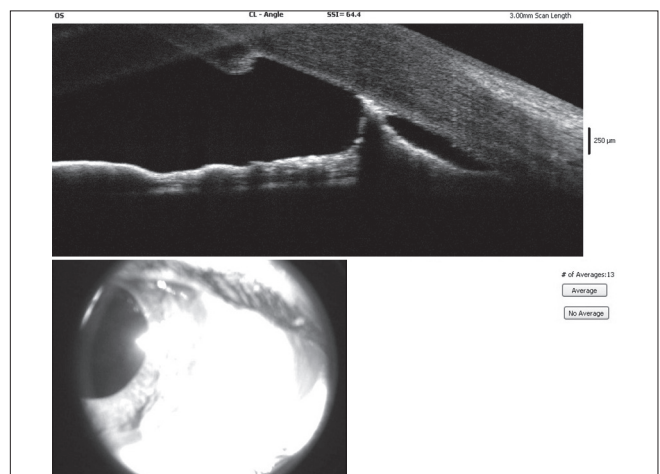


Figure 3: Left Eye- 2 month's postoperative anterior segment OCT scan showing edge of graft and PAS

(Humphrey's field analyzer) were within normal limits. Since there was no evidence of glaucoma in either eye, no antiglaucoma medications were prescribed.

Discussion

There has been a paradigm shift in the management of endothelial dysfunctions in the last few years, and endothelial keratoplasty is now a widely-accepted treatment of choice for endothelial dysfunctions of varied etiology.^[7-9] DSEK has several advantages over PKP like an early rehabilitation, better quality of vision, better retention of recipient corneal structural integrity and innervation and no suture related complications.^[7,8] Since endothelial decompensation is most common cause of dimness of vision in ICE syndrome, EK may be a preferred treatment over PKP in such cases.^[4-6]

However, DSEK is technically challenging in phakic patients with ICE syndrome. PAS, iris abnormalities, and a shallow anterior chamber characterize eyes with ICE syndrome. Presence of PAS in particular makes endothelial keratoplasty in these cases more challenging because it reduces the operating space in anterior chamber, tend to bleed if ruptured intraoperatively and may increase the chances of rejection if the graft is in contact with PAS. The reduction of the available operating space makes the posterior stromal graft insertion and positioning difficult. The extra manipulation hence required, may increase the endothelial cell damage. With an intention of increasing this operating space, clear lens extraction (CLE) was performed before implanting the endothelial graft. It increased the surgical ease of endothelial keratoplasty and minimized the graft manipulation. Since the operating space was more, we could easily avoid touching PAS and hence could avoid bleeding and related difficulties in surgery. Also, since our patient was 40 years old and would be on long-term topical steroids, there was high possibility of developing a cataract.^[10] In a retrospective study by Tsui *et al.*, 4 out of 10 cases that underwent phakic EK in Fuchs endothelial dystrophy developed cataract within 1 year.^[11] After cataract surgery, one eye developed graft failure requiring repeat EK. To avoid future cataract surgery and hence chance of graft failure, clear lens extraction during endothelial keratoplasty has been described for phakic intraocular lens-induced corneal decompensation.^[12,13] In our patient, future cataract surgery in the presence of PAS and endothelial graft could have been technically challenging and affected the survival of graft. It was avoided by removal of clear lens during endothelial keratoplasty. In present case, we selected the graft size in such a way that the edges of the graft do not touch the existing PAS. Hence, the additional chances of endothelial rejection were avoided while retaining the advantages of EK.

We preferred sheet's glide for graft insertion over any other technique of EK because of presence of PAS. Sheet's glide assisted graft insertion involved minimal graft manipulation in AC, and surgery was accomplished without any complication.

The main endothelial cell loss during endothelial keratoplasty is during surgery, and the cell loss tends to stabilize after an initial loss.^[14] Since pre-operative endothelial cell density of donor cornea was not available, it is difficult to comment on endothelial cell loss during the surgery, but endothelial cell

density remained stable between 6 months and 1 year of follow-up, and cornea maintained its clarity.

Combined procedure saves the patient from multiple surgical procedures along with their entailing cost and risks. However, the long-term comparative outcomes are needed to ascertain the usefulness of combined procedure over DSEK alone in such patients.

To conclude, combined clear lens extraction and DSEK may be a safe approach in patients with corneal decompensation due to ICE syndrome.

References

1. Eagle RC Jr, Font RL, Yanoff M, Fine BS. Proliferative endotheliopathy with iris abnormalities. The iridocorneal endothelial syndrome. *Arch Ophthalmol* 1979;97:2104-11.
2. Eagle RC Jr, Font RL, Yanoff M, Fine BS. The iris naevus (Cogan-Reese) syndrome: Light and electron microscopic observations. *Br J Ophthalmol* 1980;64:446-52.
3. Crawford GJ, Stulting RD, Cavanagh HD, Waring GO III. Penetrating keratoplasty in the management of iridocorneal endothelial syndrome. *Cornea* 1989;8:34-40.
4. Huang T, Wang Y, Ji J, Gao N, Chen J. Deep Lamellar Endothelial Keratoplasty for Iridocorneal Endothelial Syndrome in Phakic Eyes. *Arch Ophthalmol* 2009;127:33-6.
5. Price MO, Price FW Jr. Descemet's stripping endothelial keratoplasty for treatment of iridocorneal endothelial syndrome. *Cornea* 2007;26:493-7.
6. Bahar I, Kaiserman I, Buys Y, Rootman D. Descemet's stripping with endothelial keratoplasty in iridocorneal endothelial syndrome. *Ophthalmic Surg Lasers Imaging* 2008;39:54-6.
7. Gorovoy MS. Descemet's stripping automated endothelial keratoplasty (DSAEK). *Cornea* 2006;25:886-9.
8. Basak SK. Descemet's stripping and endothelial keratoplasty in endothelial dysfunctions: Three-month results in 75 eyes. *Indian J Ophthalmol* 2008;56:291-6.
9. Mittal V, Mittal R, Sangwan VS. Successful descemet stripping endothelial keratoplasty in congenital hereditary endothelial dystrophy. *Cornea* 2011;30:354-6.
10. Price MO, Price DA, Fairchild KM, Price FW Jr. Rate and risk factors for cataract formation and extraction after Descemet stripping endothelial keratoplasty. *Br J Ophthalmol* 2010;94:1468-71.
11. Tsui JY, Goins KM, Sutphin JE, Wagoner MD. Phakic descemet stripping automated endothelial keratoplasty: Prevalence and prognostic impact of postoperative cataracts. *Cornea* 2011;30:291-5.
12. Alió JL, Abdelrahman AM, Javaloy J, Iradier MT, Ortuño V. Angle supported anterior chamber phakic intraocular lens explantation: Causes and outcome. *Ophthalmology* 2006;113:2213-20.
13. Mittal V, Mittal R, Singh D. Simultaneous bilensectomy and endothelial keratoplasty for angle-supported phakic intraocular lens-induced corneal decompensation. *Indian J Ophthalmol* 2011;59:314-7.
14. Rice A, Spokes DM, Anand S, Ball JL. Endothelial cell survival and graft profile analysis in descemet stripping endothelial keratoplasty. *Cornea* 2011;30:865-71.

Cite this article as: Mittal V, Mittal R, Maheshwari R. Combined endothelial keratoplasty and clear lens extraction for corneal decompensation in iridocorneal endothelial syndrome. *Indian J Ophthalmol* 2014;62:651-3.

Source of Support: Nil. **Conflict of Interest:** None declared.