

Low-voltage electricity-induced lung injury

Thai Truong¹ , Thuong Vu Le¹, David L. Smith², Stephen P. Kantrow³ & Van Ngoc Tran¹

¹Department of Internal Medicine, Faculty of Medicine, University of Medicine and Pharmacy, Ho Chi Minh City, Vietnam.

²Department of Radiology, Louisiana State University Health Sciences Center, School of Medicine, New Orleans, LA, USA.

³Section of Pulmonary/Critical Care and Allergy/Immunology, Louisiana State University Health Sciences Center, School of Medicine, New Orleans, LA, USA.

Keywords

Electrical visceral injury, haemoptysis, lung necrosis, pulmonary oedema, rhabdomyolysis.

Correspondence

Thai Truong, Department of Internal Medicine, Faculty of Medicine, University of Medicine and Pharmacy, 217 Hong Bang, Ward 11, District 05, Ho Chi Minh City 700000, Vietnam.

E-mail: truongthaiavn2003@gmail.com

Received: 11 October 2017; Revised: 26 November 2017;

Accepted: 30 November 2017; Associate

Editor: Bei He.

Respirology Case Reports, 6 (2), 2018, e00292

doi: 10.1002/rcr2.292

Abstract

We report a case of bilateral pulmonary infiltrates and haemoptysis following low-voltage electricity exposure in an agricultural worker. A 58-year-old man standing in water reached for an electric watering machine and sustained an exposure to 220 V circuit for an uncertain duration. The electricity was turned off by another worker, and the patient was asymptomatic for the next 10 h until he developed haemoptysis. A chest radiograph demonstrated bilateral infiltrates, and chest computed tomography (CT) revealed ground-glass opacities with interstitial thickening. Evaluations, including electrocardiogram, serum troponin, N-terminal pro-B-type natriuretic peptide (NT-pro BNP), coagulation studies, and echocardiogram, found no abnormality. The patient was treated for suspected electricity-induced lung injury and bleeding with tranexamic acid and for rhabdomyolysis with volume resuscitation. He recovered with complete resolution of chest radiograph abnormalities by Day 7. This is the first reported case of bilateral lung oedema and/or injury after electricity exposure without cardiac arrest.

Introduction

Electricity-induced lung injury has rarely been reported but may occur after high or low voltage exposure. In the only example of pulmonary oedema due to electrical injury in the literature, arrhythmia leading to cardiac arrest was considered to be the cause [1]. In other reported cases, the electric current appears to directly injure lung tissue, with focal consolidation on radiographs and necrosis and coagulation on histopathological examination [2,3]. The electrical injury may lead to additional complications, such as haemoptysis, acute respiratory distress, and infection. We report a case of bilateral pulmonary infiltrates and haemoptysis after low-voltage electricity exposure.

Case Report

A 58-year-old man suffered a low-voltage (220 V source) electric shock while working in a drainage ditch. While standing in water to his ankles, he reached for an electric watering machine with his right hand. During the shock, he fell down with his back against the edge of ditch, his

feet in the water and unable to release the watering machine from his right hand. A witness observed him lying in the ditch and turned off the electric supply after an uncertain duration. There was no loss of consciousness reported and no witnessed seizure activity. The accident was 600-m away from the power source, with the actual electric potential expected to decrease from 220 V to approximately 180 V.

Ten hours later, he coughed up about 20 mL of bright red blood, leading to hospital admission. He denied having fever, chest pain, or shortness of breath. He had no past medical history of respiratory or cardiovascular disease. Vital signs showed a pulse rate of 90 beats/min, a respiratory rate of 20 breaths/min, a temperature of 37°C, an arterial blood pressure of 120/80 mmHg, and a room-air peripheral capillary oxygen saturation (SpO₂) of 95%. Physical examination revealed scattered crackles in both lungs and a full-thickness burn in his right palm. His chest radiograph demonstrated heterogeneous opacities in both lungs (Fig. 1A). His chest computed tomography (CT) scan demonstrated perihilar ground-glass opacities of

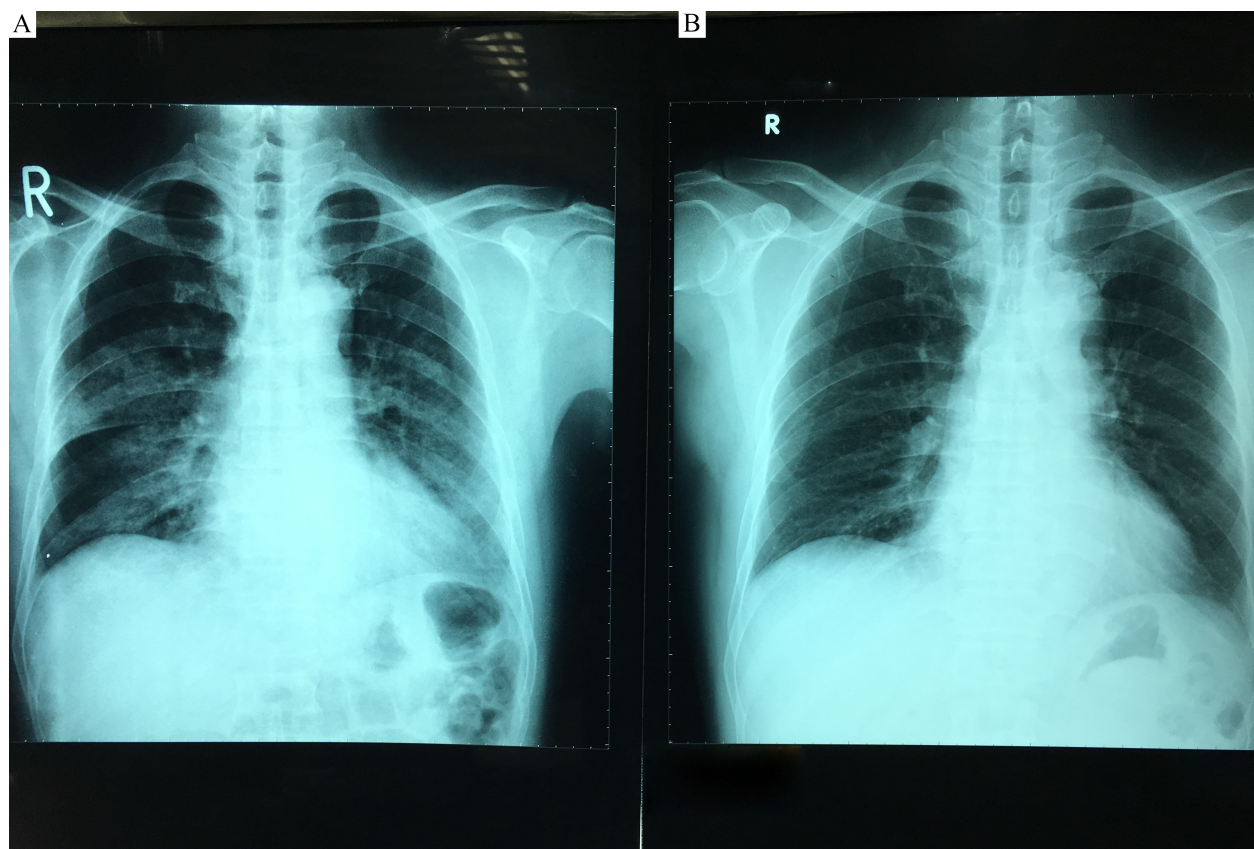


Figure 1. (A) Initial chest radiograph demonstrates heterogeneous opacities in both lungs. (B) Chest radiograph performed on day 7 shows complete resolution of the opacities.

both lungs with right upper lobe predominance, thickening of interlobular septa and intralobular lines, and diffuse bronchial wall thickening (Fig. 2). Laboratory results demonstrated the elevated assays of serum creatine phosphokinase (CPK), 1338 U/L; lactate dehydrogenase (LDH), 466 U/L; creatine kinase-MB (CK-MB), 57 U/L; and aspartate aminotransferase (AST), 64 U/L. Urine myoglobin performed on Day 2 was negative. The serum troponin I and NT-pro BNP levels were 0.011 ng/mL and 0.1 pmol/L, respectively. The platelet count, prothrombin time, and partial thromboplastin time were within normal range. No abnormality was found on an electrocardiogram (ECG). Normal cardiac function was observed on an echocardiogram performed on hospital Day 1. The sputum culture and acid-fast bacillus stains were negative.

The patient was suspected to have electricity-induced lung injury complicated by haemoptysis and rhabdomyolysis. He was treated with intravenous (i.v.) tranexamic acid (500 mg twice per day for 7 days) and i.v. normal saline (1500 mL per day for 4 days). Serum CPK and LDH decreased to 74 and 392 U/L, respectively, by Day 6. Renal function remained normal (blood urea nitrogen 14 mg/dL,

serum creatinine 0.85 mg/dL). Chest radiograph performed on Day 7 showed complete resolution of the opacities, and the patient was discharged (Fig. 1B).

Discussion

To our knowledge, there have been four English-language case reports of electricity-associated lung damage [1–4]. The first case was an episode of acute cardiogenic pulmonary oedema that followed electricity-induced ventricular fibrillation and cardiopulmonary resuscitation, with documentation of high pulmonary artery occlusion pressure, low cardiac index, and low oxygen saturation of mixed venous blood [1]. Two subsequent cases in electrical workers were due to the high-voltage electric current (≥ 1000 V), had focal consolidation on lung imaging, and were managed with surgical resection. Histopathological findings included lung infarction, coagulative necrosis, and lipid pneumopathy in one case on Day 4 and infarction, liquefaction, and abscess formation in the other on Day 27 [2,3]. Focal lung injury has also been reported in an electrical worker after a low-voltage shock (380 V)

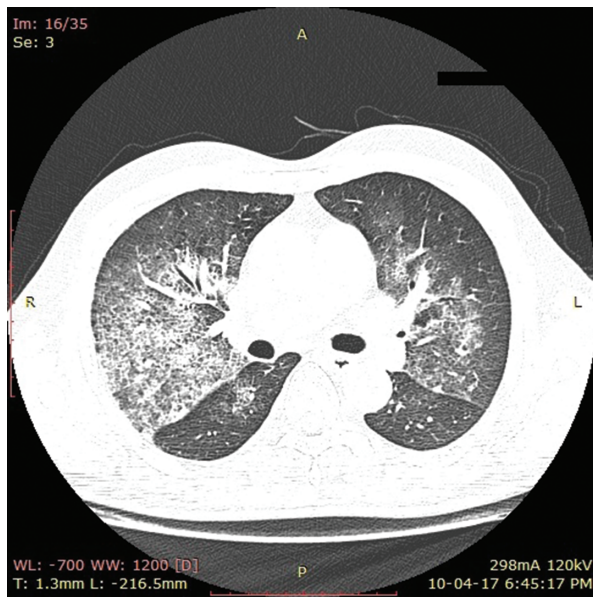


Figure 2. Chest computed tomography (CT) scan demonstrates perihilar ground-glass opacities of both lungs with right upper lobe predominance, thickening of interlobular septa and intralobular lines, and diffuse bronchial wall thickening.

complicated by respiratory arrest in the field and subsequent cerebral oedema. An area of consolidation in the right lower lobe noted at admission was managed medically, with no additional respiratory complications [4].

Our patient was exposed to low-voltage electrical current with an uncertain interval of contact. His cutaneous manifestations were focal and mild, but the correlation between cutaneous injury and visceral injury after electric shock is weak. Both thermal and non-thermal mechanisms may contribute to electricity-induced tissue injury. Electrical current through visceral tissues can cause Joule heating and irreversible denaturation of macromolecules throughout the cells [5]. In addition, electrical forces can lead to electroporation, in which polar amino acid residues reorient and cause conformational damage of channel

proteins [5]. These mechanisms may result in cell membrane dysfunction, injury, rupture, and necrosis. The severity of damage is associated with the characteristics of electric current, including magnitude, type, and direction, and by the interval of contact, resistance of the entrance point, and personal susceptibility [5].

Our case is the first report of acute bilateral pulmonary infiltrates due to electrocution without cardiac arrest. The radiographic features and haemoptysis we observed were consistent with pulmonary oedema (cardiogenic or non-cardiogenic) and/or a diffuse lung injury. Our investigations after admission did not identify myocardial necrosis, left ventricular dysfunction, or arrhythmia; however, temporary ventricular dysfunction or arrhythmia cannot be excluded. Direct injury by electrical current remains a possible mechanism in this case.

Disclosure Statement

Appropriate written informed consent was obtained for publication of this case report and accompanying images.

References

1. Schein RMH, Kett DH, Marchena EJD, et al. 1990. Pulmonary edema associated with electrical injury. *Chest* 97(5):1248–1250.
2. Masanes MJ, Gourbiere E, Prudent J, et al. 2000. A high voltage electrical burn of lung parenchyma. *Burns* 26(7):659–663.
3. Schleich AR, Schweiger H, Becsey A, et al. 2010. Survival after severe intrathoracic electrical injury. *Burns* 36(5): e61–e64.
4. Karamanli H, and Akgedik R. 2017. Lung damage due to low-voltage electrical injury. *Acta Clin. Belg.* 72(5):349–351.
5. Marques EGSC, Júnior GAP, Neto BFM, et al. 2014. Visceral injury in electrical shock trauma: proposed guideline for the management of abdominal electrocution and literature review. *Int. J. Burns Trauma* 4(1):1–6.