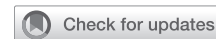

# The necessity of preoperative planning and nodule localization in the modern era of thoracic surgery

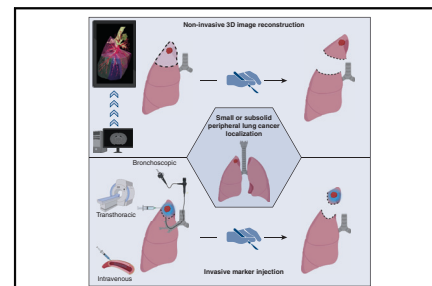


Stijn Vanstraelen, MD,<sup>a</sup> Gaetano Rocco, MD,<sup>a,b</sup> Bernard J. Park, MD,<sup>a</sup> and David R. Jones, MD<sup>a,b</sup>

The validation of the efficacy of lung cancer screening and the increasing use of computed tomography overall have led to an increased detection of small-sized and ground-glass opacity lung cancers.<sup>1,2</sup> Lobectomy for all isolated primary lung cancers has been the standard of care since the results of a randomized Lung Cancer Study Group 821 trial, reported in 1995.<sup>3</sup> Recently, 2 recent large randomized trials by Altorki and colleagues<sup>4</sup> and Saji and colleagues<sup>5</sup> have challenged this paradigm by demonstrating comparable recurrence-free and overall survival rates for sublobar resection when compared to lobectomy for small (<2 cm), peripheral nodules that are confirmed to be node-negative intraoperatively.

Within a similar time period, there has been a steady transition toward minimally invasive surgical approaches to the treatment of lung cancer with video-assisted thoracic surgery (VATS) and robotic approaches.<sup>6-8</sup> In cases where lesions have significant ground-glass opacification or are located deep within the lung parenchyma there can be challenges with intraoperative localization as well as the assessment of resection margins. In fact, several studies have shown that the likelihood of local recurrence significantly increases when the margin-to-tumor ratio is <1 or the absolute resection margin is <5 mm.<sup>9,10</sup>

To address these challenges, preoperative radiographic planning tools and localization methods have been developed to assist thoracic surgeons in identifying small and/or part-solid lung cancers. Although feasibility and efficacy have been demonstrated, the selection of the most appropriate modality in the context of curative treatment for early-stage lung cancer requires further evaluation. A comprehensive understanding of the current technical aspects, success rates, as well as the advantages and disadvantages of each modality, is essential to inform the decision-making process.



Overview of the possible techniques for precision localization of small pulmonary nodules.

## CENTRAL MESSAGE

Preoperative planning and localization are indispensable tools for surgical management of small pulmonary nodules in modern minimally invasive thoracic surgery.

## NONINVASIVE LOCALIZATION METHODS: PREOPERATIVE 3-DIMENSIONAL RECONSTRUCTION

To date, thoracic surgeons have primarily relied on 2-dimensional (2D) computed tomography imaging to locate lesions, assess resectability, determine the appropriate surgical resection, and plan for the necessary margins. Recent advancements in 3-dimensional (3D) imaging reconstruction technology, incorporating bronchovascular anatomy tracing and integration of artificial intelligence, have enabled enhanced localization of lesions within the various lung segments.<sup>11-13</sup> Bakhuis and colleagues<sup>12</sup> compared treatment plans based on 2D versus 3D imaging and found that the actual nodule site differed from what had been predicted using 2D imaging in 14% of cases. Moreover, comparative studies have consistently shown a lower incidence of inadequate margins when preoperative planning incorporates 3D reconstruction, as opposed to relying only on 2D imaging.<sup>12,13</sup> The same study by Bakhuis and colleagues<sup>12</sup> demonstrated that the treatment plan required adjustment in 52% of the patients to ensure adequate margins.

Preoperative 3D reconstruction technology can identify 98% of the anatomical variations by improving the visualization of the spatial relationship between the lesion and the bronchopulmonary vasculature, allowing for more precise dissection.<sup>11</sup> As a result, segmentectomy with 3D reconstruction has been associated with notable reductions in operative time (relative risk, 0.043;  $P = .021$ ) and operative blood loss (40.4 mL;  $P = .009$ ) when compared with 2D imaging.<sup>11,14</sup> Furthermore, 3D reconstruction could hold a significant educational value and can enhance anatomical knowledge and proficiency in surgical residency training.<sup>14</sup> In fact, residents trained with 3D models and exposed to thoracoscopic

From the <sup>a</sup>Thoracic Service, Department of Surgery, and <sup>b</sup>Fiona and Stanley Druckenmiller Center for Lung Cancer Research, Memorial Sloan Kettering Cancer Center, New York, NY.

Supported, in part, by the National Institutes of Health/National Cancer Institute Cancer Center Support Grant P30 CA008748.

Received for publication Nov 6, 2023; revisions received Dec 18, 2023; accepted for publication Jan 1, 2024; available ahead of print Feb 2, 2024.

Address for reprints: David R. Jones, MD, Thoracic Service, Department of Surgery, Memorial Sloan Kettering Cancer Center, 1275 York Ave, New York, NY 10065 (E-mail: [jonesd2@mskcc.org](mailto:jonesd2@mskcc.org)).

JTCVS Open 2024;18:347-52  
2666-2736

Copyright © 2024 The Author(s). Published by Elsevier Inc. on behalf of The American Association for Thoracic Surgery. This is an open access article under the CC BY-NC-ND license (<http://creativecommons.org/licenses/by-nc-nd/4.0/>).

<https://doi.org/10.1016/j.jtc.2024.01.004>

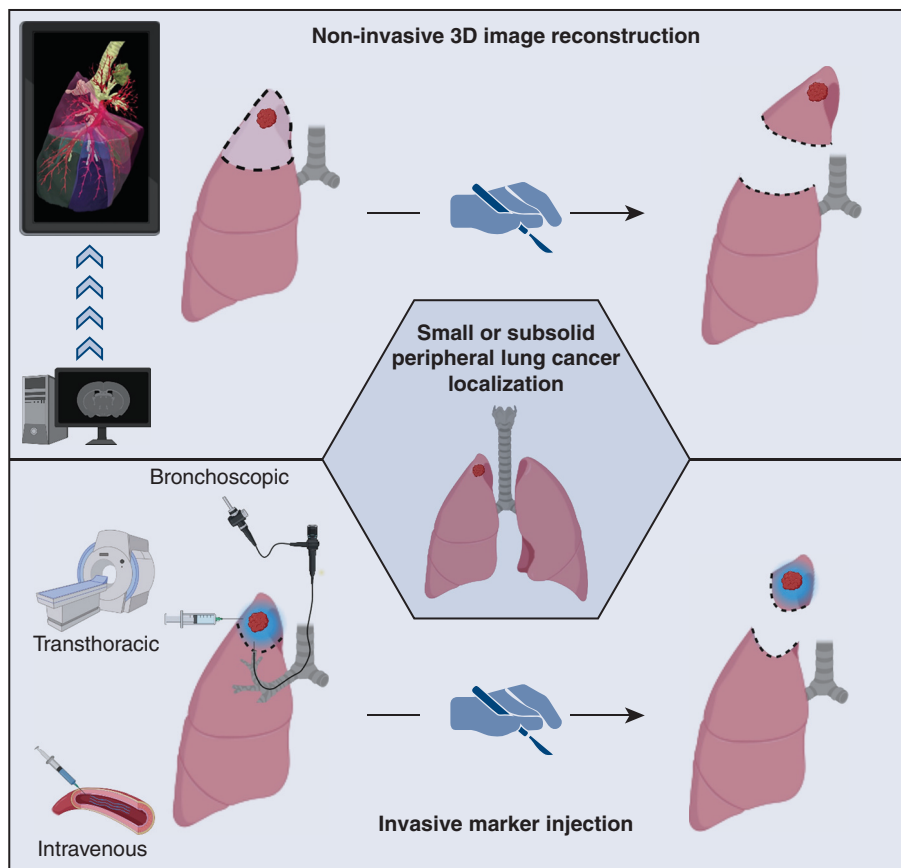
techniques can achieve operative times comparable to those of experienced surgeons who transitioned to the same video-assisted procedure without receiving 3D-model training.<sup>14</sup>

Nonanatomic sublobar resections were carried out in only a limited number of cases, accounting for up to 4% of resections following 3D reconstruction.<sup>11,12</sup> The difficulties associated with palpation during minimally invasive surgery in combination with shape alterations of the lung in the deflated state may preclude a safe estimation of oncologic margins for nonanatomical resections, which, in turn, may lead surgeons to more extensive resections.<sup>15</sup> Intraoperative cone beam computed tomography has shown promise in accurately identifying nodules within deflated lungs and could, to some extent, support nonanatomical sublobar resections.<sup>15</sup> However, this approach necessitates the use of intraoperative fluoroscopy and lead protection for operating room personnel. Consequently, performing nonanatomical sublobar resections based on 3D reconstruction alone can remain challenging and therefore may necessitate more invasive alternatives (Figure 1).

**INVASIVE LOCALIZATION METHODS**

Among the simplest techniques, probably, still is the transthoracic injection of radiolabeled technetium-99m macro-aggregated albumin in or near the pulmonary nodule, as described by Daniel and colleagues.<sup>16</sup> The macro-aggregated albumin utilized in this approach is retained in the lung parenchyma for up to 18 hours, albeit typically injected on the morning of the operation. Intraoperatively, a thin radio probe is used to locate the lesion and determine the margins based on the washout of the radio signal.

Reports have demonstrated the safety of this technique, with minor lung collapse occurring in approximately 10% of cases and successful identification and resection of pulmonary nodules achieved in approximately 99% of cases.<sup>17,18</sup> As an alternative, transthoracic injection of methylene blue or lipiodol have been explored. In the case of lipiodol injection, localization is less dependent on tumor depth, resulting in successful identification in 100% of cases.<sup>19</sup> However, lipiodol requires the use of intraoperative fluoroscopy and lead protection, whereas methylene blue is subject to rapid diffusion, influenced by the distance to the lung surface, and may potentially interfere with histopathologic assessment.<sup>19</sup> Furthermore, the placement of microcoils or hookwires can also aid in localizing more deeply located nodules, using intraoperative fluoroscopy.<sup>20</sup> However, due to the possibility of marker dislodgment and migration, the identification rate is noted to be around 95%.<sup>20</sup> A systematic review by Park and colleagues<sup>21</sup> demonstrated comparable localization rates among the use of microcoils, hookwires, and lipiodol injection, with lipiodol achieving the highest rates. Microcoils exhibited the lowest incidence of pneumothorax and hemorrhage (16% and 6%, respectively), compared with hookwires (35% and 16%, respectively) and lipiodol (31% and 12%, respectively). This advantage is suggested to be attributed to the design of the microcoils, featuring a platinum composition with thrombogenic fiber coating. Although rare, hookwire placement comes with the additional disadvantages of potential life-threatening air embolism.<sup>21</sup> Additionally, a study comparing the use of hookwires to radiotracer localization demonstrated comparable localization and resection rates (100% for both approaches) but a lower incidence of procedural pneumothoraxes following radiotracer localization (hookwire 69.2% vs radiotracer 24.2%;  $P < .0001$ ) and a tendency toward



**FIGURE 1.** Overview of the noninvasive and invasive approaches for precision localization of ground-glass opacities or small pulmonary nodules. Created with BioRender.

more lung-sparing excisions (hookwire 34.26 cc vs radiotracer 20.19 cc;  $P = .07$ ).<sup>22</sup>

Another interesting and less-invasive technique has been investigated by researcher of the ELUCIDATE (Enabling Lung Cancer Identification Using Folate Receptor Targeting) Study Group.<sup>23,24</sup> Leveraging the enhanced permeability and different retention effect of lung parenchyma and cancer tissue, they demonstrated that pulmonary nodules could retain indocyanine green, administered intravenously 24 hours before surgery, for a longer duration than normal lung parenchyma. This allowed for the identification of pulmonary nodules using near-infrared imaging during surgery in 83% of cases, with no reported complications. However, the successful localization was dependent on the depth of the nodule.<sup>23</sup> Expanding on the concept of enhanced tumor retention in combination with increased folate receptor expression, the same research group developed a folate-targeting molecular contrast agent called pafolacianine.<sup>24,25</sup> When injected intravenously 2-3 hours before surgery, pafolacianine exhibited high contrast with the background lung parenchyma on near-infrared imaging. Nevertheless, nodule identification remained primarily linked to the limited fluorescent feedback in more deeply located lesions (>1.5 cm).<sup>25</sup> Notably, the presence of occult synchronous lesions and the adequacy of margins could be assessed based on the fluorescent feedback of pafolacianine, leading to changes in the resection plan for 29% of patients.<sup>24,25</sup> The injection of pafolacianine resulted in drug-related minor adverse events in 17%.<sup>24</sup>

Instead of using transthoracic or intravenous injection, Sato and colleagues<sup>E1</sup> investigated the technique of bronchoscopic virtual-assisted lung mapping in a multicenter prospective trial involving 153 patients. This technique uses bronchoscopic 3D navigation to inject indigo carmine into the lung parenchyma, marking the margins around the pulmonary nodule with the bronchial tree serving as a reference (multi-spot dye-marking). The externally visible dye markings facilitate intraoperative localization and enable both anatomical and nonanatomical resections of the pulmonary nodule. Despite the overall intraoperative identification of 93% of the dye markers, the resection rates based on this technique varied between 25% and 100% and were dependent on the center’s experience as well as the depth of the parenchymal lesion. In fact, there was a 10% chance of resection failure when the lesion was located 3 cm from the lung surface.<sup>26</sup> The use of bronchoscopic injection demonstrated similar complication rates as transthoracic localization, including bulla formation in 10% and pneumothorax in 10% of cases, with 1 case necessitating chest tube placement.<sup>E2</sup> The same investigators leveraged the benefits of radiotracer localization (high accuracy) and bronchoscopic mapping (same session procedure) to bronchoscopically insert a radiofrequency emitting microchip in the close proximity of small (<1 cm) or deep (>1 cm from the pleural surface) pulmonary nodules.<sup>E2,E3</sup> In similarity to the radiotracer localization, a marker probe is used to locate the chip and consequently the

**TABLE 1. Summary of preoperative mapping and localization techniques**

Technique	Localization rate (%)	Advantages.	Disadvantages	Ref
<b>Noninvasive</b>				
Computed tomography 3-dimensional reconstruction	98	No invasive or second procedure required Detection of bronchopulmonary anomalies More accurate identification of involved segment No adverse events Low-cost	Less applicable for non-anatomical sublobar resection	11-13
<b>Invasive</b>				
Transthoracic technetium or lipiodol	99-100	Nonanatomical sublobar resection possible Possible for deeper nodules Margin assessment intraoperatively Low-cost	Second procedure necessary Gamma probe (Technetium) Fluoroscopy and lead protection (Lipiodol) Pleural spillage (Technetium)	16,17,19
Transthoracic microcoil or hookwire	95-97	Nonanatomical sublobar resection possible Possible for deeper nodules Low-cost	Second procedure necessary Fluoroscopy and lead protection Migration of the marker Pneumothorax/air embolism	20
Intravenous indocyanine green or folate target	83-100	Intravenous injection Good discrimination with background uptake Detection of occult synchronous lesion Margin assessment intraoperatively Nonanatomical sublobar resection possible	Deeper nodules more difficult to localize Near-infrared camera required More expensive	23-25
Bronchoscopic virtual-assisted lung mapping	93	Nonanatomical sublobar resection possible Possible for deeper nodules One session procedure	Longer operative time Expertise dependent (resection rate: 25-100%) (Robotic) bronchoscopic expertise required	E2
Radiofrequency microchip placement	100	Nonanatomical sublobar resection possible Possible for deeper nodules One session procedure	Longer operative time Bronchoscopic expertise required Limited signal diffusion for margin assessment	E3,E4

pulmonary nodule intraoperatively to facilitate anatomical or nonanatomical resection with adequate margins. The probe emits an electromagnetic field that activates the transmission of radiofrequency waves by the microchip. These waves are in turn detected by a receiver antenna within the probe.<sup>E3,E4</sup> The small series involving 11 patients demonstrated a localization and resection rate of 100% without procedural complications.<sup>E4</sup>

Given the array of existing and emerging techniques, each having its unique advantages and potential drawbacks, it is essential for thoracic surgeons to familiarize themselves with a variety of localization techniques. Subsequently, they can apply the most suitable strategy tailored to the patient or the specific nodule being targeted. Future research should prioritize the identification of the most effective technique, with respect to the characteristics of the nodule, to enhance proficiency and ensure adequate resection margins, particularly for nodules located at greater depths. Currently, due to its noninvasive features, 3D reconstruction may offer an advantage over the invasive approaches for patients requiring segmentectomy and for more centrally located lesions, often requiring anatomical resections.<sup>11,12</sup> Invasive approaches may hold an advantage in the setting of nonanatomical resections, whereas radiotracer and radiofrequency markers have demonstrated a potential benefit for deeper lesions.<sup>17,19</sup> However, in the current era of value-based health care, the cost associated with these approaches should also be considered. In this context, despite high initial software cost, 3D reconstruction could demonstrate cost-effectiveness, particularly in high-volume centers, by avoiding additional procedures involving personnel and consumables (transthoracic injection or bronchoscopy). Additionally, 3D reconstruction may reduce the number of inadequate resections that would require adjuvant therapy.<sup>12</sup> Similarly, the cost associated with transthoracic or navigational bronchoscopic marker placement, which requires secondary procedures or prolonged operative time, respectively, could potentially be mitigated by expediting the completion of the index operation. Nevertheless, integrating these procedures into the treatment paradigm will also necessitate rigorous organization and planning. Table 1 summarizes localization rates and advantages/disadvantages of the various existing techniques. Furthermore, given the increasing adoption of artificial intelligence, future research should also be focused on the integration of artificial intelligence into the computer software of white-light and near-infrared cameras. This integration has the potential to further improve intraoperative localization and margin assessment in sublobar resection during thoracoscopic surgery. As an illustrative example, a small-scale Phase I trial in patients with oropharyngeal cancer undergoing robotic-assisted resection demonstrated better differentiation between normal and cancerous tissue via fluorescence lifetime imaging enhanced by artificial intelligence.<sup>E4</sup>

## CONCLUSIONS

In the modern era of thoracic surgery, the increased detection of small-sized lung cancers through lung cancer screening, in conjunction with the growing adoption of minimally invasive sublobar resection, emphasizes the importance of incorporating preoperative planning and localization strategies into the existing treatment paradigms. At present, 3D reconstruction may offer an advantage over invasive approaches for patients requiring segmentectomy and for more centrally located lesions, whereas invasive approaches may hold an advantage in the setting of nonanatomical resections. The synergistic utilization of various techniques will undoubtedly play a crucial role in enabling efficient and oncologically sound minimally invasive resections of these small nodules,

particularly in cases involving ground-glass opacities or nonsubpleural lung cancer.

## Conflict of Interest Statement

Dr Park serves as a consultant for Intuitive Surgical, AstraZeneca, CEEVRA, and Medtronic. Dr Rocco has a financial relationship with Scanlan, AstraZeneca, and Medtronic. Dr Jones serves as a consultant or speaker for or has received grant support from Merck, AstraZeneca, Genentech, More Health, and DAVA Oncology. The other author has no conflicts of interest to disclose.

The *Journal* policy requires editors and reviewers to disclose conflicts of interest and to decline handling manuscripts for which they may have a conflict of interest. The editors and reviewers of this article have no conflicts of interest.

## References

1. The National Lung Screening Trial Research Team. Reduced lung-cancer mortality with low-dose computed tomographic screening. *N Engl J Med*. 2011;365:687-96.
2. de Koning HJ, van der Aalst CM, de Jong PA, Scholten ET, Nackaerts K, Heuvelmans MA, et al. Reduced lung-cancer mortality with volume CT screening in a randomized trial. *N Engl J Med*. 2020;382:503-13. <https://doi.org/10.1056/nejmoa1911793>
3. Ginsberg RJ, Rubinstein LV. Randomized trial of lobectomy versus limited resection for T1 N0 non-small cell lung cancer. *Ann Thorac Surg*. 1995;60:615-23. [https://doi.org/10.1016/0003-4975\(95\)00537-U](https://doi.org/10.1016/0003-4975(95)00537-U)
4. Altorki N, Wang X, Kozono D, Watt C, Landrenau R, Wigle D, et al. Lobar or sublobar resection for peripheral stage IA non-small-cell lung cancer. *N Engl J Med*. 2023;388:489-98. <https://doi.org/10.1056/nejmoa2212083>
5. Saji H, Okada M, Tsuboi M, Nakajima R, Suzuki K, Aokage K, et al. Segmentectomy versus lobectomy in small-sized peripheral non-small-cell lung cancer (JCOG0802/WJOG4607L): a multicentre, open-label, phase 3, randomised, controlled, non-inferiority trial. *Lancet (London, England)*. 2022;399:1607-17. [https://doi.org/10.1016/S0140-6736\(21\)02333-3](https://doi.org/10.1016/S0140-6736(21)02333-3)
6. Downey RJ, Cheng D, Kernstine K, Stanbridge R, Shennib H, Wolf R, et al. Video-assisted thoracic surgery for lung cancer resection: a Consensus Statement of the International Society of Minimally Invasive Cardiothoracic Surgery (ISMICS) 2007. *Innovations*. 2007;2:293-302. <https://doi.org/10.1007/s11748-011-0898-6>
7. Cerfolio R, Louie BE, Farivar AS, Onaitis M, Park BJ. Consensus statement on definitions and nomenclature for robotic thoracic surgery. *J Thorac Cardiovasc Surg*. 2017;154:1065-9. <https://doi.org/10.1016/j.jtcvs.2017.02.081>
8. Bertolaccini L, Batirel H, Brunelli A, Gonzalez-Rivas D, Ismail M, Ucar AM, et al. Uniportal video-assisted thoracic surgery lobectomy: a consensus report from the Uniportal VATS Interest Group (UVIG) of the European Society of Thoracic Surgeons (ESTS). *Eur J Cardio-Thorac Surg*. 2019;56:224-9. <https://doi.org/10.1093/ejcts/ezz133>
9. Schuchert MJ, Abbas G, Awais O, Pennathur A, Nason KS, Wilson DO, et al. Anatomic segmentectomy for the solitary pulmonary nodule and early-stage lung cancer. *Ann Thorac Surg*. 2012;93:1780-7. <https://doi.org/10.1016/j.athoracsur.2011.11.074>
10. Sawabata N, Ohta M, Matsumura A, Nakagawa K, Hirano H, Maeda H, et al. Optimal distance of malignant negative margin in excision of nonsmall cell lung cancer: a multicenter prospective study. *Ann Thorac Surg*. 2004;77:415-20. [https://doi.org/10.1016/S0003-4975\(03\)01511-X](https://doi.org/10.1016/S0003-4975(03)01511-X)
11. Hagiwara M, Shimada Y, Kato Y, Nawa K, Makino Y, Furumoto H, et al. High-quality 3-dimensional image simulation for pulmonary lobectomy and segmentectomy: results of preoperative assessment of pulmonary vessels and short-term surgical outcomes in consecutive patients undergoing video-assisted thoracic surgery. *Eur J Cardio-Thorac Surg*. 2014;46:e120-6. <https://doi.org/10.1093/ejcts/ezu375>
12. Bakhuis W, Sadeghi AH, Moes I, Maat APWM, Siregar S, Bogers AJJC, et al. Essential surgical plan modifications after virtual reality planning in 50 consecutive segmentectomies. *Ann Thorac Surg*. 2023;115:1247-55. <https://doi.org/10.1016/j.athoracsur.2022.08.037>

13. Wu X, Li T, Zhang C, Wu G, Xiong R, Xu M, et al. Comparison of perioperative outcomes between precise and routine segmentectomy for patients with early-stage lung cancer presenting as ground-glass opacities: a propensity score-matched study. *Front Oncol*. 2021;11:1-8. <https://doi.org/10.3389/fonc.2021.661821>
14. Zhu XY, Yao FR, Xu C, Ding C, Chen J, Wang WY, et al. Utility of preoperative three-dimensional CT bronchography and angiography in uniportal video-assisted thoracoscopic anatomical lobectomy: a retrospective propensity score-matched analysis. *Ann Transl Med*. 2021;9:480. <https://doi.org/10.21037/atm-21-474>
15. Uneri A, Nithianathan S, Schafer S, Otake Y, Stayman JW, Kleinszig G, et al. Deformable registration of the inflated and deflated lung in cone-beam CT-guided thoracic surgery: initial investigation of a combined model- and image-driven approach. *Med Phys*. 2013;40:1-15. <https://doi.org/10.1118/1.4767757>
16. Daniel TM, Altes TA, Rehm PK, Williams MB, Jones DR, Stolin AV, et al. A novel technique for localization and excisional biopsy of small or ill-defined pulmonary lesions. *Ann Thorac Surg*. 2004;77:1756-62. <https://doi.org/10.1016/j.athoracsur.2003.10.099>
17. Grogan EL, Jones DR, Kozower BD, Simmons WD, Daniel TM. Identification of small lung nodules: technique of radiotracer-guided thoracoscopic biopsy. *Ann Thorac Surg*. 2008;85:S772-7. <https://doi.org/10.1016/j.athoracsur.2007.10.105>
18. Ambrogi MC, Melfi F, Zirafa C, Lucchi M, De Liperi A, Mariani G, et al. Radio-guided thoracoscopic surgery (RGTS) of small pulmonary nodules. *Surg Endosc*. 2012;26:914-9. <https://doi.org/10.1007/s00464-011-1967-8>
19. Watanabe K, Nomori H, Ohtsuka T, Kaji M, Naruke T, Suemasu K. Usefulness and complications of computed tomography-guided lipiodol marking for fluoroscopy-assisted thoracoscopic resection of small pulmonary nodules: experience with 174 nodules. *J Thorac Cardiovasc Surg*. 2006;132:320-4. <https://doi.org/10.1016/j.jtcvs.2006.04.012>
20. Sharma A, McDermott S, Mathisen DJ, Shepard JAO. Preoperative localization of lung nodules with fiducial markers: feasibility and technical considerations. *Ann Thorac Surg*. 2017;103:1114-20. <https://doi.org/10.1016/j.athoracsur.2016.09.112>
21. Park CH, Han K, Hur J, Lee SM, Lee JW, Hwang SH, et al. Comparative effectiveness and safety of preoperative lung localization for pulmonary nodules: a systematic review and meta-analysis. *Chest*. 2017;151:316-28. <https://doi.org/10.1016/j.chest.2016.09.017>
22. Vollmer I, Pérez-carpio A, Sánchez-lorente D, Boada M, Martínez D, Sánchez M, et al. Preoperative localization of lung nodules: a comparative analysis of hook-wire and radio-guided procedures. *J Thorac Dis*. 2022;14:4329-40. <https://doi.org/10.21037/jtd-22-552>
23. Okusanya OT, Holt D, Heitjan D, Deshpande C, Venegas O, Jiang J, et al. Intraoperative near-infrared imaging can identify pulmonary nodules. *Ann Thorac Surg*. 2014;98:1223-30. <https://doi.org/10.1016/j.athoracsur.2014.05.026>
24. Sarkaria IS, Martin LW, Rice DC, Blackmon SH, Slade HB, Singhal S, et al. Pa-folacianine for intraoperative molecular imaging of cancer in the lung: the ELUCIDATE trial. *J Thorac Cardiovasc Surg*. 2023;166:e468-78. <https://doi.org/10.1016/j.jtcvs.2023.02.025>
25. Predina JD, Newton A, Corbett C, Xia L, Sulyok LF, Shin M, et al. Localization of pulmonary ground-glass opacities with folate receptor-targeted intraoperative molecular imaging. *J Thorac Oncol*. 2018;13:1028-36. <https://doi.org/10.1016/j.jtho.2018.03.023>

**Key Words:** 3D planning, localization, segmentectomy, sublobar resection, small pulmonary nodules

**E-References**

- E1. Sato M, Kobayashi M, Kojima F, Tanaka F, Yanagiya M, Kosaka S, et al. Effect of virtual-assisted lung mapping in acquisition of surgical margins in sublobar lung resection. *J Thorac Cardiovasc Surg.* 2018;156:1691-701.e5.
- E2. Sato T, Yutaka Y, Nakamura T, Date H. First clinical application of radiofrequency identification (RFID) marking system—precise localization of a small lung nodule. *J Thorac Cardiovasc Surg Tech.* 2020;4:301-4.
- E3. Yutaka Y, Sato T, Tanaka S, Miyahara S, Yoshizawa A, Morita S, et al. Feasibility study of a novel wireless localization technique using radiofrequency identification markers for small and deeply located lung lesions. *J Thorac Cardiovasc Surg Tech.* 2022;12:185-95.
- E4. Marsden M, Weyers BW, Bec J, Sun T, Gandour-Edwards RF, Birkeland AC, et al. Intraoperative margin assessment in oral and oropharyngeal cancer using label-free fluorescence lifetime imaging and machine learning. *IEEE Trans Biomed Eng.* 2021;68:857-68.