

IDH1 Mutation in Brain Stem Glioma: Case Report and Review of Literature

Abstract

The role of isocitrate dehydrogenase 1 (IDH1) mutation in brain stem glioma is not clear. To the best of our knowledge, six cases of brain stem gliomas carrying IDH1/2 mutations are currently reported in the literature. One case of diffuse brain stem glioma with IDH1 mutation, which was followed for 2 years, is presented and compared with IDH1 negative tumors. A 22-year-old lady was referred with diplopia and left arm palsy. Neuroimaging detected a nonenhancing, nonhomogeneous diffuse infiltrating brain stem tumor extending from pons to medulla. Microsurgical debulking was performed. Microscopic evaluation of the tissue specimen and immunohistochemistry revealed an astrocytoma WHO Grade II with proliferation rate of 3% and glial fibrillary acidic protein (GFAP)-positive tumor cells. Interestingly, the tumor cells expressed mutated IDH1 R132H protein. The patient underwent adjuvant radiation and chemotherapy. The primary and 2 years' clinical/radiological characteristics did not indicate any significant difference from other cases without IDH1 mutation. The prognostic value of IDH1/2 mutation in brain stem glioma is unclear. Brain stem biopsies may allow determination of a tissue-based tumor diagnosis for further investigations.

Keywords: Brain stem, glioma, IDH1 protein, mutation, treatment

Introduction

Brain stem gliomas are uncommon in adults and constitute about 2% of gliomas.^[1] According to the WHO classification of brain tumors, brain stem gliomas predominately consist of astrocytic and oligodendroglial tumors and are assigned to all Grades (I-IV).^[2] Biopsies from brain stem gliomas are technically problematic and often the neuropathologist receives only very small pieces of tissue. Molecular markers are often helpful tools in such a diagnostically-challenging setting and could also provide diagnostic information. Mutations in the genes isocitrate dehydrogenase 1 (IDH1) and IDH2 are observed in 60–90% of supratentorial diffusely infiltrating gliomas,^[3,4] but only in a frequency of 7% in infratentorial diffusely infiltrating gliomas.^[5]

To the best of our knowledge, six cases of brain stem gliomas carrying IDH1/2 mutations are currently documented in the literature.^[5,6] Here, an unusual case of infratentorial glioma carrying an IDH1 mutation is presented and compared to other cases of our database without IDH1

mutation. Besides, review of the literature and discussion about potential consequences are performed.

Case Report

A 22-year-old woman was referred with diplopia since 6 months ago, which aggravated at looking to the right side. Furthermore, she suffered from a weakness of left arm for 3 months, which recovered partly under steroid treatment.

The magnetic resonance assessment detected a high-intensity diffuse enlargement on T2-weighted and fluid attenuated inversion recovery (FLAIR) images extending from pons to medulla with the greatest diameter of 3.7 cm and cross-sectional diameter of 2.8 cm × 2.3 cm [Figure 1]. In FLAIR images, a nonhomogeneous signal with central area of signal loss, probably due to hemosiderin was detected. In contrast enhancing T1-weighted images, no enhancement was found. The findings were in favor of a low grade glioma.

Operative findings and postoperative course

Informed consent was signed by the patient. The patient was intubated

**Seyed Amirhossein Javadi^{1,2},
Christian Hartmann³,
Gerhard Franz Walter²,
Roozbeh Banan³,
Amir Samii^{2,4}**

¹Brain and Spinal Injury Research Center, Neuroscience Institute, Tehran University of Medical Sciences, Tehran, Iran, ²Department of Neurosurgery, International Neuroscience Institute, ³Department of Neuropathology, Hannover Medical School (MHH), Institute of Pathology, Hannover, ⁴Leibniz Institute for Neurobiology, Magdeburg, Germany

Address for correspondence:
Dr. Seyed Amirhossein Javadi,
P. O. Box: 61-14185, BASIR,
Imam Khomeini Hospital,
Keshavarz Bulv., Tehran, Iran.
E-mail: javadi1978@yahoo.com

Access this article online

Website: www.asianjns.org

DOI: 10.4103/1793-5482.228540

Quick Response Code:



How to cite this article: Javadi SA, Hartmann C, Walter GF, Banan R, Samii A. IDH1 mutation in brain stem glioma: Case report and review of literature. *Asian J Neurosurg* 2018;13:414-7.

This is an open access journal, and articles are distributed under the terms of the Creative Commons Attribution-NonCommercial-ShareAlike 4.0 License, which allows others to remix, tweak, and build upon the work non-commercially, as long as appropriate credit is given and the new creations are licensed under the identical terms.

For reprints contact: reprints@medknow.com

under permanent somatosensory-evoked potential monitoring, brainstem auditory-evoked potential, sixth nerve monitoring with motor evoked potential (MEP), and median nerve electromyography monitoring in the semi-sitting position. Lateral suboccipital craniotomy was performed to allow a retrosigmoid approach. After direct electrical stimulation, biopsies were obtained superior to the level of the lower cranial nerves. The first piece was sent for rapid frozen section and the remaining was kept for final histologic assessment. Due to an increased latency and decreased amplitude at MEP of the left arm, further debulking was terminated. The patient developed postoperatively a worsening of her weakness in the left arm, which recovered to the preoperative status within 2 weeks. She was referred for receiving chemotherapy combined with radiotherapy.

Pathological findings

Microscopic evaluation of the tissue specimen showed an astrocytic tumor of moderate cellularity and mild pleomorphism generating a fibrillary matrix. The nuclei were unsuspecting, and no mitotic figure was found. The vessels in the tumor revealed a delicate appearance and no necrosis was present. By immunohistochemistry, a proliferation rate of 3% and GFAP-positive tumor cells were observed [Figure 2]. Therefore, astrocytoma WHO Grade II was diagnosed. Interestingly, the tumor cells expressed mutated IDH1 R132H protein. The IDH1 R132H mutation was further confirmed by pyro sequencing [Figure 3].

Follow-up course

At 2 years follow-up, the patient was stable without any changes at clinical presentation; the size of tumor had decreased significantly. On reviewing our data base, the result of IDH1 mutation was provided for 15 cases of brain stem glioma (out of 64 cases) including astrocytoma Grade II and pilocytic astrocytoma Grade I. Therefore, the rate of IDH1 mutation of brain stem glioma was 6.7% at our case series. The mean age was 26 ± 12 (range 4–45). The mean follow-up in our case series was 4.2 ± 2 years (mean \pm standard deviation), ranging from 2 to 11 years. The mean recurrence free period was 3 years.

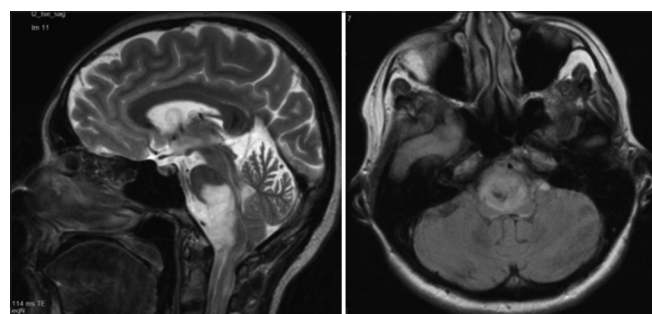


Figure 1: Axial and sagittal T2-weighted magnetic resonance images of brain stem glioma

Discussion

The presented case is an unusual infratentorial diffuse astrocytoma with an IDH1 mutation. Low rates of IDH1 mutation are reported at brain stem glioma. To the best of our knowledge, there are six cases of brainstem gliomas with IDH1 mutation currently reported in the literature.^[5,6] Ellezam *et al.* reported IDH1 mutation in 7% (3 out of 44 cases) of infratentorial gliomas.^[5] Songtao *et al.* reported five cases of IDH1 mutation at diencephalon or brain stem glioma; however, they did not separate pure brain stem gliomas without supratentorial extension.^[7] Ida *et al.* demonstrated one case of IDH1 mutation among 19 cerebellar gliomas.^[6] Instead, Khuong-Quang *et al.* found no IDH1 mutations in 42 cases of pediatric pontine diffuse gliomas.^[8] IDH1 was also negative in 25 cases of pediatric brainstem glioma analyzed by Oka *et al.*^[9] Reyes-Botero *et al.* detected three cases of IDH1 mutation among 17 samples, which included R132G, R132C, and R132H.^[10] The authors concluded that most of the mutations of brain stem glioma were non R132H.

The presented case did not indicate statistically significant difference from other patients in literature without IDH1 mutation, regarding primary and follow-up clinical/radiological presentation. However, long-term follow-up may detect prognostic value of IDH1 mutation in brain

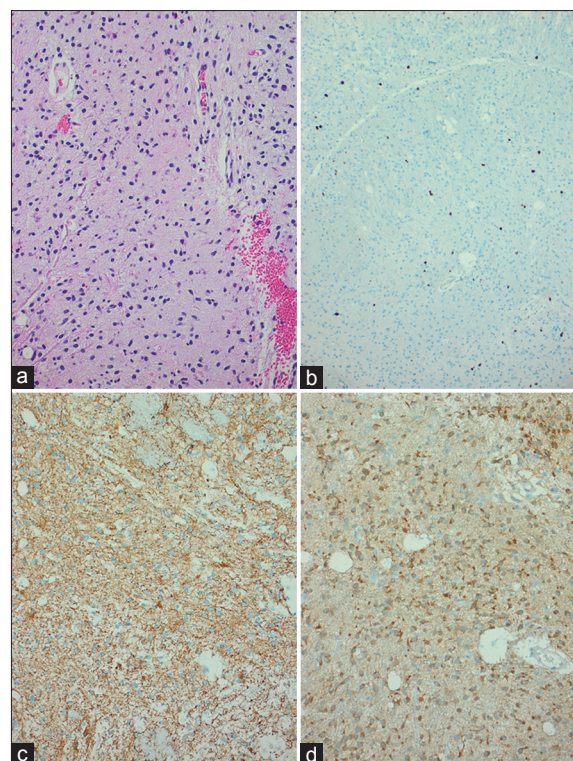


Figure 2: Histology showed in H and E staining a typical diffusely infiltrating astrocytoma WHO Grade II of moderate cellularity and mild pleomorphism (a). The Ki67/Mib1 proliferation rate was 3% (b), the tumor cells expressed glial fibrillary acidic protein (c), and mutated IDH1 R132H protein (d)

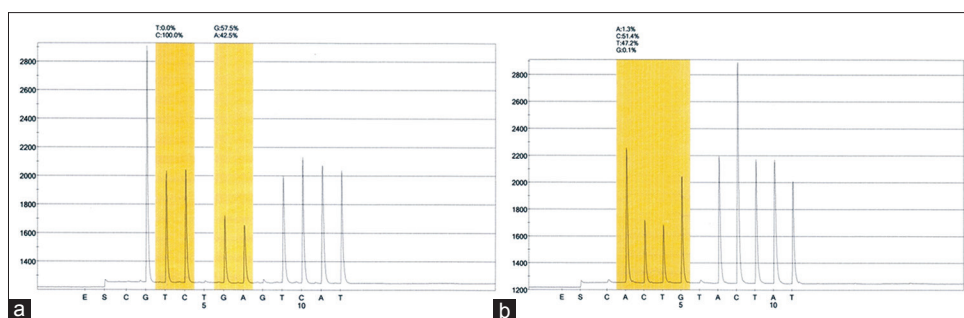


Figure 3: Pyrogram (a: Forward, b: Reverse) showing a c. 395G>A mutation (CGT → CAT) leading to amino acid change from arginine to histidine in codon 132

stem gliomas. The current knowledge regarding the prognostic value of IDH1/2 mutations in brain stem gliomas is unclear. Reyes-Botero *et al.* concluded that patients with IDH1 mutations had longer survival time.^[10] H3F3A mutations in malignant brain stem gliomas were found to better predict the biological behavior than the current WHO criteria.^[11,12] It remains an issue of speculation if patients with IDH1/2-mutated brain stem gliomas show a better survival than those patients with H3F3A-mutated brain stem tumors.

A certain number of diffusely infiltrating brain stem gliomas are genetically related to their supratentorial counterparts. Therefore, determining the IDH1/2 status in diffusely infiltrating brain stem gliomas should be recommended. In case of uncertain differentiation between a diffusely infiltrating astrocytoma WHO Grade II and a pilocytic astrocytoma WHO Grade I, a positive IDH1/2 status may help to assign an exact diagnosis, especially in case of negativity for H3F3A mutation and BRAF: KIAA1549 fusion/duplication. Even more, the availability of a specific antibody allows an inexpensive test for mutated IDH1 R132H protein.^[13]

Currently, no clear concept regarding the cell of origin of IDH1/2-mutated tumor cells is established. The vast difference in frequencies of IDH1/2 mutations between supra- and infra-tentorial gliomas may argue toward a very small number of those nonneoplastic precursor cells in the brain stem in comparison to the telencephalon. An alternative concept would be to speculate that IDH1/2-mutated brain stem glioma cells were initially induced supratentorially and migrated later in the infratentorial areas of the brain. At least in the case presented here, we found no clinical and neuroradiological evidence for a second supratentorial lesion.

Conclusion

The presented case is a rare infratentorial diffuse astrocytoma with an IDH1 mutation. However, the prognostic value of IDH1/2 mutation in brain stem glioma is unclear. Brain stem biopsies may allow determination of a tissue-based tumor diagnosis for further investigations.

Acknowledgment

We would like to appreciate our technician's support ("MTA") Britta Hasemeier, regarding IDH1/2 sequencing and arranging the sequencing figure.

Financial support and sponsorship

Nil.

Conflicts of interest

There are no conflicts of interest.

References

- Guillamo JS, Monjour A, Taillandier L, Devaux B, Varlet P, Haie-Meder C, *et al.* Brainstem gliomas in adults: Prognostic factors and classification. *Brain* 2001;124(Pt 12):2528-39.
- Louis DN, Ohgaki H, Wiestler OD, Cavenee WK, Burger PC, Jouvet A, *et al.* The 2007 WHO classification of tumours of the central nervous system. *Acta Neuropathol* 2007;114:97-109.
- Hartmann C, Meyer J, Balss J, Capper D, Mueller W, Christians A, *et al.* Type and frequency of IDH1 and IDH2 mutations are related to astrocytic and oligodendroglial differentiation and age: A study of 1,010 diffuse gliomas. *Acta Neuropathol* 2009;118:469-74.
- von Deimling A, Korshunov A, Hartmann C. The next generation of glioma biomarkers: MGMT methylation, BRAF fusions and IDH1 mutations. *Brain Pathol* 2011;21:74-87.
- Ellezam B, Theeler BJ, Walbert T, Mammoser AG, Horbinski C, Kleinschmidt-DeMasters BK, *et al.* Low rate of R132H IDH1 mutation in infratentorial and spinal cord grade II and III diffuse gliomas. *Acta Neuropathol* 2012;124:449-51.
- Ida CM, Lambert SR, Rodriguez FJ, Voss JS, Mc Cann BE, Seys AR, *et al.* BRAF alterations are frequent in cerebellar low-grade astrocytomas with diffuse growth pattern. *J Neuropathol Exp Neurol* 2012;71:631-9.
- SongTao Q, Lei Y, Si G, YanQing D, HuiXia H, XueLin Z, *et al.* IDH mutations predict longer survival and response to temozolomide in secondary glioblastoma. *Cancer Sci* 2012;103:269-73.
- Khuong-Quang DA, Buczkwicz P, Rakopoulos P, Liu XY, Fontebasso AM, Bouffet E, *et al.* K27M mutation in histone H3.3 defines clinically and biologically distinct subgroups of pediatric diffuse intrinsic pontine gliomas. *Acta Neuropathol* 2012;124:439-47.
- Oka H, Utsuki S, Tanizaki Y, Hagiwara H, Miyajima Y, Sato K, *et al.* Clinicopathological features of human brainstem gliomas. *Brain Tumor Pathol* 2013;30:1-7.
- Reyes-Botero G, Giry M, Mokhtari K, Labussière M, Idbah A, Delattre JY, *et al.* Molecular analysis of diffuse intrinsic

- brainstem gliomas in adults. *J Neurooncol* 2014;116:405-11.
11. Schwartzenuber J, Korshunov A, Liu XY, Jones DT, Pfaff E, Jacob K, *et al.* Driver mutations in histone H3.3 and chromatin remodelling genes in paediatric glioblastoma. *Nature* 2012;482:226-31.
 12. Wu G, Broniscer A, McEachron TA, Lu C, Paugh BS, Becksfort J, *et al.* Somatic histone H3 alterations in pediatric diffuse intrinsic pontine gliomas and non-brainstem glioblastomas. *Nat Genet* 2012;44:251-3.
 13. Capper D, Zentgraf H, Balsl J, Hartmann C, von Deimling A. Monoclonal antibody specific for IDH1 R132H mutation. *Acta Neuropathol* 2009;118:599-601.