

Case Report

# Cerebrospinal Fluid Concentration of the RET Inhibitor Pralsetinib: A Case Report

Loek A.W. de Jong<sup>a</sup> Rolf W. Sparidans<sup>b</sup> Michel M. van den Heuvel<sup>c</sup>

<sup>a</sup>Department of Pharmacy, Radboud University Medical Center Research Institute for Medical Innovation, Radboud University Medical Center, Nijmegen, The Netherlands; <sup>b</sup>Division of Pharmacology, Department of Pharmaceutical Sciences, Faculty of Science, Utrecht University, Utrecht, The Netherlands; <sup>c</sup>Department of Pulmonary Diseases, Radboud University Medical Center Research Institute for Medical Innovation, Radboud University Medical Center, Nijmegen, The Netherlands

## Keywords

Pralsetinib · Cerebrospinal fluid · Lung cancer · Brain metastasis · Case report

## Abstract

**Introduction:** Pralsetinib is used to treat metastatic RET fusion-positive non-small cell lung cancer. Preclinical studies of pralsetinib have shown blood-brain barrier (BBB) penetration and intracranial activity. The intracranial efficacy of pralsetinib in patients with brain metastasis is considered to be greater compared to older multikinase tyrosine kinase inhibitors. However, CSF concentrations of pralsetinib in patients are not well described in the literature. **Case Presentation:** We report a case of a patient with RET fusion-positive NSCLC treated with pralsetinib. Despite extracranial clinical and radiological remission, the patient developed progressive brain metastasis during treatment with pralsetinib. We measured the pralsetinib concentration in plasma and in CSF to determine the CSF-to-unbound plasma ratio. The measured pralsetinib concentrations in plasma and CSF were 1,951 ng/mL (~57 unbound) and 14 ng/mL, respectively, reflecting a CSF-to-unbound plasma concentration ratio of 0.25. Our findings were compared with data from the literature. **Conclusion:** We showed that pralsetinib penetrates the CSF well and is expected to be an effective treatment for brain metastasis of RET fusion-positive NSCLC. Lack of intracranial efficacy is more likely to be caused by intrinsic or acquired tumor resistance instead of suboptimal exposure of pralsetinib in the brain.

© 2023 The Author(s).  
Published by S. Karger AG, Basel

## Introduction

Over the past decade, many drugs have been developed for non-small cell lung cancer (NSCLC) that specifically target oncogenic drivers including EGFR, ALK, ROS1, KRAS, BRAF, MET, HER2, NTRK, and RET [1]. Rearranged during transfection (RET) fusion-positive lung

Correspondence to:  
Michel M. van den Heuvel, [Michel.vandenheuvel@radboudumc.nl](mailto:Michel.vandenheuvel@radboudumc.nl)

adenocarcinoma occurs in 1–2% of lung cancer patients [2]. Besides lung adenocarcinoma, RET fusions are observed most commonly in patients with thyroid papillary carcinoma and salivary gland carcinoma and with a lower prevalence in other solid tumors [3, 4]. Based on the phase 1/2 ARROW trial, the RET inhibitor pralsetinib (Graveto<sup>®</sup>) has been granted approval by the FDA and EMA to treat RET-fusion positive non-small cell lung cancer (NSCLC) [5]. Brain metastases are highly prevalent in patients with advanced NSCLC with an increased incidence in patients with targetable mutations [6, 7]. In patients with RET-rearranged lung cancer, 25% of patients have CNS involvement at diagnosis, with a lifetime prevalence of 46% [8]. Brain metastasis can cause a variety of symptoms, including headache, cognitive dysfunction, focal neurological deficits, strokes, and seizures. In the past local radiotherapy of brain metastasis was the cornerstone of treatment. According to the guidelines from American Society of Clinical Oncology, systemic treatment with targeted therapies may be favored over local therapies in patients with asymptomatic brain metastasis from oncogene-driven NSCLC [9]. For patients with RET-positive advanced NSCLC and brain metastasis, pralsetinib is considered an effective therapy based on a small group of patients that were treated with this drug. In order to yield intracranial activity, pralsetinib must cross the blood-brain barrier (BBB). Data regarding brain exposure of pralsetinib in patients are lacking. We herein report a case of a patient with advanced RET-positive NSCLC who experienced intracranial progression despite treatment with pralsetinib. Pralsetinib concentrations in both plasma and cerebrospinal fluid (CSF) were measured to assess the penetration in CSF. Finally, we compared our results with earlier findings of pralsetinib exposure in CSF and with sparse data regarding another RET inhibitor, selpercatinib (Retevmo<sup>®</sup>). The CARE Checklist has been completed by the authors and attached as online supplementary material (for all online suppl. material, see <https://doi.org/10.1159/000535172>).

### Case Report

A 55-year-old woman presented with NSCLC adenocarcinoma with malignant pleural effusion. Next-generation sequencing of circulating tumor DNA revealed an EGFR exon 19 deletion and EGFR-targeted treatment was initiated. The patient was treated with gefitinib for a period of 7 months until progression (maximal response: stable disease). At that point, disease had advanced with multiple bone metastases and diagnostic suspicion of lymphangitic carcinomatosis. The patient suffered from severe invalidating dyspnea and increasing pain. The patient started treatment with pembrolizumab, pemetrexed and carboplatin, which resulted in partial remission. One year after the start of immunochemotherapy, the patient suffered from minor headaches. Magnetic resonance imaging (MRI) of the brain revealed a solitary brain metastasis and a second enhancing lesion, located in the left frontal lobe. Both lesions were treated with stereotactic radiosurgery under continuation of immunochemotherapy. Twenty-two months after the start of immunochemotherapy, new metastases were detected in the left adrenal gland together with two para-uterine lesions and chemoimmunotherapy was discontinued. Needle biopsy of the adnex confirmed a metastasis of NSCLC. Molecular screening revealed a KIF5B-RET gene rearrangement. The patient was treated with pralsetinib as part of a preapproval access program. Ten days after the initiation of treatment with pralsetinib (400 mg QD), the patient developed facial edema, muscle weakness, thrombocytopenia, neutropenia, and epistaxis requiring temporary cessation of the drug. These adverse events disappeared after a drug holiday of 10 days whereafter pralsetinib was restarted at a reduced dose of 300 mg QD. One week after restart, the patient underwent a neurological examination since she suffered from numbness in left arm and right leg and left-sided trochlear nerve palsy resulting in diplopia, which was suspicious for

leptomeningeal metastases. A brain MRI, 7 weeks after initial start of pralsetinib, showed favorable radiological response with a partial remission according to RECIST. Four months later, pralsetinib was again temporarily discontinued, now because of a polyneuropathy grade 2. Although the neuropathy was asymmetric, suggesting that a relationship with pralsetinib was less likely, the dose was reduced to 200 mg QD.

A follow-up showed ongoing extracerebral remission, but the tumor markers CEA and CA-125 increased over time and the patient suffered from increasing neurological complaints, including progressive muscle weakness in the left arm, C7-8, L4-5, and S1 radiculopathy and left-sided peripheral facial nerve palsy. Brain MRI revealed leptomeningeal metastases and the patient was treated with whole-brain radiotherapy and the pralsetinib dose was increased to 300 mg QD. Since the patient showed active leptomeningeal progression in the presence of full extracranial disease control, a lumbar puncture and venipuncture were performed to determine pralsetinib concentrations in CSF and plasma. Due to low quantity and quality of tumor DNA in the CSF sample, molecular analysis to detect potential acquired resistance mechanisms was deemed futile. Pralsetinib trough (predose) concentrations in plasma and CSF under steady-state conditions with a dose of 300 mg QD were 1,951 ng/mL and 14 ng/mL, respectively. Our findings were compared with data from the literature (Table 1) and exposure in CSF was deemed sufficient. Unfortunately, the patient died 11 months after initiation of treatment with pralsetinib. A timeline summarizing the main events of this case report is shown in Figure 1.

## Discussion

In this case report, we present a patient with RET fusion-positive lung adenocarcinoma who showed active leptomeningeal progression in the presence of full extracranial disease control during treatment with pralsetinib. Pralsetinib concentrations were determined in both CSF and plasma using a validated LC-MS/MS assay [11]. The CSF-to-unbound plasma concentration ratio was 0.25. Pralsetinib target concentrations in plasma and CSF are unknown. According to the manufacturer, a plasma concentration of 1,514 ng/mL is required to achieve brain IC<sub>90</sub> of pralsetinib for RET inhibition [12, 13].

The plasma concentration (1,951 ng/mL) at the dose of 300 mg QD in our patient exceeded the population geometric mean [range] steady-state trough plasma concentration at 400 mg QD of 1,150 [179–4,280] ng/mL, indicating adequate systemic exposure [12, 13]. Plasma protein binding of pralsetinib is 97.1% and is concentration independent. The trough plasma concentration of 1,951 ng/mL in our patient corresponds with an unbound pralsetinib concentration of 57 ng/mL. The degree of protein binding varies between plasma and CSF [14]. CSF is often regarded as a body fluid with a very low amount of drug-binding proteins and therefore the vast majority of drug in CSF is considered to be present as unbound drug. If this is the case for pralsetinib, the unbound CSF-to-unbound plasma concentration ratio in our patient is ~0.25. The half-maximal inhibitory concentration (IC<sub>50</sub>) values for wild-type RET, kinase-activated RET mutations and fusions are reported to be <0.27 ng/mL. Unbound pralsetinib concentrations in both plasma and CSF outweigh this concentration. However, CSF drug concentration does not necessarily represent the unbound drug concentration at the target site in tumor tissue [15].

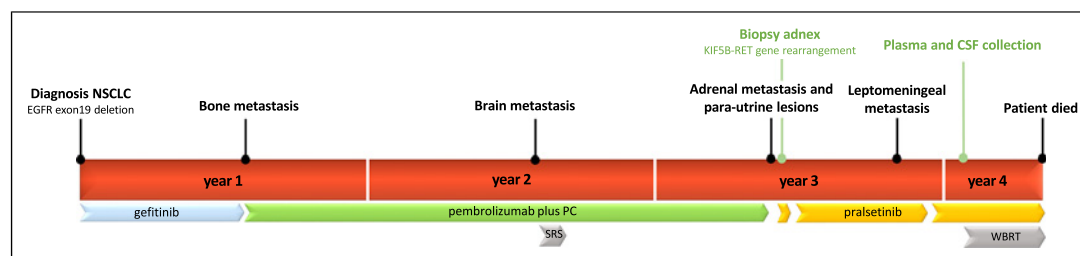
The CSF/plasma unbound ratio of 0.25 is comparable to other TKIs that are considered brain-penetrable drugs and show high intracranial response rates, like alectinib, lorlatinib, and osimertinib with CSF/plasma unbound ratios of 0.86, 0.75, and 0.21, respectively [10, 16, 17]. However, TKIs with low efficacy in brain metastasis, as is the case for gefitinib, erlotinib and crizotinib, show lower CSF/plasma ratios of <0.01 [18–20]. Brain capillary endothelial cells of the BBB express large amounts of P-glycoprotein and breast cancer resistance protein. These efflux transporters limit CNS exposure of drugs that are substrates for these transporters,

**Table 1.** Pralsetinib concentrations in CSF and plasma in humans

	Zhao et al. [10]	EMA public assessment report/FDA multidiscipline review [8, 9]	Our case
Dose, mg QD	400	400	300
Plasma, ng/mL			
C <sub>trough</sub>	48,723 <sup>1</sup>	1,150	1,951
C <sub>max</sub>		2,830	
Unbound plasma, <sup>2</sup> ng/mL			
C <sub>trough</sub>	1,413 <sup>1</sup>	33	57
C <sub>max</sub>		82	
CSF, ng/mL	376	N/A	14
CSF/plasma ratio	0.008	N/A	0.007
CSF/unbound plasma ratio	0.266	N/A	0.246

<sup>1</sup>Sampling time not specified.

<sup>2</sup>Calculated using a plasma protein binding of 97.1% [8].



**Fig. 1.** Horizontal timeline representing main events from initial diagnosis. Pembrolizumab plus PC was administered every 21 days for up to 4 cycles in combination with carboplatin and then followed by maintenance therapy of pembrolizumab and pemetrexed every 21 days. CSF, cerebrospinal fluid; PC, pemetrexed and carboplatin; SRS, stereotactic radiosurgery; WBRT, whole-brain radiotherapy.

causing reduced therapeutic efficacy against brain metastasis. In animal research it has been demonstrated that pralsetinib is a substrate of breast cancer resistance protein and especially P-glycoprotein, which can potentially limit penetration in the brain. It has been demonstrated that inhibition of these transporters with elacridar causes a 20-fold increase in brain penetration [21]. Comparable data has been published for the RET-inhibitor selpercatinib [22].

Both pralsetinib and selpercatinib are considered highly active in the treatment of brain metastasis based on reported intracranial objective response rates of 70% (95% CI: 35–93) and 82% (95% CI: 60–95), respectively. These objective response rates are based on 10 patients treated with pralsetinib and 22 patients treated with selpercatinib who had measurable intracranial metastases at baseline [23, 24]. Clinical data regarding selpercatinib concentrations in CSF are lacking. Preclinical data in mice demonstrate a brain-to-plasma ratio ranging from 0.03 to 0.07 [25]. For pralsetinib, the unbound brain-to-plasma ratio was ~0.14 in rats [12, 13]. Although a direct comparison of these ratios between different studies and species might be unreliable, the ratios seem more or less comparable. With an equal plasma protein binding in humans of 97.1% for pralsetinib and 96.1% for selpercatinib, it is

speculated that the CSF-to-(unbound) plasma ratio would be comparable for both drugs [13, 25]. However, future efforts to study CSF pharmacokinetics of both drugs would be of importance to provide more insight in CNS penetration.

In a previously published case report, a patient demonstrated clinical and radiological response with subsequent use of selpercatinib after CNS progression under pralsetinib [26]. In our case, the patient was not treated with subsequent selpercatinib. Zhao et al. [10] reported pralsetinib concentrations in plasma and CSF of 48,723 ng/mL (91  $\mu\text{M}$ ) and 376 ng/mL (704 nM), respectively. These concentrations are ~25 fold higher compared to our findings and registration data [12, 13]. Although the sampling timepoint was not specified by Zhao et al. [10], this huge difference cannot be explained by the higher dose of 400 mg QD and a possible difference between trough and peak sampling. However, the CSF-to-unbound plasma concentration ratio was comparable in both patients (0.27 vs. 0.25).

Treatment of metastatic brain lesions in NSCLC remains challenging. Due to CNS exclusion criteria in the majority of NSCLC clinical trials, the actual CNS activity of new agents is often not fully established upon marketing approval [27]. Nevertheless, much effort is being undertaken to develop new agents with optimal CNS activity. Intentional structure-delivery efforts are being made in drug development, designing new agents with low affinity for drug transporters, and enhanced intrinsic BBB permeability. In addition to brain drug delivery, another key issue in the treatment of brain metastases is the difference in tumor micro-environment and gene expression profiles between brain and peripheral lesions [28]. This further complicates the treatment of brain metastases. However, with increasing knowledge of optimal brain delivery and the oncogenic footprints of brain metastases, it can be expected that the number of agents with CNS activity will rapidly increase in the upcoming years, hopefully resulting in better treatment options for cancer patients with CNS involvement.

## Conclusion

Our findings demonstrate that pralsetinib crosses the BBB resulting in sufficient penetration in CSF to effectively treat brain metastasis of RET fusion-positive NSCLC. The lack of intracranial efficacy in our patient is therefore more likely to be caused by intrinsic or acquired tumor resistance instead of suboptimal exposure of pralsetinib in the brain.

## Statement of Ethics

The treatment of the patient was part of standard clinical care and did not require ethical approval in accordance with national guidelines. Written informed consent for publication was obtained from the patient's next of kin for the publication of the details of their medical case and any accompanying images.

## Conflict of Interest Statement

The authors have no conflicts of interest to declare.

## Funding Sources

This study was not supported by any sponsor or funder.

### Author Contributions

L.A.W.J. drafted the manuscript. R.W.S. performed the quantification of pralsetinib in plasma and CSF and reviewed the manuscript. M.M.H. was the patient's doctor in charge of all clinical information and reviewed the manuscript. All the authors approved the final version.

### Data Availability Statement

All data generated or analyzed during this study are included in this article and its online supplementary material. Further inquiries can be directed to the corresponding author.

### References

- 1 Lamberti G, Andriani E, Sisi M, Rizzo A, Parisi C, Di Federico A, et al. Beyond EGFR, ALK and ROS1: current evidence and future perspectives on newly targetable oncogenic drivers in lung adenocarcinoma. *Crit Rev Oncol Hematol*. 2020;156:103119.
- 2 Lipson D, Capelletti M, Yelensky R, Otto G, Parker A, Jarosz M, et al. Identification of new ALK and RET gene fusions from colorectal and lung cancer biopsies. *Nat Med*. 2012;18(3):382–4.
- 3 Li AY, McCusker MG, Russo A, Scilla KA, Gittens A, Arensmeyer K, et al. RET fusions in solid tumors. *Cancer Treat Rev*. 2019;81:101911.
- 4 Parimi V, Tolba K, Danziger N, Kuang Z, Sun D, Lin DJ, et al. Genomic landscape of 891 RET fusions detected across diverse solid tumor types. *NPJ Precis Oncol*. 2023;7(1):10.
- 5 Gainor JF, Curigliano G, Kim DW, Lee DH, Besse B, Baik CS, et al. Pralsetinib for RET fusion-positive non-small-cell lung cancer (ARROW): a multi-cohort, open-label, phase 1/2 study. *Lancet Oncol*. 2021;22(7):959–69.
- 6 Shin DY, Na II, Kim CH, Park S, Baik H, Yang SH. EGFR mutation and brain metastasis in pulmonary adenocarcinomas. *J Thorac Oncol*. 2014;9(2):195–9.
- 7 Zhang I, Zaorsky NG, Palmer JD, Mehra R, Lu B. Targeting brain metastases in ALK-rearranged non-small-cell lung cancer. *Lancet Oncol*. 2015;16(13):e510–21.
- 8 Drlon A, Lin JJ, Filleron T, Ni A, Milia J, Bergagnini I, et al. Frequency of brain metastases and multikinase inhibitor outcomes in patients with RET-rearranged lung cancers. *J Thorac Oncol*. 2018;13(10):1595–601.
- 9 Vogelbaum MA, Brown PD, Messersmith H, Brastianos PK, Burri S, Cahill D, et al. Treatment for brain metastases: ASCO-SNO-ASTRO guideline. *J Clin Oncol*. 2022;40(5):492–516.
- 10 Zhao Z, Su C, Xiu W, Wang W, Zeng S, Huang M, et al. Response to pralsetinib observed in meningeal-metastatic EGFR-mutant NSCLC with acquired RET fusion: a brief report. *JTO Clin Res Rep*. 2022;3(6):100343.
- 11 Şentürk R, Wang Y, Schinkel AH, Beijnen JH, Sparidans RW. Quantitative bioanalytical assay for the selective RET inhibitors selpercatinib and pralsetinib in mouse plasma and tissue homogenates using liquid chromatography-tandem mass spectrometry. *J Chromatogr B Analyt Technol Biomed Life Sci*. 2020;1147:122131.
- 12 Food and Drug Administration. Center for drug evaluation and research. NDA multi-disciplinary review and evaluation {213721} pralsetinib. 2019.
- 13 European medicines agency committee for medical products for human use. Gavreto: EPAR – Public Assessment Report; 2021.
- 14 Srinivas N, Maffuid K, Kashuba ADM. Clinical pharmacokinetics and pharmacodynamics of drugs in the central nervous system. *Clin Pharmacokinet*. 2018;57(9):1059–74.
- 15 Shen DD, Artru AA, Adkison KK. Principles and applicability of CSF sampling for the assessment of CNS drug delivery and pharmacodynamics. *Adv Drug Deliv Rev*. 2004;56(12):1825–57.
- 16 Gadgeel SM, Gandhi L, Riely GJ, Chiappori AA, West HL, Azada MC, et al. Safety and activity of alectinib against systemic disease and brain metastases in patients with crizotinib-resistant ALK-rearranged non-small-cell lung cancer (AF-002JG): results from the dose-finding portion of a phase 1/2 study. *Lancet Oncol*. 2014;15(10):1119–28.
- 17 Shaw AT, Felip E, Bauer TM, Besse B, Navarro A, Postel-Vinay S, et al. Lorlatinib in non-small-cell lung cancer with ALK or ROS1 rearrangement: an international, multicentre, open-label, single-arm first-in-man phase 1 trial. *Lancet Oncol*. 2017;18(12):1590–9.
- 18 Jackman DM, Holmes AJ, Lindeman N, Wen PY, Kesari S, Borrás AM, et al. Response and resistance in a non-small-cell lung cancer patient with an epidermal growth factor receptor mutation and leptomeningeal metastases treated with high-dose gefitinib. *J Clin Oncol*. 2006;24(27):4517–20.
- 19 Clarke JL, Pao W, Wu N, Miller VA, Lassman AB. High dose weekly erlotinib achieves therapeutic concentrations in CSF and is effective in leptomeningeal metastases from epidermal growth factor receptor mutant lung cancer. *J Neuro Oncol*. 2010;99(2):283–6.

- 20 Costa DB, Kobayashi S, Pandya SS, Yeo WL, Shen Z, Tan W, et al. CSF concentration of the anaplastic lymphoma kinase inhibitor crizotinib. *J Clin Oncol*. 2011;29(15):e443–5.
- 21 Wang Y, Sparidans RW, Potters S, Lebre MC, Beijnen JH, Schinkel AH. ABCB1 and ABCG2, but not CYP3A4 limit oral availability and brain accumulation of the RET inhibitor pralsetinib. *Pharmacol Res*. 2021;172:105850.
- 22 Wang Y, Sparidans RW, Potters S, Şentürk R, Lebre MC, Beijnen JH, et al. P-glycoprotein (ABCB1/MDR1) and BCRP (ABCG2) limit brain accumulation and cytochrome P450-3A (CYP3A) restricts oral exposure of the RET inhibitor selpercatinib (RETEVMO). *Pharmaceuticals*. 2021;14(11):1087.
- 23 Subbiah V, Gainor JF, Oxnard GR, Tan DSW, Owen DH, Cho BC, et al. Intracranial efficacy of selpercatinib in RET fusion-positive non-small cell lung cancers on the LIBRETTO-001 trial. *Clin Cancer Res*. 2021;27(15):4160–7.
- 24 Griesinger F, Curigliano G, Thomas M, Subbiah V, Baik CS, Tan DSW, et al. Safety and efficacy of pralsetinib in RET fusion-positive non-small-cell lung cancer including as first-line therapy: update from the ARROW trial. *Ann Oncol*. 2022;33(11):1168–78.
- 25 European medicines agency committee for medical products for human use. Retsevmo: EPAR – Public Assessment Report; 2020.
- 26 Tsui DCC, Kavanagh BD, Honce JM, Rossi C, Patil T, Camidge DR. Central nervous system response to selpercatinib in patient with RET-rearranged non-small cell lung cancer after developing leptomeningeal disease on pralsetinib. *Clin Lung Cancer*. 2022;23(1):e5–8.
- 27 McCoach CE, Berge EM, Lu X, Barón AE, Camidge DR. A brief report of the status of central nervous system metastasis enrollment criteria for advanced non-small cell lung cancer clinical trials: a review of the ClinicalTrials.gov trial registry. *J Thorac Oncol*. 2016;11(3):407–13.
- 28 Brastianos PK, Carter SL, Santagata S, Cahill DP, Taylor-Weiner A, Jones RT, et al. Genomic characterization of brain metastases reveals branched evolution and potential therapeutic targets. *Cancer Discov*. 2015;5(11):1164–77.