

Rare bone marrow biopsy complication: a challenging case of sacroiliitis and *Staphylococcus aureus* sepsis

Alessandro Morotti,
Maria Consiglio Barozzino, Angelo
Guerrasio

Department of Clinical and Biological
Sciences, University of Turin, Turin, Italy

Abstract

Bone marrow biopsy is a mandatory procedure to diagnose several hematological disorders. This invasive analysis is generally safe and the procedure-related risks are rare and include bleeding at the site of puncture and, very occasionally, local infections. Here, we describe a case of sacroiliitis that occurred as a consequence of bone marrow biopsy.

Case Report

A 78-year-old woman was admitted to our Internal Medicine Unit due to fever and pain at the sacroiliac region. In the past, patient was suffering rheumatoid arthritis and autoimmune thyroiditis and was occasionally treated with steroids. A couple of weeks before the admission to the hospital, the patient received a bone marrow biopsy on the right iliac crest to investigate a mild grade of anemia. A modest autoimmune hemolytic anemia and B12 vitamin deficiency were observed. The patient was indeed treated with steroids with adequate improvement of hemoglobin count and discharged from the Hematology Unit. Few days after the biopsy, the patient presented with pain and fever. Blood cultures were positive for *Staphylococcus aureus*. A nuclear magnetic resonance (NMR) of the lumbar spine and sacroiliac region was also performed. As shown in Figure 1, NMR revealed enthesitis of the right sacroiliac joint with inflammation of the gluteus maximus and medius muscles, iliacus muscle and the adductor muscles. Notably, these regions were enhanced upon paramagnetic NMR contrast agent injection. Furthermore, a fluid collection in the anterior region of the sacroiliac joint (around 29 mm of diameter) was also observed. All together, these observations were diagnostic for sacroiliitis.^{1,2} To our knowledge, no reports have described sacroiliitis as a bone marrow biopsy related complication.³⁻⁸ Similarly, no cases of sacroiliitis were ever reported as a consequence of bone marrow biopsies in our

institution in the last 20 years (average number of bone marrow biopsies/year is 350). The patient received antibiotic therapy with piperacillin/tazobactam plus vancomicine and subsequently oxacillin as a single agent, with sudden clinical improvement and normalization of the C-reactive protein values.⁹ Therapy was extended for 6 weeks and no relapse occurred.

Discussion

This case report describes sacroiliitis as a very rare complication after bone marrow biopsy. Bone marrow biopsy is a safe procedure that is eventually associated with local bleeding and, very rarely, infection. For instance, in a huge survey of 54,890 biopsies in the UK, only 26 adverse events were reported.⁷ Three of them were local infections. In this case report, bone marrow biopsy was performed by highly trained clinicians following all standard procedures to achieve a sterile field. Furthermore, the overall side effects of the Unit, where the biopsy was performed, are rare and mostly local, as described elsewhere.^{5,7} It should be question whether pre-existing steroid treatment for autoimmune diseases and/or rheumatoid arthritis should have increased

Correspondence: Alessandro Morotti, Department of Clinical and Biological Sciences, University of Turin, Regione Gonzole 10, 10043 Orbassano (TO), Italy.
Tel.: +39.011.9026806 - Fax: +39.011.9026739.
E-mail: alessandro.morotti@unito.it

Key words: Bone marrow biopsy; sacroiliitis; infection.

Acknowledgements: we thank all the member of the Internal Medicine and Hematology Division of San Luigi Hospital, Orbassano, Italy.

Contributions: AM and MCB managed the patient; AM wrote the manuscript; MCB and AG reviewed the manuscript; AG reviewed patient's management.

Conflict of interest: the authors have no conflict of interest.

Received for publication: 9 November 2015.

Revision received: 21 December 2015.

Accepted for publication: 15 January 2016.

This work is licensed under a Creative Commons Attribution NonCommercial 4.0 License (CC BY-NC 4.0).

©Copyright A. Morotti et al., 2016
Licensee PAGEPress, Italy
Clinics and Practice 2016; 6:823
doi:10.4081/cp.2016.823

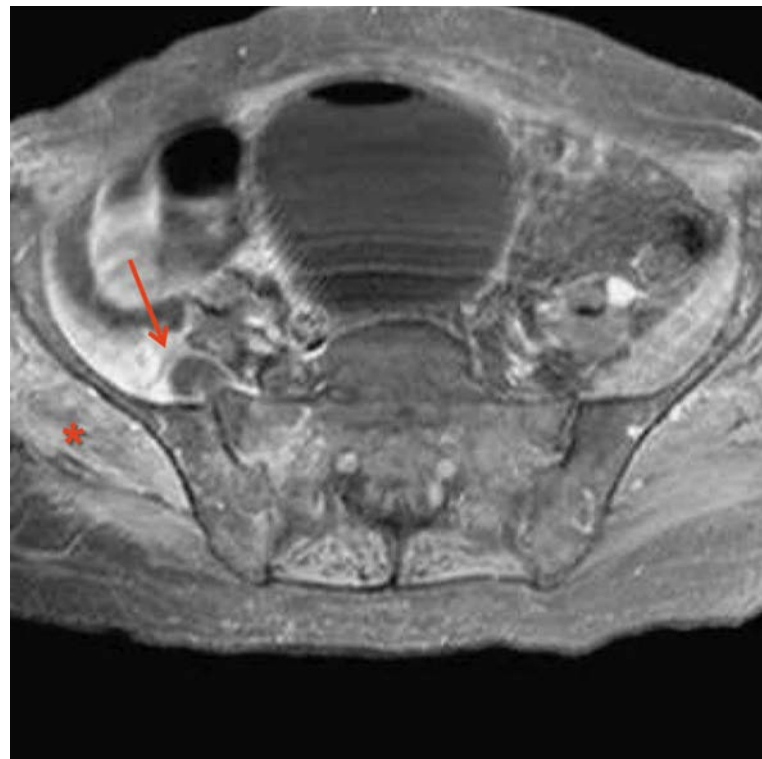


Figure 1. Nuclear magnetic resonance image showing sacroiliitis, inflammation of the gluteus maximus and medius muscles, iliacus muscle and a fluid collection in the anterior region of the right sacroiliac joint. Red arrow indicates the fluid collection in the anterior region of the sacroiliac joint; red asterisk indicates inflammation of the muscles.

the risk of infections. Moreover, it could be argued that sacroiliitis could present itself as a manifestation of chronic immune-mediated rheumatic disease or, more in general, spondyloarthritis. However, the occurrence of sacroiliitis very shortly after bone marrow biopsy and, more importantly, at the same site of the procedure, together with the development of sepsis, highly pose a causative connection between bone marrow procedure and infection of the sacro-iliac region. To further exclude the contribution of steroids treatment and preexisting bone status, it should also be noted that bone marrow biopsy is often performed in heavily immunosuppressed patients (*i.e.*, after bone marrow transplantation) and/or in highly compromised lytic bone lesions of multiple myeloma. Both situations are not known to increase the risk of developing sacroiliitis. Even the true pathogenesis of this complication is un-addressable, NMR should be considered the standard diagnostic procedure to investigate sacroiliac region. Furthermore, prolonged antibiotic therapy must be pursued to achieve complete eradication of the infection.

Conclusions

The occurrence of pain at the bone marrow biopsy site and fever should always be assessed by NMR of the sacroiliac region to rule out the diagnosis of sacroiliitis and/or local abscess. In the presence of abscess, drainage should always be considered as a mandatory procedure. Blood cultures should always be performed to identify causative bacteria. A prolonged antibiotic therapy is necessary to achieve complete eradication of the bone infection.

References

1. Stürzenbecher A, Braun J, Paris S, et al. MR imaging of septic sacroiliitis. *Skeletal Radiol* 2000;29:439-46.
2. van Gaalen FA, Bakker PAC, de Hooge M, et al. Assessment of sacroiliitis by radiographs and MRI: where are we now? *Curr Opin Rheumatol* 2014;26:384-8.
3. Parapia LA. Trepanning or trephines: a history of bone marrow biopsy. *Br J Haematol* 2007;139:14-9.
4. Fend F, Tzankov A, Bink K, et al. Modern techniques for the diagnostic evaluation of the trephine bone marrow biopsy: methodological aspects and applications. *Prog Histochem Cytochem* 2008;42:203-52.
5. Bain BJ. Morbidity associated with bone marrow aspiration and trephine biopsy - a review of UK data for 2004. *Haematologica* 2006;91:1293-4.
6. Bain BJ. Bone marrow trephine biopsy. *J Clin Pathol* 2001;54:737-42.
7. Bain BJ. Bone marrow biopsy morbidity and mortality. *Br J Haematol* 2003;121:949-51.
8. Roth JS, Newman EC. Gluteal compartment syndrome and sciatica after bone marrow biopsy: a case report and review of the literature. *Am Surg* 2002;68:791-4.
9. Sieper J. Developments in therapies for spondyloarthritis. *Nat Rev Rheumatol* 2012;8:280-7.