

# Primary Ewing's Sarcoma of Zygoma

Kapil Soni, Poonam Elhence<sup>1</sup>, Amber Kesarwani, Nikhil Rajan

Departments of Otorhinolaryngology and <sup>1</sup>Pathology, All India Institute of Medical Sciences, Jodhpur, Rajasthan, India

## Abstract

Ewing's sarcoma is a small round cell tumor, malignant in nature, typically affecting long bones and pelvis. It is most commonly presented in the pediatric age group. The occurrence of Ewing's sarcoma in the head-and-neck region is rare and is reported to be around 2%–3%, of which chances of having primary lesion are rarer. Among facial bones, mandible is the most commonly affected bone. Primary involvement of zygoma is extremely rare. Here, we present a case of primary Ewing's sarcoma of the left zygoma in a 17-year-old girl. The diagnosis was made after surgical resection, histopathology with immunohistochemistry confirmation, and cytogenetic study.

**Keywords:** Ewing's sarcoma, maxillofacial, primitive neuroectodermal tumor, zygoma

## INTRODUCTION

Ewing's sarcoma is a small round cell tumor with significant malignant potential.<sup>[1]</sup> Ewing's sarcoma is derived from the cells of neural crest and has reciprocal translocation between chromosomes 11 and 22, t(11; 22).<sup>[2]</sup> Ewing's sarcoma along with Askin tumor and primitive neuroectodermal tumor (PNET) is a part of the Ewing's sarcoma family of tumors (ESFT).<sup>[2]</sup> It is presented in the pediatric age group with erosion of bones. The occurrence in the head-and-neck region is approximately 2%–3%.<sup>[3]</sup> Primary tumor of the zygoma is extremely rare, and only six cases are reported to date.<sup>[4]</sup>

## CASE REPORT

A 17-year-old girl presented to us with a complaint of painless swelling over the left zygomatic region for three months which was progressive in nature. No history of facial weakness, fever, diplopia, nasal, or ear complaints was present.

On examination, there was a swelling measuring 3 cm × 2 cm with a smooth surface and poorly defined margin over the left zygoma, approximately 2 cm lateral to canthus, firm in consistency, tender, and mobile [Figure 1]. The overlying skin was uninvolved. No scar, sinus, or facial weakness was present. Extraocular movements were normal. No other significant clinical finding was present. There was no regional lymphatic

spread. Routine blood investigations and chest skiagram were normal.

Sonography of the swelling was done which revealed a heteroechoic lesion of size 1.5 cm × 1.3 cm along the outer margin of zygomatic bone and a heteroechoic lesion of size 2 cm × 2.8 cm along the inner margin of zygomatic bone.

Contrast-enhanced computed tomography (CT) scan [Figure 2a] of the face was done which revealed enhancing soft tissue mass lesion of size 3.1 cm × 2.4 cm × 4.1 cm in relation to the left zygomatic bone in both medial and lateral aspect with infiltration of subcutaneous tissue by the lateral aspect of tumor. Mass was abutting temporalis muscle without any infiltration. Mass was infiltrating and involving left masseter muscle. Subtle permeation and osteopenia of the left zygomatic bone were seen suggestive of its involvement.

Contrast-enhanced magnetic resonance imaging (MRI) [Figure 2b] showed enhancing soft tissue mass lesion of size 3.1 cm × 2.4 cm × 4.1 cm in relation to the left zygomatic bone both medial and lateral aspect of bone. Lateral aspect

**Address for correspondence:** Dr. Amber Kesarwani,

Department of Otorhinolaryngology, All India Institute of Medical Sciences,  
Room No. 303, Resident Hostel, Jodhpur, Rajasthan, India.  
E-mail: dramber.kesar@gmail.com

### Access this article online

#### Quick Response Code:



**Website:**  
www.amsjournal.com

**DOI:**  
10.4103/ams.ams\_267\_18

This is an open access journal, and articles are distributed under the terms of the Creative Commons Attribution-NonCommercial-ShareAlike 4.0 License, which allows others to remix, tweak, and build upon the work non-commercially, as long as appropriate credit is given and the new creations are licensed under the identical terms.

**For reprints contact:** reprints@medknow.com

**How to cite this article:** Soni K, Elhence P, Kesarwani A, Rajan N. Primary Ewing's sarcoma of zygoma. Ann Maxillofac Surg 2019;9:419-22.

of tissue is infiltrating into subcutaneous region. Mass was infiltrating and involving left masseter muscle in the lateral retromaxillary space. Marrow signal intensity of the zygomatic bone is altered, showing involvement of the bone. There was no significant lymphadenopathy present. Both CT and MRI were highly suggestive of Ewing's sarcoma of the left zygomatic bone.

Fine-needle aspiration cytology of the swelling was done, and it was suggestive of small round cell tumor.

In view of Ewing's sarcoma and its malignant nature, metastatic workup was advised. CT of thorax and abdomen was normal. Bone scan was done in which there was increased osteoblastic activity with increased vascularity seen involving left zygomatic arch. Distal skeletal involvement was not evident.

After workup, the surgery was planned. An approximately 7-cm curvilinear incision was made extending from the lower end of the left tragus toward forehead 1 cm above the hairline. Intraoperatively, zygoma was found to be thinned out and eroded which was removed along with tumor. Furthermore, tumor was found to be infiltrating masseter muscle, so cuff of muscle was also resected with tumor. The size of tumor was around 5 cm × 2.5 cm [Figure 3a and b]. There was no facial nerve weakness or any other complications postoperatively. Medical oncologist opinion was sought postsurgery, and the patient was started on chemotherapy (ifosfamide and etoposide). After seven months of postoperative period, no recurrence was seen. The patient is advised for regular follow-up on monthly basis or on notice of any signs of recurrence.

Histopathology was suggestive of poorly differentiated small round cell tumor suggestive of ESFT [Figure 4]. Other differentials were neuroendocrine carcinoma, lymphoma, and poorly differentiated synovial sarcoma.

Immunohistochemistry (IHC) was done for definite diagnosis; CD 99 marker which is seen in ≥90% of cases of Ewing's sarcoma was found to be positive [Figure 5a]. Tumor cells were also intensely reactive for FLI-1, pan CK, and Vimentin, while TLE1, Desmin, leukocyte common antigen, synaptophysin, chromogranin A, WT1, and p63 were negative. Cytogenetic study by fluorescence *in situ* hybridization was also done, and EWSR1 (22q12) translocation was found in 95% of tumor cells [Figure 5b]. On the basis of clinical features, radiological findings, histopathology report, and cytogenetic study, diagnosis of Ewing's sarcoma of the zygoma was made.

Figure 6a and b represents the postoperative photograph of the patient showing cosmetic incision made to the patient and well-healed scar mark, respectively.

## DISCUSSION

Since its first description by Ewing, the origin of Ewing's sarcoma is under debate. In recent studies, it is assumed that

it is neuroectodermal in origin and derived from cells of the neural crest.<sup>[1,2]</sup> It usually involves long bones and pelvis and occasionally ribs also. Only 2%–3% of osseous lesion occurs in the head-and-neck region.<sup>[3]</sup> Mandible is the most common site in the head-and-neck region.<sup>[3]</sup> The most common age of presentation ranges between 5 and 25 years.<sup>[5]</sup> Our patient also presented with the age corresponding to these demographic data. There is slight male preponderance noted in this lesion. The characteristic radiological finding associated with Ewing's sarcoma is “onion skin” appearance which is usually seen in long bones.<sup>[1]</sup> This finding rarely appears in lesions involving bones of head and neck. Other radiological findings which can be seen are expansion and erosion of bone. CT scan is essential to know the extension of disease, while MRI can be a supplement to know marrow or soft tissue involvement.<sup>[1]</sup>

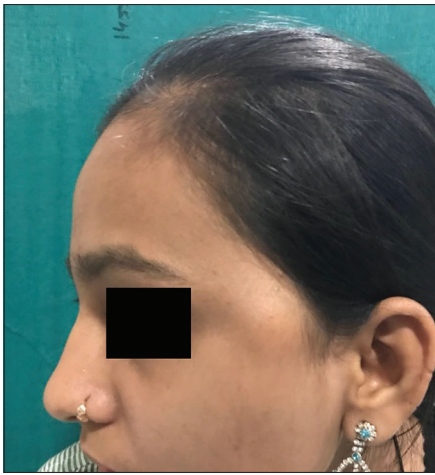Histologically, Ewing's sarcoma is a highly cellular lesion composed of narrow sheets of small, densely packed, and round cells with scanty stroma. Cells show uniformly appearing, small, round-to-oval, hyperchromatic nuclei, and scanty cytoplasm; thus, it is designated as a “small round blue cell tumor.”<sup>[1]</sup> IHC staining with MIC-2 (CD-99) is required for confirmation of diagnosis. The MIC2 gene is expressed in ≥90% of Ewing's sarcoma.<sup>[1]</sup> It is also positive for vimentin, while it is negative for desmin and myogenin. Other differentials for small round cell tumor are lymphoma, rhabdomyosarcoma, and neuroblastoma. These are morphologically similar on histology as all of these are small round blue cell tumor and differentiated on IHC only. The closest differential of Ewing's sarcoma is PNET as they belong to the same family. Histologically, there are differences between these two tumors. PNET tends to represent well-differentiated end of tumor spectrum, while Ewing's sarcoma represents the poorly differentiated end of the spectrum.<sup>[6]</sup> Cytogenetic study for EWSR1-FLI1 fusion may be required for confirmation. This fusion may be seen in ≥90% of cases.<sup>[2]</sup>

The treatment is based on presentation, i.e., localized or metastatic or recurrent and site. Surgical excision is the modality of choice followed by postoperative chemotherapy. Radiotherapy should be reserved for unresectable or residual disease. Prognosis of this tumor also depends on site and presence of metastasis. The most common site for metastasis is lungs. Other sites can be bones or lymph nodes. Survival rates in head-and-neck Ewing's sarcoma are much better than that of other sites.

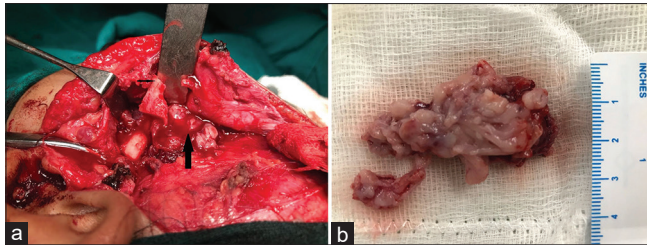
## CONCLUSION

Head-and-neck region swelling is quite common in day-to-day practice, but there are some lesions which lead to diagnostic uncertainties. Ewing's sarcoma is a common ailment, but its occurrence over zygoma is extremely rare and should be kept as differentials in head-and-neck region swelling, particularly in the young age group with destruction or erosion of bones. Surgical excision followed by histopathological and IHC study is essential for obtaining a diagnosis. It is essential to

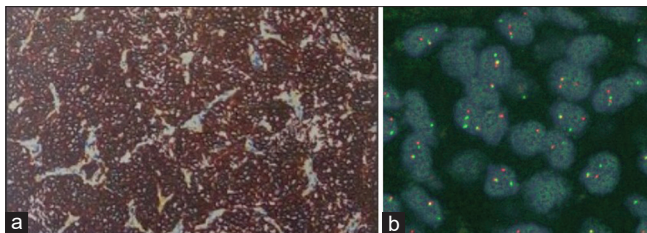




**Figure 1:** A 3 cm × 2 cm swelling over the left zygoma, approximately 2 cm lateral



**Figure 3:** (a) Intraoperative tumor specimen (thick black arrow) along with excised piece of involved zygomatic bone (thin black arrow). (b) showing excised tumor specimen of size around 5 cm × 2.5 cm with cuff of masseter muscle and excised piece of involved zygomatic bone



**Figure 5:** (a) Immunohistochemistry with CD-99 is positive in tumor cells. (b) EWSR1 (22q12) translocation was found in 95% of tumor cells

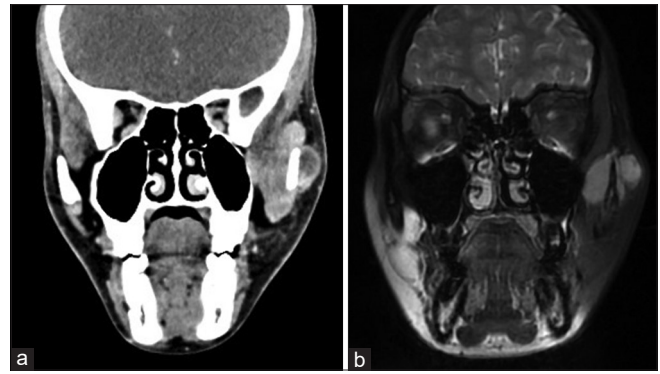
keep these patients in regular follow-up as a part of successful management.

### Declaration of patient consent

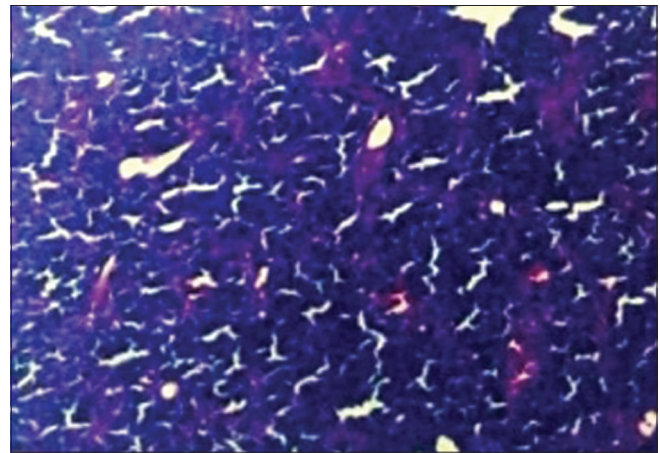
The authors certify that they have obtained all appropriate patient consent forms. In the form the patient(s) has/have given his/her/their consent for his/her/their images and other clinical information to be reported in the journal. The patients understand that their names and initials will not be published and due efforts will be made to conceal their identity, but anonymity cannot be guaranteed.

### Acknowledgment

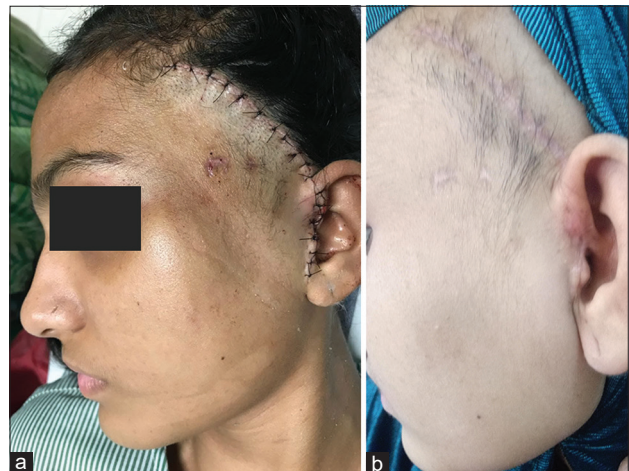We wish to thank and acknowledge Dr. Sudeep Khara (Asst. Prof.) and Dr. Anand Bardia (Senior Resident), Department



**Figure 2:** (a and b) Contrast-enhanced computed tomography scan and contrast-enhanced magnetic resonance imaging, respectively, showing enhancing soft tissue mass of size 3.1 cm × 2.4 cm × 4.1 cm in relation to left zygomatic bone in both medial and lateral aspect with infiltration of subcutaneous tissue



**Figure 4:** Histopathology showing fibromuscular tissue with an infiltrating neoplasm composed of small round blue tumor cells arranged in sheets



**Figure 6:** (a) Postoperative (day 3) picture of the patient showing cosmetic scar. (b) Postoperative (day 20) picture of the patient showing well-healed scar mark

of Pathology, All India Institute of Medical Sciences, Jodhpur, for their cooperation and providing images for the article.

## Financial support and sponsorship

Nil.

## Conflicts of interest

There are no conflicts of interest.

## REFERENCES

1. Infante-Cossio P, Gutierrez-Perez JL, Garcia-Perla A, Noguer-Mediavilla M, Gavilan-Carrasco F. Primary Ewing's sarcoma of the maxilla and zygoma: Report of a case. *J Oral Maxillofac Surg* 2005;63:1539-42.
2. Toretsky JA. Ewing Sarcoma and Primitive Neuroectodermal Tumours. Available from: <http://www.emedicine.com/ped/topic2589.htm>. [Last updated on 2008 Jun 17].
3. Cotterill SJ, Ahrens S, Paulussen M, Jürgens HF, Voûte PA, Gadner H, *et al.* Prognostic factors in Ewing's tumor of bone: Analysis of 975 patients from the European intergroup cooperative Ewing's sarcoma study group. *J Clin Oncol* 2000;18:3108-14.
4. El-Khayat B, Eley KA, Shah KA, Watt-Smith SR. Ewings sarcoma of the zygoma reconstructed with a gold prosthesis: A rare tumor and unique reconstruction. *Oral Surg Oral Med Oral Pathol Oral Radiol Endod* 2010;109:e5-10.
5. Neville BW, Damm DD, Allen CM, Bouquot JE. *Oral and Maxillofacial Pathology*. 3<sup>rd</sup> ed. St. Louis, Mo: Saunders, Elsevier; 2009. p. 660-9.
6. Votta TJ, Fantuzzo JJ, Boyd BC. Peripheral primitive neuroectodermal tumor associated with the anterior mandible: A case report and review of the literature. *Oral Surg Oral Med Oral Pathol Oral Radiol Endod* 2005;100:592-7.