

Successful Treatment of Allergic Bronchopulmonary Aspergillosis With Isavuconazole: Case Report and Review of the Literature

Samantha E. Jacobs,¹ Deborah Saez-Lacy,² Walter Wynkoop,³ and Thomas J. Walsh¹

¹Division of Infectious Diseases, Weill Cornell Medicine, New York, New York; ²Brielle Obstetrics and Gynecology, Manasquan and ³Ocean Pulmonary Associates, Brick, New Jersey

Isavuconazole is a new triazole that is approved for primary therapy of invasive aspergillosis. We provide the first report of a patient with allergic bronchopulmonary aspergillosis (ABPA) who was successfully treated with isavuconazole with marked improvement and minimal adverse effects. We further review the literature on antifungal management of ABPA.

Keywords. allergic bronchopulmonary aspergillosis; antifungal therapy; isavuconazole.

Allergic bronchopulmonary aspergillosis (ABPA) results from an abnormal exaggerated local and systemic immune response to conidia and hyphae colonizing the sinopulmonary tract. Allergic bronchopulmonary aspergillosis complicates asthma and cystic fibrosis in 1%–2% and 5%–15% of patients, respectively [1]. In asthmatic patients, ABPA presents as poorly controlled asthma with wheezing, cough, sputum production, low-grade fever, weight loss, and malaise.

Allergic bronchopulmonary aspergillosis management includes corticosteroids to control the host immune response and antifungal agents to decrease the burden of organism. Itraconazole is currently the first-line agent for symptomatic ABPA patients based on randomized, controlled clinical trials [2, 3]. Voriconazole is an alternative based on observational data [4]. However, both itraconazole and voriconazole are associated with significant adverse effects.

Isavuconazole is a broad-spectrum antifungal triazole with potent activity against *Aspergillus* species. It is recommended

as an alternative primary therapy for invasive aspergillosis syndromes in the 2016 Infectious Diseases Society of America Guidelines [5]. We provide the first report of a patient with ABPA who was successfully treated with isavuconazole after having persistent symptoms and significant side effects with itraconazole and voriconazole.

METHODS

We first sought to understand the impact of systemic antifungal management on ABPA. We therefore systematically searched the PubMed database for English-language literature of antifungal therapy for ABPA in patients with underlying asthma. The following search terms were used: “itraconazole,” “voriconazole,” “posaconazole,” “isavuconazole,” “nebulized amphotericin B,” and “allergic bronchopulmonary aspergillosis.” We then report in detail our index case.

CASE REPORT

A 56-year-old female physician with asthma was seen in consultation in May 2015 for ABPA management. Her symptoms began in September 2009 when she developed a flu-like illness with fever, malaise, nonproductive cough, and decreased exercise tolerance. She regularly attended aerobic exercise classes, but she found that any activity that increased her respiratory rate lead to coughing “fits” that precluded further exercise.

In the spring of 2010, the cough and wheezing worsened, and she had new sputum production. A serum immunoglobulin (Ig)E level was 813 IU/mL, precipitating serum IgG antibodies to *Aspergillus fumigatus* were detected, *Aspergillus* skin testing was positive, and a sputum culture grew *A. fumigatus*. A high-resolution computed tomography (CT) scan of the chest demonstrated mild hyperinflation of the lungs bilaterally and minimal inflammatory changes in the left mid-lung field. Pulmonary function tests (PFTs) revealed obstructive airways disease (forced expiratory volume [FEV]₁ 2.08L, forced vital capacity [FVC] 3.02L, FEV₁/FVC 69%) that did not improve after bronchodilator therapy. The patient was diagnosed with ABPA. In October 2010, she was prescribed prednisone 0.5 mg/kg orally daily for 1 week followed by a taper over 3 months. Her respiratory symptoms improved such that she could participate in aerobic gym classes. The serum IgE decreased to 326 IU/mL. However, she was unable to discontinue corticosteroids entirely. Sputum cultures continued to grow *Aspergillus* species through July 2011. Pulmonary function tests showed stable mild obstruction.

Over the next year, her chronic cough and sputum production continued, and she lost 15 pounds unintentionally. She resumed prednisone at approximately 1 mg/kg in October 2011.

Received 30 December 2016; editorial decision 27 February 2017; accepted 13 April 2017.

Correspondence: T. J. Walsh, MD, Director, Transplantation-Oncology Infectious Diseases Program Chief, Infectious Diseases Translational Research Laboratory Professor of Medicine, Pediatrics, and Microbiology and Immunology, Division of Infectious Diseases, Weill Cornell Medicine, 1300 York Ave., A-421, New York, NY 10065 (thw2003@med.cornell.edu).

Open Forum Infectious Diseases®

© The Author 2017. Published by Oxford University Press on behalf of Infectious Diseases Society of America. This is an Open Access article distributed under the terms of the Creative Commons Attribution-NonCommercial-NoDerivs licence (<http://creativecommons.org/licenses/by-nc-nd/4.0/>), which permits non-commercial reproduction and distribution of the work, in any medium, provided the original work is not altered or transformed in any way, and that the work is properly cited. For commercial re-use, please contact journals.permissions@oup.com
 DOI: 10.1093/ofid/ofx040

In December 2011, she started itraconazole; however, she developed hives, and the drug was discontinued. She was then treated with voriconazole 200 mg orally twice daily, and the cough and sputum production improved significantly. Prednisone was then tapered and discontinued. The serum IgE decreased from 663 IU/mL to 384 IU/mL. In March 2012, she stopped voriconazole due to an asymptomatic rise in the serum alanine aminotransferase (ALT) to 247 IU/L.

In fall 2012 and winter 2013, she had recurrent bronchitis and pneumonia due to *Pseudomonas aeruginosa*. A high-resolution CT scan of the chest showed cylindrical bronchiectasis in both lower lobes and bilateral, multiple, tiny lung nodules. Within the left lower lobe posterior basal segment, a 5.1 × 4.5 × 2.0 cm opacity was seen. Thick, white sputum was noted throughout the airways during bronchoscopy. Culture of bronchoalveolar lavage fluid grew *Aspergillus* species, *Cladosporium* species, and *Stenotrophomonas maltophilia*. Antifungal susceptibility data were not available. The patient resumed voriconazole in September 2014 and again had marked clinical improvement. The IgE levels decreased from 1583 IU/mL to 787 IU/mL. Pulmonary function tests showed moderate obstruction (FEV₁ 1.61L, FEV₁/FVC 68%). However, she experienced photopsia, and serum ALT increased to more than twice the upper limit of normal. Voriconazole was discontinued in March 2015. Given that the patient was not able to tolerate voriconazole and was concerned about the adverse effects of corticosteroids, she presented to New York-Presbyterian Hospital/Weill Cornell Medicine for further management.

Additional past medical history included corticosteroid-induced diabetes (diet-controlled), osteopenia, and seasonal allergies. Medications included *N*-acetylcysteine nebulizers, albuterol sulfate inhaler, azelastine-fluticasone nasal spray, beclomethasone inhaler, budesonide-formoterol inhaler, fexofenadine, and montelukast.

On physical examination, vital signs were unremarkable. The oxygen saturation was 96% while breathing ambient air. The body mass index was 17.4 kg/m². Mid-inspiratory and expiratory wheezing was auscultated throughout the lung fields. The remainder of the exam was normal. Serum IgE level was 676 IU/mL. Erythrocyte sedimentation rate was 20 mm/hour (normal 0–40 mm/hour) and C-reactive protein was 0.5 mg/L (normal 0.0–4.9 mg/L).

Given the patient's poor tolerance of corticosteroids (osteopenia and hyperglycemia), voriconazole (photopsia and elevated aspartate aminotransferase [AST] and ALT), and itraconazole (hypersensitivity reaction), she was prescribed oral isavuconazole 200 mg every 8 hours × 2 days, followed by 200 mg once daily. She was instructed to take isavuconazole in 4-month "pulses" so as to alleviate symptoms during ABPA exacerbations while reducing the risk of emergence of resistance. Over several weeks, she noted marked improvement in her sputum production and wheezing, and she was even able to backpack 16 miles in July 2015. She discontinued beclomethasone and continued on budesonide-formoterol alone. The serum IgE level remained elevated at 732 IU/mL. In August 2015, after 10 weeks of therapy, she stopped isavuconazole, noting that her

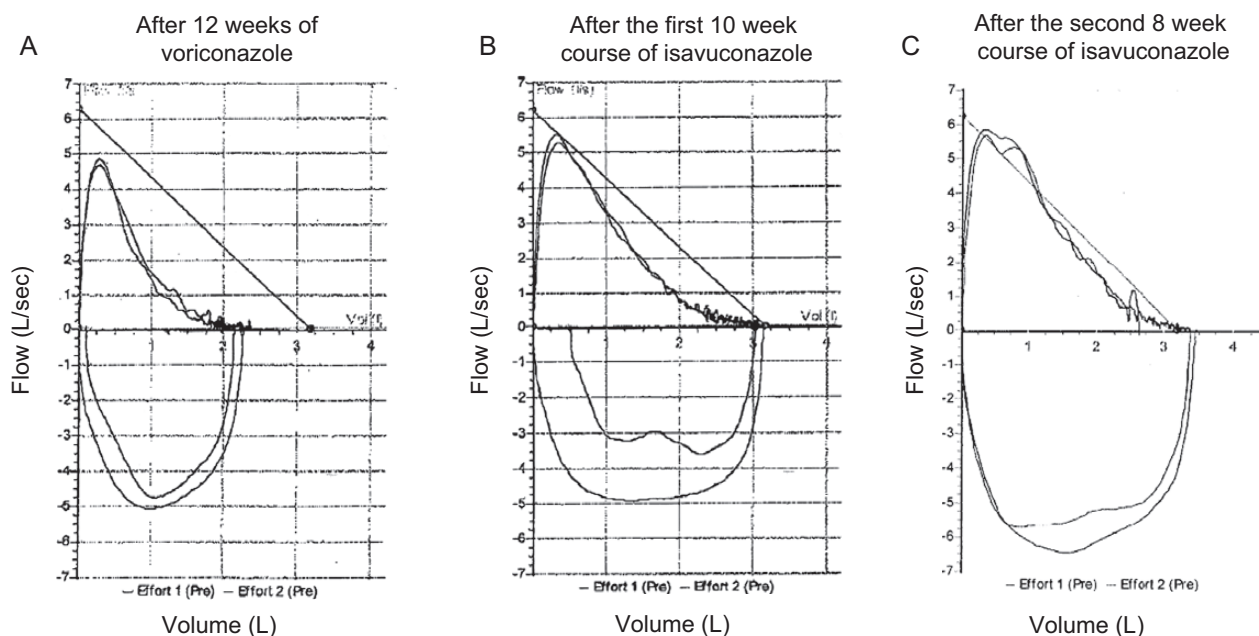


Figure 1. Flow volume curves. (A) Moderate airway obstruction while on voriconazole in December 2014 (forced expiratory volume [FEV]₁ 1.61L, forced vital capacity [FVC] 2.38L, FEV₁/FVC 68%). (B) Mild airway obstruction after first course of isavuconazole in July 2015 (FEV₁ 2.12L, FVC 3.09L, FEV₁/FVC 69%). (C) Normal flow volume curve after the second course of isavuconazole in July 2016 (FEV₁ 2.43L, FVC 3.39L, FEV₁/FVC 72%).

Table 1. Selective Literature Review of Antifungal Therapies for the Treatment of ABPA in Patients With Asthma^a

Reference	Study Design	Number of Patients	Compound(s)	Outcome Variables	Results	Adverse Effects
Jacobs et al	Current case report	N = 1	Isavuconazole 200 mg 3x/day x 2 days, then 200 mg daily	Symptoms PFTs Biomarkers Corticosteroids	<ul style="list-style-type: none"> o Symptomatic improvement o Improvement in FEV₁ and FVC o Reduction in total IgE o Reduction in inhaled corticosteroids 	Diarrhea
De Beule et al [11]	Prospective observational cohort study	N = 5 (of 137 patients with different forms of aspergillosis)	Itraconazole	Symptoms Microbiology	<ul style="list-style-type: none"> o Symptomatic improvement in 4 of 5 patients o Sterilization of sputum cultures in 3 of 4 patients with growth of <i>Aspergillus</i> species at baseline 	Among the total cohort (N = 137), 18% had adverse effects. Dyspepsia, abdominal pain, nausea, diarrhea, dizziness were most common.
Denning et al [12]	Case series	N = 6 (N = 3 with asthma)	Itraconazole 200 mg twice daily	Symptoms Biomarkers Corticosteroids	<ul style="list-style-type: none"> o Symptomatic improvement in 3 of 3 patients o Reduction in serum IgE by ≥50% in 2 of 3 patients o Reduction in corticosteroid requirement in 1 of 3 patients 	Decreased libido
Pacheco et al [13]	Case report	N = 1	Itraconazole 200 mg/day	Biomarkers PFTs Corticosteroids	<ul style="list-style-type: none"> o Reduction in <i>Aspergillus</i>-specific serum IgG levels o Improvement in FEV₁ by 19% and in FVC by 28% o Reduction in corticosteroid requirement 	Not specified
Germaud and Tuchais [14]	Observational cohort study	N = 12 (N = 9 with asthma)	Itraconazole 200 mg/day	Symptoms Biomarkers Corticosteroids	<ul style="list-style-type: none"> o Overall response (clinical, laboratory, radiographic) in 11 patients o Reduction in mean eosinophilia ~50% o Reduction in mean serum IgE ~70% o No change in <i>Aspergillus</i>-specific IgE o <i>Aspergillus</i> precipitating antibodies became negative in 7 patients o Reduction in corticosteroid use in 6 patients 	None
Nikaido et al [15]	Case report	N = 1	Itraconazole 100–150 mg/day	Biomarkers Radiology	<ul style="list-style-type: none"> o Reduction in IgE and eosinophilia o Improvement in radiographic pulmonary infiltrates 	None
Salez et al [16]	Prospective observational cohort study	N = 14	Itraconazole 200 mg/day	ABPA exacerbations PFTs Biomarkers Corticosteroids	<ul style="list-style-type: none"> o Mean number of exacerbations reduced from 2.4/year to 0.9/year ($P < .01$) o Improvement in FEV₁ and FEF25–75 o Reduction in eosinophilia by 50% o Reduction in serum IgE by 50% o Reduction in precipitating antibodies to <i>Aspergillus fumigatus</i> by 70% o Decrease in corticosteroid use 	None
Stevens et al [2]	Double-blind, placebo-controlled RCT	N = 55, followed by open label trial in 50 patients	Itraconazole 200 mg twice daily for 16 weeks, followed by itraconazole 200 mg/day for 16 weeks	Symptoms PFTs Biomarkers Radiology Corticosteroids	<ul style="list-style-type: none"> o Overall response in 13 of 28 vs 5 of 27 patients receiving itraconazole versus placebo, respectively ($P = .04$) o Improved exercise tolerance by ≥25% o Improvement in ≥1 PFT o Reduction in total IgE by ≥50% o Reduction in corticosteroids by ≥50% o No differences in improvement in radiographic pulmonary infiltrates 	No difference between itraconazole (89%) versus placebo (85%) Presumed itraconazole-related: hair loss, dry mouth, hand tremors, increased perspiration, gastritis, diarrhea, constipation, forgetfulness, fatigue, and stomach cramps

Table 1. Continued

Reference	Study Design	Number of Patients	Compound(s)	Outcome Variables	Results	Adverse Effects
Wark et al [3]	Double-blind, placebo-controlled RCT	N = 29	Itraconazole 400 mg daily versus placebo	ABPA exacerbations PFTs Biomarkers	<ul style="list-style-type: none"> Median number of asthma exacerbations requiring prednisone: zero with itraconazole and 15 with placebo, $P = .03$ No significant differences in FEV₁ or PEF Significant reduction in median total serum IgE ($P < .01$), sputum eosinophils ($P < .01$), and specific IgG to <i>A fumigatus</i> in itraconazole-treated patients 	Nausea (1 of 15 itraconazole-treated patients)
Coop et al [17]	Case report	N = 1	Itraconazole	Symptoms Biomarkers Radiology	<ul style="list-style-type: none"> Symptomatic improvement Reduction in total IgE by >50% Improvement in radiographic pulmonary infiltrates 	Not specified
Ferrari et al [18]	Case report	N = 1	Itraconazole 200 mg twice daily	Symptoms Lung function	<ul style="list-style-type: none"> Symptomatic improvement Improvement in FEV₁ from 25% to 47% and in FVC from 42% to 72% 	Renal failure and rhabdomyolysis
Rai et al [19]	Retrospective cohort study	N = 28 (including 13 patients treated with itraconazole and 15 controls)	Itraconazole 200 mg daily	Symptoms Corticosteroids	<ul style="list-style-type: none"> Symptomatic improvement in 11 of 13 treated patients Decreased requirement for rescue and maintenance corticosteroids in patients receiving itraconazole vs no antifungal therapy 	None
Erwin and Fitzgerald [20]	Case report	N = 1	Itraconazole followed by voriconazole	Symptoms Biomarkers Corticosteroids	<ul style="list-style-type: none"> Itraconazole: no change in symptoms, transient decrease in corticosteroid exposure Voriconazole: Symptomatic improvement, decrease in IgE by >50%, tapered off systemic corticosteroids 	Not specified
Pasqualotto et al [21]	Retrospective cohort study	N = 11 (of 33 patients total; the other 22 patients had SAFS)	Itraconazole 100–450 mg daily	PFTs Biomarkers Corticosteroids	<ul style="list-style-type: none"> Increased median FEV₁ ($P = .08$) Reduction in serum IgE by 37% ($P = .005$) Reduction in eosinophilia by 27% ($P = .4$) Reduction in corticosteroid dose by 43% ($P = .109$) 	Tendinitis Edema Diarrhea and rash Abnormal liver function tests Abdominal pain
Santos et al [22]	Case report	N = 1	Itraconazole 200 mg/day	Symptoms PFTs Biomarkers Radiology Corticosteroids	<ul style="list-style-type: none"> Symptomatic improvement Improvement in FEV₁ and FVC Reduction in serum IgE and eosinophilia Improvement in radiographic pulmonary infiltrates Reduction in corticosteroid dose 	None
Tang and Zhang [23]	Case report	N = 1	Itraconazole 400 mg/day	Symptoms ABPA exacerbations PFTs Biomarkers Radiology	<ul style="list-style-type: none"> Symptomatic improvement and decrease in number of ABPA exacerbations No changes in PFTs Reduction in serum IgE No improvement in radiographic pulmonary infiltrates 	Not specified
Kirschner et al [24]	Case report	N = 1	Voriconazole 300 mg twice daily	Symptoms Radiology	<ul style="list-style-type: none"> Resolution of symptoms Improvement in radiographic pulmonary infiltrates 	Not specified
Chishimba et al [4]	Retrospective observational cohort study	N = 20 with ABPA and 5 with SAFS (N = 17 with ABPA and asthma)	Voriconazole 300–600 mg/day or Posaconazole 800 mg/day	Symptoms PFTs Biomarkers Radiology Quality of life	<ul style="list-style-type: none"> Clinical response at 6 months in 73% with voriconazole and 78% with posaconazole^b No significant changes in FEV₁ or FVC Median total IgE decrease by 27% at 12 months Improvement radiographic pulmonary infiltrates in 57% with voriconazole and 50% posaconazole Quality of life improvement in 66% with voriconazole and 78% with posaconazole 	Adverse effects occurred in 40% with voriconazole and 22% with posaconazole

Table 1. Continued

Reference	Study Design	Number of Patients	Compound(s)	Outcome Variables	Results	Adverse Effects
Chishimba et al [25]	Prospective observational cohort study	N = 21 (N = 11 with SAFS and N = 10 with ABPA)	NAB 10 mg twice daily	Symptoms Quality of life Asthma control PFTs Corticosteroids	<ul style="list-style-type: none"> o Clinical response in 3 of 21 (14%) patients (improvement in asthma control, quality of life, and FEV₁ and reduction in corticosteroids) o Adverse events in 12 (57%) patients 	Adverse events in 12 (57%) patients Acute bronchospasm in 7 (33%) patients
Ram et al [10]	Open-label RCT	N = 21	NAB 10 mg twice daily for 3 days per week and NEB versus NEB alone	ABPA exacerbations PFTs Biomarkers Asthma control	<ul style="list-style-type: none"> o No difference in time to first ABPA exacerbation (primary outcome) o Decreased number of ABPA exacerbations in NAB group (1 of 12 patients) vs NEB group (6 of 9 patients) o No significant differences in FEV₁ or FVC, total IgE, or asthma control questionnaire scores between the 2 groups 	Bronchospasm in 3 NAB patients

Abbreviations: ABPA, allergic bronchopulmonary aspergillosis; FEF, forced expiratory flow; FEV₁, forced expiratory volume; FVC, forced vital capacity; Ig, immunoglobulin; NAB, nebulized amphotericin B; NEB, nebulized budesonide; PEF, peak expiratory flow; PFTs, pulmonary function tests; RCT, randomized clinical trial; SAFS, severe asthma with fungal sensitization.

^aAntifungal agents include itraconazole, voriconazole, posaconazole, isavuconazole, NAB.

^bOutcomes include the 20 ABPA patients only.

exercise tolerance was the best it had been in years. She generally tolerated isavuconazole well, with the exception of watery diarrhea that she attributed to the drug and that lingered for several weeks after stopping therapy. The serum AST and ALT remained within normal limits.

The patient continued to feel well throughout the fall 2015 and was maintained on budesonide-formoterol. On repeat PFTs, the FEV₁ had improved to 2.42L, and the FEV₁/FVC was 68%. In January 2016, sputum production and wheezing increased, consistent with an ABPA exacerbation. The patient resumed isavuconazole in March 2016 with the same loading dose. Again she had marked symptomatic improvement, and she participated in 5 hiking trips during the spring and summertime. She stopped isavuconazole in May 2016. Pulmonary function tests were repeated in July 2016 and were within normal limits (FEV₁ 2.43L, FVC 3.39L, FEV₁/FVC 72%) (Figure 1). As of January 2017, she continues to have minimal respiratory symptoms, and she has remained off systemic corticosteroids and weaned inhaled corticosteroids to 1 puff of budesonide/formoterol daily.

REVIEW OF THE LITERATURE

We identified 3 randomized clinical trials and 16 observational studies (7 observational cohort studies, 1 case series, and 8 case reports) of itraconazole, voriconazole, posaconazole, and nebulized amphotericin B for the treatment of ABPA in patients with asthma (Table 1).

DISCUSSION

To our knowledge, this is the first report of the use of isavuconazole for treatment of ABPA. Based on this patient's favorable clinical and physiologic response to isavuconazole, we believe that isavuconazole is a viable treatment option for patients with ABPA.

Isavuconazonium sulfate is a prodrug of the active triazole moiety, isavuconazole. Similar to other triazoles, isavuconazole prevents fungal cell membrane synthesis via inhibition of lanosterol-14 α -demethylase. Isavuconazole has in vitro activity against many yeasts and moulds including *Aspergillus* species, Mucorales, *Fusarium* species, and dematiaceous molds.

Isavuconazole reduces fungal burden and improves clinical outcomes in experimental models of disseminated candidiasis and aspergillosis [6, 7]. In humans, a randomized, controlled clinical trial of patients with invasive aspergillosis and other filamentous fungal infections (SECURE trial) demonstrated that isavuconazole had comparable survival rates to that of voriconazole and was safer and better tolerated [8]. This trial, combined with preclinical data, led to the approval of isavuconazole for primary therapy of invasive aspergillosis in the United States and in Europe in 2015.

The patient reported herein tolerated isavuconazole well, had marked symptomatic improvement, and demonstrated a striking physiologic response in that her FEV₁/FVC ratio normalized

for the first time in 7 years after ABPA diagnosis. This impact on PFTs after taking isavuconazole suggests that it was more effective than voriconazole, although we cannot exclude the possibility that prior courses of voriconazole or improved asthma symptom management also contributed to the difference. Of note, isavuconazole also had a corticosteroid-sparing effect for the patient thus reducing the risk for short-term and long-term adverse effects.

A potential explanation for the relatively greater response to treatment with isavuconazole versus voriconazole is that isavuconazole achieved higher drug exposure and a more rapid clearance of organism in comparison to voriconazole, for which therapeutic drug monitoring was not performed. An alternate explanation for subtherapeutic concentrations of voriconazole may be the phenomenon of autoinduction [9]. An advantage of isavuconazole is its predictable linear pharmacokinetics.

Treatment with isavuconazole is generally safe and well tolerated, a key distinguishing feature of the drug compared with other ABPA therapies. Unique adverse reactions among patients receiving voriconazole include transient vision changes, visual hallucinations, and photosensitivity [4]. Among patients on long-term therapy, periostitis and squamous cell carcinoma are concerns. Itraconazole is associated with gastrointestinal upset, congestive heart failure, rash, and increased liver enzymes. Posaconazole is associated with gastrointestinal upset depending on the formulation, and there are sparse data supporting its use for ABPA. Nebulized amphotericin B causes coughing and bronchospasm during inhalation [10].

CONCLUSIONS

In summary, we present the first report of a patient with underlying asthma and ABPA to be successfully treated with isavuconazole with minimal adverse effects. Based on this case report, we suggest consideration of an open-label or randomized trial of isavuconazole versus voriconazole for the treatment of ABPA in patients with underlying asthma.

Acknowledgments

T. J. W. is a Scholar of the Save Our Sick Children Foundation and a Scholar of the Sharp Family Foundation in Pediatric Emerging Infectious Diseases.

Financial support. This work was funded in part by the Save Our Sick Children Foundation (to T. J. W.).

Potential conflicts of interest. T. J. W. has received research grants for experimental and clinical antimicrobial pharmacotherapeutics from Astellas, Cubist, Novartis, Merck, Pfizer, Allergan, and Theravance. He also has served as consultant to Astellas, ContraFect, Cubist, Draisi, iCo, Novartis, Pfizer, Methylgene, SigmaTau, and Trius. All authors have submitted the ICMJE Form for Disclosure of Potential Conflicts of Interest. Conflicts that the editors consider relevant to the content of the manuscript have been disclosed.

References

1. Agarwal R, Chakrabarti A, Shah A, et al. Allergic bronchopulmonary aspergillosis: review of literature and proposal of new diagnostic and classification criteria. *Clin Exp Allergy* **2013**; 43:850–73.
2. Stevens DA, Schwartz HJ, Lee JY, et al. A randomized trial of itraconazole in allergic bronchopulmonary aspergillosis. *N Engl J Med* **2000**; 342:756–62.
3. Wark PA, Hensley MJ, Saltos N, et al. Anti-inflammatory effect of itraconazole in stable allergic bronchopulmonary aspergillosis: a randomized controlled trial. *J Allergy Clin Immunol* **2003**; 111:952–7.
4. Chishimba L, Niven RM, Cooley J, Denning DW. Voriconazole and posaconazole improve asthma severity in allergic bronchopulmonary aspergillosis and severe asthma with fungal sensitization. *J Asthma* **2012**; 49:423–33.
5. Patterson TF, Thompson GR 3rd, Denning DW, et al. Practice guidelines for the diagnosis and management of aspergillosis: 2016 update by the Infectious Diseases Society of America. *Clin Infect Dis* **2016**; 63:1–60.
6. Warn PA, Sharp A, Mosquera J, et al. Comparative in vivo activity of BAL4815, the active component of the prodrug BAL8557, in a neutropenic murine model of disseminated *Aspergillus flavus*. *J Antimicrob Chemother* **2006**; 58:1198–207.
7. Kovanda LL, Petraitiene R, Petraitis V, et al. Pharmacodynamics of isavuconazole in experimental invasive pulmonary aspergillosis: implications for clinical breakpoints. *J Antimicrob Chemother* **2016**; 71:1885–91.
8. Maertens JA, Raad II, Marr KA, et al. Isavuconazole versus voriconazole for primary treatment of invasive mould disease caused by aspergillus and other filamentous fungi (SECURE): a phase 3, randomised-controlled, non-inferiority trial. *Lancet* **2015**; 6736:1–10.
9. Moriyama B, Elinoff J, Danner RL, et al. Accelerated metabolism of voriconazole and its partial reversal by cimetidine. *Antimicrob Agents Chemother* **2009**; 53:1712–4.
10. Ram B, Aggarwal AN, Dhooria S, et al. A pilot RCT of nebulized amphotericin B for maintenance of remission in patients with allergic bronchopulmonary aspergillosis. *J Asthma* **2015**; 53:517–24.
11. De Beule K, De Doncker P, Cauwenbergh G, et al. The treatment of aspergillosis and aspergilloma with itraconazole, clinical results of an open international study (1982–1987). *Mycoses* **1988**; 9:476–85.
12. Denning DW, Van Wye JE, Lewiston NJ, Stevens DA. Adjunctive therapy of allergic bronchopulmonary aspergillosis with itraconazole. *Chest* **1991**; 100:813–9.
13. Pacheco A, Martin JA, Cuevas M. Serologic response to itraconazole in allergic bronchopulmonary aspergillosis. *Chest* **1993**; 103:980–1.
14. Germaud P, Tuchsais E. Allergic bronchopulmonary aspergillosis treated with itraconazole. *Chest* **1995**; 107:883.
15. Nikaido Y, Nagata N, Yamamoto T, et al. A case of allergic bronchopulmonary aspergillosis successfully treated with itraconazole. *Respir Med* **1998**; 92:118–9.
16. Salez F, Bricchet A, Desurmont S, et al. Effects of itraconazole therapy in allergic bronchopulmonary aspergillosis. *Chest* **1999**; 116:1665–8.
17. Coop C, England RW, Quinn JM. Aspergillosis masquerading as invasive pulmonary aspergillosis. *Allergy Asthma Proc* **2004**; 25:263–6.
18. Ferraro M, Bodini I, Lo Cascio V. Rhabdomyolysis after the administration of itraconazole to an asthmatic patient with bronchopulmonary aspergillosis. *Respiration* **2004**; 71:289–91.
19. Rai SP, Panda BN, Bhargava S. Treatment of allergic bronchopulmonary aspergillosis with fluconazole and itraconazole. *Med J Armed Forces India* **2004**; 60:128–30.
20. Erwin GE, Fitzgerald JE. Case report: allergic bronchopulmonary aspergillosis and allergic fungal sinusitis successfully treated with voriconazole. *J Asthma* **2007**; 44:891–5.
21. Pasqualotto AC, Powell G, Niven R, Denning DW. The effects of antifungal therapy on severe asthma with fungal sensitization and allergic bronchopulmonary aspergillosis. *Respirology* **2009**; 14:1121–7.
22. Santos A, Loureiro G, Faria E, Chieira C. Itraconazole, an effective adjunctive treatment for allergic bronchopulmonary aspergillosis. *J Investig Allergol Clin Immunol* **2009**; 19:404–8.
23. Tang R, Zhang HY. Aspirin induced asthma accompanied with allergic bronchopulmonary aspergillosis: a case report. *Chin Med J (Engl)* **2010**; 123:2489–92.
24. Kirschner AN, Kuhlmann E, Kuzniar TJ. Eosinophilic pleural effusion complicating allergic bronchopulmonary aspergillosis. *Respiration* **2011**; 82:478–81.
25. Chishimba L, Langridge P, Powell G, et al. Efficacy and safety of nebulised amphotericin B (NAB) in severe asthma with fungal sensitisation (SAFS) and allergic bronchopulmonary aspergillosis (ABPA). *J Asthma* **2015**; 52:289–95.