

# Successful repair of an arteriovesical fistula as a complication after coil embolization for right hypogastric artery aneurysm

Jackie Zhang, MD,<sup>a</sup> Rafael Santini Dominguez, MD,<sup>a</sup> Sunny Sahajwani, MD,<sup>a</sup> Michael Phelan, MD,<sup>b</sup> and John Karwowski, MD,<sup>a</sup> *Baltimore, Md*

## ABSTRACT

An 84-year-old man has a history of a right hypogastric artery aneurysm that was excluded with endograft several years ago. His course was complicated by a type II endoleak with an enlarging aneurysm that required multiple attempts of coil embolization. Several years later, he presented with gross hematuria and was found to have embolization coils extruding into his bladder and an arteriovesical fistula. As seen in this case, endovascular intervention for a type II endoleak is not benign. We describe a novel complication of an arteriovesical fistula that necessitated a difficult repair and ultimate revascularization. (*J Vasc Surg Cases and Innovative Techniques* 2020;6:585-7.)

**Keywords:** Iliac aneurysm; Endoleak; Postoperative complication; Vascular grafting; Urinary bladder fistula

The high mortality of ruptured isolated iliac artery aneurysms necessitates elective repair for those with diameters of greater than 3 cm,<sup>1,2</sup> although more recent studies suggest surveillance until at least 4 cm.<sup>3</sup> When anatomically feasible, endovascular iliac artery aneurysmal repair (EVIAR) is preferred over an open approach. Type II endoleak is a common complication after EVIAR.<sup>4,5</sup>

A type II endoleak can often be closely observed, and intervention is only advised for aneurysms with evidence of growth, although large aneurysms may also be subjected to intervention because they are thought to be more likely to rupture.<sup>6</sup> When indicated, a type II endoleak is repaired endovascularly to prevent retrograde collateral flow to the growing aneurysmal sac. However, this approach carries significant odds of failure, high recidivism rates, frequent reinterventions,<sup>7</sup> and, as seen in this case, are not without complication.

We describe a complex open repair of an arteriovesical fistula, a rare complication from multiple attempts of coil embolotherapy of a type II endoleak in a right

hypogastric artery aneurysm. The patient provided consent for the publication of this article.

## CASE REPORT

An 84-year-old man presented to clinic with gross hematuria. He was several years status post EVIAR for a right hypogastric artery aneurysm that was excluded with outflow branch coiling and coverage of the hypogastric ostium using an endograft spanning from the right common iliac artery (CIA) to the external iliac artery. However, the coiling of outflow branches proved incomplete. The aneurysm continued to enlarge owing to type II endoleak despite multiple attempts of percutaneous translumbar coil embolizations, one of which was complicated by retroperitoneal hemorrhage requiring admission and multiple transfusions. Four years after the last intervention, he was seen by urology for hematuria, where cystoscopy revealed several embolization coils extruding into the posterior aspect of the bladder (*Fig 1*). Visualization on computed tomography angiography imaging was challenging owing to significant coil artifact. Thus, a transfemoral catheter angiography was completed, which confirmed resolution of the endoleak, but showed a large right hypogastric aneurysmal sac that was outlined by the coils (*Fig 2*). The patient was afebrile, hemodynamically stable, and without overt signs of infection. Preoperative blood cultures and urine analysis were not drawn. Still, we had high suspicion for an indolent infection of the coils as the cause of the fistula and subsequent extrusion into the bladder. The aneurysm and endograft were assumed to be infected as well. Thus, we planned for the patient to undergo a complex joint resection and repair with urology.

Given our suspicion for an infection, we avoided using any prosthetic material in the area of the prior endograft. Hence, operative management began with an extra-anatomic left-to-right femoral-femoral bypass graft. We used an 8 mm-ringed heparin-bonded expanded polytetrafluoroethylene graft (Core PROPATEN, W. L. Gore & Associates, Flagstaff, Ariz). Once distal

---

From the Division of Vascular Surgery, Department of Surgery,<sup>a</sup> and Division of Urology,<sup>b</sup> University of Maryland Medical Center.

Author conflict of interest: none.

Presented at the Thirty-third Annual Meeting of the Eastern Vascular Society, Pittsburgh, Penn, September 5-7, 2019.


Correspondence: Jackie Zhang, MD, Department of Surgery, University of Maryland Medical Center, 22 South Greene St, Baltimore, MD 21201 (e-mail: [jackie.m.zhang@gmail.com](mailto:jackie.m.zhang@gmail.com)).

The editors and reviewers of this article have no relevant financial relationships to disclose per the Journal policy that requires reviewers to decline review of any manuscript for which they may have a conflict of interest.

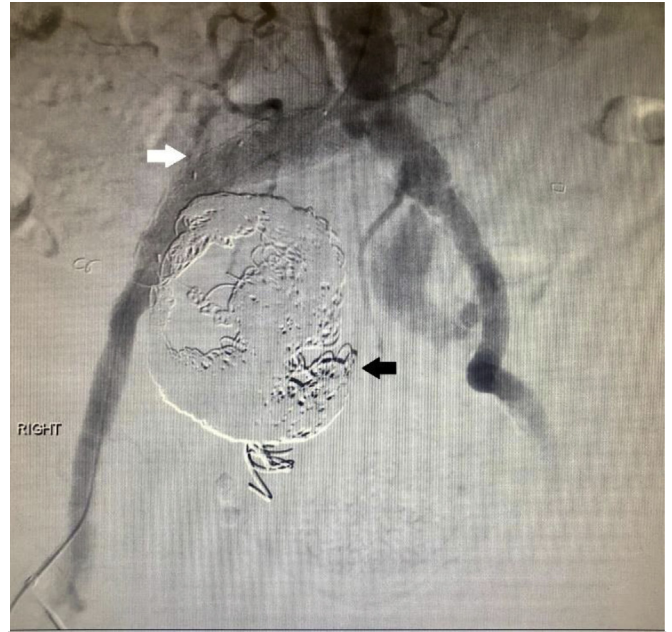2468-4287

© 2020 The Authors. Published by Elsevier Inc. on behalf of Society for Vascular Surgery. This is an open access article under the CC BY-NC-ND license (<http://creativecommons.org/licenses/by-nc-nd/4.0/>).

<https://doi.org/10.1016/j.jvscit.2020.07.020>



**Fig 1.** Angiographic coils in urinary bladder, seen on cystoscopy view.



**Fig 2.** Angiography with patent stent graft from common to external iliac artery on the right side (white arrow), no flow through proximal right internal iliac artery, and large coils protruding toward midline (black arrow).

pulses were confirmed and the revascularization deemed successful, both groins were closed and isolated.

We then sought to explant the iliac endograft, aneurysm, and coils. A midline approach was necessary to ensure adequate control of the left contralateral iliac artery for complete resection of the right iliac endograft. The aneurysm also crossed the midline, and we did not want to risk leaving any of the medial wall through a right retroperitoneal approach. Thus, via a midline laparotomy, we dissected to the retroperitoneum to gain exposure of the aortic bifurcation and bilateral iliacs including endograft. We made a longitudinal arteriotomy in the pulseless right hypogastric aneurysm and large volumes of chronic liquefied thrombus drained out under pressure. Many coils came out freely, although some were adherent to the inner lining of the aneurysm or found extruding through the wall of the aneurysm itself (Fig 3). Individual coils were also found floating freely in the retroperitoneum around the aneurysm. At that point, urology arrived to repair the iliac-cystostomy. The bladder was repaired primarily. We then proceeded with total aneurysmectomy to ensure removal of all coils.

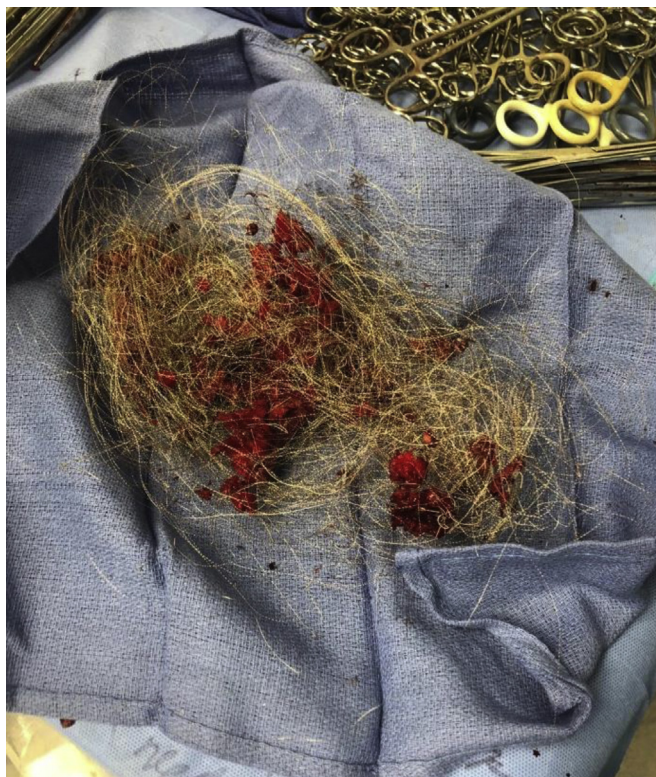We managed the endograft by cross-clamping the distal aorta below the inferior mesenteric artery and the proximal left CIA. We made a transverse arteriotomy and divided the graft at the distal right CIA, then removed both proximal and distal segments in entirety. There was obvious slime on the entire length of the endograft, which was sent for culture. The right external and CIAs were isolated and oversewn to ensure there was no retrograde bleeding. The aortic clamp was released and circulation was restored to the left CIA and right lower extremity via the femoral-femoral bypass. Hemostasis was achieved, and the abdomen was closed. The patient was transferred to intensive care in a hemodynamically stable condition with warm lower extremities and palpable pulses distally.

The patient was placed on intravenous antibiotics, but otherwise had an uneventful postoperative course. Graft cultures grew *Staphylococcus epidermidis*. He was discharged with a foley catheter and intravenous antibiotics. On 1-month follow-up, he continued to do well with repeat cystoscopy and computed tomography angiography showing intact bladder repair and patent bypass graft. The foley was removed. He completed his 4-week course of intravenous antibiotics and was started on life-long suppressive oral antibiotics. His only late sequela is an incisional hernia, for which he is pursuing intervention.

## DISCUSSION

The majority of isolated iliac artery aneurysms are found incidentally; less commonly, patients may be symptomatic from compression or erosion owing to the growing aneurysm and rupture.<sup>1,8</sup> Historically, open repair was performed with proximal and distal ligation of the aneurysm with bypass revascularization or obliterative aneurysmorrhaphy and graft interposition.<sup>9</sup> This approach is complicated by the technical challenge of operating deep in the pelvis, the unique branching pattern of the iliac arteries, and the close proximity to adjacent viscera and nerves.<sup>10</sup> Therefore, endovascular repair is preferred.

In several retrospective studies, EVIAR was associated with a lower 30-day mortality rate and similar graft patency rates when compared with open repair.<sup>11-13</sup> Although type II endoleak is frequently benign and expected to thrombose spontaneously, it remains the most common reason for intervention after endovascular repair.<sup>5,14</sup> Similar to aortic aneurysms, intervention is



**Fig 3.** Coils from prior percutaneous translumbar coil embolizations extracted from the patient.

offered for iliac aneurysms that are growing or persistent in size as a result of the endoleak.<sup>6,14</sup>

There are a variety of mechanisms for endovascular embolization of type II endoleaks including the use of coils, thrombin, or other embolic agents.<sup>14-16</sup> However, clinical success, which is defined as no recurrence of endoleak, is very difficult to achieve without open intervention. In a 9-year retrospective review of patients seen at a large tertiary institution, albeit for type II endoleak after abdominal aortic aneurysmal repairs, Gallagher et al<sup>7</sup> showed approximately 20% clinical success after 30-month follow-up from the initial treatment. The majority of these patients required reintervention, which increased their risk for complications including blood transfusions, hematoma, and cardiac arrhythmia.

We present a novel complication from an intervention for type II endoleak. Although embolotherapy was ultimately successful after multiple attempts at eliminating the endoleak and preventing exsanguination through the arteriovesicular fistula, primary infection of the coils was the etiology for the fistula. This case should offer consideration of a prosthetic graft infection when a patient with an iliac aneurysmal treatment history presents with hematuria. Direct fistula into the bladder by the native aneurysm itself seems implausible. Bacteriology

obtained at the time of explant was consistent with a prosthetic graft infection.

Given the high recurrence rate with current therapies for type II endoleak, if treatment is necessary, the timing of surgical repair as opposed to multiple failed embolotherapy attempts, needs to be addressed.

## REFERENCES

1. Richardson JW, Greenfield LJ. Natural history and management of iliac aneurysms. *J Vasc Surg* 1988;8:165-71.
2. Kasirajan V, Hertzner NR, Beven EC, O'Hara PJ, Krajewski LP, Sullivan TM. Management of isolated common iliac artery aneurysms. *Cardiovasc Surg* 1998;6:171-7.
3. Laine MT, Bjorck M, Beiles CB, Szeberin Z, Thomson I, Altreuther M, et al. Few internal iliac artery aneurysms rupture under 4 cm. *J Vasc Surg* 2017;65:76-81.
4. Boules TN, Selzer F, Stanziale SF, Chomic A, Marone LK, Dillavou ED, et al. Endovascular management of isolated iliac artery aneurysms. *J Vasc Surg* 2006;44:29-37.
5. Veith FJ, Baum RA, Ohki T, Amor M, Adiseshiah M, Blankensteijn JD, et al. Nature and significance of endoleaks and endotension: summary of opinions expressed at an international conference. *J Vasc Surg* 2002;35:1029-35.
6. Jonker FH, Aruny J, Muhs BE. Management of type II endoleaks: preoperative versus postoperative versus expectant management. *Semin Vasc Surg* 2009;22:165-71.
7. Gallagher KA, Ravin RA, Meltzer AJ, Khan MA, Coleman DM, Graham AR, et al. Midterm outcomes after treatment of type II endoleaks associated with aneurysm sac expansion. *J Endovasc Ther* 2012;19:182-92.
8. Levi N, Schroeder TV. Isolated iliac artery aneurysms. *Eur J Vasc Endovasc Surg* 1998;16:342-4.
9. Dix FP, Titi M, Al-Khaffaf H. The isolated internal iliac artery aneurysm - a review. *Eur J Vasc Endovasc Surg* 2005;30:119-29.
10. Rana MA, Kalra M, Oderich GS, de Grandis E, Glociczki P, Duncan AA, et al. Outcomes of open and endovascular repair for ruptured and nonruptured internal iliac artery aneurysms. *J Vasc Surg* 2014;59:634-44.
11. Patel NV, Long GW, Cheema ZF, Rimar K, Brown OM, Shanley CJ. Open vs. endovascular repair of isolated iliac artery aneurysms: a 12-year experience. *J Vasc Surg* 2009;49:1147-53.
12. Pitoulias GA, Donas KP, Schulte S, Horsch S, Papadimitriou DK. Isolated iliac artery aneurysms: endovascular versus open elective repair. *J Vasc Surg* 2007;46:648-54.
13. Chaer RA, Barbato JE, Lin SC, Zenati M, Kent KC, McKinsey JF. Isolated iliac artery aneurysms: a contemporary comparison of endovascular and open repair. *J Vasc Surg* 2008;47:708-13.
14. Brown A, Saggi GK, Bown MJ, Sayers RD, Sidloff DA. Type II endoleaks: challenges and solutions. *Vasc Health Risk Manag* 2016;12:53-63.
15. Antoniou GA, Nassef AH, Antoniou SA, Loh CY, Turner DR, Beard JD. Endovascular treatment of isolated internal iliac artery aneurysms. *Vascular* 2011;19:291-300.
16. Avgerinos ED, Chaer RA, Makaroun MS. Type II endoleaks. *J Vasc Surg* 2014;60:1386-91.

Submitted Apr 12, 2020; accepted Jul 30, 2020.