

Available online at www.sciencedirect.com

ScienceDirect

journal homepage: www.elsevier.com/locate/radcr

Case Report

Adrenal vein sampling for ACTH-producing pheochromocytomas ^{☆,☆☆}

Nicholas Leader, MD^a, Alexander Ushinsky, MD^b, Christopher D. Malone, MD^{b,*}

^a Department of Internal Medicine, Washington University School of Medicine in Saint Louis. 660 S. Euclid Ave, CB 8066, Saint Louis, MO, USA

^b Interventional Radiology Section, Mallinckrodt Institute of Radiology at Washington University School of Medicine in Saint Louis. 510 South Kingshighway Boulevard, Saint Louis, MO, USA

ARTICLE INFO

Article history:

Received 14 June 2021

Revised 16 June 2021

Accepted 17 June 2021

Keywords:

Adrenal vein sampling

Pheochromocytoma

ACTH-producing

pheochromocytoma

Venous intervention

ABSTRACT

Adrenocorticotropic hormone (ACTH)-producing pheochromocytoma can cause a variety of clinical manifestations of excess catecholamine and corticosteroid. Anatomic localization of this source of ectopic ACTH is critical to facilitate unilateral adrenalectomy and prevent adrenal insufficiency due to bilateral adrenalectomy. Although nuclear scintigraphy remains the diagnostic gold standard, recent radiotracer supply shortages have necessitated alternative diagnostic paradigms to localize adrenal pheochromocytomas. We present a case where adrenal vein sampling (AVS) was utilized to lateralize an adrenal pheochromocytoma and discuss the approach and nuance as it differs from routine AVS for hyperaldosteronism or hypercortisolism.

© 2021 Published by Elsevier Inc. on behalf of University of Washington.

This is an open access article under the CC BY-NC-ND license

(<http://creativecommons.org/licenses/by-nc-nd/4.0/>)

Introduction

Adrenocorticotropic hormone (ACTH)-producing pheochromocytomas represent a rare form of ectopic ACTH production that results in a wide variety of clinical manifestations related to excess catecholamine and corticosteroid circulation. These tumors often present diagnostic dilemmas not only in their clinical diagnosis but also in terms of anatomical localization of the ectopic ACTH source. While standard operative man-

agement for pheochromocytomas indicates resection of the involved adrenal gland with exploration and/or resection of the contralateral gland (especially if enlarged), a unilateral approach sparing the contralateral gland has been advocated for ACTH-producing subtype [1]. Nuclear scintigraphy with Iodine-123 metaiodobenzylguanidine or Gallium-68 DOTATATE, among others are imaging modalities that can aid in detection of adrenal pheochromocytomas [2]. However, in situations where these imaging modalities are not readily available, adrenal vein sampling (AVS) can potentially provide

[☆] *Competing interests:* The authors declare that they have no known competing financial interests or personal relationships that could have appeared to influence the work reported in this paper.

^{☆☆} *Patient consent:* Informed consent was obtained from the patient to perform the adrenal vein sampling procedure under moderate sedation per institutional guidelines. All patient identifying information has been removed from the images and case report.

* Corresponding author.

E-mail address: cmalone@wustl.edu (C.D. Malone).

<https://doi.org/10.1016/j.radcr.2021.06.055>

1930-0433/© 2021 Published by Elsevier Inc. on behalf of University of Washington. This is an open access article under the CC BY-NC-ND license (<http://creativecommons.org/licenses/by-nc-nd/4.0/>)

high clinical impact in terms of both diagnosis and treatment decisions. While AVS has been well described in localizing adrenal sources of hyperaldosteronism or hypercortisolism, its detailed role in localizing ACTH-producing pheochromocytomas of the adrenal gland is less clear. Here we present a case where AVS successfully confirmed the presence of an ACTH-producing pheochromocytoma of the left adrenal gland leading to successful subsequent clinical management and outline the nuances of the procedure distinct to this clinical entity.

Case report

Institutional review board approval was not required for preparation of this case report. A 62 year old male with past medical history of type-2 diabetes, hypertension, and multiple sclerosis was admitted to our institution with right arm weakness in the setting of hyponatremia, hypokalemia, and hyperglycemia. He had been previously evaluated on multiple occasions for uncontrolled hypertension, and other metabolic abnormalities and symptoms consistent with Cushing's syndrome. During his hospitalization, he had an elevated serum cortisol level that failed to suppress with both low and high dose dexamethasone suppression tests, elevated serum and urine metanephrines and normetanephrines, and a markedly elevated ACTH level of 682 pg/mL (normal 7-63 pg/mL), pointing to a possible ectopic source of ACTH hypersecretion. Magnetic resonance (MR) of the pituitary revealing a microadenoma lead to bilateral inferior petrosal sinus sampling (IPSS), which failed to identify it as a source of ACTH hypersecretion. An MR of the abdomen demonstrated a left adrenal nodule measuring $2.8 \times 2.9 \times 3.3$ cm (Fig. 1) and thickening of the right adrenal nodule, which in the presence of elevated serum and urine metanephrines and normetanephrines raised suspicion for an ACTH-producing pheochromocytoma. Due to a global shortage of Gallium-68 DOTATATE radiotracer in late 2019, a PET/CT scan could not be obtained in a timely fashion for anatomic localization.

Given this, the interventional radiology service was consulted for AVS to localize and confirm the left adrenal nodule as an ACTH-producing pheochromocytoma. Prior to the procedure the patient was started on a phenoxybenzamine alpha-blockade. As opposed to sampling for ACTH with IPSS, stimulation with corticotropin-releasing hormone (CRH) was not necessary as it would not have influenced ectopic ACTH sources and is meant to minimize the pulsatility of the pituitary gland [3]. AVS was performed in standard fashion involving selection of the left adrenal vein with a Simmons 2 (Cook Medical, Bloomington, IN) catheter and the right adrenal vein with a Cobra 2 (Cook Medical, Bloomington, IN) catheter (Fig. 2). However, there were several specimen collection and handling considerations for sampling of ACTH from adrenal glands. For each site, a separate sample was sent each for cortisol, catecholamine fraction, and ACTH. Catecholamine fraction including epinephrine values were obtained to confirm adequate sampling of the adrenal gland, similar to that advocated for AVS in cases of hypercortisolism, and these samples were placed in pre-chilled catecholamine tubes contain-

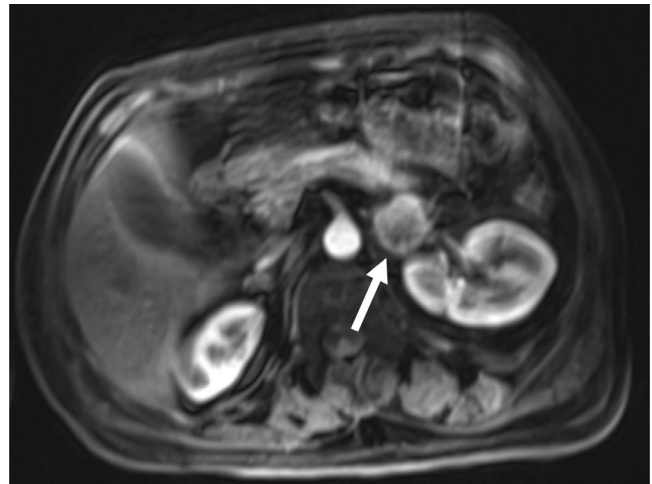

Fig. 1 – Contrast enhanced magnetic resonance (MR) image of the abdomen demonstrated a $2.8 \times 2.9 \times 3.3$ cm nodule of the left adrenal gland (white arrow)

ing EDTA-sodium metabisulfite solution on an ice slurry [4]. Blood samples for ACTH were placed in lavender-top K2 EDTA tubes also pre-chilled and on an ice slurry.

Adequate sampling of each adrenal gland was confirmed by epinephrine levels exceeding that of the periphery by greater than 100 pg/ml [4]. ACTH levels from the left adrenal gland were markedly elevated (greater than 25,000 pg/ml), and higher than that of the right adrenal gland (577 pg/ml) and periphery (725 pg/ml), confirming that this was the source of ectopic ACTH secretion. Of note, cortisol levels from the right adrenal gland were higher than that of the left (922 mcg/dL vs. 288 mcg/dL) and periphery (47.4 mcg/dL), which was hypothesized to be due to the fact that the normal right adrenal gland was more capable of responding to ACTH secretion compared to the left which was compromised by the pheochromocytoma. The patient then underwent left adrenalectomy with pathological confirmation of pheochromocytoma with adrenal cortical hyperplasia. He had a full clinical recovery and both clinical and biochemical resolution of manifestations related to excess corticosteroid and catecholamine secretion following surgery.

Discussion

Ectopic ACTH secretion can arise from a number of anatomic sources, with pituitary adenomas accounting for the majority [5]. Of these, ACTH-producing pheochromocytomas are particularly rare, representing approximately 5% of all cases [6],[7]. ACTH-producing pheochromocytomas can represent a rare source of both hypercortisolism and catecholamine excess, resulting in both uncontrolled hypertension and Cushingoid features in some patients [5],[6]. While standard operative management of adrenal pheochromocytomas advocates resection of the involved and potentially also the contralateral gland if enlarged due to the high rates of metastasis, unilateral adrenalectomy of with preservation of the contralateral

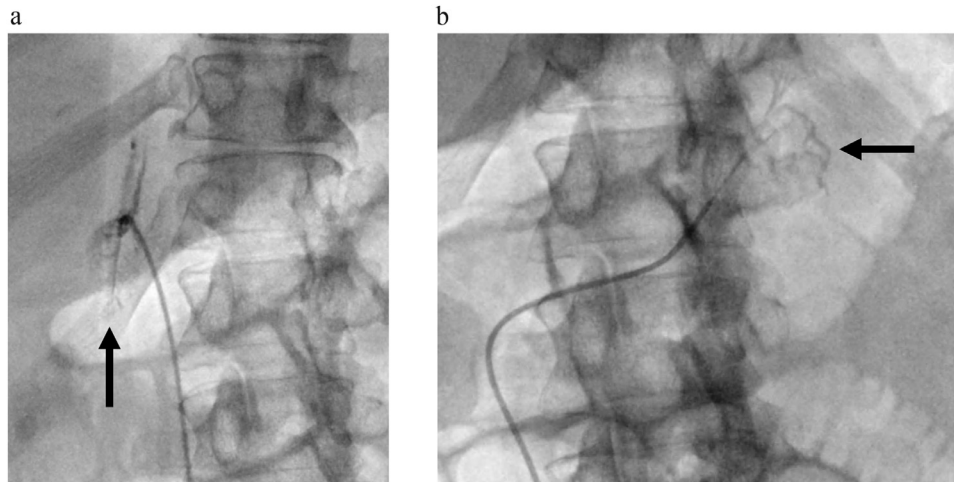


Fig. 2 – Bilateral adrenal vein sampling (AVS) was performed to confirm that the nodule of the left adrenal gland was the source of ectopic ACTH secretion. (A) Fluoroscopic contrast injection image of a Simmons-2 catheter (Cook Medical, Bloomington, IN) in the left adrenal vein shows the typical appearance of the left adrenal vein with capsular branches (black arrow) involving the known nodule on that side. (B) Fluoroscopic contrast injection image of a Cobra-2 catheter (Cook Medical, Bloomington, IN) in the right adrenal vein shows the typical branch-like pattern of the right adrenal vein. Epinephrine levels from samples from both adrenal veins were markedly elevated compared to the periphery (greater than 100 pg/ml) confirming adequate sampling

gland has been suggested specifically with ACTH-producing subtypes to preserve long term adrenal function and minimize morbidity [1]. Therefore, the correct localization and biochemical characterization of this pheochromocytoma subtype can have high clinical impact by facilitating curative surgical treatment and sparing the unaffected adrenal gland.

AVS is not typically utilized for the diagnosis and characterization of adrenal pheochromocytomas due to the wide range of normal catecholamine values in patients without pheochromocytomas [8]. However, we present a case here where adrenal sampling of ACTH provided a confirmatory diagnosis in the ACTH-producing subtype. In this case the ACTH value from the involved adrenal gland was several folds higher than that of the contralateral gland and periphery, confirming that this was the ectopic ACTH source. While the technical aspects of AVS are the same as that for the more common conditions of hyperaldosteronism or hypercortisolism, the rarity of this entity requires several important considerations in the approach and sample handling for successful execution by the Interventional Radiologist. First, as opposed to IPSS, stimulation with CRH is not necessary as non-pituitary ectopic ACTH sources do not respond to this [3]. Mitigation of hypertensive crisis from potential stimulation of the pheochromocytoma by catheterization is done with phenoxybenzamine alpha-blockade prior and during the procedure. As adrenal cortisol values will be influenced by this pathology, we utilized adrenal catecholamine values as an indicator of successful adrenal vein sampling as described by Young et al for cases of hypercortisolism [4]. Finally, the Interventional Radiologist should be prepared to obtain larger volumes of blood at each sampling position than is typically done for hyperaldosteronism due to the need to assay for additional markers such as ACTH

and catecholamines, which require placement in lavender-top K2 EDTA and EDTA-sodium metabisulfite tubes respectively both pre-chilled in an ice slurry.

This case outlines the necessary approach, patient preparation and blood sample handling for successful AVS to identify this rare condition. Given the advocated unilateral adrenalectomy approach for ACTH-producing pheochromocytomas, localization and confirmation though AVS can provide high clinical impact.

REFERENCES

- [1] Chen H, Doppman JL, Chrousos GP, Norton JA, Nieman LK, Udelsman R. Adrenocorticotrophic hormone-secreting pheochromocytomas: the exception to the rule. *Surgery* 1995;118(6):988–94 discussion 994-5PMID: 7491544. doi:10.1016/s0039-6060(05)80104-7.
- [2] Chang CA, Pattison DA, Tothill RW, Kong G, Akhurst TJ, Hicks RJ, et al. 68Ga-DOTATATE and 18F-FDG PET/CT in paraganglioma and pheochromocytoma: utility, patterns and heterogeneity. *Cancer Imaging* 2016;16:22. doi:10.1186/s40644-016-0084-2.
- [3] Ritzel K, Beuschlein F, Berr C, Osswald A, Reisch N, Bidlingmaier M, et al. ACTH after 15 min distinguishes between Cushing's disease and ectopic Cushing's syndrome: a proposal for a short and simple CRH test. *Eur J Endocrinol* 2015;173(2):197–204 Epub 2015 May 7. PMID: 25953828. doi:10.1530/EJE-14-0912.
- [4] Young WF Jr, du Plessis H, Thompson GB, Grant CS, Farley DR, Richards ML, et al. The clinical conundrum of corticotropin-independent autonomous cortisol secretion in patients with bilateral adrenal masses. *World J Surg*

- 2008;32(5):856–62 PMID: 18074172.
doi:10.1007/s00268-007-9332-8.
- [5] Folkestad L, Andersen MS, Nielsen AL, Glintborg D. A rare cause of Cushing's syndrome: an ACTH-secreting pheochromocytoma. *BMJ Case Rep* 2014;2014:bcr201420.
- [6] Gabi JN, Milhem MM, Tovar YE, Karem ES, Gabi AY, Khthir RA. Severe cushing syndrome due to an ACTH-producing pheochromocytoma: a case presentation and review of the literature. *J Endocr Soc* 2018;2(7):621–30.
- [7] Lee MN, Wan W, Chormanski DC, Kravchenko MI. Adrenal adenoma anarchy: a case of an ACTH-secreting pheochromocytoma. *Case Rep Endocrinol* 2020 26;2020:4869467.
- [8] Freel EM, Stanson AW, Thompson GB, Grant CS, Farley DR, Richards ML, et al. Adrenal venous sampling for catecholamines: a normal value study. *J Clin Endocrinol Metab* 2010;95(3):1328–32 Epub 2010 Jan 8. doi:10.1210/jc.2009-2253.